



EGYPTIAN ACADEMIC JOURNAL OF  
**BIOLOGICAL SCIENCES**  
**ZOOLOGY**


**B**



ISSN  
2090-0759

[WWW.EAJBS.EG.NET](http://WWW.EAJBS.EG.NET)

**Vol. 11 No. 3 (2019)**



**First Comparative Redescription of Six Types of Larval Stages of *Hysterothylacium* sp. (Nematoda: Raphidascarididae) From Red Sea Fishes at Hurghada, Egypt**

**Refaat M.A. Khalifa<sup>1</sup>, Abdel-Nasser A. Hussein<sup>2</sup>, and Zeinab T.M. Abdel-Ghaffar<sup>2</sup>**

1-Parasitology Department, Faculty of Medicine, Assiut University, Assiut

2-Zoology Department, Faculty of Science, South Valley University, Qena 83523, Egypt

E.Mail: Hussein.ana@sci.svu.edu.eg

**ARTICLE INFO**

Article History

Received:22/10/2019

Accepted:28/11/2019

**Keywords:**

*Hysterothylacium*;  
3<sup>rd</sup> & 4<sup>th</sup> larval  
stages, Red Sea  
fish hosts,  
Hurghada, Egypt

**ABSTRACT**

Nematodes of the genus *Hysterothylacium* (Nematoda: Raphidascarididae) infect marine fishes either with larval and adult stages. Humans can be accidentally infected upon consumption of infected seafood. Inspire of their importance, little is known about their occurrence and systematics in Egypt. During the present study, different Red Sea fishes at Hurghada (Egypt) were examined for parasitic infection. Among others four types of third-stage larvae and two types of fourth-stage larvae of *Hysterothylacium* sp. were for the first time redescribed from Egypt and compared from each other as well as from otherwise elsewhere previously described forms. Moreover, their comparative morphometry, fish hosts differences as well as their medical importance, had been discussed.

**INTRODUCTION**

*Hysterothylacium* spp. have been found to be a valid genus from the family Raphidascarididae in which the definitive hosts are piscivorous fishes (Deardroff and Overstreet, 1980). Marine fishes can act as both paratenic or intermediate and definitive hosts. In addition, species of this genus have been reported to cause human anisakidosis (Yagi *et al.*, 1996, Amores *et al.*, 2015, Andrade-Porto *et al.*, 2015). Regarding their larval stages, Shamsi *et al.* (2013 and 2015) distinguished 14 morphotypes of third and fourth larval stages from marine fishes of Australian and New Caledonian waters. From Red sea fishes at Hurghada, only Morsy *et al.* (2015) described the 4<sup>th</sup> stage larvae of a named species; *H. putagonense* from the fish host *Saurida undoquamis* (new host record from Egypt) but without distinguishing its type. Hence, the aim of the present study was to collect, distinguish and fully redescribe the different types of the encountered *Hysterothylacium* sp. larvae, identification of their fish host as an important risk factor for human infection.

## MATERIALS AND METHODS

Fishes were captured and transported as alive as possible to the Parasitology Laboratory, Zoology Department, Faculty of Science, South Valley University. Fishes were identified according to criteria of (Randall, 1983; Lieske and Myers, 2004; Lieske *et al.*, 2004) and more confirmed through the fish base (website <http://www.fishbase.org>). The gastrointestinal tract was untangled with fingers (Justine *et al.*, 2012). The whole digestive system and other viscera were opened longitudinally. Macroscopic and microscopic examination of different organs was carried out for detection of any visible nematode larval parasites. The collected larvae were cleaned by washing several times with isotonic saline solution. The relaxed larvae were preserved in bottles containing mixture of 70% alcohol and 5% glycerin for microscopical examination. The larvae were mounted on slides with few drops of lactophenol and covered by a coverslip, photographed and drawn using camera lucida. The identification of the larvae was done according to the keys of the nematode parasites of vertebrates (Yorke *et al.*, 1926; Yamaguti, 1963).

## RESULTS

Out of 29 *Parupeneus forsskali* (Barbune), two *Lethrinus variegates* (Dereiny), one *Lethrinus mahsena* (Mahsena), eight *Rhabdosargus haffara* (Haffar), two *Parupeneus cyclostomus* (Sultan Ibrahim) and two *Caesio lunaris* (Bagha) Red Sea fishes examined; different types of the third and fourth larval stages of *Hysterothylacium* sp. were found to inhabit the intestine of these fishes as shown in table1.

**Table 1:** Shows the total number of examined and infected fish species with each type of larvae stages of *Hysterothylacium* sp.

Fish host	No. of fish examined	No. of fish infected	Worm burden	Type
<i>Caesio lunaris</i>	2	1	1	IV
<i>Lethrinus mahsena</i>	1	1	2	VI
<i>Lethrinus variegates</i>	2	1	1	VI
<i>Parupeneus forsskali</i>	29	1	1	VI
		1	1	X
		1	1	XII
		1	1	XIII
<i>Rhabdosargus haffara</i>	8	1	1	XIII
<i>Parupeneus cyclostomus</i>	2	1	1	XIV

### Morphology:

#### *Hysterothylacium* sp. 3<sup>rd</sup> stage type VI (Table 2, Plates 1 & 2):

The body is very small measuring 2.71-6.20 (3.93) mm in length by 0.08-0.19 (0.12) mm in maximum width (plate 1A). Labia not developed. Esophagus muscular, measuring 246-500 (335)  $\mu$ m in length and representing 0.08-0.10 (0.08) of body length: (plate 1 B-C and plate 2A-B), distance of nerve ring from the anterior extremity 90-200 (135)  $\mu$ m. Ventriculus rounded measuring 27-70 (43)  $\mu$ m in length. The ventricular appendix has same size as esophagus measuring 246-500 (340)  $\mu$ m in length (plate 1 B). Intestinal caecum was shorter than ventricular appendix measuring 45-110 (74)  $\mu$ m in length; representing 0.22-0.25 (0.21) of esophagus length and 0.18-

0.23 (0.20) of ventricular appendix length, intestine with serpiginous pattern (plate 2A). The tail was relatively long, conical, slightly swollen at tip with a rounded tip end with a single minute spine at tip; measuring 116-170 (138)  $\mu$ m and representing 0.02-0.04 (0.03) of body length (plate 1D& plate 2C).

**Table (2):** Shows a comparison between *Hysterothylacium* sp. larva type VI (third larval stage) of the present specimens and previously described form (all measurements are in  $\mu$ m unless mentioned in mm).

Reference	Shamsi et al. (2015)	Present study
Fish host (s)	<i>Gymnocranius euanus</i> , <i>Gymnocranius superciliosus</i> , <i>Rastrelliger kanagurta</i> and <i>Sphyraena forsteri</i>	<i>Lethrinus mehseana</i> , <i>Parupeneus forsskali</i> and <i>Lethrinus variegates</i>
Locality	Off Récif Toombo and Noumèa Fishmarket	Hurghada, Safaga, Egypt in Red Sea
Site of infection	Intestinal lumen and abdominal organs	Intestine
Body length	4.78 (3.13-6.50) mm	2.71-6.20 (3.93) mm
Maximum body width	0.24 (0.15-0.33) mm	0.08-0.19 (0.12) mm
Esophagus length	0.48 (0.38-0.61) mm, 0.09 (0.08-0.11) of body length	246-500 (335), 0.08-0.10 (0.08) of body length
Nerve ring from anterior extremity	0.22 (0.18-0.28) mm	90-200 (135)
Ventriculus length	0.06 (0.05-0.08) mm	27-70 (43)
Ventricular appendix length	0.48 (0.40-0.73) mm, 2.08 (1.52-2.76) of esophagus length	246-500 (340), 1-1.07 (1.01) of esophagus length
Intestinal caecum length	0.14 (0.08-0.20) mm, 0.30 (0.21-0.43) of esophagus length, 0.29 (0.18-0.50) of ventricular appendix length	45-110 (74), 0.22-0.25 (0.21) of esophagus length, 0.18-0.23 (0.20) of ventricular appendix length
Tail length	0.14 (0.10-0.18) mm, 0.03 (0.02-0.04) of body length	116-170 (138), 0.02-0.04 (0.03) of body length

***Hysterothylacium* sp. 3<sup>rd</sup> stage type X** (Table 3, Plates 3 & 4):

The body is medium in size, whitish, finely annulated measuring 4.60 mm in length by 0.16 mm in maximum width. Labia not developed. The esophagus was muscular measuring 553 $\mu$ m in length and representing 12% of body length (plate 3B-C and plate4 A-B). The distance of the nerve ring from the anterior extremity 273  $\mu$ m. Excretory pore opening posteriorly at the level of nerve ring and measuring 340  $\mu$ m from the anterior extremity. Length of ventriculus 72  $\mu$ m. Length of ventricular appendix 598  $\mu$ m representing 1.08 times esophagus. Length of intestinal caecum was 140  $\mu$ m; representing 25% of esophagus length and 23% of ventricular appendix length (plate 3B and plate4 A). Tail with rounded tip end provided with a single spine, measuring 165  $\mu$ m and representing 3.9% of body length (plate 3D and plate4 C).

***Hysterothylacium* sp. 3<sup>rd</sup> stage type XIII** (Table 4, Plates 5 & 6):

The body is medium in size measuring 6.54-8.86 mm in length by 0.23-0.26 mm in maximum width (plate 5A), labia not developed. Esophagus long, muscular, measuring 500-680  $\mu$ m in length and representing 0.076 of body length (plate 5B-C and plate 6A-B), distance of nerve ring from the anterior extremity is 243-281  $\mu$ m. Excretory pore located anterior to the anterior end of intestinal caecum and measuring 348-586  $\mu$ m from the anterior extremity. Ventriculus is subglobular and measuring 50-96  $\mu$ m in length; Ventricular appendix length 465-635  $\mu$ m and representing 0.93 of esophagus length. The length of intestinal caecum is 160-220  $\mu$ m; representing 0.32 of esophagus length and 0.34 of ventricular appendix length; Intestine with serpiginous pattern (plate 5B and plate 6A). The tail was tapering, with a rounded tip end with a minute fine single spine at tip measuring 144-180  $\mu$ m and representing 0.020-0.022 of body length (plate 5D and plate 6C).

**Table (3):** Shows a comparison between *Hysterothylacium* sp. larva type X (third larval stage) of the present specimens and previously described form (all measurements are in  $\mu\text{m}$  unless mentioned in mm).

Reference	Shamsi <i>et al.</i> (2013)	Present study
Fish host (s)	<i>Sphyraena novaehollandiae</i>	<i>Parupeneus forsskali</i>
Locality	Port Philip Bay, Victoria	Safaga, Egypt in Red Sea
Site of infection	Intestine	Intestine
Body length	5.8 (3.9-7.1) mm	4.60 mm
Maximum body width	0.23 (0.16-0.28) mm	0.16 mm
Esophagus length	0.76 (0.58-0.90) mm, 13% (12-16%) of body length	553, 12% of body length
Nerve ring from anterior extremity	0.27 (0.16-0.40) mm	273
Excretory pore from anterior extremity	0.33 (0.19-0.48) mm	340
Ventriculus length	0.08 (0.05-0.10) mm	72
Ventricular appendix length	0.81 (0.44-1.36) mm, 1.08 (0.52-2.00) of esophagus length	598, 1.08 of esophagus length
Intestinal caecum length	0.22 (0.10-0.26) mm, 29% (17-35%) of esophagus length, 29% (15-59%) of ventricular appendix length	140, 25% of esophagus length, 23% of ventricular appendix length
Tail length	0.18 (0.13-0.26) mm, 3% (2-4%) of body length	165, 3.9% of body length

**Table (4):** Shows a comparison between *Hysterothylacium* sp. larva type XIII (third larval stage) of the present specimens and previously described forms (all measurements are in  $\mu\text{m}$  unless mentioned in mm).

Reference	Shamsi <i>et al.</i> (2015)	Present study
Fish host(s)	<i>Abalistes stellatus</i>	<i>Rhabdosargus haffara</i> and <i>Parupeneus forsskali</i>
Locality	Off Récif Toombo	Hurghada, Egypt in Red Sea
Site of infection	Intestinal lumen and abdominal organs	Intestine
Body length	9.88 mm	6.54-8.86 mm
Maximum body width	0.31 mm	0.23-0.27 mm
Esophagus length	0.75 mm, 0.076 of body length	500-680, 0.076 of body length
Nerve ring from anterior extremity	0.30 mm	243-281
Excretory pore from anterior extremity	0.62 mm	348-586
Ventriculus length	0.05 mm	50-96
Ventricular appendix length	0.70 mm, 0.93 of esophagus length	465-635, 0.93 of esophagus length
Intestinal caecum length	0.24 mm, 0.32 of esophagus length, 0.34 of ventricular appendix length	160-220, 0.32 of esophagus length, 0.34 of ventricular appendix length
Tail length	0.02 mm, 0.020 of body length	144-180, 0.020-0.022 of body length

***Hysterothylacium* sp. 3<sup>rd</sup> stage type XIV (Table 5, Plates 7 & 8):**

The body is medium in size, measuring 4.49 mm in length by 0.16 mm in maximum width (plate 7A), labia not developed. Esophagus muscular, measuring 486  $\mu\text{m}$  in length and representing 0.10 of body length (plate 7B-C and plate 8A-B), distance of nerve ring from the anterior extremity is 223  $\mu\text{m}$ ; excretory pore locates between nerve ring and intestinal caecum's tip and measuring 300  $\mu\text{m}$  from the anterior extremity. Ventriculus length 57  $\mu\text{m}$ , length of ventricular appendix 241  $\mu\text{m}$  and representing 0.49 of esophagus length; length of intestinal caecum 130  $\mu\text{m}$ ; representing 0.26 of esophagus length and 0.54 of ventricular appendix length (plate 7B and plate 8A). Tail tip bent dorsally ending to 3-4 sharp triangular minute conical

spines, measuring 122  $\mu$ m and representing 0.027 of body length (plate 7D and plate 8C).

**Table (5):** Shows a comparison between *Hysterothylacium* sp. larva type XIV (third larval stage) of the present specimens and previously described form (all measurements are in  $\mu$ m unless mentioned in mm).

Reference	Shamsi et al. (2015)	Present study
Fish host (s)	<i>Herklosichthys quadrimaculatus</i> , <i>Rastrelliger kanagurta</i> and <i>Trichiurus lepturus</i>	<i>Parupeneus cyclostomus</i>
Locality	Noumèa Fishmarket	Hurghada, Egypt in Red Sea
Site of infection	Intestinal lumen and abdominal organs	Intestine
Body length	4.93 (3.88-5.75) mm	4.49 mm
Maximum body width	0.18 (0.15-0.25) mm	0.16 mm
Esophagus length	0.66 (0.33-0.86) mm, 0.13 (0.06-0.16) of body length	486, 0.10 of body length
Nerve ring from anterior extremity	0.27 (0.22-0.33) mm	223
Excretory pore from anterior extremity	0.37 (0.31-0.43) mm	300
Ventriculus length	0.10 (0.10-0.10) mm	57
Ventricular appendix length	0.39 (0.24-0.54) mm, 0.60 (0.39-0.81) of esophagus length	241, 0.49 of esophagus length
Intestinal caecum length	0.18 (0.13-0.26) mm 0.28 (0.21-0.38) of esophagus length, 0.48 (0.35-0.63) of ventricular appendix length	130, 0.26 of esophagus length, 0.54 of ventricular appendix length
Tail length	0.18 (0.10-0.28) mm, 0.037 (0.026-0.055) of body length	122, 0.027 of body length

***Hysterothylacium* sp. 4<sup>th</sup> stage type IV (Table 6, Plates 9 & 10):**

The body was medium in size, whitish and measuring 7.31 mm in length by 0.164 mm in maximum width; cuticle characterized by fine transverse striation, with no lateral alae (plate 9A). The anterior extremity equipped by well-developed lips, a single smaller dorsal lip, and two subventrals, with deep postlabial grooves. Dorsal lip with two lateral doubled papillae, while the two subventrals equipped by mediolateral double papillae and a single lateral papilla. Esophagus long, muscular; border at its posterior bulb measuring 723  $\mu$ m in length (plate 9B-C and plate 10 A-B). The distance of nerve ring from the anterior extremity 237  $\mu$ m. Excretory pore opening posteriorly at the level of nerve ring measuring 274  $\mu$ m from the anterior extremity. Length of intestinal caecum 234  $\mu$ m and measuring 515  $\mu$ m from the tip of the anterior extremity; length of ventriculus 43  $\mu$ m. Length of ventricular appendix 789  $\mu$ m (plate 9B and plate 10A). The ratio of intestinal caecum to ventricular appendix 1:3. Anus opening separated from the posterior end of the body by 122  $\mu$ m and body width at anus 61  $\mu$ m. Tail conical with a nodulose apex (numerous minute spines) covering its tip (plate 9D and plate 10C).

***Hysterothylacium* sp. 4<sup>th</sup> stage type XII (Table 7, Plates 11 & 12):**

The body was small in size, whitish and measuring 3.22 mm in length by 0.134 mm in maximum width (plate 11A); anterior extremity equipped by well-developed lips, dorsal labium with two dorso-lateral papillae, each sub-ventral labia with one papilla. Esophagus is long, muscular; measuring 420  $\mu$ m in length, representing 13% of body length and ratio of it to body length 1:7.7 (plate 11B-C and plate 12A-B). The distance of nerve ring from anterior extremity 206  $\mu$ m. excretory pore opens posteriorly at the level of nerve ring and measuring 261  $\mu$ m from the anterior extremity. The length of ventriculus is 52  $\mu$ m. Length of ventricular appendix 295  $\mu$ m representing 71% of esophagus length; length of intestinal caecum 75  $\mu$ m; representing 18% of esophagus length and 25% of ventricular appendix length (plate 11B and plate

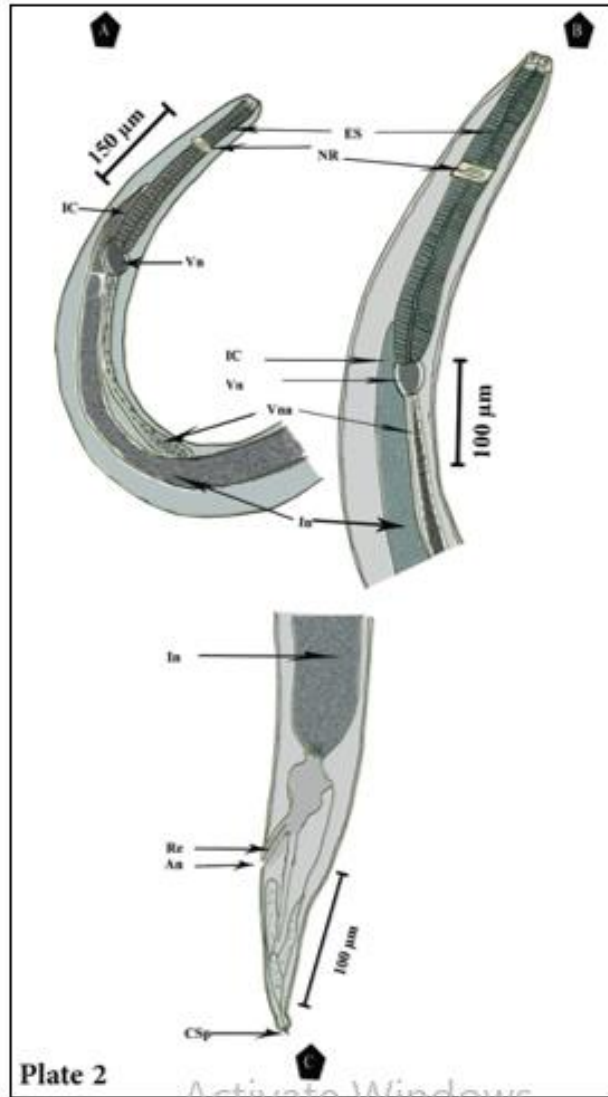

12A). Tail narrow, short, tapering with rounded tip end with a single spine; measuring 124  $\mu\text{m}$  and representing 3% of body length (plate 11D and plate 12C).

**Table (6):** Shows a comparison between *Hysterothylacium* sp. larva type IV (4<sup>th</sup> larval stage) of the present specimen and previously described forms (all measurements are in  $\mu\text{m}$  unless mentioned in mm).

Reference	Cannon (1977)	Shamsi <i>et al.</i> (2011)	Abdul Jabbar <i>et al.</i> (2012)	Shamsi <i>et al.</i> (2013)		Morryet <i>al.</i> (2015)	Li <i>et al.</i> (2016)	Zhao <i>et al.</i> (2016)	Present study
				A	B				
Fish host (s)	<i>Scaliodon jordanii</i> , <i>Lutjanus amabilis</i> , <i>Nemipterus aurifilum</i> , <i>Johnius australis</i> , <i>Sciaenops ocellatus</i> , <i>Parascoloplos aratus</i> and <i>Flounder</i>	<i>Neoplalycephalus richardsoni</i> - <i>Platycephalus</i> and <i>Aldrichetta forsteri</i>	<i>Parascirrhites forsteri</i> , <i>Chaetodon ulianensis</i> , <i>Stegastes apicalis</i> , <i>Grammatocyclops bicarinatus</i> , <i>Scemberomorus commerson</i> , <i>Cephalopholis boenak</i> , <i>Epiplatys angus</i> and <i>Caraus papuanus</i>	<i>Abudefduf whiteleyi</i> , <i>Cassio curing</i> and <i>Lutjanus argentimaculatus</i>	<i>Flindersi</i> sillago, <i>Scember australasicus</i> and <i>Sillago flindersi</i>	<i>Saurida unduquamus</i>	<i>Helleuosa stellata</i> (Yah)	<i>Pristipomoides filamentosus</i> , <i>Congreus talaboneides</i> , <i>Scemberomorus commerson</i> , <i>Scemberomorus nipponicus</i> , <i>Pennahia pawak</i> , <i>Lepidotrigla japonica</i> , <i>Uroconger lepturus</i> , <i>Rhynchoconger sclerurus</i> and <i>Polydactylus sesaricus</i>	<i>Cassio lunaris</i>
Locality	South-Eastern Queensland	South-Australian	Lizard Island, Australia	Heron Island, Queensland	Port Phillip Bay, Victoria	Hurghada, Egypt in Red Sea	East and South China Sea.	South China Sea (off Daya Gulf)	Hurghada, Egypt in Red Sea
Site of infection	Visceral cavity	Intestine, pyloric caeca, liver and pancreas	Body cavity	Encapsulated on the surface of internal organs and connective tissue	Pyloric caeca and viscera	Peritoneal cavity around the wall of the stomach as encapsulated larvae	Abdominal cavity and digestive tract	Abdominal cavity, intestine and stomach	Intestine
Body length	7.18±2.37 (3.34-12.87) mm	7.26 (2.49-19.25) mm	Not mentioned	6.4 (5.5-7.5) mm	6.0 (4.2-7.6) mm	5.5±2 (3.5-7.5) mm	8.37-13.0 mm	5.79-27.5 mm	7.31 mm
Maximum width	0.145±0.038 (0.093-0.200) mm	0.23 (0.11-0.44) mm	Not mentioned	0.14 (0.06-0.18) mm	0.20 (0.16-0.24) mm	0.1 ± 0.02 (0.08-0.12) mm	176-220	Not mentioned	0.164 mm
Body width at anus	0.066±0.013 (0.050-0.100) mm	Not mentioned	Not mentioned	Not mentioned		Not mentioned	Not mentioned	Not mentioned	61
Nerve ring from anterior extremity	0.228±0.053 (0.148-0.335) mm	0.18 (0.06-0.33) mm	0.45-0.46 (0.46) mm	0.24 (0.20-0.27) mm	0.19 (0.10-0.26) mm	Not mentioned	244-268	0.18-0.44 mm	237
Excretory pore from anterior extremity	0.270±0.052 (0.204-0.372) mm	Not mentioned	Not mentioned	0.32 mm	0.26 (0.16-0.34) mm	Not mentioned	264-293	0.21-0.52 mm	274
Anterior extremity to tip of intestinal caecum	0.563±0.147 (0.334-0.850) mm	Not mentioned	Not mentioned	Not mentioned		Not mentioned	Not mentioned	Not mentioned	515
Esophagus length	0.692±0.169 (0.409-1.000) mm	0.72 (0.45-1.16) mm	0.85-1.25 (0.94) mm	0.67 (0.46-0.80) mm	0.70 (0.54-1.04) mm	Not mentioned	610-756	0.54-1.42 mm	723
Intestinal caecum length	0.121±0.045 (0.074-0.250) mm	0.31 mm (0.10-1.05) mm	0.20 mm	0.16 (0.08-0.20) mm	0.17 (0.10-0.27) mm	Not mentioned	171-185	0.059-0.44 mm	234
Ventriculus length	0.056±0.017 (0.037-0.100) mm	Not mentioned	0.10-0.15 (0.12) mm	0.12 (0.06-0.2) mm	0.08 (0.04-0.12) mm	Not mentioned	73	0.048-0.26 mm	43
Ventricular appendix length	0.807±0.306 (0.353-1.325) mm	0.39 (0.06-1.74) mm	1.3 mm	0.8 (0.7-0.9) mm	0.93 (0.44-1.38) mm	Not mentioned	683-1124	0.57-1.93 mm	789
Tail length	0.086±0.022 (0.056-0.125) mm	0.14 (0.06-0.35) mm	0.11-0.24 (0.18) mm	0.13 (0.08-0.18) mm	0.11 (0.08-0.15) mm	0.04 (0.02-0.06) mm	122	0.068-0.27 mm	122

**Table (7):** Shows a comparison between *Hysterothylacium* sp. larva type XII (4<sup>th</sup> larval stage) of the present specimen and previously described form (all measurements are in  $\mu\text{m}$  unless mentioned in mm).

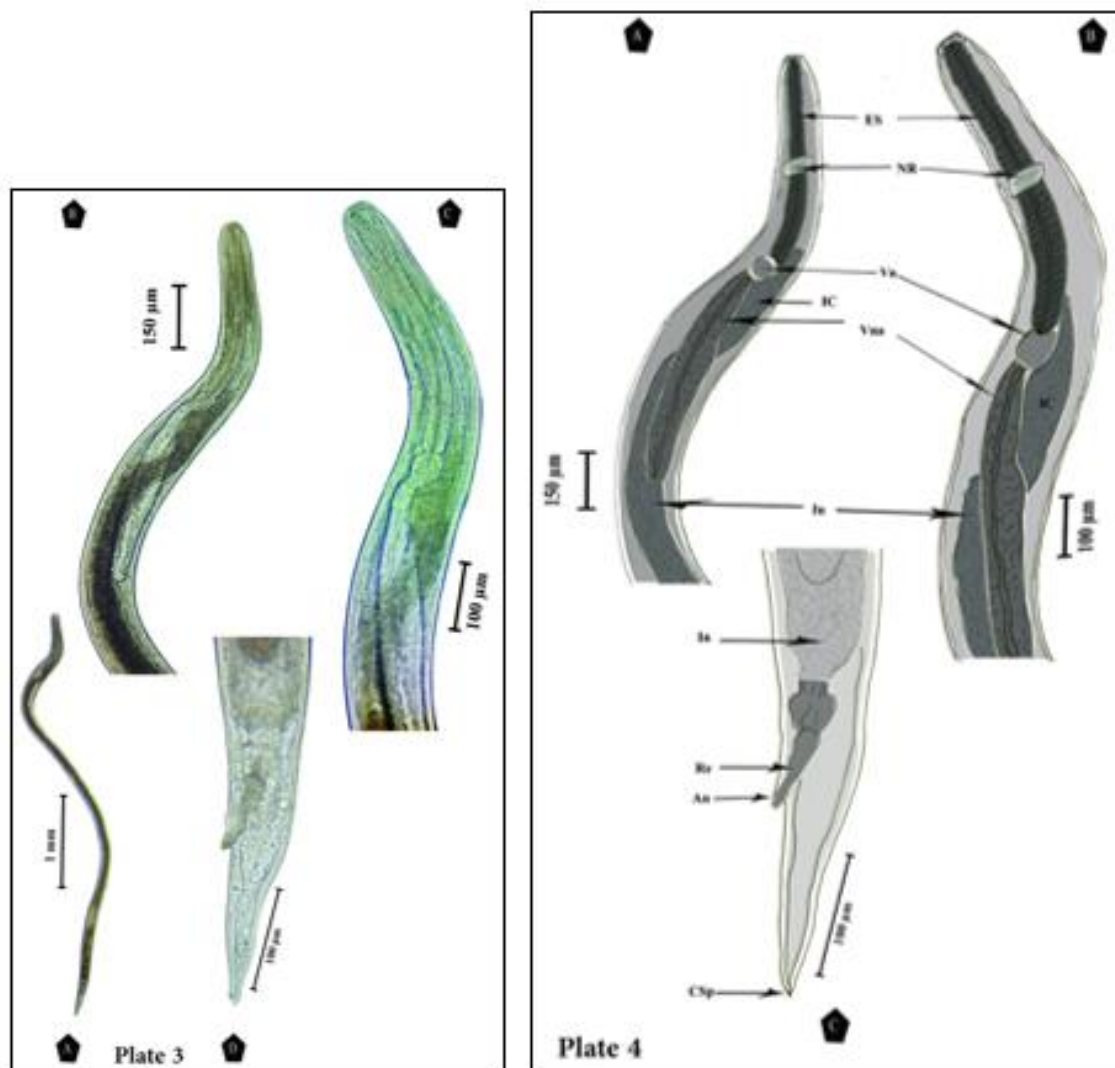
Reference	Shamsi <i>et al.</i> (2013)	Present study
Fish host (s)	<i>Lutjanus carponotatus</i>	<i>Parupeneus forsskali</i>
Locality	Heron Island, Queensland	Hurghada, Egypt in the Red Sea
Site of infection	Intestine	Intestine
Body length	4.4 mm	3.22 mm
Maximum body width	0.14 mm	0.134 mm
Esophagus length	0.56 mm, 13% of body length	420, 13% of body length
Nerve ring from anterior extremity	0.20 mm	206
Ventriculus length	0.07 mm	52
Ventricular appendix length	0.40 mm, 71% of esophagus length	295, 71% of esophagus length
Intestinal caecum length	0.10 mm, 18% of esophagus length, 25% of ventricular appendix length	75, 18% of esophagus length, 25% of ventricular appendix length
Tail length	0.14 mm, 3% of body length	124, 3% of body length



**Plate (1):** A photographs showing *Hysterothylacium* sp. (third stage larva, type VI) infecting *Rhabdosargus haffara*, *Parupeneus forsskali* and *Lethrinus variegates*.

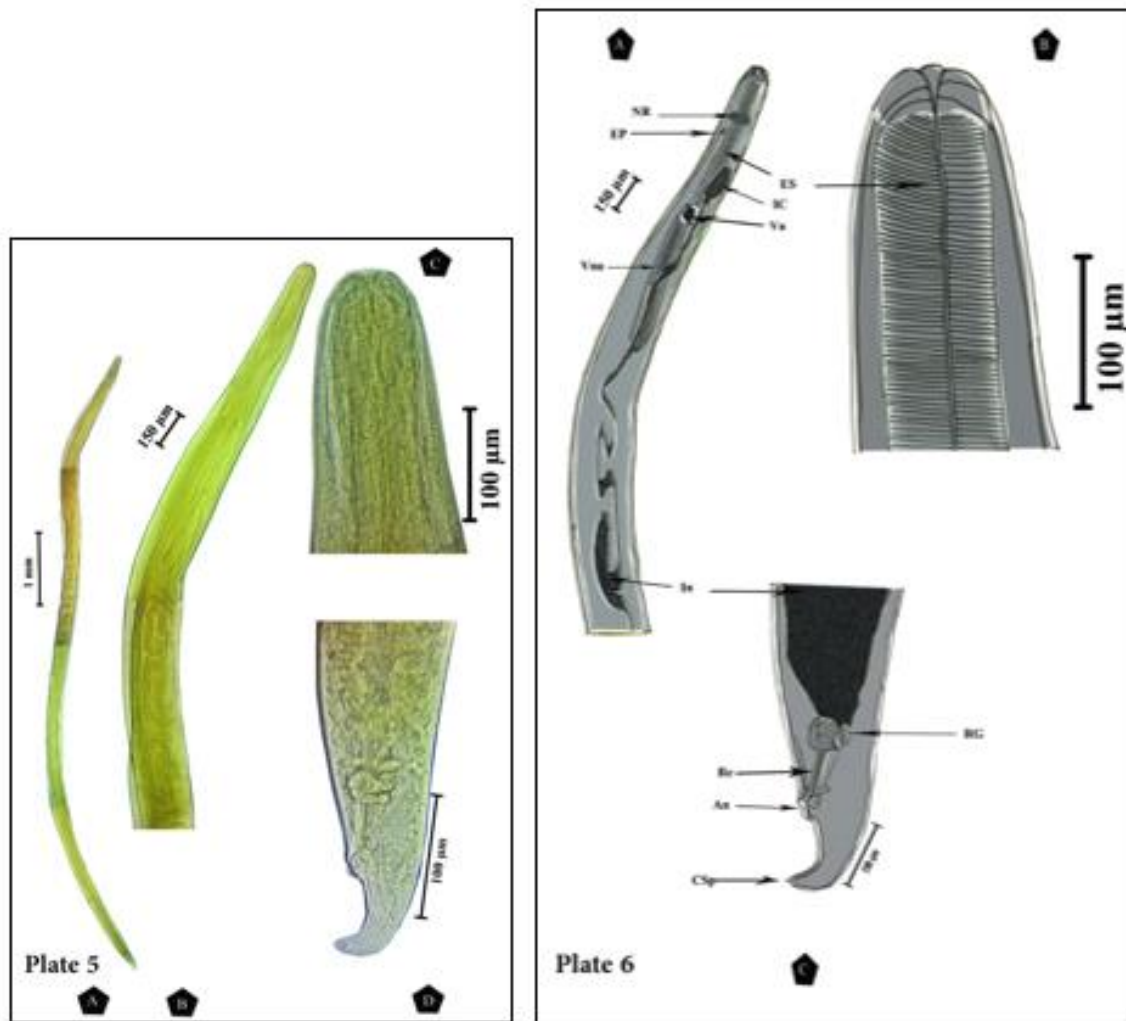
**Plate (2): Camera lucida drawings showing *Hysterothylacium* sp. (third stage larva, type VI) infecting *Rhabdosargus haffara*, *Parupeneus forsskali* and *Lethrinus variegates*: A) Lateral view of the anterior extremity of the larva showing labia not developed, nerve ring **NR**, esophagus **ES**, ventriculus **Vn**, ventricular appendix **Vna**, intestinal caecum **IC** and intestine **In**. B) High magnification of the anterior extremity of the larva showing labia not developed, nerve ring, and esophagus. C) High magnification of the posterior extremity of the larva showing its anal opening **An**, rectum **Re**. and cuticular spike **CSp****





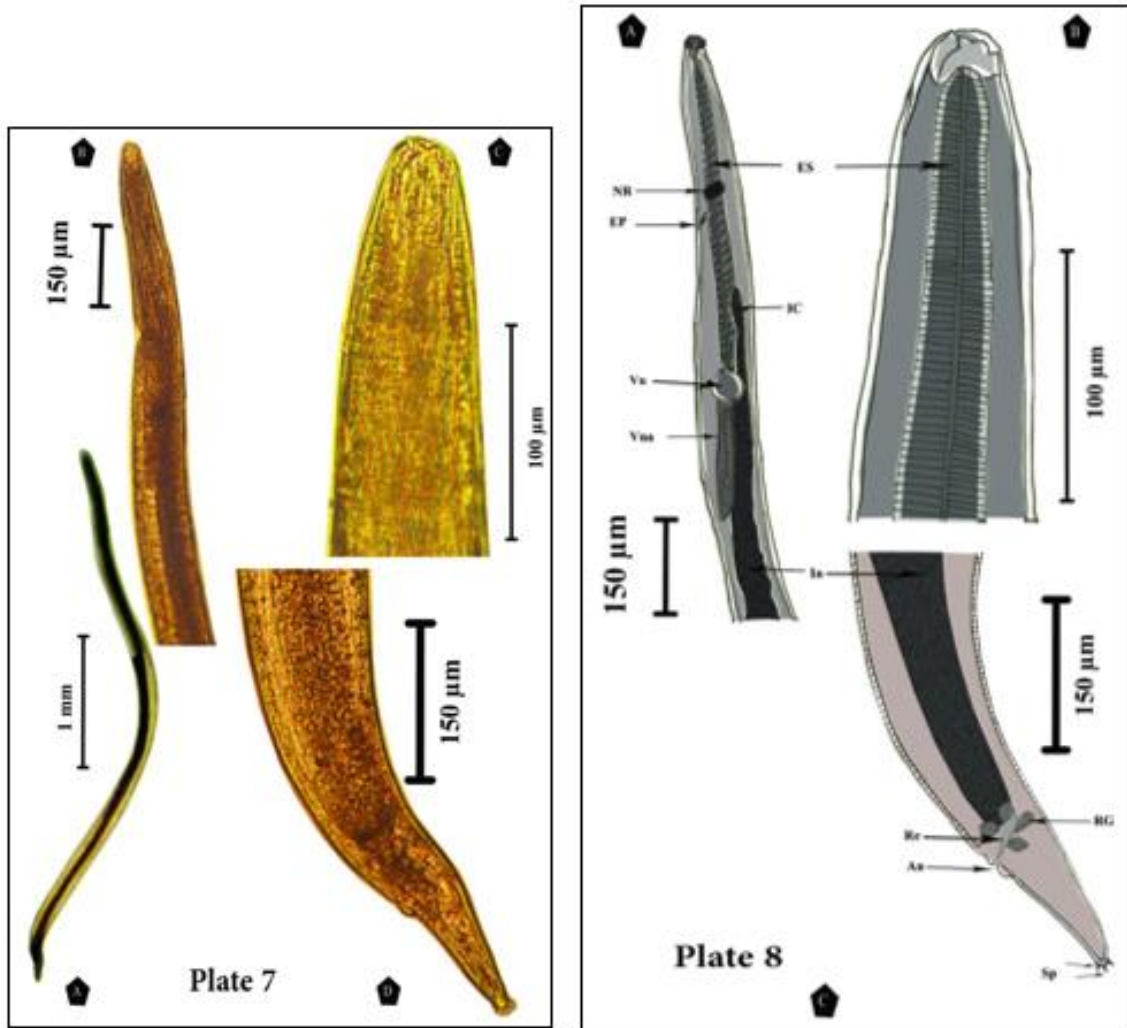
**Plate (3):** A photographs showing *Hysterothylacium* sp. (third stage larva, type X) infecting *Parupeneus forsskali*.

**Plate (4): Camera lucida drawings showing *Hysterothylacium* sp. (third stage larva, type X) infecting *Parupeneus forsskali*:** **A)** Lateral view of the anterior extremity of the larva showing labia not developed, nerve ring **NR**, esophagus **ES**, ventriculus **Vn**, ventricular appendix **Vna**, intestinal caecum **IC** and intestine **In**. **B)** High magnification of the anterior extremity of the larva showing labia not developed, nerve ring, and esophagus. **C)** High magnification of the posterior extremity of the larva showing its anal opening **An**, rectum **Re**, and cuticular spike **CSp**.



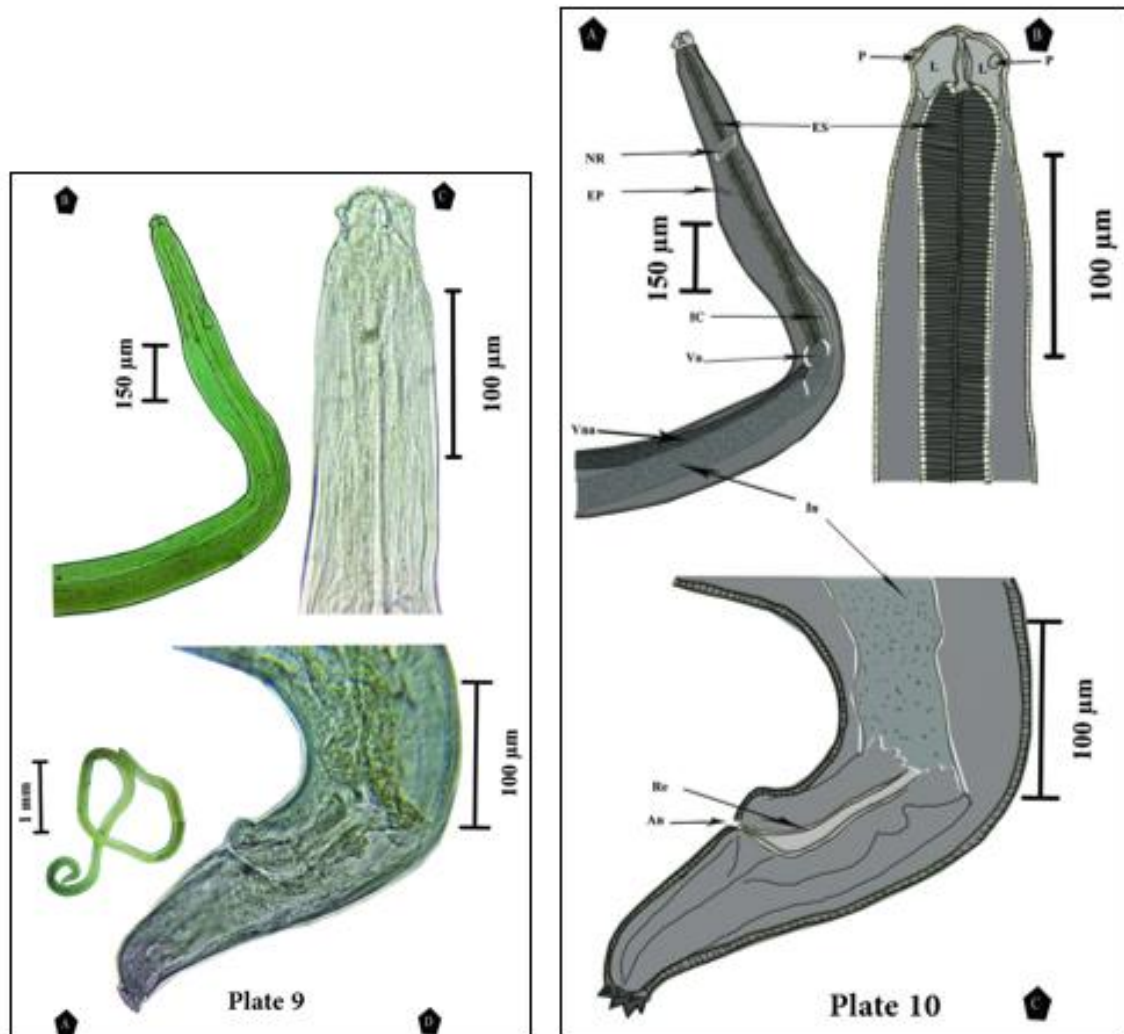
**Plate (5):** A photographs showing *Hysterothylacium* sp. (third stage larva, type XIII) infecting *Parupeneus forsskali* and *Rhabdosargus haffara*.

**Plate (6): Camera lucida drawings showing *Hysterothylacium* sp. (third stage larva, type XIII) infecting *Parupeneus forsskali* and *Rhabdosargus haffara* :** **A)** Lateral view of the anterior extremity of the larva showing labia not developed, nerve ring **NR**, excretory pore **EP**, esophagus **ES**, ventriculus **Vn**, ventricular appendix **Vna**, intestinal caecum **IC** and intestine **In**. **B)** High magnification of the anterior extremity of the larva showing labia not developed and esophagus. **C)** High magnification of the posterior extremity of the larva showing its anal opening **An**, rectum **Re**, rectal glands **RG** and cuticular spike **CSp**.



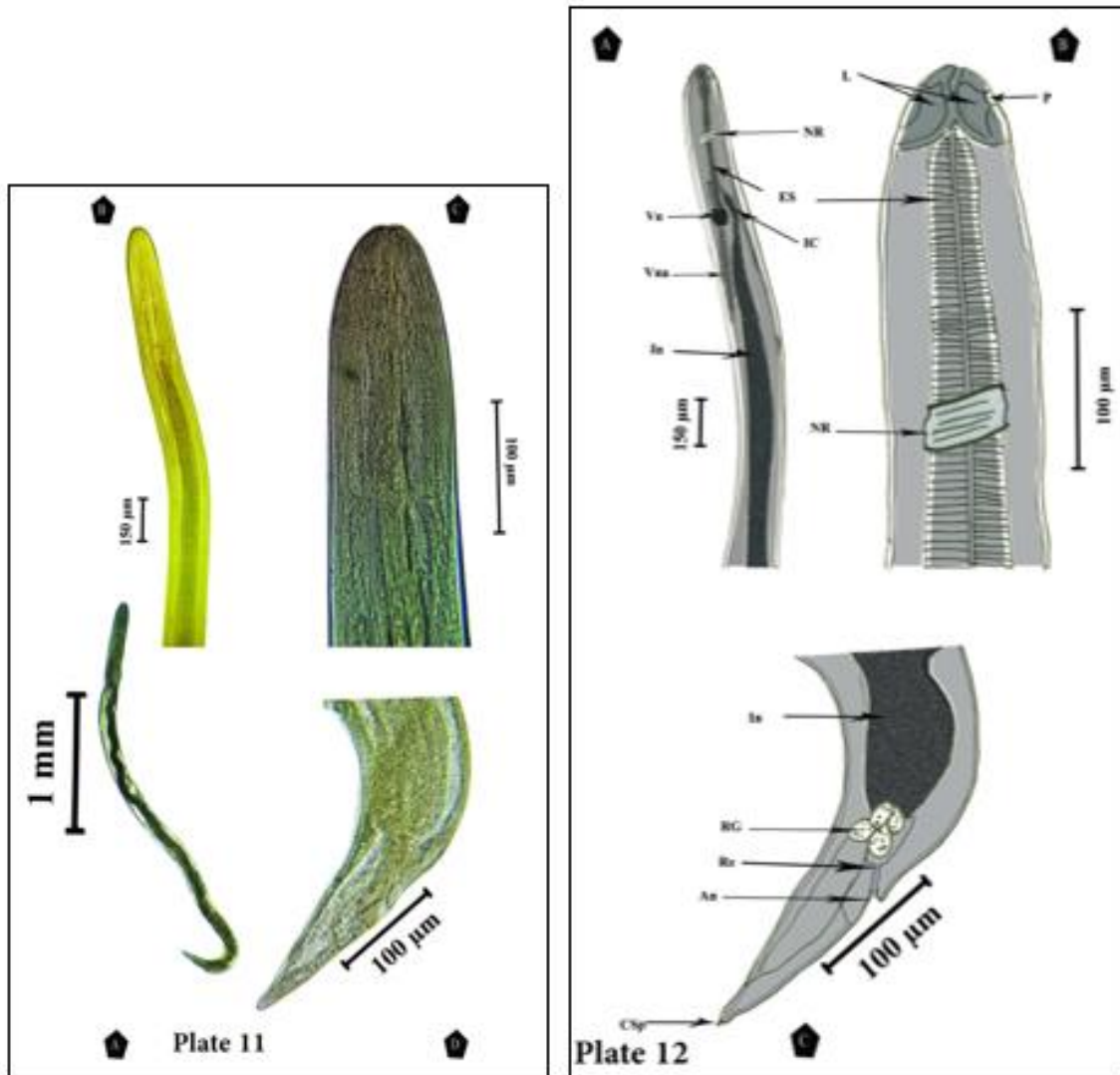
**Plate (7):** A photographs showing *Hysterothylacium* sp. (third stage larva, type XIV) infecting *Parupeneus cyclostomus*.

**Plate (8):** Camera lucida drawings showing *Hysterothylacium* sp. (third stage larva, type XIV) infecting *Parupeneus cyclostomus*: **A)** Lateral view of the anterior extremity of the larva showing labia not developed, nerve ring **NR**, excretory pore **EP**, esophagus **ES**, ventriculus **Vn**, ventricular appendix **Vna**, intestinal caecum **IC** and intestine **In**. **B)** High magnification of the anterior extremity of the larva showing labia not developed and esophagus. **C)** High magnification of the posterior extremity of the larva showing its anal opening **An**, rectum **Re**, rectal glands **RG** and 3-4 sharp triangular minute conical spines **Sp**.



**Plate (9):** A photographs showing *Hysterothylacium* sp. (fourth stage larva, type IV) infecting *Caesio lunaris*.

**Plate (10): Camera lucida drawings showing *Hysterothylacium* sp. (fourth stage larva, type IV) infecting *Caesio lunaris* :** **A)** Lateral view of the anterior extremity of the larva showing nerve ring **NR**, excretory pore **EP**, esophagus **ES**, ventriculus **Vn**, ventricular appendix **Vna**, intestinal caecum **IC** and intestine **In**. **B)** High magnification of the anterior extremity of the larva showing Lips **L**, Papillum **P**, and esophagus. **C)** High magnification of the posterior extremity of the larva showing its anal opening **An** and rectum **Re**.



**Plate (11):** A photographs showing *Hysterothylacium* sp. (fourth stage larva, type XII) infecting *Parupeneus* .

**Plate (12):** Camera lucida drawings showing *Hysterothylacium* sp. (fourth stage larva, type XII) infecting *Parupeneus forsskali*: **A)** Lateral view of the anterior extremity of the larva showing, nerve ring **NR**, esophagus **ES**, ventriculus **Vn**, ventricular appendix **Vna**, intestinal caecum **IC** and intestine **In**. **B)** High magnification of the anterior extremity of the larva showing Lips **L**, Papillum **P**, nerve ring **NR** and esophagus. **C)** High magnification of the posterior extremity of the larva showing its anal opening **An**, rectal glands **RG**, rectum **Re**, and cuticular spike **CSp**.

## DISCUSSION

Specimens were identified as belonging to the Superfamily Ascaridoidea Baird, 1853 after Yorke *et al.* (1926), Family Raphidascarididae Hartwich, 1954 and genus *Hysterothylacium* Ward and Magath, 1917 possessing all characteristics of that genus (Lips approximately equal in size, wider than long, without dentigerous ridges, ventriculus almost spherical, ventricular appendix sac-like or cylindrical, intestinal caecum usually shorter than ventricular appendix. Excretory pore at or near nerve ring level, rectal glands present or absent. The tail was conical, tip with or without spines) (Rocka, 2004; Arai and Smith, 2016). Marine fishes could act as both the paratenic or intermediate and definitive hosts of *Hysterothylacium* nematodes. In addition, species of this genus have been reported to cause human anisakidosis (Yagi, *et al.*, 1996, Amores *et al.*, 2015, Andrade-Porto *et al.*, 2015). The life cycles and larval morphogenesis of *Hysterothylacium* spp. remain mostly unknown; making species identification of the larvae of this genus from fishes, based on morphological features impossible. Cannon (1977) described four *Hysterothylacium* spp. larvae type (I-IV) from Queensland waters, Australian. Shamsi *et al.*, (2013 and 2015) distinguished 14 morphotypes of larval *Hysterothylacium* spp. (types I-XIV) from marine fishes in Australian and New Caledonian waters, of which types VI, XIII, and XIV were recorded from fishes from off New Caledonia. However, the larval types VI and XIII were reported to be characteristic by "sinusoidal" or "serpigenous" patterns of the intestine. According to Moravec *et al.*, (2016) the "sinusoidal" or "serpigenous" patterns of the intestine were, in fact, the coils of the developing genital tract. Based on DNA extraction Shamsi *et al.*, (2013) reported two distinct types of the 4<sup>th</sup> larval stage of *Hysterothylacium* sp. IV-A L4s from three Australian marine fishes, including the Whitley's sergeant *Abudefduf whitleyi* Allen and Robertson (Perciformes: Pomacentridae), redbelly yellowtail fusilier *Caesio cuning* (Bloch) (Perciformes: Caesionidae) and mangrove red snapper, *Lutjanus argentimaculatus* (Forsskål) (Perciformes: Lutjanidae) while, IV-B L4s from Flinders' sillago, *Scomber australasicus* (family: Scombridae) and *Sillago flindersi* (Family: Sillaginidae). The third and fourth stage larval stages can be distinguished by having the structure of the tip of their tail; while the third stage larvae have a cuticular spike on the tail, the fourth stage larvae are characterized by having a rounded tip covered by nodulose apex (Morsy *et al.*, 2015). In the present study, four types were identified as third-stage larvae and two types as fourth-stage larvae were described. Based on the current data, it appears that third stage *Hysterothylacium* larvae show a broad host-specificity, infecting five fish species whilst fourth stage larvae show a narrower host-specificity, occurring in two fish species. Moreover, worm burden of all larvae was very small; one larva/fish host and in only one fish host it was two/fish host. It is worth mentioning that all infected fishes in the present study are new host records. Comparison of the larval 3<sup>rd</sup> stage type X in the present study with that of Shamsi *et al.*, (2013) exhibited that the tail in the present specimen has a single spine compared with few spines in the previous description while comparison of the larval 4<sup>th</sup> stage type XII in the present study with that of Shamsi *et al.*, (2015) showed that the tail in the present specimen has a single spine compared with no spines in the previous description. It is worth mentioning that recently nine adults (one female and eight males) of *Hysterothylacium sebae* Bruce, 1990 were collected from the small intestine and redescribed for the first time from the Red Sea fish *Scarus psittacus*; recording it as new host record Khalifa *et al.*, (2018). The present data refers to the possibility of one of the present described 4th

stage larvae may be the infective stage of this nematode parasite and its life cycle is a direct one by engulfing larvae-infected fish. *Hysterothylacium* was described as a zoonotic parasite (Chai *et al.*, 2005, Lopata and Lehrer, 2009, Felizardo *et al.*, 2009) and the first case report of human infection with *H. aduncum* was reported by Yagi *et al.*, (1996) in a patient complaining of epigastralgia, vomiting, obstruction, diarrhea, ulceration, bleeding and hypersensitivity reactions in the form of urticaria, angioedema, and shock (Pontone *et al.*, 2012) and definite diagnosis can be done only by direct parasite visualization (Henriquez-Santana and Villafruela-Cives, 2009).

### Conclusion

Six different types of *Hysterothylacium* sp. (Raphidascarididae); four 3<sup>rd</sup> larval stages and two 4<sup>th</sup> larval stages are redescribed for the first time from different new host records of Red Sea fishes at Hurghada, Egypt and compared from each other as well as previously elsewhere described forms. Their occurrence in these fishes is a risk factor for human infection if infected fishes were consumed improperly cooked.

### REFERENCES

- Abdul Jabbar, A. F. ; Abdousslam, A.B. and Luke, J.N. (2012): Larval anisakid nematodes in teleost fishes from Lizard Island, northern Great Barrier Reef, Australia Marine and Freshwater Research, 63(12): 1283-1299.
- Amores, Y.; Clavijo-Frutos, E.; Salas-Casanova, C.; and Alcain-Martinez, G. (2015): Direct parasitological diagnosis of infection with *Hysterothylacium aduncum* in a patient with epigastralgia. Rev Esp Infirm Dig (Madrid) 107 (11): 699-700.
- Andrade-Porto, S.; Cárdenas, M.; Martins, M.; Oliveira, J.; Pereira, J.; Araújo, C. and Malta, J. (2015): First record of larvae of *Hysterothylacium* (Nematoda: Anisakidae) with zoonotic potential in the pirarucu *Arapaima gigas* (Osteichthyes: Arapaimidae) from South America. Braz Journal Biol 75 (4): 790-795.
- Arai, H. P. and Smith, J.W. (2016): Guide to the Parasites of Fishes of Canada Part V: Nematoda. Zootaxa, 4185 (1): 1-296.
- Cannon, L.R.G. (1977): Some larval ascaridoids from south-eastern Queensland marine fishes. Internat J Parasitol 7: 233-243.
- Chai, J.; Murrel, K.D. and Lymbry, A.J. (2005): Fish-borne zoonoses: status and issues. Intat J Parasitol 35: 1233- 1254.
- Deardroff, T.L. and Overstreet, R.M. (1980): Review of *Hysterothylacium* and *Iheringascaris* (both previously= *Thynnascaris*) (Nematoda: Anisakidae) from the northern Gulf of Mexico. Proc Biol Soc Washington 93 (4): 1035-1079.
- Felizardo, R.C.; Menezes, R. and Tortelly, M. (2009): Larvae of *Hysterothylacium* sp. (Nematoda: Anisakidae) in the solefish *Paralichthys isosceles* Jordan, 1890 (Pisces: Teleostei) from the littoral of the state of Rio De Janeiro, Brazil Vet Parasitol 1-2, 165- 167.
- Henriquez-Santana, A. and Villafrueela-Cives, M. (2009): Anisakis: pasado, presente y future. Medicina Clinica: 112: 400-403.
- Justine, J. L.; Briand, M. J. and Bray, R. A. (2012): A quick and simple method, usable in the field, for collecting parasites in suitable condition for both morphological and molecular studies. Parasitol Res, 111, 1:341-351.
- Khalifa, R. M.; Mohamadain, H.S and Karar, Y.F. (2018): First redescription and new host record of *Hysterothylacium sebae* Bruce, 1990 from the Red Sea fish *Scarus psittacus* from Egypt. J Egypt Soc Parasitol, 48 (3): 655-660.

- Li, L.; Zhao, W. T.; GUO, Y. N. and Zhang, L. P. (2016): Nematode parasites infecting the starry batfish *Haliutaea stellota* (Vahl) (Lophiiformes: Ogcocephalidae) from the East and South China Sea. *J Fish Dis*, 39 (5): 515-529
- Lieske, L. and Myers, R. F. (2004): *Coral Reef Guide of Red Sea*. Fulham Palace Road, London.
- Lieske, E.; Fiedler, K. E. and Myers, R. F. (2004): *Coral Reef Guide: Red Sea to Gulf of Aden, South Oman; (Definitive Guide to Over 1200 Species of Underwater Life)*. London: Collins.
- Lopata, A. L. and Lehrer, S. B (2009): New insights into seafood allergy. *Cur Opin Allergy Clin Immunol*, 91: 270-277.
- Moravec, F.; Gey, D. and Justine, J. L. (2016): Nematode parasites of four species of *Carangoides* (Osteichthyes: Carangidae) in New Caledonian waters, with a description of *Philometra dispar* n. sp. (Philometridae). *Parasite*, 23, 40-58
- Morsy, K.; Bashtar, A. R; Mostafa, N.; El Deeb, S. and Thabet, S. (2015): New host records of three juvenile nematodes in Egypt: *Anisakis* sp. (Type II), *Hysterothylacium patagonense* (Anisakidae), and *Echinocephalus overstreeti* (Gnathostomatidae) from the greater lizard fish *Saurida undosquamis* of the Red Sea. *Parasitol Res*, 114(3): 1119-1128.
- Pontone, S.; Leonetti, G. and Guaitoli, E. (2012): Should the host reaction to anisakidosis influence the treatment? Different clinical presentations in two cases. *Rev Es Enferm. Dig*, 104: 667-670.
- Randall, J.E. (1983): *Red Sea Reef Fishes*: IMMEL Publishing. Berkley Square, London.
- Rocka, A. (2004): Nematodes of the Antarctic fishes. *Pol Polar Res*, 25(2): 135–152.
- Shamsi, S.; Eisenbarth, A.; Saptarshi, S.; Beveridge, I.; Gasser, R. B. and Lopata, A. L. (2011): Occurrence and abundance of anisakid nematode larvae in five species of fish from southern Australian waters. *Parasitology Research*, 108 (4): 927-934.
- Shamsi, S.; Gasser, R. and Beveridge, I. (2013): Description and genetic characterisation of *Hysterothylacium* (Nematoda: Raphidascarididae) larvae parasitic in Australian marine fishes. *Parasitol Internat*, 62 (3): 320-328.
- Shamsi, S.; Poupa, A. and Justine, J. L. (2015): Characterisation of Ascaridoid larvae from marine fish off New Caledonia, with description of new *Hysterothylacium* larval types XIII and XIV. *Parasitol Internat*, 64 (5):397-404.
- Yagi, K.; Nagasawa, K.; Ishikura, H.; Nakagawa, A.; Sato, N.; Kikuchi, K. and Ishikura, H. (1996): Female worm *Hysterothylacium aduncum* excreted from human: a case report, *Jpn. J Parasitol*, 45: 12–23.
- Yamaguti, S. (1963): *Systema Helminthum*. Vol. III the Nematodes of Vertebrates Part I, LTD. Interscience publishers, London.
- Yorke, W.; Maplestone, P. A. and Stiles, C.W. (1926): *The nematode parasites of vertebrates*. New York: Hafner publishing company.
- Zhao, W.T.; Lü, L.; Chen, H. X.; Yang, Y.; Zhang, L. P. and Li, L. (2016): Ascaridoid parasites infecting in the frequently consumed marine fishes in the coastal area of China: A preliminary investigation. *Parasitology international*, 65(2): 87-98.