

EFFECT OF RED HIBISCUS AQUEOUS EXTRACT ON ALLOXAN-INDUCED DIABETES IN ADULT MALE ALBINO RATS

By

Ali Mohamed El- Hady, Nageh Mabrouk Gabr and Mohamed Ali Abbas

Department of Medical Physiology, Faculty of Medicine, Al-Azhar University, Cairo, Egypt

ABSTRACT

Background: Diabetes mellitus is a growing metabolic disorder at a fast rate throughout the world, and it is the 16th leading cause of global mortality. The significant anti-dyslipidemic effect of red Hibiscus extract may be safe and better alternative available over other agents in diabetic-associated dyslipidemia.

Objective: Demonstrating the antioxidant property of Hibiscus in the role of reduction of blood glucose level.

Material and Methods: Sixty adult male albino rats were used in this study. The rats were divided into six equal groups, i.e. control, alloxan-treated, hot red Hibiscus extract- treated cold red Hibiscus extract-treated, alloxan-treated plus hot red Hibiscus extract- treated and alloxan-treated plus cold red Hibiscus extract-treated groups. Blood samples were obtained for determination of serum glucose, insulin, total cholesterol, triglycerides, HDL- cholesterol, LDL-cholesterol as well as histopathological changes of the pancreas.

Results: Treatment with red Hibiscus (hot and cold) extract was found to be effective in ameliorating lipid profile, blood glucose and insulin levels.

Conclusion: The hypoglycemic, hypolipidemic and antioxidant properties of red Hibiscus were valuable in treatment of diabetes mellitus, and great consideration should be taken toward the use of Hibiscus as a complementary therapy beside ordinary anti-diabetic and hypolipidemic drugs.

Key words: red *Hibiscus sabdariffa*, alloxan, diabetogenic and dyslipidemia.

INTRODUCTION

Many metabolic disturbances accompany diabetes mellitus including hyperglycemia, hyperlipidemia, relative or absolute deficiency of insulin, and increased oxidative stress. These abnormalities represent the backbone in the pathogenesis of diabetic complications (*David and Dolores, 2011*). Such abnormalities cause mitochondrial superoxide overproduction. This increased superoxide production is the central and major mediator of diabetes-induced tissue damage (*Giacco and Brownlee, 2010*).

Roselle (*Hibiscus sabdariffa* L.) is an erect annual herb belonging to the family Malvaceae. It originated from Malaysia and is cultivated mainly in tropical and subtropical regions of the world (**Appel, 2003**).

Wang et al. (2000) suggested that daily consumption of red Hibiscus might be effective in lowering oxidative damage in living systems and the health effects as an antioxidant.

The aim of the present work was to evaluate the red Hibiscus extract as a

therapeutic substance on alloxan-induced diabetes mellitus in male albino rats.

MATERIALS AND METHODS

- **Alloxan** (Sigma Pharmaceuticals Company) was dissolved in 0.9% NaCl and injected at a dose of 140 mg/kg BW (Szkudelski, 2001).

- **Preparation of the dose from red hibiscus extract:** Red Hibiscus was purchased from the local market in Egypt and prepared as follows:

Cold aqueous extraction: 250 g of air dried powder of leaves of red Hibiscus platanifolius was weighed and soaked in 500 ml cold water and left for 24 hours and then filtered. The filtrate was subjected to water bath evaporation, then filtered with the help of muslin cloth and was subjected to centrifugation at 5000 rpm for 5 minutes and stored at 4°C for further use (Farombi, 2003).

Hot aqueous extract: 250 g of air dried powder of leaves of red Hibiscus platanifolius was weighed and soaked in 500 ml water that boiled for 30 minutes, left for 24 hours and then filtered. The filtrate was subjected to water bath evaporation, then filtered with the help of muslin cloth and was subjected to centrifugation at 5000 rpm for 5 minutes and stored at 4°C for further use (Vimain, 2010).

The daily Hibiscus dose given was 250 mg/kg/bw, and was administered via a metal oro- gastric tube

- **Animals:** A total of sixty adult male albino rats of local strains were used in

this study ranging in weight from 165-180 grams at the time of the research. The animals were housed under similar standard environmental conditions in suitable cages (20 x 32 x 20 cm for every 5 rats) with wide meshed raised floors to prevent coprophagia. They were kept on an ordinary rat chow and water at room temperature and normal light/dark cycle. They also were kept for ten days to adapt to the new conditions before starting the experiment. They were divided equally into 6 groups as follows:

Group I: (Control Group): Rats fed on normal standard rat chow diet served as control group

Group II: (Alloxan-treated Group): Rats were subjected to induction of diabetes by a single intraperitoneal injection of alloxan (140 mg/kg body weight) in normal saline and fed on normal standard rat chow diet.

Group III :(Cold red Hibiscus extract - treated group): Rats were fed on normal standard rat chow diet and received cold red hibiscus extract (250 mg/kg) for 4 weeks orally.

Group IV: (Hot red Hibiscus extract - treated group): Rats were fed on normal standard rat chow diet plus extracted hot red Hibiscus (250 mg/kg) for 4 weeks orally.

Group V: (Diabetic Cold red Hibiscus extract -treated group): Rats were subjected to induction of diabetes and received extracted cold red Hibiscus (250 mg/kg) for 4 weeks orally.

Group VI: (Diabetic Hot red Hibiscus extract -treated group): Rats were subjected to induction of diabetes and received extracted hot red Hibiscus (250 mg/kg) for 4 weeks orally.

- Induction of diabetes mellitus: Alloxan was injected intraperitoneally at a dose of 140 mg/kg BW. Just before alloxan injection, 2 ml of glucose (5%) were given orally. After 48 hours, blood samples were taken from tail vein for blood sugar estimation. Rats with blood sugar higher than 200 mg/dl were considered diabetic (Szkudelski, 2001).

- Collection of Blood Samples: At the end of the 4th week from the start of red Hibiscus treatment, all rats were fasted overnight. Blood was collected (4 ml of blood for each) from the retro-orbital plexus using heparinized capillary tube (0.75 - 1.0 mm internal diameter) inserted in the medial canthus. To obtain serum, the blood was collected into a dry clean graduated glass centrifuge tube. It was rapidly set to centrifuge at 5000 r.p.m. for 10 minutes. About half of the supernatant serum was sucked out into Eppendorf tubes and stored frozen at -20°C for subsequent biochemical analysis (Shermer, 1968).

- Histopathological studies: At the end of the 4th week and under ether anesthesia, abdomen of the animal was opened after reaching the stage of surgical anesthesia, as evident by loss of withdrawal reflex. Pancreas was excised for histopathological studies. Pancreatic specimens were preserved in Bouin's solution for 36 and 24 hours respectively, then transferred to

70% alcohol and preserved till used. Paraffin blocks were then made for the tissue samples. Different sections were obtained and stained with hematoxyline and eosin (Hx and E) stains and examined using a light microscope.

- Statistical Analysis: Data input and analysis were done using SPSS computer program. All results were expressed as the mean \pm standard deviation (SD). Mean values of the different groups were compared using a one way analysis of variance (ANOVA). Least significant difference (LSD) post hoc analysis was used to identify significantly different mean values. *P* value < 0.05 was accepted to denote a significant difference.

RESULTS

In group IV (diabetic-group), mean \pm standard deviation was 2.55 ± 0.41 ng/ml. The difference of blood insulin level between control group I and diabetic group IV was significant, where the blood insulin level decreased in diabetic control group (IV) compared with group (I) normal control. In group V and VI, mean \pm standard deviation were 3.03 ± 0.7 and 3.6 ± 0.87 ng/ml respectively. The difference between diabetic groups (V and VI) was significant in respect to group IV. The blood insulin level increased in these groups that were treated with hot and cold Hibiscus extract respectively compared with control diabetic group. Also, there was no significant difference in insulin levels between group V and group VI. Mean \pm standard deviation of blood glucose was 379.2 ± 23.97 mg/dl in group

IV, while were 293.9 ± 19.4 and 287.4 ± 12.58 mg/dl in groups, V and VI respectively.

Induction of diabetes significantly increased the level of total serum cholesterol, triglyceride (TG) and LDL levels associated with significant decrease in the HDL level.

Treatment with red hot and cold Hibiscus extract significantly decreased the total serum cholesterol and TG level with significant decrease in the level of LDL respectively. On the other hand, there was significant increase in the level of HDL compared to the diabetic untreated group.

Table (1): Effects of diabetes, red hot and cold Hibiscus extracts in different groups.

Groups Para- Meters	Control normal (Group I)	Normal + hot Hibiscus (Group II)	Normal + cold Hibiscus (Group III)	Diabetic (Group IV)	Diabetic + hot Hibiscus (Group V)	Diabetic + cold Hibiscus (Group VI)
Insulin (ng/ml)	5.6 ± 1.1	5.5 ± 1.3	5.7 ± 1.2	2.55 ± 0.4	3.03 ± 0.7	3.6 ± 0.87
		P > 0.05	P > 0.05	P < 0.05*	P < 0.05*	P < 0.05*
Blood Glucose (mg/dl)	95.3 ± 8.9	92.3 ± 11.47	90.35 ± 11.3	379.2 ± 23.9	293.9 ± 19.4	287.4 ± 12.58
		P > 0.05	P > 0.05	P < 0.05*	P < 0.05*	P < 0.05*
Cholesterol (mg/dl)	110.4 ± 10.3	103.74 ± 5.5	97.75 ± 7.98	197.1 ± 13.7	176.6 ± 18.5	190.5 ± 7.15
		P > 0.05	P < 0.05*	P < 0.05*	P < 0.05*	P < 0.05*
TG (mg/dl)	160.2 ± 16.7	134.3 ± 33.4	146.9 ± 15.2	269.2 ± 35	164.2 ± 35.2	149.2 ± 23.5
		P < 0.05*	P < 0.05*	P < 0.05*	P > 0.05	P > 0.05
HDL (mg/dl)	74.6 ± 4.2	75 ± 6.2	76.3 ± 9.3	63.9 ± 7.2	92.3 ± 17.1	94.7 ± 9.4
		P > 0.05	P > 0.05	P < 0.05*	P < 0.05*	P < 0.05*
LDL (mg/dl)	4.3 ± 0.9	5.9 ± 1.5	4.8 ± 1.2	76.8 ± 8.7	60.7 ± 14.6	69.9 ± 8.1
		P < 0.05*	P > 0.05	P < 0.05*	P < 0.05*	P < 0.05*

Number of rats in each group = 10.

* Significance in comparison to control

The pancreas showed normal pancreatic islets, pancreatic acini and normal blood vessels in groups I, II and III (Figure 1). On the other hand, pancreatic islets decreased in number and size, normal pancreatic acini and thick wall of the blood vessels, in diabetic group (Figure 2). The pancreas in diabetic

groups received hot red and hot Hibiscus showed normalized number of pancreatic islets and decreased size, normal pancreatic acini and improvement of the thick walled blood vessels (thinner than diabetic group but thicker than normal group) (Figure 3).

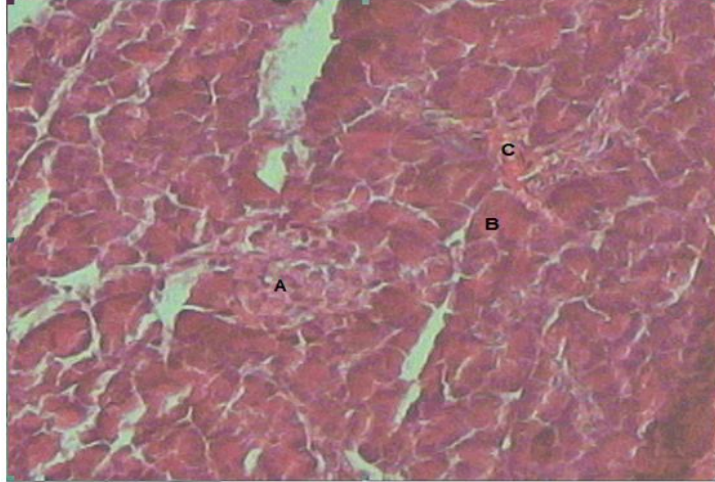


Figure (1): Section in the pancreas (Hx&E, 400X) of group I, II and III (normal control groups) showing normal pancreatic islets (A), normal pancreatic acini (B) and normal blood vessels (C).

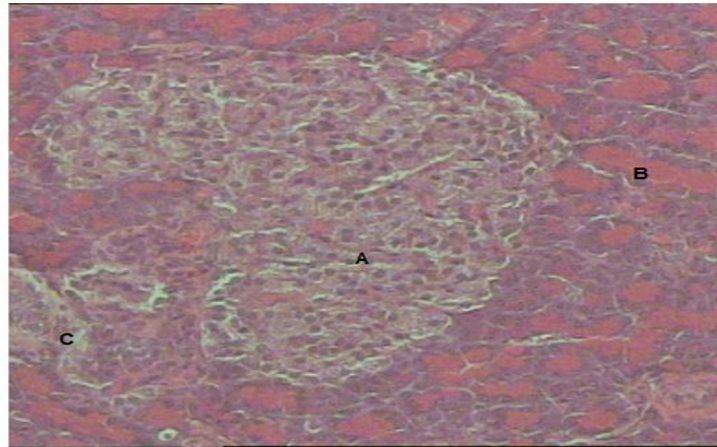


Figure (2): Section in the pancreas (Hx&E, 400X) of group IV (diabetic-group) showing pancreatic islets decreased in number and size (A), normal pancreatic acini (B) and thick wall of the blood vessels (C).

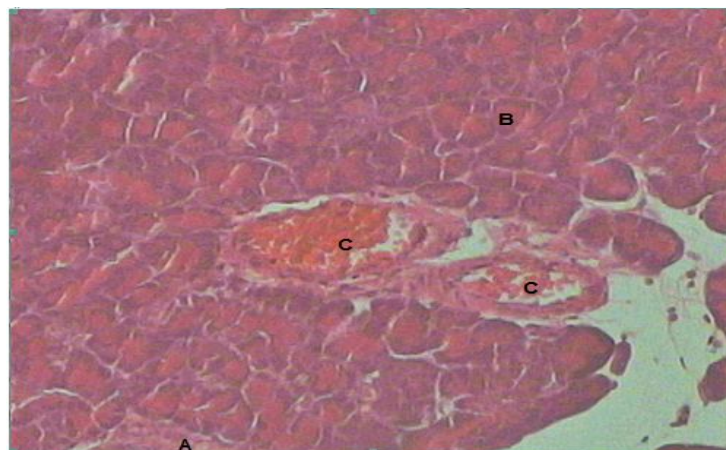


Figure (3): Section in the pancreas (Hx&E, 400X) of group V and VI- diabetic-received cold and hot red Hibiscus showing normalized number of pancreatic islets and decreased size (A), normal pancreatic acini (B) and improvement of the thick walled blood vessels (C).

DISCUSSION

In the present study, there was a significant increase in blood glucose level and a significant decrease in insulin level in diabetic group (IV) when compared with the control group (I). In treated groups with red Hibiscus hot and cold (V and VI) groups, there were significant decrease in blood glucose level and increase in insulin level when compared with diabetic group (IV). Diabetic group showed moderate to marked atrophy of the β -cells of islets of Langerhans of the pancreas. The reduction in blood glucose level could be due to increased pancreatic insulin secretion from existing β -cell of the pancreas (**Ghosh and Suryawanshi, 2001**). **Zahid et al. (2014)** stated that red Hibiscus has anti-hyperglycemic effect and the extract produces significant reduction in blood glucose level within 2 hours of its oral administration. All treated rats with extract showed significant improvement in glucose tolerance. The extracts causes hypoglycemic condition may probably due to increasing the insulin effect of plasma by stimulating insulin release from the pancreatic β -cells, or due to stimulation of peripheral glucose utilization, or enhancing glycolytic and glycogenic processes with concomitant decrease in glycogenolysis and gluconeogenesis (**Andrade-Cetto and Wiedenfeld, 2004**).

These results were compatible with that of **Mirunalini and Arulmozhi (2011)** that showed that blood glucose level increases in diabetic rats compared with treated groups.

In the present work, there was a significant increase of cholesterol, TG and LDL but HDL level decreased in diabetic

group (IV) comparing with normal group (I). Treated groups (V and VI) decreased level of cholesterol, TG and LDL but HDL level increased when compared with group (IV). In alloxan-induced diabetes mellitus, animals in the study have shown a significant dyslipidemia as evidenced by increase in cholesterol, TG, LDL and decrease in HDL level. Oral administration of Hibiscus rosa sinensis flower extract has shown significant lowering effect on serum cholesterol, TG, LDL and increase in HDL level.

These results were in agreement with the findings of **Vishnukumar et al. (2009)** who observed significant increase of cholesterol, TG and LDL and HDL level decreased in diabetic group when compared with treated groups. Also, these results were in agreement with the findings of **Thomson et al. (2007)** and **Ali and Agha (2009)** who found that cholesterol, TG and LDL levels showed significant elevations in diabetic animals when compared with normal ones. Cholesterol acyltransferase activity in intestinal mucosa is increased in diabetic rats. Therefore, an enhancement of cholesterol acyltransferase-dependent cholesterol esterification in the intestine might be one of the major factors that are responsible for hypercholesterolemia in diabetes (**Jiao et al., 2003**). **Lee et al. (2009)**, **Vishnukumar et al. (2009)** and **Gosain et al. (2010)** have shown lipid lowering activity of Hibiscus rosa sinensis flower extract in diabetic rats.

Conclusion: Activity of the red (*hot and cold*) *Hibiscus* extract against alloxan – induced diabetes mellitus is through its effect on beta cell improvement, its improving effects on varying lipid

profiles, strong antioxidant effects, and enhancing the body's immune system. There was no significant change between the effect of hot and red Hibiscus extracts.

ACKNOWLEDGMENT

I would like to express my deep appreciation and utmost thanks to Assist. Prof. Dr. Amr El-Karef, Assistant Professor of Medical Pathology, Faculty of Medicine, Mansoura University, for his great help in this work.

REFERENCES

- 1. Ali M. M. and Agha F. G. (2009):** Amelioration of streptozotocin-induced diabetes mellitus, oxidative stress and dyslipidemia in rats by tomato extract lycopene. *Scandinavian Journal of Clinical and Laboratory Investigation*, 69(3): 371-379.
- 2. Andrade-Cetto A. and Wiedenfeld H. (2004):** Hypoglycemic effect of *Acosmium panamense* bark on streptozocin diabetic rats, *J. Ethnopharmacol*, 90: 217-220.
- 3. Appel, S.D. (2003):** Red sorrel (*Hibiscus sabdariffa*) and the other 'cranberry'. *Plants and Garden News*, 18: 1 – 2.
- 4. David G. and Dolores G. (2011):** Greenspan's basic and clinical endocrinology. Pbl. New York, McGraw-Hill Medical, (9th ed.), p 17.
- 5. Farombi E.O. (2003):** African indigenous plant with chemotherapeutic potential and biotechnological approval to the production of bioactive prophylactic agent. *African Biotech*, 2: 662-667.
- 6. Ghosh S. and Suryawanshi S.A. (2001):** Effect of *Vinca rosea* extract on lipid peroxidation in hyperglycemic in STZ induced rats. *Ind J Exp Biol.*, 39:48-51.
- 7. Giacco F. and Brownlee M. (2010):** Oxidative stress and diabetic complications. *Journal of Circulation Research*, 107: 1524-1571.
- 8. Gosain S., Irchiaya R. and Sharma P.C. (2010):** Hypolipidemic effect of ethanolic extract from the leaves of *Hibiscus sabdariffa* L. in hyperlipidemic rats, *Acta Pol Pharm.*, 67(2):179-184.
- 9. Jiao S., Matsuzawa Y., Matsubara K., Kihara S., Nakamura T., Tokunaga K., Kubo M. and Tarui S. (2003):** Increased activity of intestinal acyl-CoA: cholesterol acyltransferase in rats with streptozocin induced diabetes and restoration by insulin supplementation. *Journal of Diabetes*, 37 (3):342-346.
- 10. Lee W.C., Wang C.J. and Chen Y.H. (2009):** Polyphenol extracts from *Hibiscus sabdariffa* Linnaeus attenuate nephropathy in experimental type 1 diabetes. *J Agric Food Chem.*, 57(6): 2206-2210.
- 11. Mirunalini S. and Arulmozhi V. (2011):** Antioxidant and antidiabetic effect of *Hibiscus rosasinensis* flower extract on Streptozotocin induced experimental rats a dose response study. *Nat Sci Biol*, 3(4): 13-21.
- 12. Shermer, S. (1968):** Rats haemopoietic system, in the blood morphology of laboratory animals. Chap. 2: 42.
- 13. Szkudelski T. (2001):** The mechanism of alloxan and streptozotocin action in β cells of rat pancreas. *Physiology Research Journal*, 50:536-546.
- 14. Thomson M., Zainab M., Al-Amin, Khaled K., Al-Qattan, H. Shaban and Ali M. (2007):** Antidiabetic and hypolipidaemic properties of garlic (*Allium sativum*) in streptozotocin induced diabetic rats. *International Journal of Diabetes and Metabolism*, 15:108-115.
- 15. Vimaiin H.J. (2010):** Antibacterial potentiality of *Hibiscus rosa sinensis* solvent extract and aqueous extracts against some pathogenic, Bacteria. *herbal tech industry*: 21-23.
- 16. Vishnukumar p., shingh and R amesh chander (2009):** Hypolipidemic activity of *hibiscus rosa sinensis* root in rats, *Indian j biochemistry and bioph.*
- 17. Wang C.J., Wang J.M., Lin W.L., Chu C.Y., Chou F.P. and Tseng T.H. (2000):** Protective effect of *Hibiscus anthocyanins* against tertbutyl hydroperoxide induced hepatic toxicity in rats. *Food Chem. Toxicol.*, 38: 411-416.
- 18. Zahid H., Ghazala H., Rizwanil H., Shareef H., Khursheed R., Huma A. and Hasan F. (2014):** Antihyperglycemic and hypolipidemic effects of *Hibiscus schizopetalus* (Mast) Hook in alloxan-induced diabetic rats. *Pak. J. Pharm. Sci.*, 27(1): 83-89.

على محمد الهادى محمود - ناجح مبروك محمد جبر - محمد على محمود عباس

قسم الفسيولوجيا الطبية- كلية الطب - جامعة الأزهر

خلفية البحث: داء البول السكرى هو أحد أكثر الأمراض شيوعاً، وأحد المصادر الرئيسية لإعتلال الصحة فى جميع أنحاء العالم .

الهدف من البحث: بيان تأثير المستخلص المائى لنبات الكركديه على ذكور الفئران البيضاء المصابة بمرض السكر من حيث نسب كل من السكر والإنسولين والدهون بالدم وتأثير هذا المستخلص على أنسجة البنكرياس.

طرق ومواد البحث: إستخدم فى هذا البحث ستون فأراً ذكراً أبيضاً من سلالة محلية كنموذج للدراسة. و قد قسمت الفئران إلى ستة مجموعات متساوية كالاتى:
المجموعة الأولى : مجموعة ضابطة تم تغذيتها على النظام الطبيعى القياسى وتعتبر المجموعة الضابطة.
المجموعة الثانية: مجموعة ضابطة تم إعطاؤها مستخلص الكركديه الساخن عن طريق الفم بجرعة 250 مجم/كجم.
المجموعة الثالثة: تم إعطاؤها مستخلص الكركديه البارد بالفم بجرعة 250 مجم/كجم.
المجموعة الرابعة : مصابة بالسكر تم تغذيتها على النظام الطبيعى القياسى.
المجموعة الخامسة: تم إعطاؤها مستخلص الكركديه الساخن عن طريق الفم بجرعة 250 مجم/كجم.
المجموعة السادسة: مصابة بالسكر تم إعطاؤها مستخلص الكركديه البارد بالفم بجرعة 250 مجم/كجم.

وقد تم إحداث مرض السكر فى كل من المجموعة الرابعة والخامسة والسادسة عن طريق إعطاء مادة الألوكسان (140 مجم/كجم) بالحقن فى الغشاء البريتونى مسبوقة بجرعة 2 مل جلوكوز(5%) تم إعطاؤها عن طريق الفم قبل الألوكسان بعشر دقائق وذلك لتجنب نقص نسبة الجلوكوز فى الدم بعد حقن الألوكسان. وقد إستمرت التجربة لمدة أربعة أسابيع، وتم سحب عينات الدم فى آخر التجربة وذلك لقياس:

- نسبة السكر بالدم.
- نسبة هرمون الإنسولين.
- الكوليستيرول.
- الدهون الثلاثية.
- البروتين الدهنى عالى الكثافة.

• البروتين الدهني منخفض الكثافة

كما تم أخذ عينات من البنكرياس من كل مجموعة.

نتائج البحث: أسفرت نتائج هذه الدراسة عما يلي:

- في المجموعة الرابعة تسبب حقن الألوكسان في ارتفاع نسبة كل من السكر والكوليستيرول والدهون الثلاثية والبروتين الدهني منخفض الكثافة ارتفاعاً ذو دلالة إحصائية عند مقارنتها بالمجموعة الضابطة الأولى. كما إنخفض هرمون الإنسولين بالدم في هذه المجموعة انخفاضاً ذو دلالة إحصائية عند مقارنتها بالمجموعة الضابطة الأولى.

- وفي المجموعة الخامسة تسبب حقن المستخلص المائي للكرديه الساخن في خفض نسبة كل من السكر والكوليستيرول والبروتين الدهني منخفض الكثافة انخفاضاً ذو دلالة إحصائية عند مقارنتها بالمجموعة الرابعة. كما ارتفع هرمون الإنسولين بالدم في هذه المجموعة ارتفاعاً ذو دلالة إحصائية عند مقارنتها بالمجموعة الرابعة.

- أما في المجموعة السادسة فقد تسبب حقن المستخلص المائي للكرديه البارد في خفض نسبة كل من السكر والكوليستيرول والبروتين الدهني منخفض الكثافة انخفاضاً ذو دلالة إحصائية عند مقارنتها بالمجموعة الرابعة. كما ارتفع هرمون الإنسولين بالدم في هذه المجموعة ارتفاعاً ذو دلالة إحصائية عند مقارنتها بالمجموعة الرابعة.

الاستنتاج: المستخلص المائي لنبات الكركديه تسبب في خفض نسبة السكر والدهون في دم الفئران التي تم إحداث السكر بها تجريبياً. كما تسبب أيضاً في تحسين نسبة هرمون الإنسولين في هذه الفئران، مما يعني أن استخدام هذا المستخلص يمكن أن يكون ذا فائدة تطبيقية وعاملاً مساعداً في علاج مرض السكر والوقاية من مضاعفاته. وقد يرجع ذلك إلى قدرته على زيادة إفراز هرمون الإنسولين من البنكرياس وزيادة حساسية الجسم له.