

# VALUE OF LARYNGEAL ULTRASOUND IN COMPARISON TO VOCAL CORD VIDEO STROSCOPY IN DIAGNOSIS OF VARIOUS LARYNGEAL LESIONS

By

**Hala Maghraby and Hala Abd El-Haseeb\***

Departments of Radiology and Otolaryngology\*  
Faculty of Medicine, Al Azhar University, Cairo, Egypt

## ABSTRACT

**Background:** Video stroboscopy is useful in diagnosis of various laryngeal lesion. Laryngeal ultrasound is also used as a beneficial tool in this diagnosis. **Objectives:** The main aim of this study was to evaluate the value of laryngeal ultrasound in comparison to vocal cord stroboscopy in diagnosis of different laryngeal lesions. **Patients and Methods:** This study which was carried out between August 2014 and April 2015 in Radio diagnosis and Otorhinolaryngology Departments, Al-Zahraa University Hospital, Egypt. The study included groups of thirty patients who had complaints related to the larynx as hoarseness of voice, stridor, chronic cough, choking attacks or neck swelling. These patients were referred from the ENT outpatient clinic. All the patients of the study group were subjected to both laryngeal ultrasound and vocal cord stroboscopy. **Results:** Twelve patients (40%) were normal, two patients (6.6%) had vocal fold palsy, four patients (13,3 %) had vocal fold nodules, three (10%) had vocal fold polyp, two (6.6%) had vocal fold hypertrophy, two (6.6%) had intrarytenoid edema, one (3.3%) had anterior commissure mass encroaching upon the right vocal cord, one (3.3%) had submandibular swelling and three (10%) had multinodular goitre. **Conclusion:** Laryngeal ultrasound can be used in diagnosis in different vocal cord lesions. It can be used as a complementary tool to vocal cord stroboscopy in diagnosis of vocal cord lesions.

## INTRODUCTION

Different methods have been used successfully in diagnosis of different vocal cord lesions (Singh et al., 2010 and Shalaby et al., 2013). Fibro-optic laryngoscope was used in otolaryngology outpatient clinic for laryngeal evaluation. The image of laryngoscope is larger, brighter and clearer which allows earlier diagnosis (Eller et al., 2008 and Matta et al., 2015). However, not all patients can tolerate the rigid laryngoscope especially those who are suffering from stridor, sensitive gag reflex, patients with limit of

jaw mobility or neck mobility as well as infants and children (Hartnick and Zeitels, 2005). Ultrasound became a very important widely used diagnostic tool for the head and neck diseases. However it was rarely used in the diagnosis of laryngeal diseases (Wolf et al., 2005 and Kundra et al., 2011). High-frequency ultrasound in the last years became an effective diagnostic tool with small, flexible ultrasound transducers (Wendy, 2007) and (Gomaa et al., 2013).

The present work was to evaluate the value of laryngeal ultrasound in

comparison to vocal cord stroboscopy in diagnosis of different laryngeal lesions.

### PATIENTS AND METHODS

The study was approved by the clinical research committee of the radio diagnosis and otolaryngology departments, Faculty of Medicine, Al Azhar University, Cairo, Egypt. The study started in July 2014 and ended in March 2015. All the patients of the study were consented and submitted to discussion about the methods of examination of the larynx by the two ways of the techniques. All the patients were agreed to do both methods of diagnosis.

The study group included thirty patients (18 females and 12 males) who had hoarseness of voice, chronic cough, choking attacks, stridor, or neck swelling. The mean age was  $47.5 \pm 8.8$  years (35-60 years). These patients were referred from the ENT outpatient clinic at Al-Zahra' University Hospital. All patients were subjected to full history and examination using the high-resolution laryngeal ultrasound technique, which was carried out using a small linear probe of 7-12 MHz frequency using general electric voluson -730- Expert machine, and Logic 6 machine with a linear probe for the visualization of the laryngeal structures. The vocal cords were examined in two phases: Quiet breathing for assessment of vocal cord lesions, and during phonation (long E) to assess vocal cord mobility. All the patients were also subjected to vocal cord stroboscopy.

Thus, the video image of one cycle is obtained from different portions of several cycles. The stroboscopic flashes can be emitted in one of two ways:

- Synchronization, illumination: at the same frequency of phonation.
- Asynchronization illumination at a slight variation of frequency.

Vibratory pattern was detected regarding the glottic wave (mucosal wave), amplitude of vibration, symmetry of bilateral movement, periodicity, Glottic closure, non vibrating portions (fixation) and phase closure.

**Statistical analysis:** Data were analyzed using statistical program for social science (SPSS) version 18.0. Qualitative data were expressed as frequency and percentage.

The following tests were done:

- Chi-square ( $X^2$ ) test of significance was used in order to compare proportions between two qualitative parameters.
- Receiver operating characteristic (ROC curve) analysis was used to find out the overall productivity of parameter in and to find:
- Sensitivity: Probability that a test result was positive when the disease was present (true positive rate, expressed as a percentage).
- Specificity: Probability that a test result was negative when the disease was not present (true negative rate, expressed as percentage).
- Probability (P-value) P-value  $<0.05$  was considered significant.

### RESULTS

Demographic data distribution of the study group as regards to age and sex were showed the percentage of male 40% to female 60% of the groups. The age ranged from 35-60 years with mean age  $\pm$  SD  $47.5 \pm 8.8$  years (Table 1).

**Table (1):** Demographic Data distribution of the study group as regards to the age and sex.

|                    | No.      | %  |
|--------------------|----------|----|
| <b>Sex</b>         |          |    |
| Male               | 12       | 40 |
| Female             | 18       | 60 |
| <b>Age (years)</b> |          |    |
| Range              | 35-60    |    |
| Mean ± SD          | 47.5±8.8 |    |

The study included thirty patients suffering from laryngeal symptoms. Twelve patients (40%) were normal with no evidence of any abnormality either by laryngeal ultrasound or by vocal cord stroboscopy (Fig. 1). Two patients (6.6 %) have limited mobility and diagnosis was confirmed by vocal cord stroboscopy as a vocal cord paralysis. Four patients (13.3%) had a vocal cord nodule that was diagnosed by ultrasound, and confirmed correctly by a vocal cord stroboscopy (Fig, 2 a,b). Three patients (10%) had a vocal cord polyps; diagnosed by laryngeal ultrasound and confirmed by a vocal cord stroboscopy. Two patients (6.6%) had interarytenoid edema, but the lesion could not be diagnosed by ultrasonography, and the two cases had recurrent attacks of choking and misdiagnosed as they had gastroesophageal reflux disease. They were correctly diagnosed by vocal cord stroboscopy, (Fig. 3 a,b). Two patients (6.6%) had hypertrophy of both vocal cords and complained from recurrent attacks of hoarseness of voice and choking attacks. They were diagnosed by laryngeal ultrasonography and confirmed by vocal cord stroboscopy. One patient (3.3%) had an anterior commissure mass encroaching upon the right vocal cord. The condition was diagnosed by laryngeal

ultrasonography and confirmed by vocal cord stroboscopy, (Fig. 4 ,a,b). One patient (3.3%) had bilateral submandibular swelling. By laryngeal ultrasound, both submandibular glands were found enlarged with heterogenous echopattern and surrounded by multiple cervical and submandibular lymphadenopathy. The condition was diagnosed as bilateral submandibular sialoadenitis and received medical treatment. After three weeks follow up, the study revealed the relief of the condition, and the patient became normal. Three patients (10%) had multinodular goiter and diagnosed well by laryngeal ultrasonography only, (Fig. 5).

The level of sensitivity, specificity and accuracy ogeal lesions by both methods: Normal (100.0%, 100.0% and 100.0%), Vocal cord paralysis (0.0%, 100.0% and 50.0%), Vocal cord nodule (100.0%, 100.0% and 100.0%), vocal cord polyp (100.0%, 100.0% and 100.0%), interarytenoid edema (0.0%, 100.0% and 50.0%), hypertrophy of both vocal cords (100.0%, 100.0% and 100.0%), Anterior commissure mass (100.0%, 100.0% and 100.0%), bilateral submandibular swelling (100.0%, 0.0% and 50.0%), multinodular goiter (100.0%, 0.0% and 50.0%) respectively (Table 2).

**Table (2):** Diagnostic Performance of various laryngeal lesions by laryngeal ultrasound and vocal cord video- stropscopy as regards to sensitivity, specificity and accuracy.

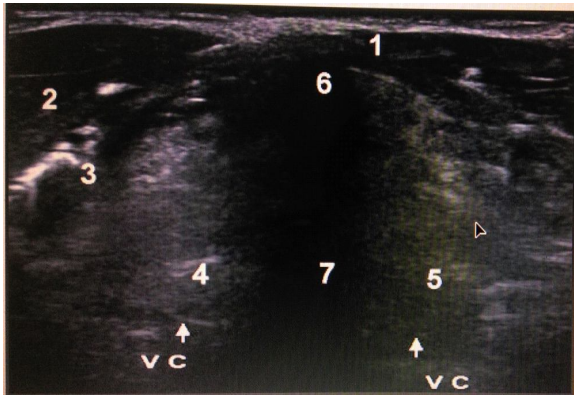
| <b>Parameters</b><br><b>Various laryngeal lesions</b> | Sens.  | Spec.  | Accuracy |
|---|--------|--------|----------|
| Normal  | 100.0% | 100.0% | 100.0%   |
| Vocal cord paralysis                                  | 0.0%   | 100.0% | 50.0%    |
| Vocal cord nodule                                     | 100.0% | 100.0% | 100.0%   |
| Vocal cord polyp                                      | 100.0% | 100.0% | 100.0%   |
| Interarytenoid edema                                  | 0.0%   | 100.0% | 50.0%    |
| Hypertrophy of both vocal cords                       | 100.0% | 100.0% | 100.0%   |
| Anterior commissure mass                              | 100.0% | 100.0% | 100.0%   |
| Bilateral submandibular swelling                      | 100.0% | 0.0%   | 50.0%    |
| Multinodular goiter                                   | 100.0% | 0.0%   | 50.0%    |

Also, in this study, comparison between laryngeal ultrasound and vocal cord video-stropscopy as regards to various laryngeal pathologies showed a difference between both methods as regard to cord

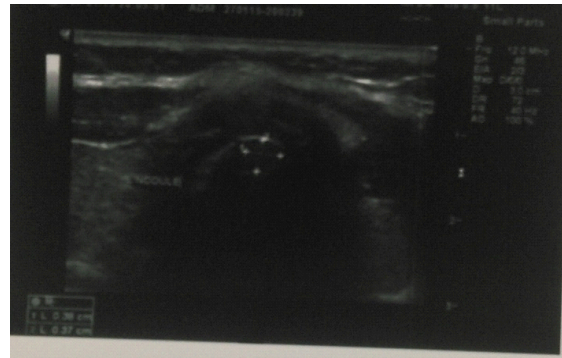
paralysis, interarytenoid edema, bilateral submandibular swelling and multinodular goiter but non significant. The rest have equal results (table 3).

**Table (3):** Comparison between laryngeal ultrasound and vocal cord video stropscopy as regard to various laryngeal lesions.

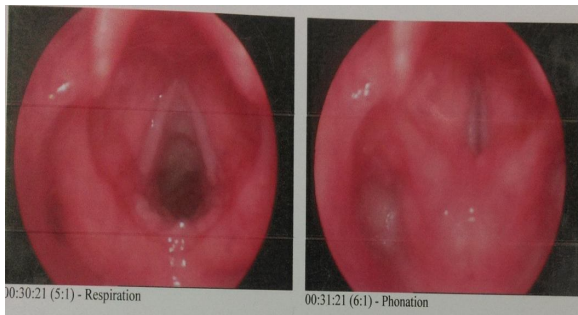
| <b>Groups</b><br><b>Various laryngeal lesions</b> | <b>Laryngeal ultrasound (n=30)</b> |          | <b>Vocal cord video stropscopy (n=30)</b> |          | <b>Chi-square test</b> |          |
|---|------------------------------------|----------|---|----------|------------------------|----------|
|   | <b>No.</b>                         | <b>%</b> | <b>No.</b>                                | <b>%</b> | <b>No.</b>             | <b>%</b> |
| Normal  | 12                                 | 40.0%    | 12  | 40.0%    | 0.000                  | 1.000    |
| Vocal cord paralysis                              | 0                                  | 0.0%     | 2   | 6.7%     | 0.525                  | 0.469    |
| Vocal cord nodule                                 | 4                                  | 13.3%    | 4   | 13.3%    | 0.000                  | 1.000    |
| Vocal cord polyp                                  | 3                                  | 10.0%    | 3   | 10.0%    | 0.000                  | 1.000    |
| Interarytenoid edema                              | 0                                  | 0.0%     | 2   | 6.7%     | 0.525                  | 0.469    |
| Hypertrophy of both vocal cords                   | 2                                  | 6.7%     | 2   | 6.7%     | 0.000                  | 1.000    |
| Anterior commissure mass                          | 1                                  | 3.3%     | 1   | 3.3%     | 0.000                  | 1.000    |
| Bilateral submandibular swelling                  | 1                                  | 3.3%     | 0   | 0.0%     | 0.171                  | 0.679    |
| Multinodular goiter                               | 3                                  | 10.0%    | 0   | 0.0%     | 1.404                  | 0.236    |



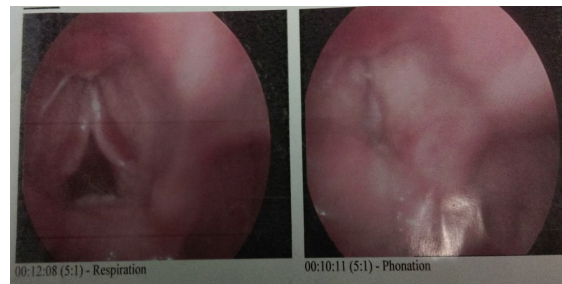
**Figure (1):** Normal sonographic appearance of the larynx at the level of the vocal fold: 1. Skin and subcutaneous tissue. 2. Strap muscles. 3. Thyroid lamina, 4. 5. Right vocal fold. 6. Anterior commissure. 7. Glottic chink.



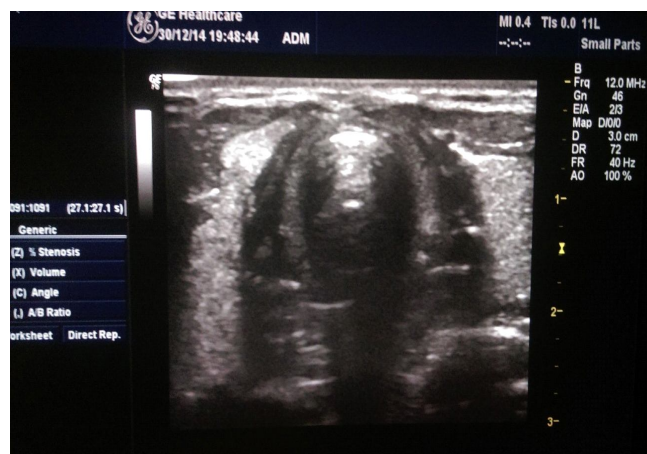**Figure (2a):** Laryngeal ultrasound revealing vocal cord nodule above the laryngeal inlet.



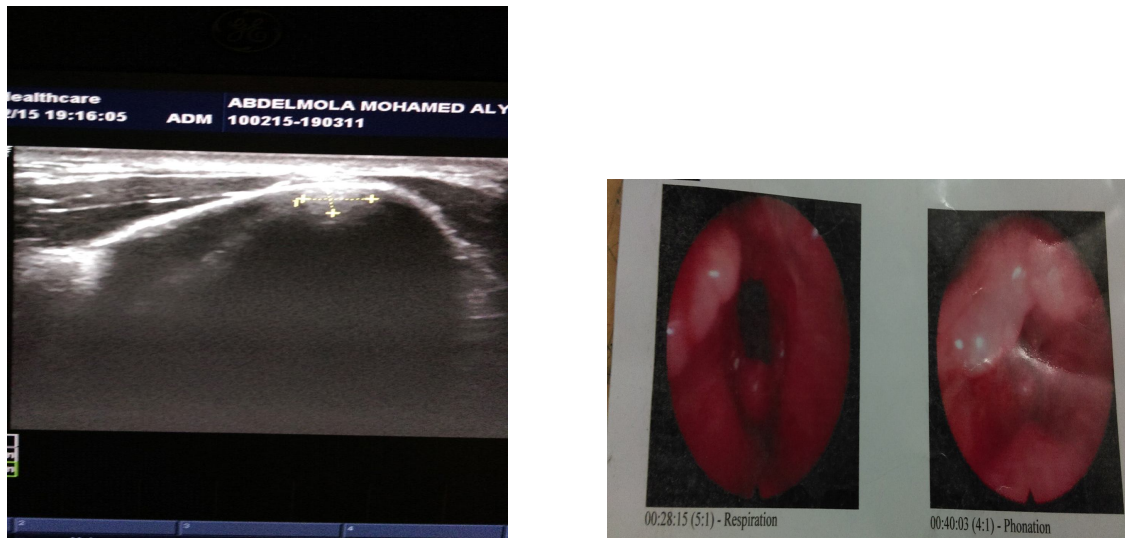
**Figure (2b):** The same patient with vocal cord stroboscopy revealing lymphoid deposition above the laryngeal inlet.



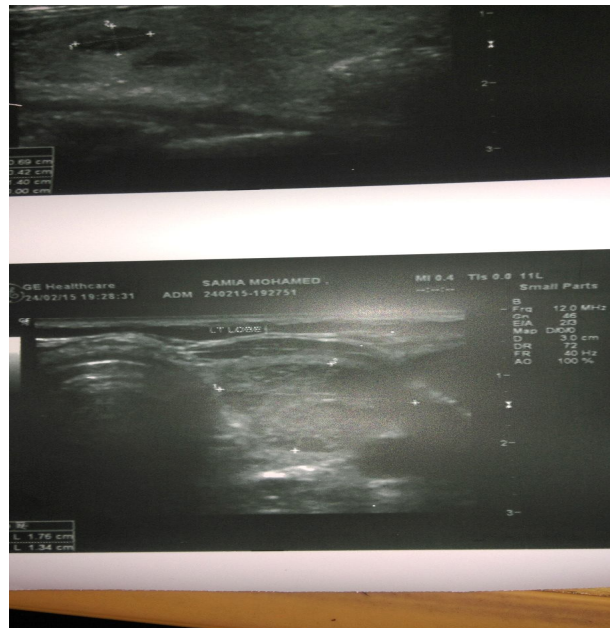**Figure (3a):** Male patient 50 years old with hoarseness of voice, vocal cord stroboscopy revealing diffuse swelling of the whole length of both vocal folds, picture of Reinke's edema.



**Figure (3b):** laryngeal ultrasonography of the same patient which is completely normal.



**Figure (4 a,b):** Small mass lesion seen at the anterior commissure encroaching upon the right vocal fold.



**Figure (5):** Laryngeal ultrasound revealing multinodular goiter.

## DISCUSSION

For several decades, vocal cord evaluation was performed using the indirect mirror examination. More recently, the Otolaryngologists use of the fiberoptic laryngoscope for routine evaluation of the larynx. However, this technique requires a cooperative patient as well as application of topical anesthetic

and decongestant (Dedecjus et al., 2010). Ultrasound imaging has become a very powerful tool for diagnostic radiology, especially in scanning of the head and neck (Singh M et al., 2010 and Shalaby et al., 2013).

Jadcherla SR et al. (2006), imaged the complete visualization of adduction and abduction of the vocal cords by vocal cord stroboscopy. High- resolution laryngeal

ultrasonography at frequencies ranging from 10 to 30 MHz was demonstrated to be useful in the diagnosis of various lesions of the vocal folds (Huang et al., 2007). Laryngeal ultrasound has many advantages including its simplicity, safety, non-invasive, non-expensive, painless, and anesthesia is not necessary (Sirikci A et al., 2007 and Nasr et al., 2013).

In the present study, comparison between laryngeal ultrasound and vocal cord video-stroboscopy showed a difference between laryngeal ultrasound and vocal cord stroboscopy in vocal cord paralysis, inter arytenoids edema, bilateral submandibular swelling and multi-nodular goiter. The rest of the other laryngeal lesions have equal results between both techniques. These results agreed with Zajkowski (2007) who stated that ultrasound considered the first imaging in the salivary gland diseases, and as valuable adjunct in some laryngeal pathologies. This result was also in agreement with Gomaa et al. (2013).

The accuracy of various laryngeal lesions in this study with video-stroboscopy and laryngeal ultrasound were totally have the same results except in vocal cord paralysis, interarytenoid edema, bilateral submandibular swelling and multinodular goiter. This agreed with Khalil et al. (2010) who found that the free margin of the vocal folds could not be well delineated due to the air-soft tissues interface. Also, complete thyroid cartilage calcification causing the visualization of the laryngeal space is unclear as complete calcification of the thyroid cartilage created an acoustic shadow which made it hard to analyze the larynx (Khalil et al.

2010; Hu et al. 2011 and Matta et al. 2015).

In the present work, the normal anatomy of the vocal folds was well demarcated, whereas the posterior part of the free margins were not clearly identified. This is in agreement with Nasr et al. (2013) and Gomaa et al. (2013).

Also, in this work, the thyroid lamina, anterior commissure and vocal process of the arytenoids cartilage were clearly demarcated during both phonation and normal breathing. This is consistent with results of Nasr et al. (2013). The vocal cord movement is clearly visible in all cases of this study except in two patients who presented with vocal cord paralysis and their thyroid cartilages were calcified. This was in agreement with study of Nasr et al. (2013).

In this study, it was found that vocal cord nodules were detected in four patients (13.3%) and vocal cord polyps in three patients (10%). These two lesions were detected in 100% of patients on performing laryngeal ultrasound as well as vocal cord video-stroboscopy (Table 2 and 3). It is in agreement with the findings of Khalil el al. (2010).

By comparison of the findings of laryngeal ultrasonography and vocal cord video-stroboscopy in this study, it had been found that both modalities were comparable with a great extent. Moreover, the laryngeal ultrasound was more valuable in detecting all various laryngeal lesions except in vocal cord paralysis and interarytenoid edema, but the vocal cord video-stroboscopy results were better in interarytenoid edema and vocal cord thickening and edema that was detected in four patients (6.7% for each lesion



respectively). The accuracy represented 50% and 100% as regard to these two lesions which were performed by both modalities. These results were in agreement with Khalil et al. (2010) who concluded that laryngeal ultrasound had the same diagnostic ability as vocal cord video-stroboscopy in the assessment of vocal cord mobility. The results of our study were also in agreement with the results of HU et al. (2011) who decided that laryngeal ultrasonography was considered a non-invasive complementary technique in detecting some types of laryngeal lesions.

Ultrasound is considered as the first imaging tool in diagnosis of soft tissues of the head and neck and some laryngeal pathologies. Real time ultrasound examination allows for dynamic assessment of lesions. (Zajkowski and Biatek, 2007). Also, the ultrasound evaluate the mobility of the vocal cord that can be assessed easily by scanning in the midline transversely (Loveday, 2003 and Enaba et al., 2012). Our study agreed with Khalil et al. (2010); Amis et al. (2012) and Mohamed et al. (2015) that concluded that the laryngeal ultrasound has the same diagnostic ability as the video-stroboscopy in the assessment of the vocal cord mobility.

Khalil et al. (2010) and Wang et al. (2012) studied that the ultrasound can detect vocal cord nodules and polyps. The intra-arytenoid edema could not be detected as the arytenoid and interarytenoid area could not be identified by laryngeal ultrasound. However, the vocal cord video-stroboscopy was more useful. This was in agreement with Khalil et al. (2010) who reported that the interaryte-

noid edema could not be detected as the arytenoids, and interarytenoid area could not be seen by laryngeal ultrasound. No cases of ulceration was found in our study (Shao et al. 2002 and Schade et al. 2006).

Today, vocal cord video-stroboscopy is the clinical gold standard for assessment of phonatory and valvular functions of the glottis (Matta et al., 2015). However, it may suffer from some limitations imposed by a sensitive gag reflex or neck and jaw rigidity (Hartnick and Zeitels, 2005).

## CONCLUSION

High-resolution laryngeal ultrasound can be used in diagnosis of different vocal cord lesions as a complementary tool to video stroboscopy for diagnosis of various lesions of vocal cords. However, it cannot be used as the first tool for diagnosis before special experience has to be gained prior to it.

## REFERENCES

1. **Amis RJ, Gupta D, Dowdall JR, Srirajakalindini A and Flobe A (2012):** Ultrasound assessment of vocal fold paresis: a correlation case series with flexible fiberoptic laryngoscopy and adding the third dimension (3-D) to vocal fold mobility assessment. *Middle East J. Anesthesiol.*, 21:493-8.
2. **Dedecjus M, Adamczewski Z, Brzezinski J and Lewinski A (2010):** Real-time, high-resolution ultrasonography of the vocal folds - a prospective pilot study in patients before and after thyroidectomy. *Langenbechs Arch Surg.*, 395:859-864.
3. **Eller R, Ginsburg M, Lurie D, Heman-Ackah Y, Lyons K and Sataloff R (2008):** Flexible laryngoscopy: a comparison of fiber optic and distal chip technologies. *J Voice*, 22: 746-750
4. **Enaba MM, Elgerby KM and Fayeze W (2012):** Comparative study between laryngeal ultra-sonography and C.T scan of various



- laryngeal lesions. *Med J Cairo Univ.*: 80:219-24.
5. **Gomaa MA, Hammad MS, Mamdoh H, Osman N and Eissawy MG (2013):** Value of high resolution ultrasonography in assessment of laryngeal lesions. *Otolaryngologia Polska*, 67:252-256.
  6. **Hartnick CJ and Zeitels SM (2005):** Pediatric video laryngostroboscopy., *Int J Pediatr Otorhinolaryngol*,69:215–219.
  7. **Hu Q, Zhu SY, Zhang Z, Luo F, Mao YP, and Guan XH (2011):** Assessment of glottic sq. cell carcinoma: Comparison of sonography & non-contrast magnetic resonance imaging. *J Ultrasound Med.*, 30: 1467-1474.
  8. **Huang CC, Sun L, Dailey SH, Wang SH and Shung KK (2007):** High frequency ultrasonic characterization of human vocal fold tissue. *J Acoust Soc Am.*, 122:1827
  9. **Jadcherla SR, Gupta A, Stoner E, Coley BD, Wiet GJ and Shaker R (2006):** Correlation of glottal closure using concurrent ultrasonography and nasolaryngoscopy in children: a novel approach to evaluate glottal status. *Dysphagia*, 21:75–81
  10. **Khalil T, Madian Y and Farid A (2010):** High resolution laryngeal ultrasound for diagnosis of vocal cords lesions. *EJENTAS*, 11:64-68.
  11. **Kundra P, Mishra Sk and Ramesh A (2011):** Ultrasound of the airway. *India J. Anesth.*, 55:456-62.2.
  12. **Loveday EJ (2003):** Ultrasound of the larynx. *Imaging*, 15:109–114.
  13. **Matta IR, Halan KB, Agrawal RH and Kalwari MS (2015):** Laryngeal ultrasound in diagnosis of vocal cord palsy: An under utilized tool?.*Journal of Laryngology and Voice*, vol. 4 (1):244-49.
  14. **Mohamed D, El. Henawi DM, Ahmed MR, Farid AM and Hassan H (2015):** laryngeal u/s and laryngoscopy for the diagnosis and management of bilateral vocal fold paralysis. *The Egyptian Journal of Otolaryngology*, 31(4):231-236.
  15. **Nasr WF; Amer H.S; Askar SM and Enaba MM (2013):** Laryngeal Ultrasound as effective as CT scars for the diagnosis of various laryngeal lesions. *The Egyptian Journal of Otolaryngology*, 29:93-98.
  16. **Schade G, Kothe C and Leuwer R (2006):** Sonography of the larynx – an alternative to laryngoscopy. *HNO.*, 51:585-590.
  17. **Shalaby HA.A, Maaly MA and Abdellah TF (2013):** Ultra-sonography diagnostic validity in structural and functional laryngeal disorders. *Menoufia Medical Journal*, 26:170-176.
  18. **Shao J, Stern J, Wang Z.M, Hanson D and Jiang J (2002) :** Clinical evaluation of 70? and 90? laryngeal telescopes. *Arch Otolaryngol Head Neck Surg.*, 128 : 941 - 944
  19. **Singh M, Chin KJ and Chan VW (2010):**Use of sonography for airway assessment: an observational study. *J Ultrasound Med*, 29:79–85.
  20. **Sirikci A, Karatas E, Durucu C, Baglam T, Bayazit Y and Ozkur A (2007) :** Noninvasive assessment of benign lesions of vocal folds by means of Ultrasonography. *Laryngoscope*, 116:823–827.
  21. **Wang CP, Chen TC, Yang TL, Chen CN, Lin CF and Loub PJ (2012):** Trancutaneuos, U/S for evaluation of vocal fold movement in patients with thyroid dis. *Eur. J Radiol*, 81: e 288-91.
  22. **Wendy D (2007):** Laryngeal ultrasound provides noninvasive assessment of vocal fold lesions. *Ann Otol Rhinol Laryngol.*, 171:631–647.
  23. **Wolf M, Primov-Fever A, Amir O and Jedwab D (2005):** The feasibility of rigid stroboscopy in children. *Int J Pediatr Otorhinolaryngol.*, 69:1077–1079.
  24. **Zajkowski P and Bialek EJ (2007):** Ultrasound imaging in laryngology. *Otolaryngol Pol* , 61:544–549.

### هالة مغربى - هالة عبد الحسيب محمد \*

قسمي الأشعة التشخيصية والأنف والأذن والحنجرة \* - كلية الطب (بنات) جامعة الأزهر

**خلفية البحث:** تقييم التصوير الحنجري للأحبال الصوتية في تشخيص الأمراض المختلفة للحنجرة وكذلك استخدام الموجات فوق الصوتية على الحنجرة في التشخيص لمثل هذه الأمراض.

**الهدف من البحث:** عمل مقارنة بين استخدام الموجات فوق الصوتية على الحنجرة مع التصوير الحنجري للأحبال الصوتية في تشخيص الأمراض المختلفة المتعلقة بالأحبال الصوتية.

**المرضى وطرق البحث:** أجريت هذه الدراسة في الفترة ما بين أغسطس عام 2014 وحتى أبريل عام 2015 في قسم الأشعة التشخيصية وقسم الأذن والأنف والحنجرة - مستشفى الزهراء الجامعي. واشتملت الدراسة على ثلاثين مريضاً مما يعانون من أعراض مرضية متعلقة بأمراض الحنجرة مثل الهجة الصوتية، إختناقات الحنجرة، السعال المزمن، شرقة الغشاء المبطن للبلعوم أو وجود كتلات ورمية بالعنق. وقد تم عمل الموجات فوق الصوتية لكافة المرضى الخاضعين للدراسة بالإضافة إلى عمل التصوير الحنجري في الأحبال الصوتية أيضاً.

#### النتائج:

كانت نتائج البحث المكون من ثلاثين مريضاً كالتالى:

- إثني عشر مريضاً (40%) كانوا طبيعيين تماماً ولم توجد لديهم أية أمراض تبين وجودها سواء بالموجات فوق الصوتية أو نتيجة عمل التضيق الحنجري.
- إثنان من المرضى (6.6%) يعانون من شلل في الأحبال الصوتية.
- أربعة مرضى (13.3%) يعانون من نتوءات ولحميات على الأحبال الصوتية من الجهتين.
- ثلاثة مرضى (10%) يعانون من زوائد عنقودية بالأحبال الصوتية ذات جهة واحدة.
- إثنان مرضى (6.6%) يعانون من ترهل بالأحبال الصوتية الأساسية.
- إثنان من المرضى (6.6%) لديهم إرتشاح سائل على مدخل الحنجرة الخلفى مع وجود تورم بالأحبال الصوتية.
- مريض واحد (3.3%) لديه ورم على مدخل النجرة الأمامية ممتدا حتى الحبل الصوتى الأيمن.
- مريض واحد (3.3%) لديه وجود كتلة ورمية بالغدة اللعابية أسفل مفصل الفك السفلى.
- ثلاثة مرضى (10%) يعانون من تضخم بالفص الأيمن والأيسر مع نتوءات للغدة الدرقية.

**الخلاصة:** يمكن استخدام الموجات فوق الصوتية للحنجرة في تشخيص الأمراض المختلفة المتعلقة بالأحبال الصوتية وتعتبر مكملةً للتصوير الحنجري للأحبال الصوتية وذلك في تشخيص كافة الأمراض المختلفة المتعلقة بالأحبال الصوتية.