

ANTIOXIDANT, LIPID PEROXIDATION-INHIBITORY AND ANTI-ULCER ACTIVITIES OF BROWN PROPOLIS

Omar Mahmoud Mohamed Mohafez¹, Ihab Talat Abdel-Raheem² and Alaa Mohamed Nafady^{3*}

¹Department of Biochemistry, Faculty of Pharmacy, Al-Azhar University, Assiut 71524, Egypt.

²Department of Pharmacology and Toxicology, Faculty of Pharmacy, Al-Azhar University, Assiut 71524, Egypt

³Department of Pharmacognosy, Faculty of Pharmacy, Al-Azhar University, Assiut 71524, Egypt

تم تعيين التأثيرات المضادة للاكسدة لخلاصة الايثانول للصبغ البنى لنحل العسل بالتجارب المعملية عن طريق - - بيكريل هيدرازيل (د د ب) الماحى للشوارد الحرة وبطريقة الفوسفومولبيدات. وقد تبين ان لصبغ النحل تأثيرات فعالة في تركيز من - ميكروجرام/ وعلاوة على ذلك فلقد اثبتت التجارب الحيوية على الجرزان ان صبغ نحل العسل له تأثيرات قوية كمضاد للاكسدة كما ان له تأثير قوى في منع اكسدة الدهون في نسيج الكبد المتعرض لتأثير رباعي كلوريد الكربون ومن ناحية اخرى فلقد وجد ان المعجزة المسبقة للجرزان بخلاصة مغ النحل تقيها من حدوث القرحة عند تعاطى الاندوميثاسين كما اتضح من تراجع مؤشر القرحة والتغيرات الهستولوجية مثل زيادة الجلوتاثيون وتراجع دلالة اكسدة الدهون. ونستخلص من ذلك ان خلاصة الايثانول للصبغ البنى لنحل العسل قد اظهرت تأثيرات اساسية كمضاد للاكسدة والتقرح.

The antioxidant activity of the ethanolic extract of brown propolis was determined by in-vitro antioxidant assays via 1,1-diphenyl-2-picryl-hydrazyl (DPPH·) free radical scavenging activity and phosphomolybdenum method. The brown propolis extract had an effective DPPH-scavenging activity at 20-200µg/ml concentrations. Moreover, the in-vivo experiments showed that brown propolis extract has a powerful antioxidant and lipid peroxidation inhibitory activity in the liver tissues challenged with CCl₄. On the other hand, we found that pretreatment of rats with propolis extract protected gastric tissues against indomethacin-induced gastropathy as demonstrated from reduction in the ulcer index, attenuation of histopathological changes and amelioration of the altered oxidative stress biomarkers like glutathione, thiobarbituric acid reactive substance levels and superoxide dismutase activity in gastric tissues. In conclusion, total ethanolic extract of brown propolis exposed major anti-oxidant and anti-ulcer activities.

INTRODUCTION

Propolis (bee glue) was employed as an antiseptic in wound treatment, mouth disinfectant, anti-pyretic, anti-bacterial, anti-fungal, anti-viral, hepatoprotective, anti-inflammatory, treat gastroduodenal ulcers and immunomodulatory activities in addition to lowering blood pressure and cholesterol levels¹⁻³. When applied externally, it relieves various types of dermatitis caused by bacteria and fungi. It had been observed that different constituents' combinations are essential for the biological activity of the bee glue¹⁻³. The major constituent is polyphenols including flavo-

noids, accompanied by phenolic acids and esters, phenolic aldehydes and ketones. Other compounds in propolis are volatile oils and aromatic acids, waxes, resins, balsams and pollen grains⁴. According to the above mentioned data the total extract could have antioxidant activity and hence protects against several injuries caused by ROS. Therefore, the objective of this study was to estimate the total antioxidant activity and the protective effects of the propolis against CCl₄ in liver and indomethacin in gastric tissues.

EXPERIMENTAL

Chemicals

Brown propolis was purchased from Brazil (Supplied by Yamada Bee Company, Japan). A voucher specimen was deposited at the Department of Pharmacognosy, Faculty of Pharmacy, Al-Azhar University, Assiut, Egypt. DPPH, trichloroacetic acid and carbon tetrachloride were obtained from Merck and Sigma–Aldrich (Germany). Indomethacin was obtained from Nile Co., for Pharmaceutical Industries (Cairo, Egypt). All other chemicals are of analytical grade.

Animals and experimental design

a- For antioxidant activity

Male Wister Albino rats (8-10 weeks old) weighing from 100-125 g were used in this study, they were kept for two days to accommodate on laboratory conditions, under constant environmental and nutritional conditions. For lipid peroxidation experiment, animals were divided into three groups randomly: group one (control group n= 5) orally received equal volume of the solvent (50% ethanol and 0.1% tween-80) that used to dissolve the propolis extract; group two (propolis group n= 5) orally received 150 mg/Kg brown propolis extract followed by 1 ml/kg CCl₄ dissolved in olive oil, and, group three (CCl₄ group n= 5) received 1 ml/kg CCl₄ dissolved in olive oil. Each rat in all groups received 0.5 ml as a total volume. Regarding gastric mucosal protection experiments against indomethacin-induced gastric ulcers, rats were maintained at 12 hrs light/dark cycle during the study. They were fasted for 24 hrs before the experiments but had free access to drinking water⁵.

b- For antiulcer activity

The animals were divided into 4 groups each of 8 rats. Group 1: Rats in this group (control) were given the vehicle by intragastric gavage. Group 2: Rats in this group were orally treated with 100 mg/kg of propolis extract⁶. Propolis extract was suspended in 50% ethanol and tween 80 (drops) then diluted with distilled water for oral administration. Group 3: Rats in this group were treated by intragastric gavage with 48 mg/kg of indomethacin. This dose of indomethacin is within the range reported in

the literatures to elicit macroscopically visible acute hemorrhagic erosions and ulcers in the stomach of normal rats⁷. Group 4: Rats in this group were 1 hr pretreated with brown propolis extract orally before indomethacin at the same previous doses.

Extraction of brown propolis for antioxidant and antiulcer activity

Brown propolis (50 g) was cut into small pieces and extensively extracted with 70% hot ethanol three times each time 1 L., filtered, collected, concentrated and dried under vacuum till constant weight to afford of brownish extract, which was subjected to lyophilization (3 g).

In-vitro free radical scavenging activity using DPPH

The total radical scavenging capacity of the extract was determined and compared to standard antioxidant compounds (-tocopherol and hydroxyl ammonium chloride) by using the DPPH radical scavenging method. This spectrophotometric assay uses the stable radical, 1,1-diphenyl-2-picryl-hydrazyl (DPPH) as a reagent⁸. The method of Blois⁹ was used with slight modifications in order to assess the DPPH free radical scavenging capacity of brown propolis extract. Briefly, a 20 μM solution of DPPH was prepared in ethanol and 1mL of this solution was added to 1 mL ethanolic propolis solution at different concentrations (20–200 μg/mL). These solutions were mixed thoroughly and incubated in the dark for 30 min. The absorbance was measured at 517 nm against blank samples lacking scavenger. A standard curve was prepared using different concentrations of DPPH. The DPPH scavenging capacity was expressed as μM in the reaction medium and calculated from the calibration curve determined by linear regression ($r^2: 0.9999; y = 0.0869x + 0.0856$)⁸. The capability to scavenge the DPPH radical was calculated using the following equation: DPPH scavenging effect (%) = $(1 - AS/AC) \times 100$ Where AC is the absorbance of the control (1 mL DPPH solution plus 1ml ethanol, and AS is the absorbance in the presence of propolis extract¹⁰⁻¹². DPPH decreases significantly upon exposure to radical scavengers.

***In-vitro* evaluation of antioxidant capacity by phosphomolybdenum method**

Total antioxidant capacity of brown propolis extract was determined by the formation of phosphomolybdenum complex. This assay is based on the reduction of Mo (VI) to Mo (V) by antioxidant compounds and subsequent formation of a green phosphate–Mo (V) complex at acidic pH which has its maximum absorption at 695 nm. A high absorbance value indicates that the sample possessed good antioxidant activity¹³. The antioxidant capacity of brown propolis extract was determined according to the method of¹⁴ with some modifications; an aliquot of 0.1 mL of sample solution was combined with 1 mL reagent solution (0.6 M sulphuric acid, 28 mM sodium phosphate and 4 mM ammonium molybdate). The tubes were capped and incubated in boiling water for 90 min. After the mixture had cooled, the absorbance of the mixture was measured at 695 nm using a spectrophotometer (T80 UV/Vis spectrometer PG Instruments Ltd, UK) against reagent blank. The readings were taken at 15, 30, 60, and 90 min time intervals. The antioxidant activity was expressed as the absorbance of the sample. The higher the absorbance value, the higher is the antioxidant activity.

Determination of liver content of thiobarbituric acid reactive substance

Animals in the three groups (control group, propolis group and CCl₄ group) were sacrificed 48 hrs after receiving by intragastric gavage 50% ethanol in the control group; 150 mg/kg propolis extract dissolved in 50% ethanol followed by 1 ml/kg CCl₄ in the propolis group or 1 ml/kg CCl₄ alone in the CCl₄ group. The livers were excised rapidly and homogenized in 10 mM tris-HCl buffer pH 7.4 on ice. The liver content of malondialdehyde (MDA) and glutathione (GSH) were done directly on the freshly prepared specimens. Colorimetric determination of thiobarbituric acid reactive substance (TBARS) [as MDA equivalent]¹⁵, is based on the reaction of one molecule MDA with two molecules of thiobarbituric acid (TBA) at low pH (2-3) and a temperature of 95°C for 45 min. The resultant pink color was extracted with n-butanol, and the absorbance was determined at 532 nm spectrophoto-

metrically. A standard calibration curve was constructed using serial dilutions of HCl-treated 1,1,3,3-tetraethoxypropane as MDA (10-100 µM) precursor. The liver content of TBARS (as MDA) was determined from the standard curve ($R^2 = 0.9999$; $y = 0.0042x - 0.0021$). MDA content was expressed as µM/50 mg protein. The homogenate total protein content was assayed using Biuret reagent and bovine serum albumin as a standard.

Determination of hepatic glutathione (GSH) content

GSH content in liver homogenates from the three groups was determined using Ellman's reagent¹⁶. The assay is based on reduction of Ellman's reagent [5,5'-dithiobis (2-nitrobenzoic acid)] by SH groups to form 1 mole of 2-nitro-5-mercaptobenzoic acid per one mole of SH. The nitromercaptobenzoic acid has an intense yellow color and can be determined spectrophotometrically at 412 nm. A standard calibration curve was constructed using serial dilutions of reduced glutathione (10-100 µM). The liver content of GSH was determined from the standard curve ($R^2 = 0.9973$; $y = 0.0024x + 0.0071$). GSH content was expressed as µM/mg protein.

Determination of antiulcer activity

After 6 hrs of indomethacin treatment the rats were sacrificed by decapitation; the stomachs were rapidly removed and processed for evaluation of gastric mucosal damage, calculation of the ulcer score and histopathological examination. Gastric glandular mucosal tissues were weighed, homogenized in ice-cold bi-distilled water using a Teflon homogenizer to obtain a 10% w/v aqueous homogenate. The aliquot was kept frozen at (-40°C) until determination of oxidative stress biomarkers like glutathione (GSH), thiobarbituric acid reactive substance (TBARS) levels and superoxide dismutase (SOD) activity. Glutathione content of gastric mucosal tissues homogenate was determined using Ellman's reagent¹⁶. Lipid peroxide levels in gastric mucosal tissue homogenate were measured according to the method of Mihara and Uchiyama¹⁵. The enzymatic activity of superoxide dismutase in gastric mucosal tissue homogenate was determined in the gastric

mucosa according to the method of Marklund¹⁷, by computing the difference between auto-oxidation of pyrogallol alone and in presence of superoxide dismutase enzyme.

Evaluation of gastric mucosal injury

The stomachs rapidly removed, opened by an incision along the greater curvature, washed 3 times with physiological solution, pinned out on a wax platform, and photographed. The lesions, hemorrhagic or ulcerative, were counted and measured with microcalipers by an observer who was unaware of the treatment. The gastric ulcer index was then calculated as the sum of the lengths in millimeters of all glandular mucosal lesions (seen as red streaks)¹⁸.

Histopathological evaluation

The stomach of each animal was dissected out then fixed in 10% formalin for 24 hrs and processed for histopathological examination. Four micrometer-thick paraffin sections were stained with hematoxylin and eosin for light microscope examination using conventional protocol¹⁹. A minimum of 8 fields for each stomach section were examined and assigned for severity of changes by an observer blinded to the treatments of the animals.

Statistical Analysis

Results were expressed as the means \pm SEM. Statistically significant difference was determined by one-way analysis of variance (ANOVA) followed by Tukey's posthoc test for multiple comparisons. A probability value of $p < 0.05$ was considered to indicate statistical significance.

RESULTS AND DISCUSSION

In this *in-vitro* assay, the total antioxidant activity of propolis extract was measured and compared with hydroxyl ammonium chloride (Fig. 1). According to the results, propolis extract had marked antioxidant activity and the effect increased with increasing reaction time and increasing concentration. The total antioxidant activity of propolis extract at the concentration of 50 $\mu\text{g/mL}$ at 90 min was 0.655 while it was 0.715 for hydroxyl ammonium chloride. The total antioxidant of propolis extract was comparable to that of the hydroxyl

ammonium chloride at all the concentrations tested.

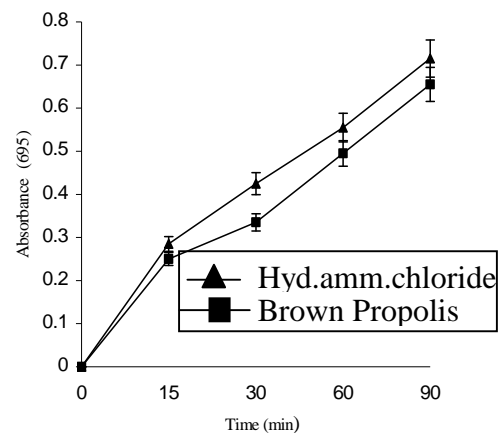


Fig. 1: Total antioxidant activity of the brown propolis extract as determined by phosphomolybdenum method compared to hydroxylammonium chloride. Results are mean \pm SD of three parallel measurements. Higher absorbance value indicates higher antioxidant activity.

Brown propolis extract exhibited effective *in-vitro* radical scavenging activity as seen in figure 2. It is an effective DPPH radical scavenger in a concentration-dependent manner (20-200 $\mu\text{g/mL}$, $r^2:0.9975$). There was a significant decrease ($p < 0.001$) in the concentration of DPPH radical due to the scavenging capacity at all brown propolis extract concentrations. The scavenging effect (%) of brown propolis extract, -tocopherol and hydroxyl ammonium chloride on the DPPH radical was (47.57, 51.11 and 54.25%, respectively) at the concentration of 100 $\mu\text{g/mL}$. DPPH free radical scavenging activity of propolis extract also increased with increasing concentrations ($r^2:0.9975$).

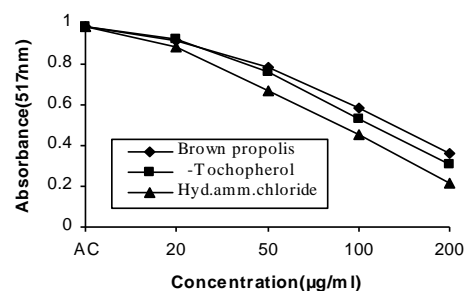


Fig. 2: Free radical scavenging activity of brown propolis extract. DPPH free radical scavenging activity of different concentrations (20-200 $\mu\text{g/mL}$) of brown propolis extract compared to -tocopherol and hydroxylammonium chloride. Results are mean \pm SD of three parallel measurements ($r^2: 0.9999$; $y = 0.0869x + 0.0856$).

In-vivo lipid peroxidation (as MDA equivalent) in hepatic tissue was measured in the three groups of animal (control, CCl₄ and brown propolis). As shown in figure 3, there is a significant ($p < 0.001$) decrease in MDA level in brown propolis extract group compared to that of the CCl₄ group. The MDA concentration was 38.97 ± 2.15 , 77.8 ± 2.16 and 97.02 ± 3.59 μM MDA/ 50mg protein for control, brown propolis extract and CCl₄, respectively. This clearly indicates that administration of propolis extract protects from the lipid peroxidation effect of CCl₄.

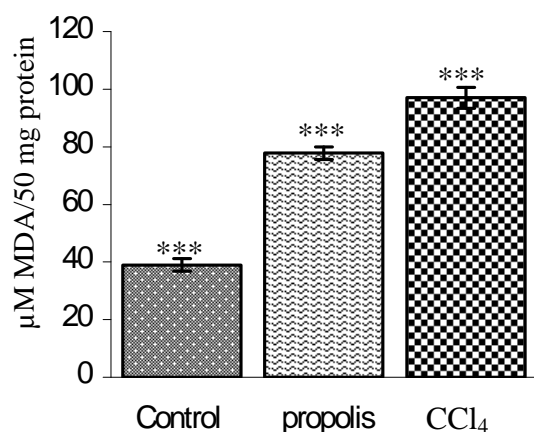


Fig. 3: *In-vivo* lipid peroxidation inhibitory effect of brown propolis extract. MDA levels in 50 mg protein of liver homogenate in the different groups. The control group received solvent of the propolis extract (50% ethanol and 0.1% tween-80); propolis group received 150 mg/Kg brown propolis extract followed by 1 ml/kg CCl₄ dissolved in olive oil and the CCl₄ group received 1ml/kg CCl₄ dissolved in olive oil. Results are mean \pm SD of the five rats of each group as calculated from the standard curve. ($R^2 = 0.9999$; $y = 0.0042x - 0.0021$). The significant difference between the groups was determined by ANOVA test. $***P < 0.001$.

Hepatic tissue content of reduced glutathione was measured in the three groups (control, CCl₄ and brown propolis extract). In spite the absence of complete normalization ($p < 0.001$), there was a significant increase in GSH level in propolis group in comparison to that of the CCl₄ group as shown in figure 4. The GSH concentration was 5.2 ± 0.21 , 4.1 ± 0.24 and 2.4 ± 0.26 μM GSH/mg protein for control, brown propolis extract and CCl₄, respectively. These results declared the *in-vivo*

antioxidant activity of the brown propolis extract and confirmed its lipid peroxidation inhibitory activity.

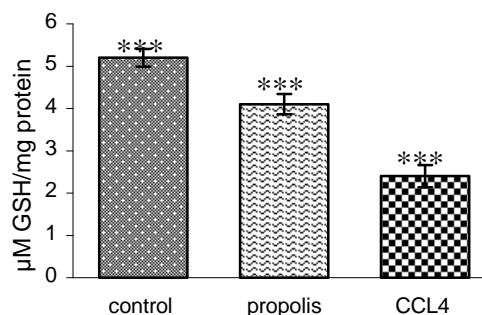


Fig. 4: Effect of brown propolis extract on liver content of reduced glutathione. GSH levels in the different groups was determined by Ellman's reagent. The control group received solvent of the propolis extract (50% ethanol and 0.1% tween-80); propolis group received 150 mg/Kg brown propolis extract followed by 1 ml/kg CCl₄ dissolved in olive oil and the CCl₄ group received 1 ml/kg CCl₄ dissolved in olive oil. Results are mean \pm SD of the five rats of each group and the concentration calculated using the standard curve. ($R^2 = 0.9973$; $y = 0.0024x + 0.0071$). The significant difference between the groups was determined by ANOVA test. $***P < 0.001$.

Qualitative evaluation of gastric mucosal injury morphologically

No visible hemorrhagic or ulcerative lesions were seen in control and propolis groups (Fig. 5A and B). Oral administration of indomethacin for 6 hrs induced gross glandular gastric mucosal damage in rats. These hemorrhagic and ulcerative lesions were seen as red streaks (Fig. 5C). Pretreatment with propolis extract markedly reduced the visible hemorrhagic lesions induced by indomethacin in rat stomachs (Fig. 5D).

Quantitative estimation of gastric ulcer index (GUI)

The hemorrhagic and ulcerative lesions induced by indomethacin were expressed as gastric ulcer index (calculated as the sum of the lengths in millimeters of all lesions) (Fig. 6). The ulcer index (mm) measured in the gastric mucosa of indomethacin-treated group was (80 ± 6.1 mm). Pretreatment with propolis extract markedly reduced the ulcer index to (20 ± 1.4 mm) producing about 75% reduction in gastric lesions induced by indomethacin in rat

stomachs (Fig. 6). Similar to vehicle control group, oral administration of propolis extract alone to rats did not show hemorrhagic or ulcerative lesions (Fig. 6).

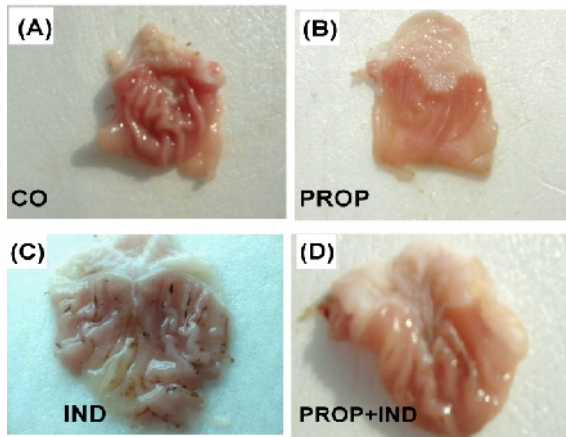


Fig. 5: The gross protective effects of brown propolis extract against gastric mucosal hemorrhagic lesions induced by indomethacin in rats. Visible hemorrhagic and ulcerative lesions were absent in control (CO) and propolis extract (PROP) groups (photos A, B). Gross appearance of hemorrhagic lesions (seen as dark streaks) was found in indomethacin (IND) group (photo C). Pretreatment with propolis extract (PROP+IND) markedly reduced the visible hemorrhagic lesions induced by full forming indomethacin in rat stomach (photo D).

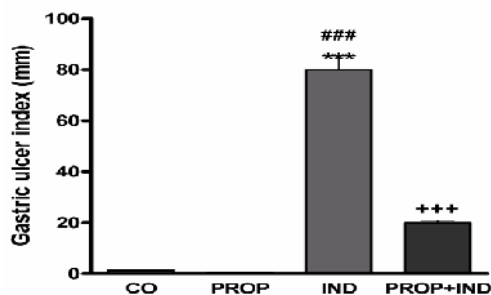


Fig. 6: Effects of indomethacin (IND), brown propolis extract (PROP), and their combination (PROP+IND) on gastric ulcer index compared to control (CO). Data are expressed as means \pm SEM., (n = 8/group). The significant difference between two groups was determined by ANOVA followed by Tukey's multiple comparison test. *** $P < 0.001$, statistically significant difference from control group, ### $P < 0.001$, statistically significant difference from propolis group, +++ $P < 0.001$, statistically significant difference from indomethacin group.

Histological evaluation of gastric mucosal injury

Sections from control and propolis extract groups showed normal histological structure of the gastric mucosa, lamina propria and submucosal layer (H&E x40) (Fig. 7, photos A, B). In indomethacin group, there was diffuse leucocyte infiltration (m) in lamina propria of the mucosa (H&E x64, (Fig. 7, photo C). The glandular portion showed edema with congestion in the blood vessels (v) of the serosal layers (s) (Fig. 7, photo D) (H&E x64). Pretreatment with brown propolis extract before indomethacin maintained the normal histological structure of the glandular mucosa (H&E x64) (photo I) with few leucocytes cells infiltration (m) (H&E x64) (Fig. 7, photo E). Pretreatment with brown propolis extract attenuated the leucocytes infiltration from diffuse one to little infiltration indicating that extract decreased ROS-generated inflammation but it did not inhibit it at all. This may be attributed to competitive antagonism between the antioxidant activity of the extract and free radicals generation by indomethacin or the dose of the extract needs to be modified.

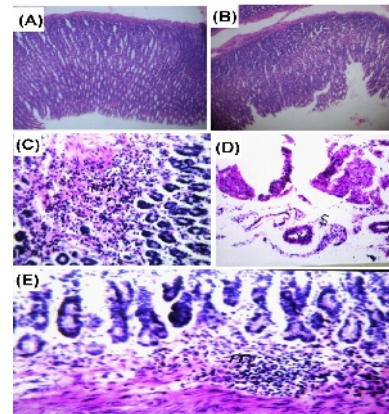


Fig. 7: The histopathological alterations induced by indomethacin and the protective effects of brown propolis extract against gastric mucosal hemorrhagic lesions induced by indomethacin in rats. Sections from control and propolis groups showed normal histological structure of the gastric mucosa, lamina propria and submucosal layer (H&E x40) (photos A, B). Indomethacin group showed diffuse leucocyte infiltration (m) in lamina propria of the mucosa (H&E x64, (photo C). The glandular portion showed edema with congestion in the blood vessels (v) of the serosal layers (s) (photo D) (H&E x64). Pretreatment with propolis extract before indomethacin maintained the normal histological structure of the glandular mucosa (H&E x64) (photo I) with few leucocytes cells infiltration (m) (H&E x64) (photo E).

Several investigators have postulated a link between generation of free radicals elicited by indomethacin and the pathogenesis of gastric ulcer²⁰⁻²². In this study, indomethacin produced a decrease in glutathione levels from 25±1.6 to 15±1.3 nmol/g tissue. Our results were further supported by the data obtained from Morsy and Fouad²⁰ who reported depletion in glutathione contents in gastric tissues of indomethacin-treated rats. Propolis extract prevented the indomethacin-induced decline in glutathione content and restored its normal level to 21±2 (Table 1). Moreover, indomethacin caused an elevation in TBARS levels in gastric tissues from 3±0.31 to 9±0.71 nmol/g tissue. The free radicals induce lipid peroxidation and changes in membrane lipid composition further aggravates gastric damage²¹. Propolis extract was able to normalize the elevated TBARS levels to 5±0.43 nmol/g tissue (Table 1). In this study, the reduction in superoxide dismutase activity after indomethacin treatment has been previously recorded²² suggesting that oxidative stress is one of the causes of indomethacin-

induced gastropathy. Superoxide dismutase activity (U/mg protein) was decreased in gastric tissues of indomethacin-treated rats from 36±4.1 to 14±0.9. However, superoxide dismutase activity was increased to 30±2.1 after propolis extract administration (Table 1). Several studies have reported that among the signs of indomethacin-induced gastric ulcers is increased gastric acidity^{20&22}, however in our study the brown propolis extract did not affect the basal gastric acidity or the elevated gastric acidity induced by indomethacin indicating that the propolis extract is truly gastroprotective agent regardless to gastric acidity. Our results were in accord with that of Borrelli *et al.*²³ who reported that the major components of propolis extract did not affect the basal gastric acid secretion nor the secretion stimulated by other stimulants.

Several other researchers have reported the antiulcer activity of Brazilian green propolis^{24&25}, however, this is the first time to report about the antiulcer activity of brown propolis extract as indicated from the results of this study.

Table 1: Effects of indomethacin (IND), Propolis extract (PROP) and their combination (RROP+IND) on reduced glutathione contents (GSH), thiobarbituric acid reactive substance contents (TBARS) and superoxide dismutase activity (SOD) in gastric tissues compared to control (CO) group.

Parameters/Group	Control (CO)	Propolis (PROP)	Indomethacin (IND)	Combination PROP+IND
GSH (nmol/g tissue)	25 ± 1.6	27 ± 2.1	15 ± 1.3***	21 ± 2* ⁺⁺
TBARS (nmol/g tissue)	3 ± 0.31	4 ± 2.3	9 ± 0.71***	5 ± 0.43 ⁺
SOD (U/mg protein)	36 ± 4.1	39 ± 3	14 ± 0.9***	30 ± 2.1* ⁺⁺

The significant difference between groups was determined by ANOVA followed by Tukey's multiple comparison test. * $P < 0.05$ *** $P < 0.001$, statistically significant difference from control group. ⁺ $P < 0.05$; ⁺⁺ $P < 0.01$, statistically significant difference from indomethacin group.

Conclusions

Brown propolis extract has a gastroprotective activity against indomethacin-induced ulcers and its mechanism is probably through its antioxidant activity without any effects on gastric acidity suggesting that this extract is a truly gastroprotective agent regardless to gastric acidity.

Acknowledgment

We are grateful to **Prof. Dr. Adel M. Bakeer**, Professor of Pathology, Faculty of Veterinary Medicine, Cairo University for his kind help in performing histopathological studies and interpretation of their results.

REFERENCES

- 1- W. Greenway, T. Scaysbrook, and F. R. Whatley, "The Analysis of Bud Exudate of Populus and of Propolis, by Gas Chromatography-Mass Spectrometry". Proceeding of Royal Society, London, VB232, 1987, pp. 249-272.
- 2- V. Bankova, R. Christov, A. Kujmgiev, M. C. Marcucci and S. Popov, "Chemical composition and antibacterial activity of Brazilian propolis", Zeitschrift für Naturforschung, 50C, 167-173 (1995).
- 3- W. Greenway, J. May, T. Scaysbrook and F. R. Whatley, "The composition and plant origins of propolis: a report of work at Oxford", Bee world, 71, 107-118 (1990).
- 4- S. Castaldo and F. Capasso, "Propolis, an old remedy used in modern medicine", Fitoterapia, 73c, 1-6 (2002).
- 5- T. Suzuki, N. Yoshida, N. Nakabe, Y. Isozaki, H. Kajikawa, T. Takagi, "Prophylactic effect of rebamipide on aspirin-induced gastric lesions and disruption of tight junctional protein zonula occludens-1 distribution", Journal Pharmacological Science, 106, 469-477 (2008).
- 6- S. Rodríguez, O. Ancheta, M. E. Ramos, D. Remírez, E. Rojas, R. González, "Effects of Cuban red propolis on galactosamine-induced hepatitis in rats", Pharmacological Research, 35, 1-4 (1997).
- 7- B. L. Slomiany, A. Slomiany, "Role of endothelin-converting enzyme-1 in the suppression of constitutive nitric oxide synthase in rat gastric mucosal injury by indomethacin", Scand Journal of Gastroenterology, 35, 1131-1136 (2000).
- 8- M. Burits and F. Bucar, "Antioxidant activity of *Nigella sativa* essential oil", Phytotherapy Research, 14, 323-328 (2000).
- 9- A. A. Adedapo, F. O. Jimoh, A. J. Afolayan, and P. J. Masika, "Antioxidant activities and phenolic contents of the methanol extracts of the stems of *Acokanthera oppositifolia* and *Adenia gummifera*", BMC Complementary and Alternative Medicine, 8, 54 (2008).
- 10- J. Ancerewicz, E. v., P. A. Carrupt, B. Testa, F. Bree, R. Zini, J. P. Tillement, S. Labidalle, D. Guyot, A. M. Chauvet-Monges, A. Crevat and A. Le Ridant, "Structure-property relationships of trimetazidine derivatives and model compounds as potential antioxidants", Free Radiccal Biological Medicine, 25, 113-20 (1998).
- 11- I. Gulcin, S. Beydemir, H. A. Alici, M. Elmastas and M. E. Buyukokuroglu, "*In-vitro* antioxidant properties of morphine". Pharmacological Research, 49, 59-66 (2004).
- 12- S. Y. Lin, C. C. Wang, Y. L. Lu, W. C. Wu and W. C. Hou, "Antioxidant, anti-semicarbazide-sensitive amine oxidase, and anti-hypertensive activities of geraniin isolated from *Phyllanthus urinaria*", Food Chemical Toxicology, 46, 2485-92 (2008).
- 13- P. Prieto, M. Pineda and M. Aguilar, "Spectrophotometric quantitation of antioxidant capacity through the formation of a phosphomolybdenum complex: specific application to the determination of vitamin E", Analytical Biochemistry, 269, 337-341 (1999).
- 14- M. Mihara and M. Uchiyama, "Determination of malonaldehyde precursor in tissues by thiobarbituric acid test", *ibid.*, 86, 271-278 (1978).
- 15- G. L. Ellman, "Tissue sulfhydryl groups", Achieve of Biochemistry Biophysiology, 82, 70-77 (1959).
- 16- S. L. Marklund, "Superoxide dismutase isoenzymes in tissues and plasma from New Zealand black mice, nude mice and normal BALB/c mice", Mutatant Research, 148, 129-134 (1985).

- 17- J. L. Wallace, C. M. Keenan, DN. Granger, "Gastric ulceration induced by nonsteroidal anti-inflammatory drugs is a neutrophil-dependent process", *American Journal of Physiology*, 259, 462-467 (1990).
- 18- J. Bancroft, A. Stevens, "Theory and Practice of Histological Techniques", In: Stevens A (eds). New York: Churchill Livingstone, 1982, pp. 188-190.
- 19- S. Gupta, and, J. Prakash, "Studies on Indian green leafy vegetables for their antioxidant activity", *Plant Foods Human Nutrition*, 64, 39-45 (2009).
- 20- M. A. Morsy, A. A. Fouad, "Mechanisms of gastroprotective effect of eugenol in indomethacin-induced ulcer in rats", *Phytotherapy Research*, 22, 1361-1366 (2008).
- 21- P. Sandhya, P. Varalakshmi, "Effect of lipoic acid administration on gentamicin-induced lipid peroxidation in rats", *Journal of Applied Toxicology*, 17, 405-408 (1997).
- 22- T. K. Motawi, H. M. Abd Elgawad, N. N. Shahin, "Gastroprotective effect of leptin in indomethacin-induced gastric injury", *Journal of Biomedical Sciences*, 15, 405-412 (2008).
- 23- F. Borrelli, I. Posadas, R. Capasso, G. Aviello, V. Ascione, F. Capasso, "Effect of caffeic acid phenethyl ester on gastric acid secretion *in-vitro*", *European Journal of Pharmacology*, 3, 521, 139-143(2005).
- 24- M. P. Barros, M. Lemos, E. L. Maistro, M. F. Leite, Sousa, J. P. J. K. Bastos. "Andrade SF. Evaluation of antiulcer activity of the main phenolic acids found in Brazilian Green Propolis", *Journal of Ethnopharmacology*, 120, 372-377 (2008).
- 25- M. Lemos, M. P. de Barros, J. P. Sousa, A. A. da Silva Filho, J. K. Bastos, S. F. de Andrade, "*Baccharis dracunculifolia*, the main botanical source of Brazilian green propolis, displays antiulcer activity", *Journal of Pharmacy Pharmacology*, 59, 603-608 (2007).