

NESFATIN-1 TREATMENT ALLEVIATES INDOMETHACIN-INDUCED GASTRIC ULCER IN RATS

By

Dalia I. Abd Al-Aleem and Dalia M. Abd- Al-Mottaleb

Departments of Physiology and Pharmacology, Faculty of Medicine, Zagazig University

ABSTRACT

Background: Indomethacin is a non-steroidal anti-inflammatory drug which is known to produce serious adverse effects including ulcerative lesions. Nesfatin-1, is an identified anorexigenic peptide to have antioxidant effects.

Objective: This study aimed to investigate the possible ameliorative effect of nesfatin-1 against indomethacin induced gastric ulcer in rats, with exploration of the possible mechanisms underlying this effect.

Materials and methods: Twenty four adult male albino rats were the animal model of this study. Ulcers were induced using oral indomethacin (20mg/kg) daily for 7 days. The rats were randomly assigned to vehicle-treated control group (I), indomethacin-treated (II), and indomethacin-treated for 7 days followed by nesfatin-1 (1ug/kg i.p) daily for 10 days. Assessment of gastric juice parameters (total acid output, pepsin activity and mucin content),-gastric mucosal levels of malondialdehyde (MDA) , tumor necrosis factor –alpha (TNF-alpha) , nitrite and prostaglandin E2 (PGE2) levels were also determined. This in addition to assessment of gastric lesions and histopathologic examination of the gastric mucosa in each group.

Results: Nesfatin-1 displayed a significant ameliorative effect in gastric lesions induced by indomethacin as indicated by a significant decrease in ulcer index and improved histopathology, along with a significant reduction in measured gastric juice parameters .It also reduced both gastric mucosal MDA and TNF-alpha significantly and increased nitrite and PGE2 levels in this ulcer model.

Conclusion: Nesfatin-1 attenuates indomethacin- induced gastric ulcer and potentiates ulcer healing in the stomach of rats exposed to chronic administration of indomethacin. This effect depended upon decrease in gastric secretion, increase in nitric oxide and PGE2, besides an antioxidant anti-inflammatory role.

Keywords: Nesfatin-1, indomethacin, gastric ulcer, MDA, TNF-alpha, nitric oxide, rats.

INTRODUCTION

Gastric ulcer is an illness that affects a considerable number of people world-wide. The etiological factors of this disorder include stress, smoking, nutritional deficiencies, frequent and indiscriminate use of non steroidal anti-

inflammatory drugs (NSAIDs) (**Khazaei and Salehi , 2006**).

The pathophysiology of gastric ulcer has generally focused on imbalance between aggressive and protective factors in the stomach (**Lima et al., 2006**). The gastric ulcerogenic action of NSAIDs is believed to occur mainly due to their local

inhibitory effect on gastric prostaglandin E2 (PGE2) and prostaglandin I2 (PGI2) that are the main inhibitors of gastric acid secretion (Ribeiro-Rama et al., 2009), in addition to oxidative gastric damage and the generation of pro-inflammatory mediators (Kolgazi et al., 2014).

Nesfatin-1 was identified as an anorexigenic factor associated with leptin and melanocortin signaling in the hypothalamus (Maejima et al., 2009 and Darambazar et al., 2015).

This hypothalamic neuropeptide is composed of 82 amino acids with a molecular weight of 9.8 kDa, which is derived from the larger protein nucleobindin-2 (NUCB2) (Oh-I et al., 2006).

As a brain-gut peptide, nesfatin/NUCB2 is expressed in appetite-control hypothalamic nuclei, including the paraventricular nucleus of the hypothalamus (PVN), supraoptic nucleus (SON), arcuate nucleus (ARC) and lateral hypothalamic area (LHA) (Kohno et al., 2007). Additionally, peripheral tissues, such as the stomach, adipose tissue, the heart and pancreas were considered as sources for this peptide (Stengel et al., 2009, Garcà-Galiano et al., 2010, Foo et al., 2010, Zhang et al., 2010, Angelone et al., 2013 and Stengel et al., 2013).

Interestingly, NUCB2 mRNA expression is 10-times higher in the rat gastric mucosa than in the brain giving rise to a predominant production of nesfatin-1 in the stomach (Stengel et al., 2009). Nesfatin-1 regulates gastrointestinal motility and, in particular, it inhibits gastric contractions in the fasted state (Watanabe et al., 2015).

It is worth mentioning that nesfatin-1 has neuroprotective function in rats with subarachnoid hemorrhage through anti-inflammatory and antiapoptotic properties (Ozsavci et al., 2011 and Tang et al., 2012).

The present study aimed to investigate the possible ameliorative effect of nesfatin-1 against indomethacin induced gastric ulcer in rats, with exploration of the possible mechanisms underlying this effect.

MATERIALS AND METHODS

All the experimental procedures were conducted in accordance with the guiding principles for the care and use of research animals and were approved by the Institutional Review Board of Faculty of Medicine, Zagazig University.

Drugs and chemicals: Nesfatin-1 was obtained from Sigma chemical Co. (St. Louis, MO. USA) as a powder and was dissolved in normal saline. Indomethacin was obtained from Sigma chemical Co. (St. Louis, MO. USA), and was suspended in 0.5 % carboxymethylcellulose (Merck, Darmstadt, Germany).

Animals: Twenty four adult male albino rats of a local strain weighing 130-160 grams were purchased from the animal house of Faculty of Veterinary Medicine-Zagazig University. Animals were housed in plastic cages (40x28x18cm -4/cage) and given tap water ad libitum, fed with standard commercial rat chow and were left to accommodate for one week before dosing, normal light/dark regular cycles in partially humid and well aerated room.

Experimental design: The animals were randomly divided into three equal groups : (I) Vehicle-treated control group: in which the animals received carboxymethylcellulose (0.5%) orally daily for 7 days then saline was administered intraperitoneally (i.p.) for 10 days - (II) indomethacin- treated group, chronic gastric ulcer induction where the rats received oral indomethacin in a dose of 20 mg? kg suspended in 0.5% of carboxymethylcellulose daily for 7 days (**Tariq et al., 2007**), then received i.p saline for 10 days. (III) indomethacin- treated group followed by nesfatin-1 : in which animals were given oral indomethacin in a dose of 20 mg? kg suspended in 0.5% of carboxymethylcellulose daily for 7 days , then given Nesfatin-1 (1ug/Kg) intraperitoneal for 10 days (**Kolgazi et al., 2014**). At 17th day, rats were fasted for 16 hours prior to sample collection (**Xia et al., 2012**)

Pyloric ligation: It was carried out at the end of the study period in order to collect gastric secretion (**Alumets et al., 1982**). This was done under ether anesthesia, a midline abdominal incision was performed, the pyloric portion of the stomach was gently mobilized and carefully ligated with a silk ligature around the pyloric sphincter taking care not to interfere with gastric blood supply. Abdominal incision was sutured and the animals were allowed to recover from anesthesia, the stomach was excised,

Analysis of gastric juice: Three hours after the ligation, rats of all groups were euthanized with an overdose of ether, their stomachs were rapidly removed, opened by an incision along the greater curvature and the gastric juice were collected.

Gastric juice from each animal was centrifuged at 1000 g for 10 minutes to remove any solid debris and the volume of the supernatant was measured. The supernatant was then assayed for total acid concentration (**Hara et al., 1991**). The total acid output was calculated by multiplying the volume of gastric juice by the total acid concentration. Also, pepsin activity (**Sanyal et al., 1971**) and mucin content (**Winzler, 1955**) were determined.

Quantification of ulceration: Degrees of ulceration in the indomethacin-treated animals were quantified using the procedure outlined by **Szabo and Hollander, (1985)**. Briefly, cleaned stomachs were pinned on a corkboard and ulcers were scored using dissecting microscope with square-grid eyepiece based on grading on a 0–5 scale (depicting severity of vascular congestions and lesions/hemorrhagic erosions) as follows: 0= Almost normal mucosa, 1= Vascular congestions, 2= One or two lesions, 3= Severe lesions, 4= Very severe lesions, 5= Mucosa full of lesions. Mean ulcer score for each animal was expressed as ulcer index.

Biochemical analysis of gastric mucosa: The stomach was rinsed with saline and divided into three parts. Gastric mucosa of one part was scrapped and homogenized in 2 ml normal saline containing 0.1 M dithiothreitol and centrifuged at 2000 r.p.m for 10 minutes at room temperature. The supernatant was used for determination of prostaglandin E2 (PGE2) level by ELISA using PGE2 immunoassay kit (R&D systems, USA) according to **Granstrom et al. (1980)**.

The mucosa of another part of the stomach was also scrapped, homogenized in cold potassium phosphate buffer (0.05 M, pH7.4) and centrifuged at 2000 r.p.m for 10 minutes at 4°C; the supernatant was then kept at - 80°C for measurement of malonaldehyde (MDA) using Oxis kits (MDA586, Oxis International, Foster City, CA, USA) (Niehaus and Samuelsson, 1968) , and TNF-alpha using enzyme linked immunosorbent assay kit (Abcam, Catalog No. ab100785, USA)(He and Ting, 2002). Also the total nitrate/nitrite in the gastric mucosal homogenate was assayed after reduction of nitrate to nitrite using the cadmium reduction method (Sastry et al., 2002).

Histological studies: These were performed according to the method previously described (Ogihara and Okabe, 1993). At autopsy, small pieces of tissue, including ulcers, were embedded in paraffin and sectioned at 5µm in an automated microtome. Haematoxylin and eosin staining was done. Tissue contraction, regeneration of the ulcerated mucosa, formation of granulation tissue, glands arrangement and inflammatory exudates were observed under the

microscope. To get the histopathological picture of the ulcer before healing, a pilot study was done on the stomach mucosa on day seven of treatment with indomethacin.

Statistical analysis: Data were presented as mean ± S.D and statistical significance was determined by one way analysis of variance (ANOVA) followed by LSD test, P values less than 0.05 were considered to be significant. In statistical analysis, SPSS version 18 program for Windows (SPSS Inc. Chicago, IL, USA) was used.

RESULTS

Indomethacin significantly increased gastric juice total acid output as compared to control group .In contrast, Nesfatin-1 treatment significantly reduced total acid output in group III. Pepsin activity significantly increased by indomethacin as compared with the control group. Rats treated with Nesfatin-1 showed significant reduction in pepsin activity when compared with that of group II. Also, indomethacin significantly reduced gastric juice mucin content in group II compared to the control group. In Nesfatin-1 treated rats, this value significantly raised when compared with that of group II (Table 1).

Table (1): Total acid output, pepsin activity and mucin content of gastric juice in all groups (Mean ± SD).

Parameters	Total acid output (meq/3h)	Pepsin activity (?g/ml tyrosine)	Mucin content (mg %hexose)
I. Control	49.4.4±3.03	119.5±4.3	85±3.2
II. Indomethacin treated	70.9±5.3 ^{a*}	169.8±8.47 ^{a*}	55.13±4.79 ^{a*}
III. Indomethacin treated followed by Nesfatin-1 treatment	60.5.±2.5 ^{a*,b*}	130.48±5.43 ^{a*,b*}	73.74±6.64 ^{a*,b*}

*=significant, a (versus group I), b (versus group II)

Indomethacin significantly increased gastric mucosal MDA levels as compared to control group. In contrast, Nesfatin-1 treatment significantly reduced MDA in group III. Gastric mucosal TNF-alpha levels significantly increased by indomethacin as compared with the control group. Rats treated with Nesfatin-1 showed significant reduction in TNF-

alpha levels when compared with that of group II. Also, indomethacin significantly reduced both gastric mucosal content of PGE2 and nitrite in group II compared to the control group. In nesfatin-1 treated rats, those values significantly raised when compared with that of group II (Table 2).

Table (2): Gastric mucosal MDA, TNF-alpha, PGE2 and nitrite in all groups (Mean ± SD).

Parameters Groups	Malonaldehyde level (nmol/gm wet Tissue)	TNF-alpha (pg/ml)	PGE2 (ng/gm wet Tissue)	Nitrite (nmol/gm wet Tissue)
I. Control	19.1±0.2	290.5±12	319±10.5	165±3.59
II. Indomethacin treated	54.3±4.1 ^{a*}	430±25 ^{a*}	160±4.5 ^{a*}	105.13±5.79 ^{a*}
III. Indomethacin treated followed by Nesfatin-1 treatment	26.6±2.2 ^{a*,b*}	330±15 ^{a*,b*}	210±±7.5 ^{a*,b*}	129.8±6.64 ^{a*,b*}

*=significant, a (versus group I), b (versus group II)

Indomethacin significantly increased gastric ulcer index as compared to control group. In contrast, Nesfatin-1 treatment

significantly reduced this index in group III (p<0.001) (Fig.1).

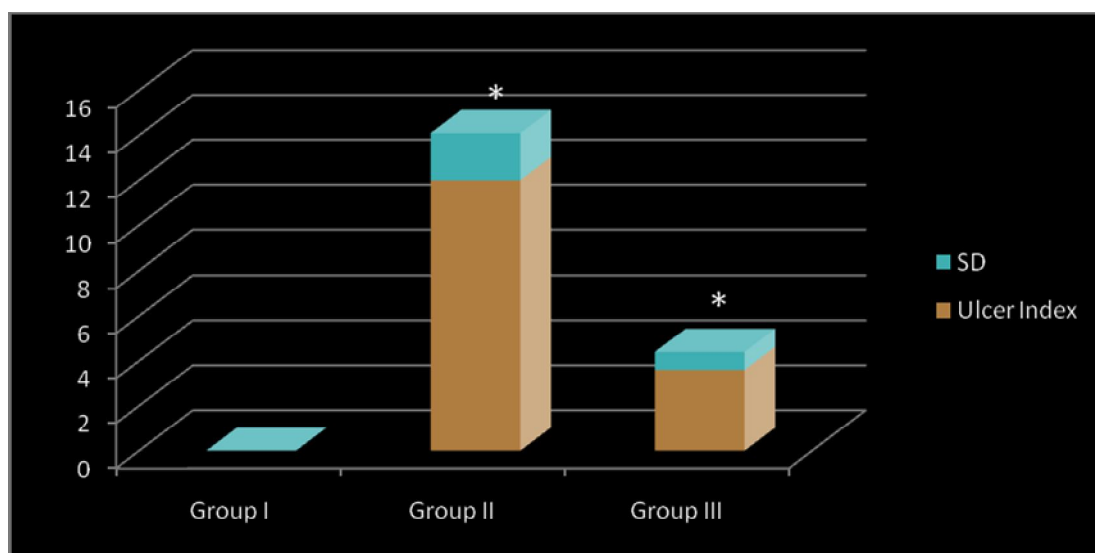


Figure (1): Ulcer index of all groups.

Histopathology of the stomachs

On 7 th day of indomethacin administration, treated rats in the pilot study showed sharply defined mucosal ulcer in stomach. Damaged mucosal epithelium, glands, inflammatory exudates, proliferated fibroblast and cellular debris were found in the ulcerated wall of stomach (Fig. 2b). No sign of healing was seen.

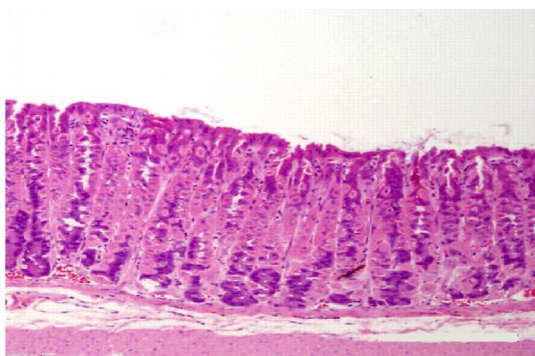


Figure (2a): Gastric mucosa of control group (I).

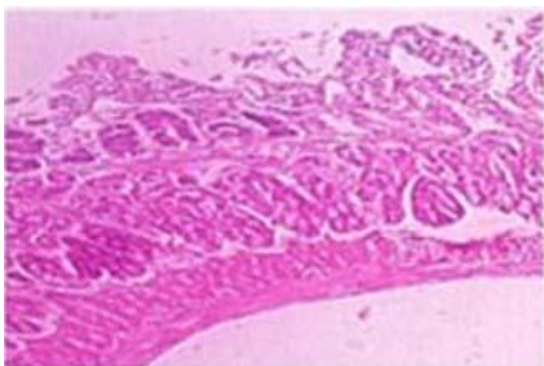


Figure (2c): Gastric mucosa on 17 th day of indomethacin administration in group II.

On 17th day of the study, group II rats showed reduced inflammatory exudates along with some extent of mucosal regeneration, glandular organization and reduced size of ulcer (Fig. 2c). Group III, showed minimal inflammatory exudates and proper organization of glands (Fig.2d).

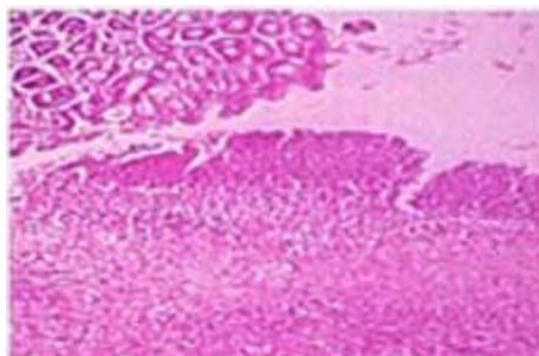


Figure (2b): Gastric mucosa On 7 th day of indomethacin administration.

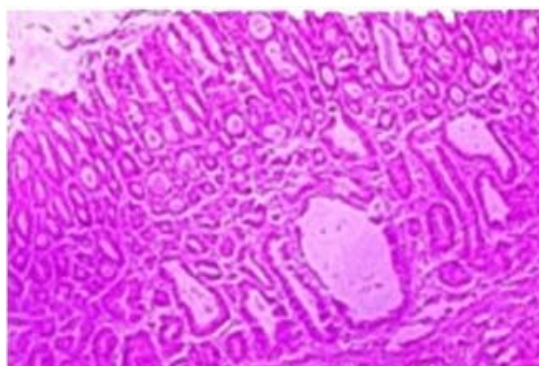


Figure (2d): Gastric mucosa On 17 th day of indomethacin administration in group III.

Figure 2: Histopathological examination of the stomach mucosa.

DISCUSSION

The diversity of etiological factors underlying gastric ulcers and the complex nature of pathways participating in healing always make peptic ulcers treatment a complicated challenge (El-Moselhy et al., 2009).

The current study highlighted the alleviating effect of Nesfatin-1 on indomethacin- induced gastric ulcer as it significantly improved all the deleterious effects induced by indomethacin on both gastric mucosa and gastric juice contents. This effect was associated with down-

regulation of inflammatory and oxidative stress markers together with increased in gastric mucosal levels of both PGE2 and nitric oxide. **Szlachcic et al. (2013)**, found that peripheral and central administration of Nesfatin-1 inhibited stress induced increase in gastric acid and pepsin secretion in rats which is in keeping with the observations by **Xia et al. (2012)** who observed the inhibition of gastric secretion after a central administration of Nesfatin-1 that involved the vagal mechanism.

In this regard, it is worthy to mention that peripheral Nesfatin-1 administrated by intravenous injection has been shown to be able to cross the blood-brain-barrier by a non-saturable mechanism (**Pan et al., 2007** and **Price et al., 2007**).

The result of the present work showed significant elevation in gastric MDA level in group II, an indicator for lipid peroxidation which is a well established mechanism for cellular injury (**Kwiecien et al., 2002**). Nesfatin-1 treatment caused significant reduction in MDA level as compared to those of group II. It was reported that this peptide possesses free radicals scavenger activity (**Kolgazi et al., 2014**). This suggests that nesfatin-1 accelerated ulcer healing via antioxidant activity.

The result of the current study showed significant elevations in gastric TNF-alpha in indomethacin treated group as compared to control group. This observation is in accordance with previous studies (**Zhang et al., 2008** and **Moustafa et al., 2013**). Nesfatin-1 administration produced a significant reduction of TNF-alpha in the gastric mucosa, adding also anti-inflammatory role to its beneficial effects. This is in accordance with the

results of other investigators (**Szlachcic et al., 2013** , **Kolgazi et al., 2014** and **Ozturk et al., 2015**).

Nitric oxide (NO) plays a crucial role in the gastroprotection and ulcer healing mechanisms (**Laine et al., 2008**). The result of the present work showed marked reduction in mucosal nitrite level (as indicator of NO) in indomethacin- treated group. This is attributed to the ability of indomethacin to upregulate the endothelin-1 leading to decrease production of gastric mucosal NO (**Slomiany and Slomiany, 2000**). Nesfatin-1 was able to increase the nitrite levels in this ulcer model in group III.

In the present study, rats treated with nesfatin-1 showed a significant increase in PGE2 level in gastric mucosa. PGE2 influences virtually every component of the mucosal defense; stimulates mucus, bicarbonate; maintains mucosal blood flow; enhances the resistance of the epithelial cells to injury induced by cytokines (**Brzozowski et al., 2005**). In addition, our results showed that , oral administration of indomethacin resulted in a significant reduction in gastric mucosal PGE2 level, which may be through inhibition of cyclooxygenase (**Bandyopadhyay et al., 1999**) .

NO was reported to increase PGE2 biosynthesis in vivo through CGMP dependent mechanism (**Abi-Gerges et al., 2001**) and it is possible to assume that NO might regulate the release and or the biosynthesis of PGE2 in the stomach after damage during ulcer healing. Gastroprotective effects of Nesfatin-1 may involve endogenous PG and NO production. Nesfatin-1 exerts hyperemic effect on the gastric mucosa and that the selective or

non-selective cyclooxygenase (COX) blockers reduced this effect (Szlachcic et al., 2013).

CONCLUSION

Nesfatin-1 attenuated indomethacin-induced gastric ulcer and potentiated ulcer healing in the stomach of rats exposed to chronic administration of indomethacin, and this effect depended upon decrease in gastric secretion, increase in nitric oxide and prostaglandin E2, besides an antioxidant anti-inflammatory role.

ACKNOWLEDGMENT

The authors like to acknowledge and appreciate the effort of Prof. Dr. Ola A. Megahed; Professor of Pathology, Faculty of Medicine, Zagazig University, for performing the ulcer index and histopathological studies.

REFERENCES

1. Abi-Gerges N, Fischmeister R and Me'ry PF. (2001) : G protein-mediated inhibitory effect of a nitric oxide donor on the L-type Ca² current in rat ventricular myocytes. *J Physiol.*, 531(Pt 1):117-130.
2. Alumets, J, Ekelund M, Hakanson R, Hedenbro J, Rehfeld JF, Sundler F and Vallgren S. (1982): Gastric acid response to pylorus ligation in rats: is gastrin or histamine involved? *J. Physiol.*, 323: 145-156.
3. Angelone T, Filice E, Pasqua T, Amodio N, Galluccio M, Montesanti G, Quintieri AM and Cerra MC. (2013): Nesfatin-1 as a novel cardiac peptide: identification, functional characterization, and protection against ischemia/reperfusion injury. *Cell Mol Life Sci.*, 70(3):495-509.
4. Bandyopadhyay U, Das D, Bandyopadhyay D, Bhattacharjee M and Benerjee RK. (1999): Role of reactive oxygen species in mercaptomethylimidazole- induced gastric acid secretion and stress-induced gastric ulceration. *Curr. Sci.*, 76 : 55-63.
5. Brzozowski T, Konturek PC, Konturek SJ, Brzozowska I and Pawlik T. (2005): Role of prostaglandins in gastroprotection and gastric adaptation. *J Physiol Pharmacol.*, 56(Suppl 5): 33-55.
6. Darambazar G, Nakata M, Okada T, Wang L, Li E, Shinozaki A, Motoshima M, Mori M and Yada T. (2015): Paraventricular NUCB2/nesfatin-1 is directly targeted by leptin and mediates its anorexigenic effect. *Biochem Biophys Res Commun.*, 4;456(4):913-8.
7. El-Moselhy MA, Abdel-Hamid NM and Abdel-Raheim SR. (2009): Gastroprotective Effect of Nicorandil in Indomethacin and Alcohol-Induced Acute Ulcers. *Appl. Biochem. Biotechnol.*, 152 (3) : 449-459.
8. Foo KS, Brauner H, Ostenson CG and Broberger C. (2010):Nucleobindin- 2/nesfatin in the endocrine pancreas: distribution and relationship to glycaemic state. *J Endocrinol.*, 204: 255-263.
9. Garc'a -Galiano D, Navarro VM, Gaytan F and Tena-Sempere M. (2010): Expanding roles of NUCB2/nesfatin-1 in euroendocrine regulation. *J. Mol. Endocrinology*, 45: 281-290.
10. Granstrom E, Hamberg M and Hansson G. (1980): Chemical instability of 15-keto-13, 14-dihydro-PGE₂: the reason for low assay reliability. *Prostaglandins*, 19:933-945.
11. Hara N , Hara Y, Natsume Y and Goto Y. (1991):Gastric hyperacidity and mucosal damage caused by hypothermia correlate with increase in GABA concentrations of the rat brain . *Eur. J. Pharmacol.*, 194 (1): 77-81.
12. He KL and Ting AT. (2002): A20 inhibits tumor necrosis factor (TNF) alpha-induced apoptosis by disrupting recruitment of TRADD and RIP to TNF receptor 1 complex in Jurkat T cells. *Mol. Cell. Biol.*, 22(17):6034-45.
13. Khazaei M and Salehi H. (2006): Protective effect of falcaria vulgaris extract on ethanol induced gastric ulcer in rat. *Iran. J. Pharmacol .Therap.*, 5(1) ; 43-46.
14. Kohno D, Nakata M, Maejima Y, Shimizu H, Sedbazar U and Yoshida N. (2008): Nesfatin-1

- neurons in paraventricular and supraoptic nuclei of the rat hypothalamus coexpress oxytocin and vasopressin and are activated by refeeding. *Endocrinology*, 149:1295-301.
15. Kolgazi M, Cantali-Ozturk C, Deniz R, Ozdemir-Kumral ZN, Yuksel M, Sirvanci S and Yeğen BC.(2014):Nesfatin-1 alleviates gastric damage via direct antioxidant mechanisms. *J Surg Res.*; doi: 10.1016/j.jss.2014.06.057. [Epub ahead of print].
 16. Kwiecien S, Brzozowski T and Konturek J.(2002): Effects of reactive oxygen species action on gastric mucosa in various models of mucosal injury. *J. Physiol. Pharmacol.*, 53(1) ; 39-50.
 17. Laine L, Takeuchi K and Tarnawski A. (2008): Gastric mucosal defense and cytoprotection: bench to bedside. *Gastroenterology*, 135: 41-60.
 18. Lima ZP , Severi JA , Pellizzon CH , Brito AR , Solis PN , Ca'ceres A, Giro'n LM, Vilegas W and Hiruma-Lima CA. (2006): Can the aqueous decoction of mango flowers be used as antiulcer agent ? *J. of Ethnopharmacology*, 106(1):29-37.
 19. Maejima Y, Sedbazar U, Suyama S, Kohno D, Onaka T, Takano E, Yoshida N, Koike M, Uchiyama Y, Fujiwara K, Yashiro T, Horvath TL, Dietrich MO, Tanaka S, Dezaki K, Oh-I S, Hashimoto K, Shimizu H, Nakata M, Mori M and Yada T. (2009): Nesfatin-1-regulated oxytocinergic signaling in the paraventricular nucleus causes anorexia through a leptin-independent melanocortin pathway. *Cell Metab.*, 10: 355-365.
 20. Moustafa YM, Khoder DM, El-Awady EE and Zaitone SA. (2013) : Sildenafil citrate protects against gastric mucosal damage induced by indomethacin in rats. *Eur Rev Med Pharmacol Sci.*, 17(2):179-88.
 21. Niehaus WG and Samuelsson B. (1968): Formation of malondialdehyde from phospholipid arachidonate during microsomal lipid peroxidation. *Eur J Biochem.*, 6:126–130.
 22. Ogihara Y and Okabe S. (1993): Effect and mechanism of Sucralfate on healing of acetic acid induced gastric ulcers in rats. *J Physiol Pharmacol.* ,44:109-18.
 23. Oh-I S, Shimizu H, Satoh T, Okada S, Adachi S, Inoue K, Eguchi H, Yamamoto M., Imaki T, Hashimoto K, Tsuchiya T, Monden T, Horiguchi K, Yamada M and Mori M. (2006): Identification of nesfatin-1 as a satiety molecule in the hypothalamus. *Nature*, 443(7112):709–712.
 24. Ozsavci D, Ersahin M., Sener A, Ozakpinar OB, Toklu HZ, Akakin D, Sener G and Yegen BC. (2011): The novel function of nesfatin-1 as an anti-inflammatory and antiapoptotic peptide in subarachnoid Hemorrhage induced oxidative brain damage in rats. *Neur. Surg.*, 68: 1699–1708.
 25. Ozturk C C , Oktay S, Yuksel M, Akakin D, Yarat A and Kasimay Cakir O. (2015): Anti-inflammatory effects of nesfatin-1 in rats with acetic acid - induced colitis and underlying mechanisms. *J. Physiol. Pharmacol.*, 66 (5): 741-750.
 26. Pan W, Hsuchou H and Kastin AJ. (2007): Nesfatin-1 crosses the blood-brain barrier without saturation. *Peptides*, 28: 2223–2228.
 27. Price TO, Samson WK, Niehoff ML and Banks WA. (2007): Permeability of the blood-brain barrier to a novel satiety molecule nesfatin-1. *Peptides*, 28:2372–2381.
 28. Ribeiro-Rama AC, Figueiredo IV, Veiga F, Castel-Branco MM, Cabrita AM and Caramona MM. (2009): Evaluation of gastric toxicity of indomethacin acid , salt form and complexed forms with hydroxypropyl-beta-cyclodextrin on wister rats : histopathologic analoges. *Fundam Clin. Pharmacol.*, 23(6), 747-55.
 29. Sanyal AR, Denath OK, Bhattacharya SK and Gode KD.(1971): The effect of cyproheptadine on gastric acidity. In: Pfeiffer,C.J.(Ed.)*Peptic ulcer*. Pbl.Scandinavian University Books, Munksgoard, pp312-318.
 30. Sastry KV, Moudgal RP, Mohan G, Tyagi JS and Rao GS.(2002): Spectrophotometric determination of serum nitrite and nitrate by copper-cadium alloy.*Anal. Biochem.* 306(1):79-82.
 31. Slomiany BL and Slomiany A. (2000): Role of endothelin-converting enzyme-1 in the suppression of constitutive nitric oxide synthase in rat gastric mucosal injury by

- indomethacin. *Scand J Gastroenterol.*, 35(11): 1131-6.
32. Stengel A, Goebel M, Yakubov I, Wang L, Witcher D, Coskun T, Tache' Y, Sachs G and Lambrecht NW. (2009): Identification and characterization of nesfatin-1 immunoreactivity in endocrine cell types of the rat gastric oxyntic mucosa. *Endocrinology*, 150(1): 232-238.
33. Stengel A, Hofmann T and Goebel-Stengel M. (2013): Ghrelin and NUCB2/nesfatin-1 are expressed in the same gastric cell and differentially correlated with body mass index in obese subjects. *Histochem Cell Biol.*, 139: 909-918.
34. Szabo S and Hollander D (1985): Pathways of gastrointestinal protection and repair: mechanisms of action of sucralfate. *Am J Med.*, 86 (6A): 23-31.
35. Szlachcic A, Sliwowski Z, Krzysiek-Maczka G, Surmiak M J, Pajdo R, Drozdowicz D, Konturek SJ and Brzozowski J. (2013): New satiety hormone nesfatin-1 protects gastric mucosa against stress-induced injury: Mechanistic roles of prostaglandins, nitric oxide, sensory nerves and vanilloid receptors. *Peptides*, 49 (2013) 9-20 .
36. Tang CH, Fu XJ B, Xu XL, Wei XJ and Pan HS. (2012): The anti-inflammatory and anti-apoptotic effects of nesfatin-1 in the traumatic rat brain. *Peptides*, 36:39-45.
37. Tariq M , Khan HA , Elfaki I, Arshaduddin M, Al Moutaery M , Al Rayes H and Al Swailam R. (2007): Gastric antisecretory. antiulcer effects of simvastatin in rats. *J. Gastroenterology and Hepatology*, 22(12): 2316-2323.
38. Watanabe AI, Mochiki E, Kimura A, Kogure N, Yanai M, Ogawa A, Toyomasu Y, Ogata K, Ohno T, Suzuki H and Kuwano H. (2015): Nesfatin-1 Suppresses Gastric Contractions and Inhibits Interdigestive Migrating Contractions in Conscious Dogs. *Dig Dis Sci.*, [Epub ahead of print].
39. Winzler RJ. (1955): Determination of serum glycoproteins. In: Glick, D.P. (Ed), *Methods of Biochemical Analysis*. Pbl. Interscience Publishers Inc., New Work, pp, 279-311.
40. Xia Z F, M. Fritze D, Li JY, Chai B, Zhang C, Zhang W and Mulholland M. (2012): Nesfatin-1 inhibits gastric acid secretion via a central vagal mechanism in rats. *American Journal of Physiology*, 303(5): G570-G577.
41. Zhang AQ, Li XL, Jiang CY, Lin L, Shi RH, Chen JD and Oomura Y.(2010): Expression of nesfatin-1/NUCB2 in rodent digestive system. *World J Gastroenterol.*, 16: 1735-1741.
42. Zhang X, Tajima K, Kageyama K and Kyoi T. (2008): Irsogladine maleate suppresses indomethacin-induced elevation of proinflammatory cytokines and gastric injury in rats. *World J Gastroenterol.*, 14;14(30):4784-90.

1

داليا إبراهيم عبد العليم إبراهيم - داليا محمد عبد المطلب

قسمي الفسيولوجيا والفارماكولوجيا-كلية الطب - جامعة الزقازيق

خلفيه البحث: الإندوميثاسين هو عقار مضاد للالتهابات غير الستيرويدية، والذي يعرف بآثاره الجانبية الخطيرة مثل التسبب في تقرح المعدة. نسفاتين 1 هو أحد الببتيدات مفقدة الشهية التي تم إكتشافها حديثاً، وقد أظهرت بعض الدراسات مؤخرًا أن له تأثيرات مضادة للأكسدة.

الهدف من البحث: تهدف هذه الدراسة إلى معرفة مدى التأثير الممكن للنسفاتين 1 على تخفيف قروح المعدة الناجمة عن الإندوميثاسين في الجرذان مع إستكشاف الآليات الممكنة الكامنة وراء هذا التأثير .

مواد و طرق البحث: أجريت هذه الدراسة على أربع و عشرين ذكرا من الجرذان البيضاء البالغة حيث تم تقسيمها إلى ثلاث مجموعات متساوية: المجموعة الضابطة و المجموعة المعالجة بالإندوميثاسين (20 مجم/كجم) يوميا عن طريق الفم لمدة سبعة أيام و المجموعة المعالجة بالإندوميثاسين لمدة سبعة أيام يليه نسفاتين 1- (ميكروجرام / كجم) عن طريق البريتون يوميا لمدة عشر أيام.

وفى كل هذه المجموعات تم تقييم المعلمات الخاصة بالعصارة المعدية (إجمالى إنتاج حامض المعدة، ونشاط البيبسين ومحتوى الميوسين)، ومستويات المالون داي الدهيد وعامل نخر الورم -ألفا، وكذلك مستويات النيتريت و البروستاجلاندين E2 فى غشاء المعدة بالإضافة إلى حساب مؤشر التقرح و الفحص النسيجي لغشاء المعدة فى كل المجموعات فى نهاية مدة الدراسة. النتائج: المعالجة بالنسفاتين 1 أدت إلى إنخفاض ذى دلالة إحصائية فى إنتاج حامض المعدة ونشاط البيبسين مع إرتفاع ذى دلالة إحصائية فى الميوسين المحتوى فى عصارة المعدة. كما أن النسفاتين-1 أدى إلى خفض ذى دلالة إحصائية فى مستويات المالون داي الدهيد وعامل نخر الورم -ألفا فى الغشاء المخاطي للمعدة حيث صاحب ذلك إرتفاع ذو دلالة إحصائية فى مستويات النيتريت و البروستاجلاندين E2 . أما الفحص النسيجي لغشاء المعدة فقد أكد هذه التأثيرات الإيجابية لهذا البيبتيد حيث وجد تحسن ملحوظ فى حالة الأنسجة مقارنة بالمجموعة الغير معالجة مع إنخفاض ذى دلالة إحصائية فى مؤشر التقرح.

الإستنتاج : نسفاتين 1 يساعد على تخفيف وإلتئام قروح المعدة الناجمة عن الإندوميثاسين فى الجرذان، وهذا التأثير يعتمد على خفض إفراز حامض المعدة، وزيادة فى مادة أكسيد النيتريك و البروستاجلاندين E2 ، إلى جانب الدور المضاد للالتهابات والأكسدة لهذا البيبتيد.