

RENOPROTECTIVE EFFECTS OF THYMOQUINONE AGAINST CISPLATIN-INDUCED NEPHROTOXICITY IN RATS

By

Mohamed Hassan Abdelsattar

Department of Medical Physiology, Faculty of Medicine, Al-Azhar University, Cairo

ABSTRACT

Background: Cisplatin (CIS) is one of the most effective chemotherapeutic agents and is used to treat various types of tumors. However its optimal clinical benefit is limited by its serious nephrotoxicity. **Objective:** Investigating the possible effects of thymoquinone (TQ), a compound derived from *Nigella sativa* with strong anti-oxidant properties, against CIS-induced nephrotoxicity. **Materials and Methods:** Forty adult male albino rats were divided into four equal groups: Rats in the first group were injected daily with normal saline, rats in the second group received TQ, rats in the third group were injected with CIS on the sixth day of experiment, whereas rats in the fourth group received TQ in drinking water for 11 consecutive days in addition to CIS injection (7.5 mg/kg, i.p.) on the sixth day of experiment. The animal were sacrificed at day 12 and following parameters were evaluated: (i) the levels of serum creatinine (Cr) and the blood urea nitrogen (BUN) as biomarkers of renal function, (ii) the renal content of thiobarbituric acid reactive substances (TBARS) as an index of lipid peroxidation and oxidative stress, (iii) total glutathione (GSH) content and glutathione S-transferase (GST) activity in renal tissues as indices of antioxidant mechanisms, and (iv) the histopathological hallmarks of kidney specimens. **Results:** CIS administration induced nephrotoxicity associated with significant higher in the levels of serum Cr, BUN, and renal TBARS and significant reductions in the renal GSH and GST. The histopathological findings supported the presence of seriously injured kidney. However, administration of TQ efficiently reduced the development of CIS nephrotoxicity and its associated biochemical and histopathological features. **Conclusion:** TQ mediates via, at least in part its antioxidant property, a marked renoprotective effect against CIS-induced nephrotoxicity.

Key words: Thymoquinone, Nephrotoxicity, Oxidative stress, Cisplatin, Antioxidant.

INTRODUCTION

Cisplatin (CIS) represents a class of antineoplastic drugs containing a heavy metal, platinum. It is effective against several human tumors, e.g. testis, ovary, head, neck and lung (**Katzung, 2004**). Therapeutic effects of CIS are associated with severe side effects, mainly nephrotoxicity and neurotoxicity that limit its clinical use (**Yao et al., 2007**). Original pathway of CIS transport in renal cells is

active transport, although CIS enters the cells through passive diffusion as well. The organic cation transporter 2 (OCT2) is the major transporter for CIS uptake in proximal tubular cells (**Ciarimboli, 2014**).

The exact underlying pathogenic principals of CIS-induced nephrotoxicity still obscure. However, the generation of free oxygen radicals in tubular cells and activates the mitogen-activated protein kinase (MAPK) (**Arany et al., 2004**) have been proposed as an important pathogenic

process (Sung et al., 2008). Various data indicate that CIS induces oxidative stress (Chirino and Pedraza-Chaverri, 2009), lipid peroxides (Noori and Mahboob, 2010) and DNA damage (Basu and Krishnamurthy, 2010). In the presence of CIS, reactive oxygen species (ROS) are generated in cells via the xanthine-xanthine oxidase system, mitochondria, and NADPH oxidase (Kawai et al., 2006). Several antioxidants such as diethyldithiocarbamate (Li et al., 2002), carvedilol (Gamal El-Din and Al-Bekairi, 2006) and lipoic acid (Almaghrabi, 2015) have been tested for their ability to protect against CIS-induced nephrotoxicity in experimental animals. None of these compounds has proved to be clinically efficient as complete protection in patients.

The seeds of *Nigella sativa* Linn, commonly known as black cumin and black seed, are used in folk (herbal) medicine all over the world for the treatment and prevention of a number of diseases and conditions (Hosseinian et al., 2015). Both volatile and fixed oils were isolated and extracted from the black *Nigella sativa* seeds (Al-Naghib et al., 2009). According to the common practices of "evidence-based herbal medicine", thymoquinone (TQ) is the main bioactive constituent of the *Nigella sativa* volatile oil (Khan et al., 2014).

The multiple pivotal antioxidant properties of TQ against oxidative damages induced by a variety of oxidative stress and free radical-generating agents have been strongly confirmed (Ashraf et al., 2011). In addition, the remarkable anti-inflammatory (Majdalawieh and Fayyad, 2015), immunotherapeutic

(Kapan et al., 2012), antidiabetic (Alimohammadi et al., 2013), antihypertensive (Fallah et al., 2013), anti-proliferative and anti-cancer potentialities (Khan et al., 2011) of TQ have been revealed. However, its renoprotective effects, particularly against chemicals and drugs-induced oxidative stress and nephrotoxicity, are not well covered.

The present work was a trial to investigate the TQ effects against the CIS-induced nephrotoxicity.

MATERIALS AND METHODS

Chemicals: Thymoquinone (2-isopropyl-5-methyl-1,4-benzoquinone) was purchased from Sigma Chemical (St Louis, MO, USA) and freshly dissolved in physiologic saline (1 mg/1 ml) on the same day of its use (Kanter et al., 2005 and Khattab and Nagi, 2007). Cisplatin (Cis-dichlorodiamine-platinum II) was purchased from Mayne Pharmaceuticals (Warwickshire, UK). The documented dose of cisplatin that induced nephrotoxicity in rats was 7.5 mg/kg BW (Yilmaz et al., 2004).

Animals and experimental design: Forty adult male albino rats, weighing 160-180 g were used in this study. The rats were housed in metabolic cages (20 x 32 x 20 cm for every 5 rats) and had free access to tap water and rat chow. The animals were randomly divided into four equal groups: The first group (control group) received normal saline (i.p.) for 11 consecutive days, the second group (TQ group) received oral TQ (5 mg/ kg/ day) via gastric gavage for 11 consecutive days, the third group (CIS group) received normal saline (i. p.) for 11 consecutive days and CIS (7.5 mg/kg, i.p.) on the sixth

day of experiment (Mansour et al., 2002). The fourth group (TQ+CIS group) received TQ in drinking water for 11 consecutive days in addition to CIS injection (7.5 mg/kg, i.p.) as a single dose on the sixth day of experiment.

Sacrificing and sampling: On the 12th day of the experiment, blood samples were withdrawn from the retro-orbital plexus by heparinized capillary tubes, and allowed to clot and retract at room temperature for 1 h before centrifugation twice at 10,000 x g for 10 minutes. Supernatants (i.e., serum samples) were collected and immediately stored at -20 °C until used. Rats were sacrificed and both kidneys were excised quickly and rinsed with a PBS (phosphate buffered saline) solution, pH 7.4, to remove any blood cells and clots. The right kidney was used for histopathological analysis while the left one was cut into small pieces, homogenized into 5 volume of ice-cold Tris HCl buffer (50 mM, pH 7.4), and centrifuged at 10,000 x g for 10 min. The volume of supernatant was collected and stored at -20 °C until used.

Biochemical analysis of kidney function: The levels of serum creatinine (Cr) and blood urea nitrogen (BUN) were spectrophotometrically measured at absorbance of 520 nm (Fabiny and Ertingshausen, 1971) and 642 nm (Tobacco et al., 1979) respectively.

Assessment of antioxidant defense states: The level of total glutathione (GSH) was determined according to the method described by Baillie & Slatter (1991) and the activity of its related enzyme; glutathione-S-transferase (GST) was determined according to the methods described by Habig & Jakoby (1974).

Determination of lipid peroxidation and oxidative stress in kidney tissues: The concentrations of thiobarbituric acid reactive substances (TBARS) in the supernatants of renal tissues homogenates were measured spectrophotometer at 532 nm as described by Ohkawa et al (1979).

Histopathological assessment of renal damage: Paraffin sections, at 4 µm thickness, were prepared from each kidney, stained with hematoxylin and eosin (H&E) and, then, microscopically examined.

Statistical Analysis: Data input and analysis were done using SPSS version 16 computer program. All results were expressed as the means ± SD. Statistical comparisons between different groups were done using one-way analysis of variance (ANOVA) followed by the Tukey–Kramer multiple comparison test, to judge the difference between various groups. Significance was considered at P<0.05.

RESULTS

Effects of thymoquinone on cisplatin-induced renal damage in rats: In comparison with values of normal controls, i.p. injections of CIS into rats resulted in marked impairment of their renal functions, as reflected by significant increases in the levels of their serum Cr (from 0.69±0.9 mg/dl to 3.19 mg/dl) and BUN (from 20.92 mg/dl to 98.0± 15.31 mg/dl). On the other hand, pre-treatment of the rats with TQ (5 mg/kg/day) 5 days before and after single injection of CIS produced an efficient protecting effect on their renal functions, whereas the levels of serum Cr and BUN were almost reserved to the control values (Tab. 1).

Effects of thymoquinone on cisplatin-induced depletion of renal antioxidant defence mechanism: CIS produced significant decrease in the level of GSH and the activity of GST in rat renal tissues. The concentration of GSH significantly lowered from 5.91 ± 0.34 μ mol/g wet kidney tissue to 1.74 ± 0.29 μ mol/g wet kidney tissue and the activity of GST lowered from 2.89 ± 0.33 nmol/min/g wet kidney tissue to 0.64 ± 0.27 nmol/min/g wet kidney tissue. However, pretreatment with TQ before and after single injection of CIS obviously counteracted and reversed these depleting effects of CIS on renal GSH and GST. Moreover, when TQ was administered alone into normal rats, it significantly elevated the levels of the GSH content and GST activity in their renal tissues by 129% and 133%, respectively (Figs. 1 & 2).

Effects of thymoquinone on cisplatin-induced lipid peroxidation and oxidative stress in renal tissues: The levels of TBARS in control rats were 487.00 ± 26.00 nmol/g wet kidney tissues. However, injection of CIS into normal rats resulted in significant increase in the concentrations of TBARS to 1019.00 ± 103.00 nmol/g wet kidney tissues at day

12. On the other hand, pretreatment of the rats with TQ (5 mg/kg/day) before and after single injection of CIS produced significant decrease on renal TBARS. Oral administration of TQ into normal rats caused an insignificant lowering of TBARS in the renal tissues.

Histopathological observations: The histo-pathological finding of kidney tissues supported the aforementioned biochemical data and confirmed the remarkable renoprotective effects of TQ against CIS-induced nephrotoxicity. Control or TQ-treated rats revealed normal morphology of renal tubules and glomeruli (fig. 4 A&B). Kidney sections of rats receiving CIS showed clear histopathological hallmarks of severely induced glomerular and tubular degenerative changes and necrosis, interstitial nephritis, sloughing of the tubular epithelial cells and marked intraluminal blood stagnation (fig. 4C). Administration of TQ before and after single injection of to CIS revealed almost a complete preservation of almost normal histomorphology of renal glomeruli and tubules (fig. 4D).

Table (1): The effect of TQ on CIS-induced changes in rat serum Cr and BUN (Mean \pm SD).

Parameters	Creatinine (mg/dl)	Blood Urea Nitrogen (mg/dl)
Control	0.69 ± 0.9	20.92 ± 1.71
TQ	0.86 ± 0.14	19.12 ± 1.96
CIS	3.19 ± 0.48^a	98.0 ± 15.31^a
TQ + CIS	0.66 ± 0.03^b	25.43 ± 1.27^b

^a, Significantly different from control group. ^b, Significantly different from CIS group (P < 0.05).

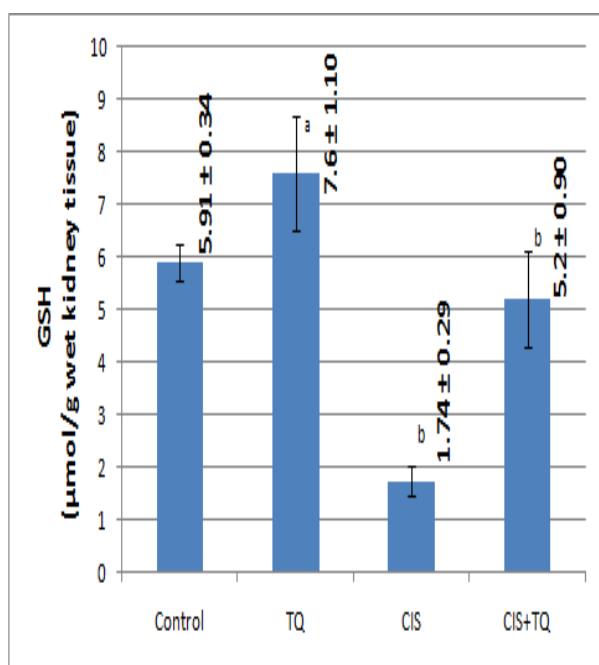


Figure (1): Effects of TQ on the levels of total glutathione (GSH) in CIS-administered rats. Data are presented as the mean \pm SD. ^a, Significantly different from control group. ^b, Significantly different from CIS group ($P < 0.05$).

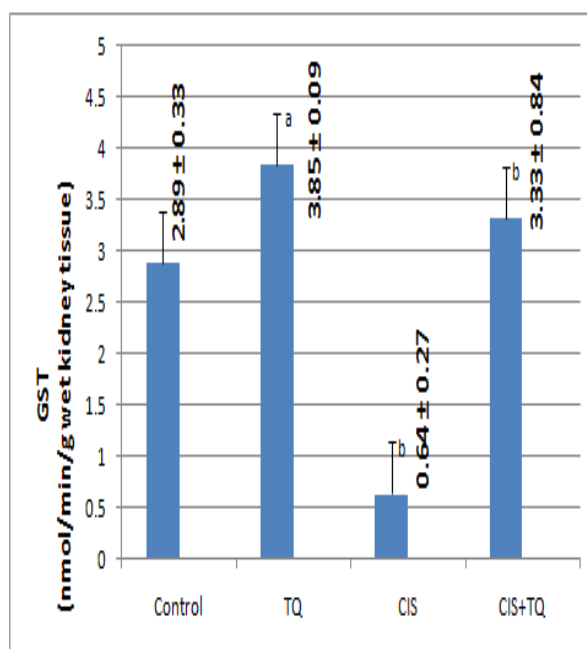


Figure (2): Effects of TQ on the activity of glutathione S-transferase (GST) in CIS-administered rats. Data are presented as the mean \pm SD. ^a, Significantly different from control group. ^b, Significantly different from CIS group ($P < 0.05$).

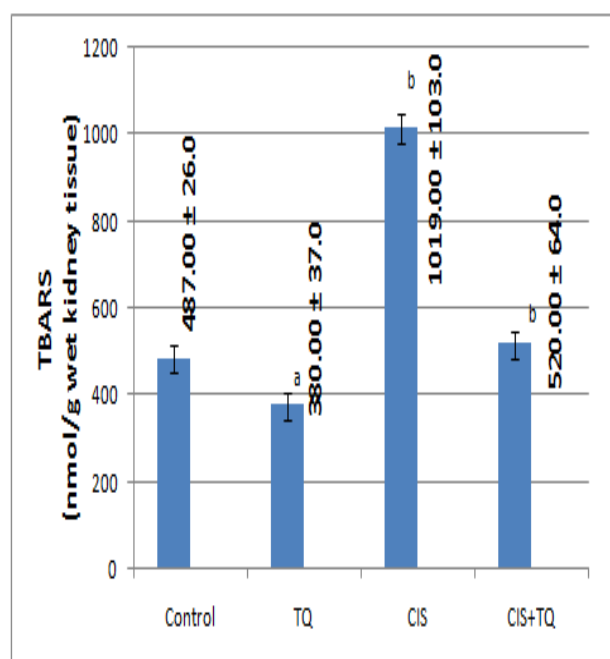


Figure (3): Effects of TQ on the levels of thiobarbituric Acid Reactive Substances (TBARS) in CIS-administered rats. Data are presented as the mean \pm SD. ^a, Significantly different from control group. ^b, Significantly different from CIS group ($P < 0.05$).

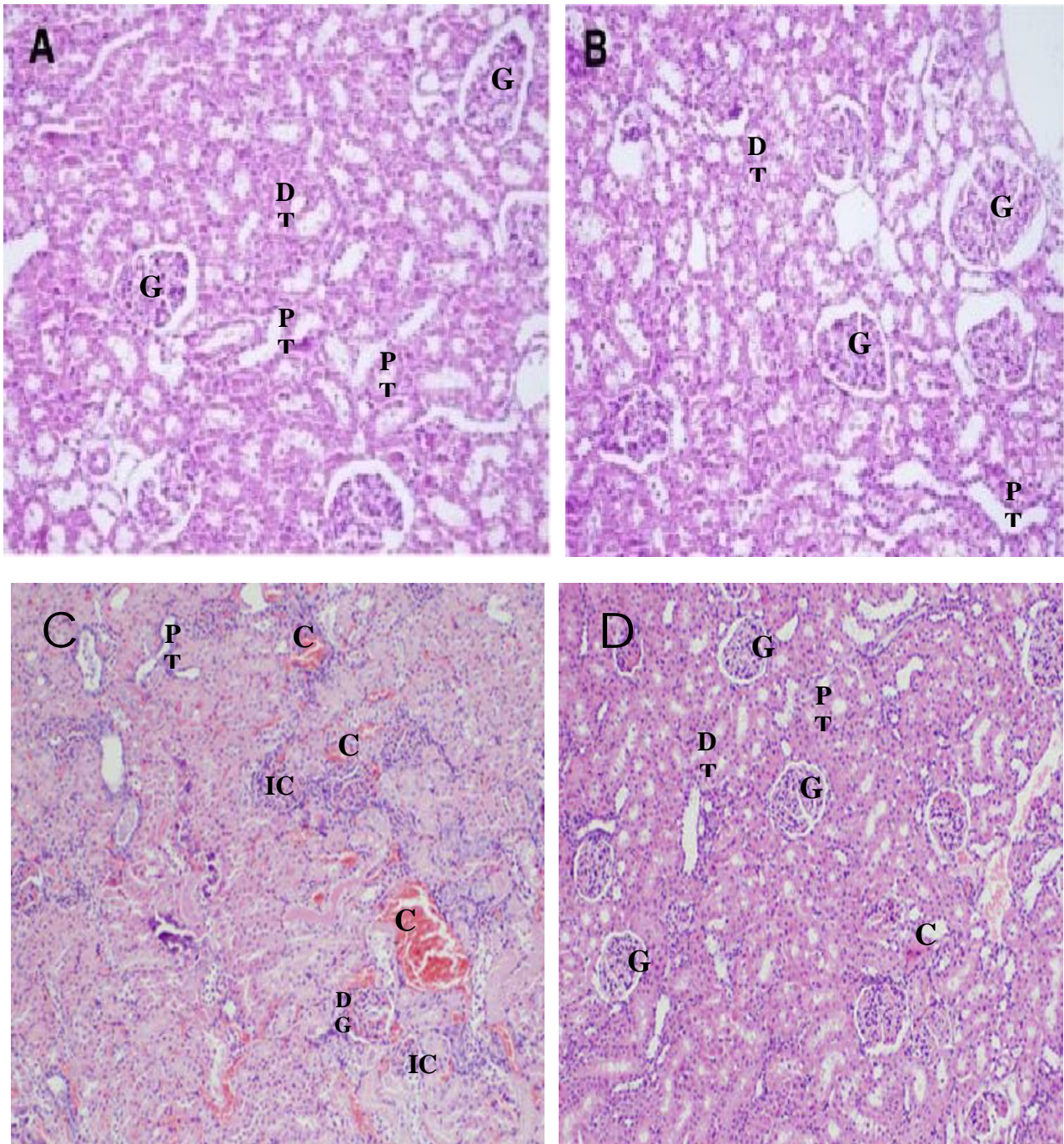


Figure (4): Light photomicrographs of the rats' kidney sections (H&E X200). **A:** section from control kidneys showed normal histology with no evidence of pathological change. **B:** section from TQ-treated kidneys. **C:** section from CIS-treated kidneys. The pathological changes included clear hallmarks of severely induced necrotic glomeruli and tubular necrosis, inflammatory cells infiltration and marked congested blood vessels. **D** section from (TQ+CIS)-treated kidneys. Administration of TQ resulted in remarkable improvement in the histological appearance and reduction in glomerular and tubule cell damage, glomeruli (G) and renal tubules (T), degenerated glomeruli, inflammatory cells (IC), proximal tubules (PT), distal tubules (DT), congestion (C).

DISCUSSION

Nephrotoxicity induced by cisplatin as an important antineoplastic drug is one of the prominent causes of acute renal injury (Ozkok and Edelstein, 2014). CIS induces apoptosis or necrosis in the kidney cells by reduction in ATPase activity, mitochondrial damage and induction of cell cycle arrest and also disruption of renal tubular cell transport systems (Yousef and Hussien, 2015). CIS generates oxidative and nitrosative stresses because of depletion or inhibition of antioxidant enzymes and proteins which result into nephrotoxicity (Peres and J?nior, 2013). In addition, inflammation and fibrogenesis which are mainly induced via TNF- α production have an important role in pathogenesis of CIS-induced nephrotoxicity (Miller et al., 2010). In this regard, it has been suggested that using of agents with powerful antioxidant properties can interfere with the development of CIS-associated nephro-toxicity and acute renal failure (ARF) (Peres and J?nior, 2013). Accordingly, the present study was designed to investigate the possible renoprotective effects of TQ, a compound derived from the volatile oil of the *Nigella sativa* seeds with well-evidenced antioxidant properties, on rat model of CIS-induced nephrotoxicity.

In this work, i.p. injection of CIS into rats (7.5 mg/kg) resulted in development of destructive renal injury that was associated with significant higher in the levels of serum Cr and BUN. In addition, the findings of histopathological examinations confirmed the biochemical data and showed the clear signs of severe nephrotoxicity in the form of massive

glomerular and tubular degenerative changes and necrosis, tubulointerstitial nephritis and dilation of the tubular lumen with intraluminal blood stagnation, These results were in accordance with previous reports of Arunkumar et al. (2012) and Shalaby et al. (2014) in human patients, and Prabhu et al. (2013) and Abdel Moneim et al. (2014) in experimental animals. On the other hand, when TQ (5 mg/kg/day; orally) was administered for 5 consecutive days before and continued for another 5 consecutive days after single dose of CIS (7.5 mg/kg i.p.) rendered rats less susceptible to kidney damage induced by treatment with CIS. This protection was evidenced in the serum as the elevated level in both urea and creatinine concentrations markedly lowered and the histomorphology of the kidneys was entirely normalized. Interestingly, these results support those of the previous studies that demonstrated the protective properties of TQ against nephrotoxicity and cardiotoxicity induced by other chemotherapeutic agents such as gentamicin, ifosfamide, and doxorubicin (Mousavi and Mohajeri, 2014) as well as against hypertension-induced renal damage (Kattab and Nagi, 2007).

In the present study, CIS significantly lowered the content of GSH and the activity of its related enzyme GST in rat renal tissues. Similar observations have been previously reported by Abdel Moneim et al. (2014) and Sahu et al. (2014). In contrast, administration of TQ prevented entirely the depleting effects of CIS on renal GSH and GST. These results were in agreement with the findings of previous studies showed the powerful inhibitory effects of TQ against chemicals-induced depletion of GSH and

its related antioxidant enzymes (**Banerjee et al., 2010 and Abdel-Wahab, 2015**).

It is evident that the content of GSH and the activity of its related enzymes, particularly GST, constitute the essential antioxidant and detoxification elements in most human and animal cells and tissues (**Mari et al., 2009**). In addition, the intracellular GSH status and the activity of GST appear to be sensitive indicators of the overall health of a cell and its ability to resist toxic challenges (**Kensara et al., 2013**). Moreover, **Soliman et al. (2013)** showed that kidneys from CIS-treated rats have a weak or even no antioxidant defence mechanism and are more vulnerable to reactive oxygen species (ROS). Also, **Al-Malki and Sayed (2014)** reported that due to induction of GSH and GST in liver tissues, TQ mediated a marked chemopreventive-antioxidant effect in hepatic disorders via induction of GST in liver tissues. Based on these collective evidences, it could be suggested that the preventative effect of TQ against CIS-induced depletion of renal GSH and GST is, at least in part, an important event in the renoprotective effects of TQ against CIS-induced nephrotoxicity and ARF.

Lipid peroxidation of cell membranes is also considered as one of the major reasons for oxygen radical-induced cellular and tissue injury (**Dianzani and Barrera, 2008**). It is used as an indicator of oxidative stress in all human cells and tissues (**Boveris et al., 2008**). TBARS is a widely employed assay in determining lipid peroxidation and oxidative damage (**Dawan-Linsley et al., 2005**). In the present study, the concentrations of TBARS in renal tissues of all animal groups were measured, and their values

showed that CIS significantly elevated TBARS levels. Thereby, it could be suggested that lipid peroxidation and oxidative stress induced by CIS might play a role in CIS-induced renal damage. On the other hand, pretreatment of the rats with TQ before and after single injection of CIS clearly prevented these inducing effects of CIS on renal TBARS. In support with these results, a strong relationship between CIS-nephrotoxicity, lipid peroxidation and oxidative stress has been previously confirmed (**Rubera et al., 2013**). Also, it has been illustrated that TQ inhibits lipid peroxidation, decreases cellular oxidative stress, and stimulates antioxidant defence capacity (**Jrah-Harzallah et al., 2013**). The findings of the previous studies run in a full constancy with the findings in the present study wherein both the inducing effects of TQ on renal GSH and GST and its inhibitory effects on lipid peroxidation have clearly been demonstrated.

In conclusion, the present study suggested that TQ provided a significant protective effect against CIS-induced severe nephrotoxicity and ARF in rats by a mechanism related, at least in part, to its ability to lower lipid peroxidation and oxidative stress as well as to preserve the activity of antioxidant elements and enzymes in renal tissues.

ACKNOWLEDGMENT

I would like to thank **Dr Mohamed Abdo**, Lecturer of histology, Al-Azhar Faculty of Medicine, for histopathological analysis.

REFERENCES

1. **Abdel Moneim A.E., Othman M.S. and Aref A.M. (2014):** Azadirachta indica Attenuates Cisplatin-Induced Nephrotoxicity and Oxidative

- Stress. *BioMed Research International*, 2014: 1-11.
- Abdel-Wahab W.M. (2015):** Therapeutic Efficacy of Thymoquinone and Selenium Against Cyclosporine A Nephrotoxicity in Rats. *Journal of Pharmacology and Toxicology*, 10 (2): 60-70.
 - Alimohammadi S., Hobbenaghi R., Javanbakht J., Kheradmand D., Mortezaee R., Tavakoli M., Khadivar F. and Akbari H. (2013):** Protective and antidiabetic effects of extract from *Nigella sativa* on blood glucose concentrations against streptozotocin (STZ)-induced diabetic in rats: an experimental study with histopathological evaluation. *Diagn. Pathol.*, 8: 137-142.
 - Almaghrabi O.A. (2015):** Molecular and biochemical investigations on the effect of quercetin on oxidative stress induced by cisplatin in rat kidney. *Saudi. J. Biol. Sci.*, 22(2): 227–231.
 - Al-Malki A.L. and Sayed A.A. (2014):** Thymoquinone attenuates cisplatin-induced hepatotoxicity via nuclear factor kappa- β . *BMC Complementary and Alternative Medicine*, 14:282-290.
 - Al-Naqeeb G., Maznah I. and Al-Zubairi A.S. (2009):** Fatty acid profile, α -tocopherol content and total antioxidant activity of oil extracted from *Nigella sativa* seeds. *Int. J. Pharmacol.*, 5: 244-250.
 - Arany I., Megyesi J.K., Kaneto H., Price P.M. and Safirstein R.L. (2004):** Cisplatin-induced cell death is EGFR/src/ERK signaling dependent in mouse proximal tubule cells. *Am. J. Physiol. Renal Physiol.*, 287: F543–F549.
 - Arunkumar P.A., Viswanatha G.L., Radheshyam N., Mukund H. and Belliyappa M.S. (2012):** Science behind cisplatin-induced nephrotoxicity in humans: A clinical study. *Asian Pac. J. Trop. Biomed.*, 2(8): 640–644.
 - Ashraf S.S., Rao M.V., Kaneez F.S., Qadri S., Al-Marzouqi A.H., Chandranath I.S. and Adem A. (2011):** *Nigella sativa* extract as a potent antioxidant for petrochemical-induced oxidative stress. *J. Chromatogr. Sci.*, 49: 321-326.
 - Baillie T.A. and Slatter J.G. (1991):** Glutathione: a vehicle for the transport of chemically reactive metabolites in vivo. *Acc. Chem. Res.*, 24 (9): 264–270.
 - Banerjee S., Padhye S., Azmi A., Wang Z., Philip P., Kucuk O., Sarkar F.H. and Mohammad R.M. (2010):** Review on Molecular and Therapeutic Potential of Thymoquinone in Cancer. *Nutr. Cancer*, 62(7): 938–946.
 - Basu A. and Krishnamurthy S. (2010):** Cellular Responses to Cisplatin-Induced DNA Damage. *Journal of Nucleic Acids*, 2010: 1-16.
 - Boveris A., Repetto M.G., Bustamante J., Boveris A.D. and Valdez L.B. (2008):** The concept of oxidative stress in pathology. In: ? Ivarez, S.; Evelson, P. (ed.), *Free Radical Pathophysiology*, pp. 1-17, Transworld Research Network: Kerala, India, ISBN: 978-81-7895-311-3.
 - Chirino Y.I. and Pedraza-Chaverri J. (2009):** Role of oxidative and nitrosative stress in cisplatin-induced nephrotoxicity. *Exp. Toxicol. Pathol.*, 61(3): 223–242.
 - Ciarimboli G. (2014):** Membrane Transporters as Mediators of Cisplatin Side Effects. *Anticancer Res.*, 34: 547-550.
 - Dawn-Linsley M., Ekinci F.J., Ortiz D., Rogers E. and Shea T.B. (2005):** Monitoring thiobarbituric acid-reactive substances (TBARs) as an assay for oxidative damage in neuronal cultures and central nervous system. *Journal of Neuroscience Methods*, 141(2): 219–222.
 - Dianzani M. and Barrera G. (2008):** Pathology and physiology of lipid peroxidation and its carbonyl products. In: ? Ivarez, S.; Evelson, P. (ed.), *Free Radical Pathophysiology*, pp. 19- 38, Pbl. Transworld Research Network: Kerala, India.
 - Fabiny D.L. and Ertingshausen G. (1971):** Automated reaction-rate method for determination of serum creatinine with the CentrifChem. *Clin. Chem.*, 17(8): 696-700.
 - Fallah H.H., Amini M., Mohtashami R., Ghamarchehre M.E., Sadeqhi Z., Kianbakht S. and Fallah H.A. (2013):** Blood pressure lowering effect of *Nigella sativa* L. seed oil in healthy volunteers: a randomized, double-blind, placebo-controlled clinical trial. *Phytother. Res.*, 27: 1849-1853.
 - Gamal El-Din A.M. and Al-Bekairi A.M. (2006):** Carvedilol, A Beta Adrenoceptor Blocker with Antioxidative Potential, Attenuates Cisplatin-induced Nephrotoxicity in

- Rats. Journal of Applied Sciences Research, 2(6): 331-335.
21. **Habig W.H., Pabst M.J. and Jakoby W.B. (1974):** Glutathione S-transferases. The first enzymatic step in mercapturic acid formation. J. Biol. Chem., 249(22): 7130-7139.
 22. **Hosseinian S., Khajavi R.A., Hadjzadeh M., Mohamadian R.N., Havakhah S.H. and Shafiee S. (2015):** The protective effect of *Nigella sativa* against cisplatin induced nephrotoxicity in rats. Avicenna J. Phytomed., 1-11.
 23. **Jrah-Harzallah H., Ben-Hadj-Khalifa S., Almawi W.Y., Maaloul A., Houas Z. and Mahjoub T. (2013):** Effect of thymoquinone on 1,2-dimethyl-hydrazine-induced oxidative stress during initiation and promotion of colon carcinogenesis. E.J.C, 49(5): 1127-1135.
 24. **Kanter M., Demir H., Karakaya C. and Ozbek H. (2005):** Gastroprotective activity of *Nigella sativa* L oil and its constituent, thymoquinone against acute alcohol-induced gastric mucosal injury in rats. World J. Gastroenterol., 11(42): 6662-6666.
 25. **Kapan M., Tekin R., Onder A., Firat U., Evliyaoglu O., Taskesen F. and Arikanoglu Z. (2012):** Thymoquinone ameliorates bacterial translocation and inflammatory response in rats with intestinal obstruction. Int. J. of Surgery, 10: 484-488.
 26. **Katzung B.G. (2004):** Cancer chemotherapy. In Basic and Clinical Pharmacology. 9th ed., Section 8, Chap. 55, pp. 906, Pbl. NewYork: McGraw-Hill.
 27. **Kawai Y., Nakao T., Kunimura N., Kohda Y. and Gemba M. (2006):** Relationship of intracellular calcium and oxygen radicals to Cisplatin-related renal cell injury. J. Pharmacol. Sci., 100: 65-72.
 28. **Kensara O.A. (2013):** Protective effect of vitamin C supplementation on oxonate-induced hyperuricemia and renal injury in rats. Int. J. Nut. Metab., 5(4): 61-68.
 29. **Khan A., Chen H.C., Tania M. and Zhang D.Z. (2011):** Anticancer Activities of *Nigella sativa* (Black Cumin). Afr. J. Tradit. Complement Altern. Med., 8: 226-232.
 30. **Khan S.A., Khan A.M., Karim S., Kamal M.A., Damanhoury G.A. and Mirza Z. (2014):** Panacea seed ‘‘*Nigella*’’: A review focusing on regenerative effects for gastric ailments. Saudi Journal of Biological Sciences, 1-12.
 31. **Khattab M.M. and Nagi M.N. (2007):** Thymoquinone supplementation attenuates hypertension and renal damage in nitric oxide deficient hypertensive rats. Phytother. Res., 21(5): 410-414.
 32. **Li G., Sha S., Zotova E., Arezzo J., Van De Water T. and Schacht J. (2002):** Salicylate Protects Hearing and Kidney Function from Cisplatin Toxicity without Compromising its Oncolytic Action. Lab. Invest., 82:585-596
 33. **Majdalawieh A.F. and Fayyad M.W. (2015):** Immunomodulatory and anti-inflammatory action of *Nigella sativa* and thymoquinone: A comprehensive review. International Immunopharmacology, 28 (1): 295-304.
 34. **Mansour M.A., Mostafa A.M., Nagi M.N., Khattab M.M. and Al-Shabanah O.A. (2002):** Protective effect of aminoguanidine against nephrotoxicity induced by cisplatin in normal rats. Comparative Biochemistry and Physiology Part C, 132: 123-128.
 35. **Mari M., Morales A., Colell A., Garcia-Ruiz C. and Fernandez-Checa J.C. (2009):** Mitochondrial Glutathione, a Key Survival Antioxidant. Antioxidants & redox signaling, 11 (11): 2685-2700.
 36. **Miller R.P., Tadagavadi R.K., Ramesh G. and Reeves W.B. (2010):** Mechanisms of Cisplatin Nephrotoxicity. Toxins, 2: 2490-2518.
 37. **Mousavi G. and Mohajeri D. (2014):** Effect of ground black seeds (*Nigella sativa* L.) on renal tubular cell apoptosis induced by ischemia/reperfusion injury in the rats. Iran J. Basic Med. Sci., 17(12): 1032-1035.
 38. **Noori S. and Mahboob T. (2010):** antioxidant effect of carnosine pretreatment on cisplatin-induced renal oxidative stress in rats. Indian Journal of Clinical Biochemistry, 25 (1): 86-91.
 39. **Ohkawa H., Orishi N. and Yagi K. (1979):** Assay for lipid peroxides in animal tissues by thiobarbituric acid reaction. Anal Biochem., 95(2):351-358.
 40. **Ozkok A. and Edelstein C.L. (2014):** Pathophysiology of Cisplatin-Induced Acute Kidney Injury. Bio. Med. Research International, 2014: 1-17.
 41. **Peres L.A.B. and J?nior A.D. (2013):** Acute nephrotoxicity of cisplatin: molecular mechanisms. J. Bras. Nefrol., 35 (4): 332-340.

42. Prabhu V., Kannan N. and Guruvayorappan C. (2013): 1,2-Diazole prevents cisplatin-induced nephrotoxicity in experimental rats. *Pharmacol. Rep.*, 65(4): 980-990.
43. Rubera I., Durantón C., Melis N., Cougnon M., Mograbi B. and Tauc M. (2013): Role of CFTR in oxidative stress and suicidal death of renal cells during cisplatin-induced nephrotoxicity. *Cell Death and Disease*, 4: e817-e827.
44. Sahu B.D., Kalvala A.K., Koneru M., Kumar J.M., Kuncha M., Rachamalla S.S. and Sistla R. (2014): Ameliorative Effect of Fisetin on Cisplatin-Induced Nephrotoxicity in Rats via Modulation of NF- κ B Activation and Antioxidant Defence. *PLOS ONE*, 9(9): 1-15.
45. Shalaby R.H., Rashed L.A., Ismaail A.E., Madkour N.K. and Elwakeel S.H. (2014): Hematopoietic stem cells derived from human umbilical cord ameliorate cisplatin-induced acute renal failure in rats. *Am. J. Stem Cells*, 3(2): 83-96.
46. Soliman D.E., Gabry M.S., Farrag A.H. and Abdel Moniem A.E. (2013): The Protective Role of Neem Leaves Extract on Cisplatin-Induced Polysaccharides and Protein Depletion in Rat Liver and Kidney. *Pakistan J. Zool.*, 45(6): 1687-1698.
47. Sung M.J., Kim D.H., Jung Y.J., Kang K.P., Lee A.S., Lee S., Kim W., Davaatseren M., Hwang J., Kim H., Kim M.S., Kwon D.Y. and Park S.K. (2008): Genistein protects the kidney from cisplatin-induced injury. *Kidney International*, 74:1538-1547.
48. Tabacco A., Meattini F., Moda E. and Tarli P. (1979): Simplified enzymic/colorimetric serum urea nitrogen determination. *Clin. Chem.*, 25(2): 336-337.
49. Yao X., Panichpisal K., Kurtzman N. and Nugent K. (2007): Cisplatin nephrotoxicity: a review. *Am. J. Med. Sci.*, 334: 115-124.
50. Yilmaz H.R., Iraz M., Sogut S., Ozyurt Z.Y., Akyol O. and Gergerlioglu S. (2004): The effects of erdosteine on the activities of some metabolic enzymes during cisplatin induced nephrotoxicity in rats. *Pharmacol. Res.*, 50: 287-290.
51. Yousef M.I. and Hussien H.M. (2015): Cisplatin-induced renal toxicity via tumor necrosis factor- α , interleukin 6, tumor suppressor P53, DNA damage, xanthine oxidase, histological changes, oxidative stress and nitric oxide in rats: Protective effect of ginseng. *Food and Chemical Toxicology*, 78: 17-25.

محمد حسن عبد الستار

قسم الفسيولوجيا الطبية – كلية الطب - جامعة الأزهر - القاهرة

خلفية للبحث: يستخدم عقار السيسبلاتين في علاج أنواع متعددة من السرطانات ولكن سميته البالغة على الكلى تحد من الإستفادة المثلى به في الطب السريري.

الهدف من البحث: صمم هذا العمل لبيان مدى التأثيرات الكلوية الحمائية المحتملة لمركب الثيموكينون المشتق من زيت حبة البركة وذو الخواص المؤكدة في مقاومته للتأكسد و ضد السمية الكلوية لعقار السيسبلاتين في الجرذان.

مواد وطرق البحث: اشتملت عينة البحث على أربعين جرذا من الذكور وقد قسمت الجرذان إلى أربعة مجموعات متساوية وتم معالجتها كما يلي:
المجموعة الأولى وهي المجموعة الضابطة
المجموعة الثانية: تلقت مركب الثيموكينون (5 مجم/كجم/ اليوم) عن طريق الفم لمدة 11 يوم.
المجموعة الثالثة: تم حقنها داخل الغشاء الصفاقي بعقار السيسبلاتين (7,5 مجم/كجم) في اليوم السادس من التجربة لإحداث السمية الكلوية.
المجموعة الرابعة: تلقت مركب الثيموكينون لمدة 11 يوم بالإضافة للحقن بعقار السيسبلاتين في اليوم السادس من التجربة وبنفس النظام الجرعى السالف الذكر.

وقد تم سحب عينات دم وريدية في اليوم الثاني عشر من التجربة مع إستخلاص جميع الكلى للفحوصات والتحليل الآتية: (1) قياس مستوى نيتروجين يوريا الدم والكرياتينين في أمصال الدم كدلالات بيوكيميائية للوظائف الكلوية، (2) تقييم المحتوى الكلى من المواد المتفاعلة مع حمض الثيوباربيتوريك كمؤشر على صورة أكسدة الدهون والإجهاد المؤكسد في الأنسجة الكلوية، (3) تقدير كمية الجلوتاثيون ونشاط الإنزيم التابع له وهو الإنزيم ناقل الكيريت للجلوتاثيون كرمز لقدرة النسيج الكلى في تضاده للتأكسد، (4) الفحوص الهستوباثولوجية الميكروسكوبية للأنسجة الكلوية المستخلصة.

النتائج: قد أظهرت نتائج البحث السمية البالغة لعقار السيسبلاتين على الكلى وما يصحبها من إزدياد ذات دلالة إحصائية في مستويات نيتروجين يوريا الدم والكرياتينين وفي المحتوى الكلى من المواد المتفاعلة مع حمض الثيوباربيتوريك وكذلك إنخفاض ذات دلالة إحصائية في كمية الجلوتاثيون ونشاط الإنزيم التابع له في الأنسجة الكلوية. وقد عزز الفحص الميكروسكوبى هذه السمية بما أظهرته الفحوص الهستوباثولوجية من وجود تهتكات شديدة في كلى الجرذان. ومن ناحية أخرى قد أثبتت النتائج أن إعطاء مركب الثيموكينون منع عقار السيسبلاتين من إحداث هذه السمية الكلوية وما يتبعها من تغيرات بيوكيميائية وهستوباثولوجية.

الإستنتاج: وعلى هذا يمكن القول بأن إحقاق مركب الثيموكينون بعقار السيسبلاتين يحمى الكلى من السمية البالغة لهذا العقار وذلك على الأقل عن طريق قدرته على منع أكسدة الدهون والإجهاد المؤكسد والمحافظة على مضادات الأكسدة في الأنسجة الكلوية.