

## Comparative Study between Endoscopic Transcanal Myringoplasty Versus Microscopic Myringoplasty in middle age group (20-40 years)

Wael Hassan Abo-Elwafa, Mohammed Kamel Ibrahim Alawady, Hossam Mohammed Esam

Otorhinolaryngology- Faculty of Medicine - Al Azhar University

Corresponding author: Hossam Mohammed Esam, email: hossamesam49@gmail.com

### ABSTRACT

**Background:** The surgical goals of myringoplasty are the closure of the tympanic membrane perforation and improvement of the hearing levels.

**Aim of the work:** To compare the results, advantages and disadvantages between endoscope and microscope in myringoplasty.

**PATIENTS AND METHODS:** This study was carried out in the Otorhinolaryngology Department at Alhussin and Bab-Alsharia University Hospitals. The study included 40 patients with a diagnosis of chronic suppurative otitis media of tubo-tympanic type, divided into two groups and each group contained 20 patients. All patients were operated by one surgeon.

**Results:** The difference in age, sex, side of diseased ear and size of perforation between the two groups was not significant. In group (A) the circumference of the perforation was clearly visualized in all patients (100%). While, in group (B) the circumference of the perforation could not be visualized in 7 patients (35%), 5 patients (25%) required external auditory canal curettage and 2 patients (10%) required endoscope-assisted microscopic myringoplasty to evaluate the ossicular chain. The difference between the 2 groups was significant (P.value = 0.004). In group (A) the graft was uptaken in 85% of patients while in group (B) the graft was uptaken in 80% of patients with no significant difference between the two groups (p = 0.677).

**Conclusion:** The ability to easily negotiate through EAC, Panoramic, wide angle, and magnified view provided by the endoscope and uninterrupted picture overcomes most of the disadvantage of the microscope.

**Key words:** chronic suppurative otitis media - endoscope – microscope.

### INTRODUCTION

Myringoplasty is mainly the treatment of choice for the tympanic membrane perforations, whether associated or not with non-suppurative chronic otitis media<sup>(1)</sup>. The surgical goals of myringoplasty are the closure of the tympanic membrane perforation and improvement of the hearing levels<sup>(2)</sup>.

There has been an increase in the use of endoscopes in ear surgery in the last decade, not only as an adjunct method, but exclusively<sup>(3)</sup>. The use of the endoscope for myringoplasty has a significant advantage because it is simple to use, not only for ear examination, but also for repairing of the tympanic membrane perforation. This provides a magnified vision and enables the surgeon to change from a close up to a wide angle view rapidly, just by going closer or by withdrawing the endoscope. Further, it provides an all-round view to the surgeon, who can rotate the angled endoscope to visualize the deep anterior canal wall, anterior marginal perforations, anterior recess, sinus tympani, fascial recess, hypotympanum and the attic<sup>(4)</sup>. Microscope gives binocular vision and allow the surgeon to free his both hands for the operative work. The main advantage of the microscope is that it provides a magnified view along a straight line<sup>(5)</sup>. The view during microscopic surgery is defined and limited by the narrowest segment of the ear canal, while the endoscope can bypasses the narrow part of the ear canal and provides a wide view, even by using a 0° endoscope<sup>(6)</sup>.

### MATERIALS AND METHOD

This study was carried out in the Otorhinolaryngology Department at Alhussin and Bab-Alsharia University Hospitals. The study included 40 patients. The age of all patients was > 20 years old with a diagnosis of chronic suppurative otitis media of tubo-tympanic type. The patients were divided into two groups, each group contained 20 cases:

- **Group A:** 20 patients were operated on using the endoscope-assisted myringoplasty.
- **Group B:** 20 patients were operated on using microscopic myringoplasty.

#### Inclusion Criteria:

- 1) Patients having small, medium and large (subtotal) dry perforation of tympanic membrane.
- 2) Patients having chronic suppurative otitis media of tubo-tympanic type.
- 3) No evidence of infection in nose, paranasal sinuses, nasopharynx and throat.
- 4) Fit for surgery.

#### Exclusion criteria:

- 1) Patients less than 20 years old or older than 40 years old.
- 2) Wet ears.
- 3) Revision Myringoplasty.
- 4) Patients with chronic suppurative otitis media of attico-antral type (cholesteatoma).

- 5) Patients with complications of chronic otitis media.
- 6) Patients with chronic diseases as diabetes mellitus, chronic renal or hepatic diseases.

**Preoperative assessment:**

-All patients will be subjected pre-operatively to:

- 1) Thorough history taking.
- 2) Full ENT examination.
- 3) Investigations including hematological investigations.
- 4) Pure Tone Audiometry.

**Surgical technique**

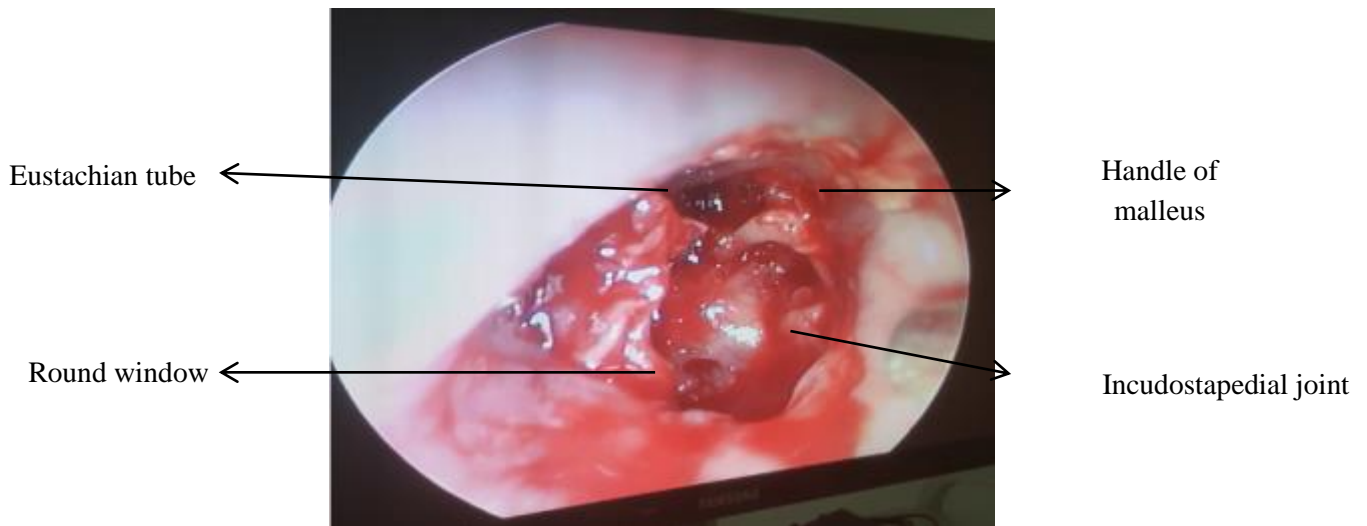
All patients were operated under general anesthesia. After written consent, patients were classified into two groups: The first group included 20 ears of 20 patients (50%) done by endoscopic transcanal technique, and the second group included 20 ears of 20 patients (50%) done by microscope through transcanal technique. Endoscopic transcanal

myringoplasty was done using 4 mm 0 degree endoscope.

Patients were positioned in a supine position. Sterilization of the ear was done and the tragus was injected with saline Adrenaline (1/200000).

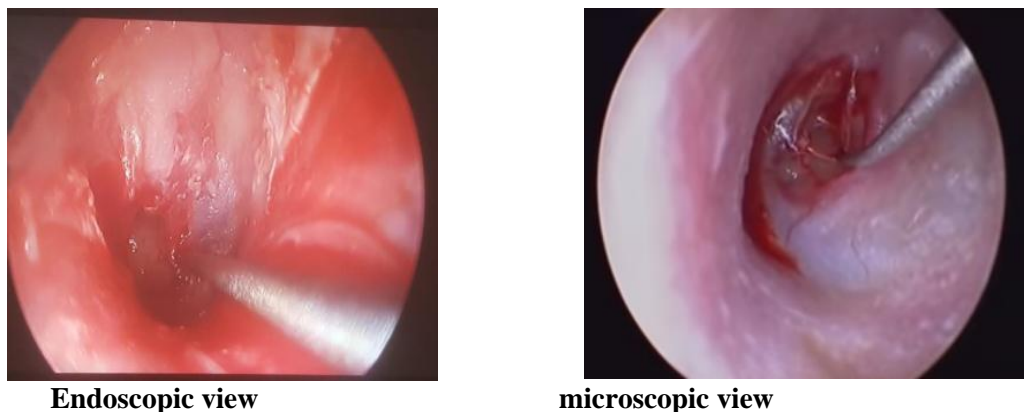
In the endoscopic technique, the middle ear was inspected, and following findings were noted: State of the ossicles and incudostapedial joint, eustachian tube opening, oval and the round window and any hidden granulation tissues within the middle ear were seen and removed using the endoscope that may be source of infection and graft rejection.

In microscopic group, during refreshment of the edges of the perforation, the circumference of the perforation could not be visualized in some cases. 5 patients required external auditory canal curettage and 2 patients required using endoscope to assist the microscope in visualization of the edges of the perforation.

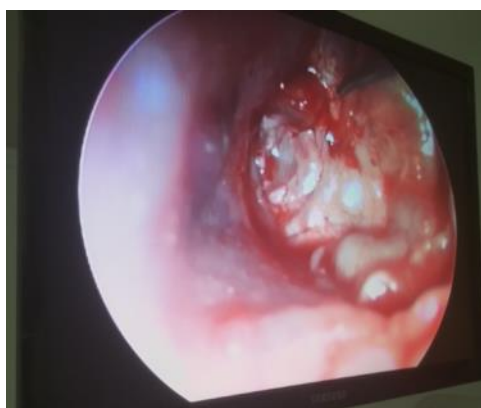

**Figure (1):** Exploration of the middle ear cavity by endoscope showing handle of malleus, Eustachian tube orifice, the incudostapedial joint, and the round-window niche.

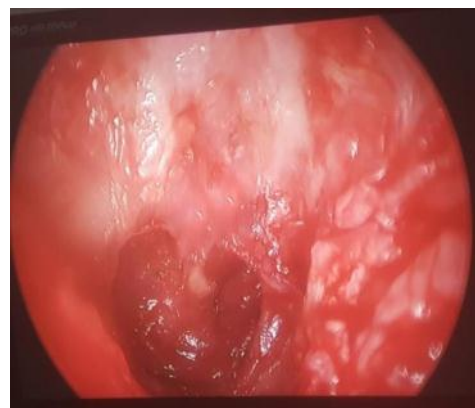
The margin of the TM perforation was trimmed. Small pieces of gelfoam were placed in the middle ear through the perforation for preventing medial displacement of the graft. The tympano meatal flap was raised few mm from the annulus to expose the handle of malleus, then the graft was taked under the handle to close the perforation in all surrounding. Then the tympano-meatal flap repositied to its place. Gelfoam was placed lateral to the graft for lateral support. Suturing of the tragal incision and then packing of external auditory canal in both were done.



**Figure (2):** trimming the edges of the perforation



Endoscopic view



microscopic view

Figure (3): placing the graft

**Postoperative care and follow up:**

Patients were discharged on the same day of the surgery. All patients received postoperative antibiotics for at least 7 days after surgery. Patients were instructed to avoid wetting of the ears, sneezing, constipation and vigorous blowing of the nose.

Postoperative Follow-up was performed for at least 2 months. The first postoperative visit was after one week for removal of aural pack and stitches after which antibiotic ear drops were prescribed for one week. Follow up included otoscopic examination of the TM to monitor graft healing. Audiological assessment (PTA) was done at the end of the second month postoperatively.

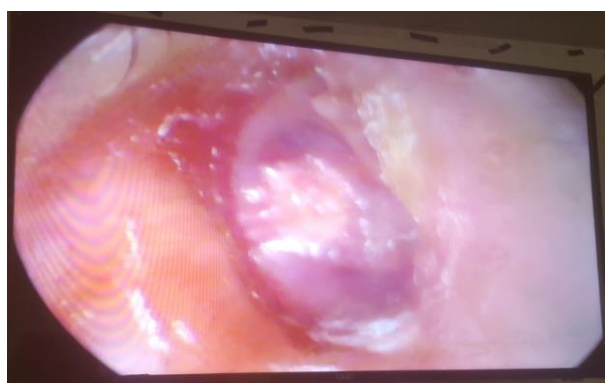

Figure (4): Follow up endoscopic image after 1 month shows successful results with complete graft uptake.

Also we assessed symptomatic improvement by improvement of the air-bone gap in the PTA, which was evaluated by measuring the air-bone conduction defect at 500, 1000, 2000, 4000 Hz preoperative. Then, the mean air bone gap was obtained by the total air bone gaps for ears in each group divided by their numbers and the same was done on the end of the 2nd month postoperative for both groups A and B.

**Ethical approval:**

The study was approved by the Ethics Board of Al-Azhar University.

**RESULTS**

The study was done from March 2018 to May 2019.

The results of 40 patients underwent endoscopic and microscopic myringoplasty were analyzed.

**Age, sex and side of diseased ear distribution**

The age of the patients ranged from 20 to 40 years old in all cases, with mean of  $31.40 \pm 5.95$  years in group A &  $31.85 \pm 5.76$  years in group B. There was no significant difference between the two groups regarding the age distribution (P value 0.809).

In endoscopic group (group A): males represented 70% (14 cases) and females represented 30% (6 cases) while in microscopic group (group B): males represented 45% (9 cases) and females represented 55% (11 cases). The difference in sex between the patients was not significant (P value 0.11).

Table (1): Distribution of patients with respect to age, sex and side in the study groups

	Group A N=20	Group B N=20	P-value
<b>Age in years</b>			
Mean $\pm$ SD	31.40 $\pm$ 5.95	31.85 $\pm$ 5.76	0.809
<b>Sex: n (%)</b>			
MALES	14 (70%)	9 (45%)	0.110
FEMALES	6 (30%)	11 (55%)	0.110
<b>Side of diseased ear</b>			
Right	12 (60%)	9 (45%)	0.342
Left	8 (40%)	11 (55%)	0.342

**Size of perforation**

In group (A), the size of perforation was large (subtotal) in 10 patients (50%) , medium sized in 6 patients(30%) and small in 4 patients (20%). While in group (B), the perforation was large (subtotal) in 12 patients (60%), medium sized in 4 patients (20%) and small in 4 patients (20%). The difference in size of perforation distribution between the two groups was not significant.

**Table (2):** Distribution of patients with respect size of perforation in the study groups

Size of perforation	Group A	Group B	
Large (subtotal)	10 (50%)	12 (60%)	0.530
Medium	6 (30%)	4 (20%)	0.470
Small	4 (20%)	4 (20%)	1.000

**Visualization of the edges of the perforation and ossicular chain:**

In group (A) the circumference of the perforation was clearly visualized in all patients (100%) even when the ear canal was narrow or protruding and in patients with subtotal perforation without need for external auditory canal curettage or canaloplasty.

While in group (B), the circumference of the perforation could not be visualized in 7 patients (35%), 5 patients (25%) required external auditory canal curettage and 2 patients (10%) required microscopic myringoplasty assisted by endoscope to evaluate the ossicular chain. The difference between the 2 groups was significant (p. value = 0.004).

**Table (3):** visualization of the edges of the perforation

Visualization of the edges of the perforations: n(%)	Group A N=20	Group B\ N-20	P –value
Visualized	20 (100%)	13 (65%)	0.004
Could not be visualized	0 (0%)	7 (35%)	
<b>Added procedures</b>			
Curettage	0 (0%)	5 (25%)	0.018
Microscope assisted by endoscope	0 (0%)	2 (10%)	0.151

**Pre-operative and post-operative ABGs**

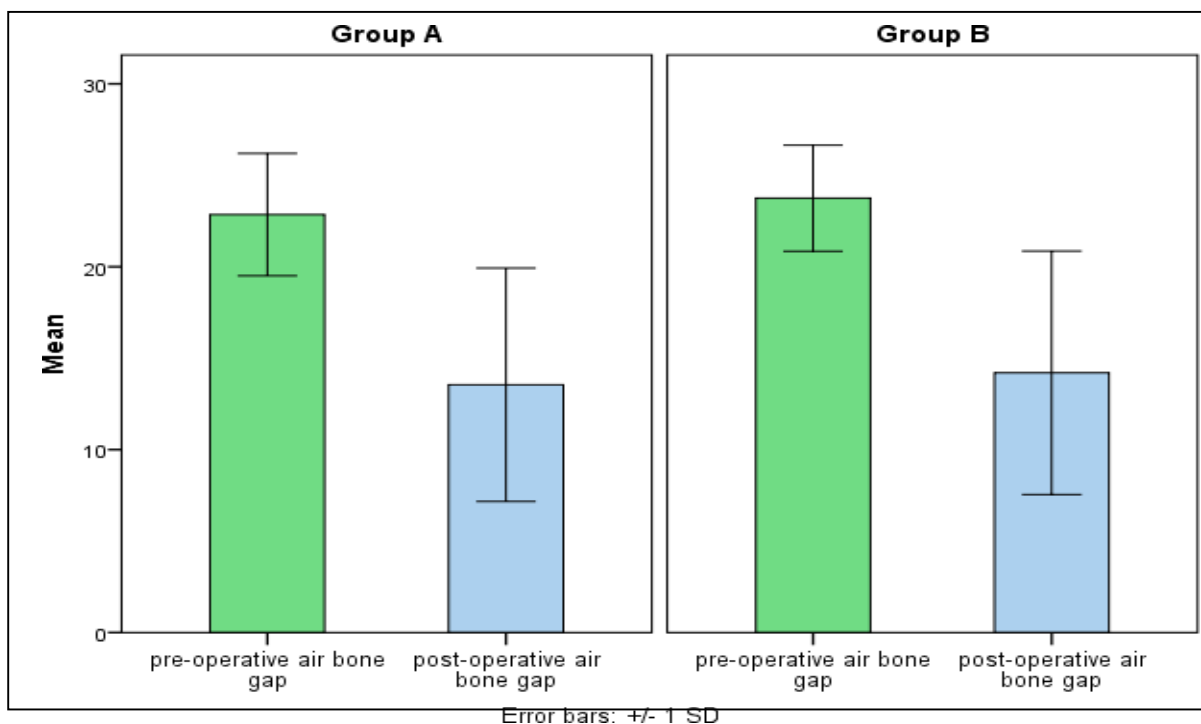
Preoperatively, the air bone gap was  $22.85 \pm 3.34$  in endoscopic group (group A) &  $23.75 \pm 2.90$  in microscopic group (group B). There were no significant differences between the two groups (p=0.369). Postoperatively, ABG was  $13.55 \pm 6.37$  in group A &  $14.20 \pm 6.65$  in group B with no significant differences between the two groups (p = 0.754). The gain in ABGs was  $9.30 \pm 4.66$  in group A &  $9.55 \pm 4.72$  in group B with no significant difference between the two groups (p = 0.867). Statistical analysis revealed that the difference between preoperative and last postoperative mean air bone gap in the two groups was significant (P < 0.001).

**Graft success rate**

In endoscopic group the graft was uptaken in 85% of patients (17 patients) and not taken in 15% of patients (3 patients). While in microscopic group the graft was uptaken in 80% of patients (16 patients) and not taken in 20% of patients (4 patients). There were no significant difference between the two groups (p = 0.677).

**Table (4):** ABGs and graft taking of the studied groups

	Group A N=20	Group B N=20	P-value
	Mean ± SD	Mean ± SD	
PreoperativeABG	$22.85 \pm 3.34$	$23.75 \pm 2.90$	0.369
PostoperativeABG	$13.55 \pm 6.37$	$14.20 \pm 6.65$	0.754
ABG gain	$9.30 \pm 4.66$	$9.55 \pm 4.72$	0.867
ABG gain percent	$42.33\% \pm 22.7$	$42.02\% \pm 23.10$	0.966
Graft taking			0.677
Taken	17(85%)	16(80%)	
Not taken	3(15%)	4(20%)	



**Figure (5):** Preoperative and postoperative ABGs of the studied groups

### Post-operative complications

Regarding complications, there were 3 residual perforations in endoscopic group (15 %) and another 4 residual perforations in microscopic group (20 %). All presented with post-operative infection and irregular follow up. No other complications were reported as SNHL in both groups. So there was no statistically significant difference regarding complications between endoscopic and microscopic groups after 2 months postoperatively.

### DISCUSSION

With the development of the rigid endoscopes in sinus surgery, other extended applications in other fields have emerged. Mer and his colleagues introduced the middle ear endoscopy in 1967<sup>(7)</sup>, but till the last decade endoscopes have been mainly used for photographic and diagnostic purposes. Recently few surgeons have been doing endoscopic middle ear surgery<sup>(8)</sup>.

Different endoscopes have been used recently in the performance of ear surgery in general and myringoplasty in particular, and the surgical success rate of endoscope assisted tympanoplasty ranges between 80% and 100%<sup>(9)</sup>.

The main goal of the operation is closure of the perforation and improvement of the hearing levels<sup>(10)</sup>. Using a thin, rigid endoscope, the surgeon can perform less invasive procedures and protection of the anatomy, which allows for functional reconstruction during surgery<sup>(11)</sup>.

In our study, group (A) included 20 ears, which underwent endoscopic transcanal myringoplasty, while group (B) included 20 ears, which underwent microscopic transcanal myringoplasty. Patients showed conductive deafness in pre-operative pure tone audiometry (PTA).

In group (A) the circumference of the perforation was clearly visualized in all patients (100%) even when the ear canal was narrow or protruding and in patients with subtotal perforation without need for external auditory canal curettage or canaloplasty. While in group (B), the circumference of the perforation could not be visualized in 7 patients (35%), 5 patients (25%) required external auditory canal curettage and 2 patients (10%) required microscopic myringoplasty assisted by endoscope to evaluate the ossicular chain. So, there were statistically significant differences between the 2 groups (p.value = 0.004).

In this study, endoscope gave good exposure to the perforation and the middle ear, which is similar to observation made in study of **Lade et al.**<sup>(12)</sup> compared 60 patients underwent either microscopic or endoscopic tympanoplasty type 1. Of the 30 patients who underwent the microscopic myringoplasty, four underwent external auditory canal curettage and five required canaloplasty to evaluate the ossicular system. Of the 30 patients who underwent the endoscopic myringoplasty, none of the patients required such interventions, and no difficulty was noted in the assessment of the ossicles. Also, in a study made by **Migirov and Wolf**<sup>(13)</sup> reported that **the** transcanal



microscope-assisted endoscopic myringoplasty had a 100% surgical success rate. This technique can be especially appropriate for patients with bone overhang, narrow external canals, anterior defects that making the perforation margins barely visible under a microscope. Moreover, the study conducted by **Furukawa et al.** <sup>(14)</sup> reported that the circumference of the perforation could not be confirmed with a microscope before denuding in 12.0% of patients. Furthermore, the entire perforation was not visible in 20.0% of patients after the refreshment of the edges. While endoscope can show the entire tympanic membrane in one field with clear visualization of the edges of the perforation, even when the ear canal is narrow or protruding.

In this study, the graft was uptaken in 85% of patients (17 patients) and not taken in 15% of patients (3 patients) in group (A), while the graft was uptaken in 80% of patients (16 patients) and not taken in 20% of patients (4 patients) in group (B). Patients in group (A) revealed improvement in the postoperative A-B gap of statistically significant differences between the preoperative A-B gap and the postoperative A-B gap. The mean A-B gap preoperatively was  $22.85 \pm 3.34$  & postoperative mean A-B gap (after 2 month)  $13.55 \pm 6.37$ . So, there were statistically significant differences between the preoperative A-B gap and the postoperative A-B gap in endoscopic group with P-value < 0.001 (HS).

In group (B), the study showed significant improvement in A-B gap. The mean A-B gap preoperatively was  $23.75 \pm 2.90$ . Postoperative mean A-B gap (after 2 month) was  $14.20 \pm 6.65$ . So, there were statistically significant differences between the preoperative A-B gap and the postoperative A-B gap in endoscopic group with P-Value < 0.001 (HS). The improvement in the A-B gap was  $9.30 \pm 4.66$  in group (A) and  $9.55 \pm 4.72$  in group (B) with no significant difference between the two groups ( $p = 0.867$ ).

The present results are in line with those of **Furukawa et al.** <sup>(14)</sup> who reported that 25 ears that underwent transcanal endoscopic myringoplasty; the graft taking rate was 84.0% and the improvement in ABG was 10.3 dB postoperative. And **Karhuketo et al.** <sup>(15)</sup> reported that in 29 endoscopic myringoplasty patients with follow up for one year postoperative, the perforation closure rate was 80% and the improvement of ABG was 7 dB postoperative. Also, **Ayache** <sup>(3)</sup> reported that the use of cartilage grafts in patients that underwent endoscopic myringoplasty can achieve a success rate of 96% <sup>(3)</sup>. The endoscopic approach could fulfill the goal of causing the least amount of trauma to the normal tissues with the increasing use of the minimally invasive surgery.

According to this study, the disadvantage of the endoscope is a one handed technique. The surgeon has

to hold the scope in one hand during all the time of the operation while only the other hand is free operative work. At time of excessive bleeding, it becomes extremely difficult to operate as only one hand is free. Also, blood soils the tip of the endoscope which obscures the surgical field. Thus the tip of the endoscope must be cleaned frequently. While in microscopic technique both hands are free for operation. So, while performing endoscopic myringoplasty, meticulous hemostasis is necessary for doing smooth surgeries. This problem can be solved by developing a stand for the endoscope, which can fix the scope in desired position so both hands are free to operate.

In our study, endoscopes allowed us close inspection of the tympanic membrane perforation, the drum remnant, the eustachian tube orifice and the mucosa of the middle ear and the ossicular chain. The anatomical variations (stenotic or tortuous ear canal, anterior meatal overhang etc.) that hamper the view of entire tympanic membrane during ear surgery were overcome by the use of endoscopes. Endoscope provides monocular vision that leads to loss of depth perception <sup>(16)</sup>.

## CONCLUSION

The ability to easily negotiate through EAC, panoramic, wide angle, and magnified view provided by the endoscope and uninterrupted picture overcomes most of the disadvantage of the microscope. Endoscope being portable is easy to be carried in camps. In this study, success rate was almost comparable between endoscopic and microscopic technique. One handed technique and loss of depth perception are some of the disadvantages of the endoscope that can be overcome with practice. So, endoscopic myringoplasty can be a good alternative of microscopic myringoplasty.

## REFERENCES

1. **Tawab A, Gharib F, ElSharkawy L, Algarf T (2014):** Myringoplasty with and without cortical mastoidectomy in treatment of non-cholesteatomatous chronic otitis media, a comparative study. Clin Med Insights Ear Nose Throat., 7: 19-23.
2. **Hong P, Bance M, Gratzer PF (2013):** Repair Of tympanic membrane perforation using novel adjuvant therapies: a contemporary review of experimental and tissue engineering studies. Int J Pediatr Otorhinolaryngol., 77: 3-12.
3. **Ayache S (2013):** cartilaginous myringoplasty: the endoscopic transcanal procedure. Eur Arch Otorhinolaryngol., 270: 853-60.
4. **Patil RN (2003):** Endoscopic tympanoplasty – Definitely advantageous (preliminary reports). Asian J Ear Nose Throat, 25: 9-13.

5. **Yadav SPS, Aggarwal N, Julaha M, Goel A (2009):** Endoscope assisted myringoplasty. Singapore medical journal, 50: 510-2.
6. **Tarabichi M, Ayache S, Nogueira JF, Al Qahtani M, Pothier DD(2013):** Endoscopic management of chronic otitis media and tympanoplasty. Otolaryngol Clin North Am., 46:155–163.
7. **El-Guindy A (1992):** Endoscopic transcanal myringoplasty. The Journal of Laryngology and Otology, 106:493–5.
8. **Harugop S, Mudhol RS, Godhi RA (2008):** A comparative study of endoscope assisted myringoplasty and microscope assisted myringoplasty. Indian J Otolaryngol Head Neck Surg., 60: 298–302
9. **Dünder R, Kulduk E, Soy FK, Aslan M, Hanci D, Muluk NB (2014):** Endoscopic versus microscopic approach to type 1 tympanoplasty in children. Int J Pediatr Otorhinolaryngol., 78: 1084–1089.
10. **Shrestha S , Sinha B (2006):** Hearing results after myringoplasty. Kathmandu University Medical Journal, 4: 455-459.
11. **Aoki K (2001):** Advantages of endoscopically assisted surgery for attic cholesteatoma. Diagn Ther Endosc ., 7: 99-107.
12. **Lade H, Choudhary SR, Vashishth A (2014):** Endoscopic vs microscopic myringoplasty: a different perspective. Eur Arch Otorhinolaryngol., 271: 1897-902.
13. **Migirov L and Wolf M (2015):** Transcanal microscope-assisted endoscopic myringoplasty in children. BMC pediatrics, 15:32-35.
14. **Furukawa T, Watanabe T, Ito T, Kubota T, Kakehata S (2014):** Feasibility and advantages of transcanal endoscopic myringoplasty. Otol Neurotol., 35: e140-5.
15. **Karhuketo TS, Ilomaki JH, Pukakka HJ(2001):** Tympanoscope-assisted myringoplasty. ORL J Otorhinolaryngol Relat Spec., 63: 353-7.
16. **Glasscock ME, Shambaugh GE (2003):** Tympanoplasty. In: Glasscock and Shambaugh. surgery of the ear, 5th edition. <https://journals.sagepub.com> > doi > abs > j.otohns