



Ameliorative Effect of Sugarcane (Blackstrap) Molasses Against Gamma Radiation or Manganese- Induced Testicular Toxicity in Male Albino Rats



N. Abdel-Magied[#], N.A. Abdel Aziz, S.M. Shedid, G.A. Ahmed

Radiation Biology Research Department, National Center for Radiation Research and Technology (NCRRT), Atomic Energy Authority, Nasr City, Cairo, Egypt.

SUGARCANE molasses is a potent antioxidant. Radiation and excess manganese are toxins causing a wide range of adverse effects that can be severe and induce tissues damage to mammals. In an attempt to minimize these effects, the present study aims to evaluate the mitigating effect of molasses on radiation or manganese toxicity-induced testicular tissue damage. Rats were whole-body gamma-irradiated with a single dose of 6Gy, or administered $MnCl_2 \cdot 4H_2O$ in a single intraperitoneal injection (100mg/kg body weight). The results showed that molasses treatment (200mg/ 100g body weight/day) for seven days post-radiation or manganese toxicity induced a marked amelioration in the oxidative stress biomarkers of serum and testicular tissues of rats manifested by decreased levels of total nitrate/nitrite (NOx) and malondialdehyde (MDA) associated with an elevation in the total antioxidant capacity (TAC). Molasses treatment has induced also a significant elevation in the mitochondrial cytochrome c oxidase (COX). Marked improvement in the level of serum testosterone, luteinizing hormone (LH), follicle-stimulating hormone (FSH), and glucose was also observed. Moreover, molasses was effective in modulating the concentration levels of copper (Cu), iron (Fe), zinc (Zn), manganese (Mn) and selenium (Se) in testicular tissue and epididymis. Additionally, the epididymal sperm count, as well as motility and viability percentage had markedly increased in rats treated with molasses, whereas there was a significant decrease in the number of sperms with abnormal morphology. In conclusion, sugarcane molasses can be considered as a new natural mitigating agent on the testicular injury induced by radiation or Mn-toxicity.

Keywords: Oxidative stress, Mitigators, Radiation, Manganese toxicity, Sugarcane, Testicular tissue.

Introduction

Human exposure to ionizing radiation under different circumstances either from natural or man-made sources has become a common application in the medicine and industry.

Radiation damage is caused by the overproduction of reactive oxygen species (ROS) that overwhelm the levels of antioxidants, resulting in oxidative stress and cellular damage (Spitz et al., 2004; Shedid et al., 2017). Despite the fact that manganese (Mn) is an essential trace element utilized by virtually all forms of life,

excessive amount of this element from industrial use of manganese and manganese compounds in the production of paint pigments, dry cell batteries, glass, ceramics and steel production induces excess formation of lipid peroxidation products in the cells (Santamaria & Sulsky, 2010), leading to oxidative stress which provokes neurotoxicity (Harischandra et al., 2015), immune toxicity (Son et al., 2007), heart damage (Huang et al., 2015) and reproductive dysfunction, particularly in males (Mohammed et al., 2018). In this context, it was shown that radiation-or excess manganese-toxicity -induced oxidative stress, which is a powerful mechanism that can lead to

[#]Corresponding author email: nanyabdelmagid@yahoo.com

Received 5/9/2019; Accepted 16/12/2019

DOI: 10.21608/ejrsa.2019.16629.1081

©2019 National Information and Documentation Center (NIDOC)

the disruption of spermatogenesis process causing sperm damage, deformity and eventually male infertility (Alahmar, 2019).

The testicular tissue is highly susceptible to oxidative stress due to its high content of polyunsaturated fatty acids (PUFAs) that are prone to lipid peroxidation (Guerriero et al., 2014) and also due to the toxic effects of reactive oxygen metabolites resulting from spermatogenesis and Leydig cell steroidogenesis processes (Aitken & Roman, 2008). Radiation or manganese toxicity mitigating agents are synthetic or natural agents that have the ability to prevent the perpetuation of damage and thus reduce the expression of toxicity. Unfortunately, chemical or synthetic mitigators have a lot of side effects in relation to their benefits; therefore, it is necessary to use natural antioxidants to avoid or reduce these side effects (Copp et al., 2013).

Natural antioxidants work by preventing or breaking the oxidative chain reaction or by reducing the formation of ROS. Antioxidants preserve the function of male reproductive system against homeostatic disturbances caused by oxidative stress, as well as potentially improving sperm DNA integrity and semen quality (Chyra-Jach et al., 2018).

Blackstrap molasses is a by-product of sugarcane's refining process. It is a dark viscous liquid resulting from the third boiling of the sugarcane syrup, and contains a large quantity of phenols, flavonoids (Kong et al., 2016), many essential minerals such as calcium, magnesium, manganese, potassium, copper, iron, phosphorous, cobalt, sodium and chromium as well as vitamins such as vitamin B6, pantothenic acid, niacin, thiamine and riboflavin (Takara et al., 2002; Nayaka et al., 2009). Blackstrap molasses exhibits antioxidant, anti-inflammatory, antimutagenic, tyrosinase inhibitory capabilities and hepatoprotective effect in laboratory experiments (Rahiman & Pool, 2010; Guan et al., 2014; Ali et al., 2019).

The current study was undertaken to investigate the role of blackstrap molasses against oxidative testicular damage induced by radiation or manganese toxicity in the male rats through assessment of some biochemical markers in the serum, testis and epididymis, as well as observation of the epididymal sperm morphology,

sperm count, motility, and viability percentage.

Material and Methods

Animals

Male albino rats were obtained from the Atomic Energy, the National Center for Radiation Research and Technology (NCRRT). Rats 3-4 month's age, weighing (200±10g) were housed under standard conditions of ventilation, temperature, humidity, lighting (12hrs light/dark cycle) and fed on standard pellets diet containing all nutritive elements. Food and water were available *ad-libitum*. All animal procedures were performed in accordance with the Ethics Committee of the National Research Center conformed to the Guide for the care and use of Laboratory Animals published by the National Institutes of Health (NIH publication No. 85-23, revised 1996).

Gamma- irradiation processing

Whole body gamma irradiation was performed using a Canadian Gamma Cell-40 (Cs- 137) (Atomic Energy of Canada Ltd, Ottawa, Ontario, Canada), located at NCRRT, Cairo, Egypt. The dose rate was 0.45Gy/minute during the experiment. The rat's whole body was exposed to gamma rays at a single dose of 6Gy.

Manganese treatment

Manganese dichloride tetrahydrate (MnCl₂·4H₂O; 99.99%) was purchased from Sigma Aldrich (St Louis, MO, USA) and was administered to rats by a single intraperitoneal injection of 100mg/kg body weight. MnCl₂·4H₂O dissolved in saline (Chen et al., 2006).

Sugarcane (blackstrap) molasses treatment

Molasses was purchased from El-Hawamdia Sugar Company and was administered at a dose of 200mg/100g body-weight/ day for seven successive days (Rahiman, 2011).

Study design

To assess the efficiency of molasses on testicular damage, animals were divided into six groups (6 animals in each group). (1) Control: Rats received saline; (2) Molasses: Rats received molasses by gavage (200mg/100g body-weight/day) for 7 successive days; (3) RAD: Rats were irradiated at a single dose of 6 Gy (4) RAD + molasses: Rats were irradiated at a dose of 6Gy, followed by molasses treatment (200mg/100g

body-weight/day) for 7 days; (5) $MnCl_2$: Rats intraperitoneally injected at a single dose of $MnCl_2 \cdot 4H_2O$ (100mg/kg body-weight) dissolved in saline; (6) $MnCl_2$ + Molasses: Rats injected with $MnCl_2 \cdot 4H_2O$ followed by molasses treatment (200mg/100g body-weight /day) for 7 days.

Preparation of samples

Rats were sacrificed the 7th day post- radiation or manganese administration after a fasting period of 12hrs, the blood was collected, allowed to clot and centrifuged at 3000rpm for 10min to obtain the serum for biochemical assay. Testis and the epididymis were immediately removed for biochemical analysis and sperms morphological examinations.

Biochemical analysis

Assessment of serum total testosterone

Serum testosterone was determined using Rat Testosterone Enzyme-Linked Immunosorbent Assay (ELISA) Kit Cat. No. SE120089 (Sigma Aldrich, St Louis, MO, USA). It is based on the principle of competitive binding between testosterone in the sample and testosterone-horseradish peroxidase (HRP) conjugate for antibody binding in the wells. After incubation, the wells are washed to remove unbound material and substrate solution is then added, which is catalyzed by HRP to produce blue coloration. The reaction is terminated by addition of stop solution that stops the color development and produces a color change from blue to yellow. The intensity of signal is inversely proportional to the amount of testosterone in the sample and the intensity is measured at 450nm (Tietz, 1995).

Assessment of serum luteinizing hormone (LH) and follicle stimulating hormone (FSH)

Serum concentration of LH and FSH were determined using Rat LH ELISA Kit Cat. No.CSB-E12654r and Rat FSH ELISA Kit Cat. No. CSB-E06869r, respectively from CUSABIO. These assays employ the competitive inhibition enzyme immunoassay technique according to the protocol provided with each kit.

Assessment of serum glucose

Serum glucose content was measured according to Trinder (1969) using glucose kit (Biodiagnostics, Egypt). Glucose is oxidized to gluconic acid and H_2O_2 by glucose oxidase. H_2O_2 reacts with phenol and 4 amino-antipyrine to form colored quinonimine in the presence of

peroxidase. The intensity of the color measured at 510nm is proportional to the glucose concentration.

Assessment of malondialdehyde content (MDA)

Lipid peroxidation (MDA marker) was assayed according to Ohkawa et al. (1979) using lipid peroxide (MDA) colorimetric kit (Biodiagnostic, Egypt). The method is based on the reaction between Thiobarbituric acid (TBA) and malondialdehyde (MDA) in acidic medium at temperature of 95°C for 30min to form thiobarbituric acid reactive product. The absorbance of the resultant pink product can be measured at 534nm.

Assessment of total nitrate/nitrite (NOx) content

NOx content was determined according to Miranda et al. (2001). The method is based on the measurement of total nitrite levels that is the only stable end product of the autoxidation of NO, vanadium (III) reduces nitrate to nitrite and/or nitric oxide, both of which are captured by Griess reagents [premixed 50 μ L sulfanilamide (2% in 5%HCl) and 50 μ L N-(1-Naphthyl) ethylenediamine dihydrochloride(0.1%)]. The Griess reaction forms a chromophore, which results in a measurable pink metabolite measured at 540nm.

Assessment of total antioxidant capacity (TAC)

Total antioxidant capacity was determined according to Huang et al. (2005) using Total Antioxidant Capacity Assay Kit Cat. No. MAK187 Sigma co., the principle of the method depended on the conversion of Cu^{2+} ion to Cu^+ by both small molecule and protein antioxidants. However, the use of the Protein Mask stops Cu^{2+} reduction by protein, enables the analysis of only the small molecule antioxidants. The reduced Cu^+ ion chelates with a colorimetric probe, giving a broad absorbance peak at 570nm, which is proportional to TAC.

Assessment of mitochondrial cytochrome c oxidase (COX) in the testis

Mitochondria were isolated using the Mitochondrial Isolation Kit Cat. No. MITOISO1 from Sigma Aldrich (St Louis, MO, USA) according to manufacturer's instructions. The crude homogenate, mitochondrial fractions were processed immediately for COX analysis using

cytochrome c oxidase colorimetric assay Kit Cat. No. CYTOCOX1 (Sigma Aldrich, St Louis, MO, USA). The method is based on the observation of the decrease in absorbance of ferrocytochrome c measured at 550nm, which is caused by its oxidation to ferricytochrome c by COX.

Estimation of some metals in molasses, testicular tissue and epididymis

Iron (Fe), copper (Cu), zinc (Zn), calcium (Ca), magnesium (Mg), manganese (Mn) and selenium (Se) were determined. Samples were weighted and digested in concentrated pure nitric acid (65%) and hydrogen peroxide in 4:1 ratio (IAEA, 1980). Samples digestion was carried out using acids at elevated temperature and pressure using microwave (High performance, Microwave Digestion, Lab. System, Mileston Digester, mls 1200 mega, Italy). Samples were then converted to soluble matter in deionized water to the appropriate concentration levels. The studied elements were detected quantitatively using a standard curve method for each element. The selected elements were then estimated quantitatively using an atomic absorption spectrophotometer, Thermo Scientific, iCE 3000 series, England (Kingston & Jassie, 1988).

Epididymal sperm analysis

Epididymal sperm count: The epididymis cauda was removed and a sperm suspension was prepared by mincing the tissue with a scissor in 3ml of Hank's buffered salt solution (HBSS) at 37°C. The suspension was filtered to remove tissue fragments and incubated for 5min at 37°C. An aliquot of sperm suspension was diluted 1:100 with HBSS, and introduced into a Neubauer's counting chamber (Deep 1/10mm, LABART, Germany) for sperm count as described by WHO (1999).

Epididymal sperm morphology: 100µl of the prepared epididymal suspension was placed on a glass slide to make a smear, which was then air-dried and stained with 0.05% aqueous solution of eosin-Y. Each sample was examined for sperm morphology under the light microscope at 400x magnification. Abnormal sperm morphology was categorized based on the presence of one or more abnormal features such as tail defects (coiled or detached tails); neck and middle piece defects (irregular, bent middle piece, abnormally thin middle piece); and head defects (round head, small or large size, double or detached head) (AL-

Ani et al., 2009). At least 200 spermatozoa were observed under the microscope for the calculation of abnormal sperm percentage (Wyrobek & Bruce, 1978). The percentage of abnormal sperm morphology was calculated from the following formula: Abnormality % = [Abnormal sperm count/ total sperm count (200)] × 100. Sperm motility% sperm motility was determined by placing a drop of 100µl of the sperm suspension on a 37°C pre-warmed slide and covered with a cover slip. In each preparation, 200 sperm were counted in the same field (Zemjanis, 1977). The percentage of sperm motility was calculated according to the following formula. Sperm motility % = All moving sperm count/total sperm count × 100.

Sperm viability %: Sperm viability % was performed by a dye exclusion method where dye enters a non-vital (dead) cell due to the damaged plasma membrane, using the eosin nigrosin staining. One drop of sperm suspension was mixed with two drops of 1% eosin Y. After 30 s, three drops of 10% nigrosin were added and mixed well. A smear was made by placing a drop of mixture on a clean glass slide and allowed to dry in air. The prepared slide was examined, non-viable sperm have red or dark-pink heads and viable sperm have white or faintly-pink heads and the sperm numbers were recorded as described by WHO (1999). The viability% = Live/dead ratio was determined

Statistical analysis

Groups were compared by one-way analyses of variance (ANOVA), and post hoc multiple comparisons were done with Tukey's test using SPSS/PC software program (version 21; SPSS Inc., Chicago, IL, USA). The data were expressed as mean ± standard error (S.E.) and values of P ≤ 0.05 were considered statistically significant.

Results

Biochemical results

In the current study, the results demonstrated that at day 7 post -radiation or Mn-toxicity, the levels of serum testosterone and LH as well as mitochondrial COX were significantly decrease (P ≤ 0.05), while a significant increase (P ≤ 0.05) in serum FSH and glucose was observed (Table 1). Moreover, a significant elevation in the serum and testicular tissue MDA and NOx associated with a significant decrease (P ≤ 0.05) in TAC

were observed, compared to control animals (Tables 1 and 2). Significant decreases ($P \leq 0.05$) in the concentration of Cu, Zn and Se along with a noticeable increase in Fe were observed in the testicular tissue and epididymis of rats post-irradiation or Mn-toxicity. However, the concentration of Mn decreased significantly in the irradiated animal, while a marked elevation was observed post Mn-toxicity, as compared to control animals.

The results obtained revealed that the administration of molasses (200mg/100g b.wt./day) for seven days to normal rats had a non-

significant effect on all of the studied parameters. While, the administration of molasses to irradiated or Mn-treated rats improved hormones levels of testosterone, LH and FSH, as well as glucose level (Table 1), reduced oxidative stress biomarkers in the serum and testicular tissue, and elevated the activity of mitochondrial COX (Tables 1 and 2). Furthermore, molasses normalized the concentrations of the metals in the testicular tissue and epididymis (Tables 3 and 4), compared to rats post-radiation or Mn-toxicity. The concentration levels of metals in molasses were estimated (Table 5).

TABLE 1. Effect of sugarcane molasses administration (200mg/100g/day) on testosterone, luteinizing hormone (LH), follicle stimulating hormone (FSH), glucose, malondialdehyde (MDA), total nitrate/nitrite (NOx) levels and total antioxidant capacity (TAC) in the serum of different animal groups.

Parameters	Testosterone (ng/ml)	LH (mIU/ml)	FSH (mIU/ml)	Glucose (mg/dl)	MDA (mmol/L)	NOx (nM/ml)	TAC (mmol/L)
Control	4.1 ± 0.18	2.8 ± 0.05	3.7 ± 0.08	96 ± 3	150 ± 4	300 ± 2	1.9 ± 0.09
Molasses	4.2 ± 0.03 ^a (+2)	2.7 ± 0.09 (-4)	3.8 ± 0.08 (+3)	103 ± 4 (+7)	148 ± 3 (-1)	310 ± 2 (+3)	2.0 ± 0.06 (+5)
RAD	1.2 ± 0.01 ^a (-71)	0.7 ± 0.09 ^a (-75)	5.1 ± 0.05 ^a (+38)	168 ± 4 ^a (+75)	260 ± 5 ^a (+73)	502 ± 9 ^a (+67)	0.7 ± 0.08 ^a (-63)
RAD + Molasses	3.4 ± 0.06 ^{ab} (-17)	2.1 ± 0.11 ^{ab} (-25)	4.1 ± 0.06 ^{ab} (+11)	120 ± 2 ^{ab} (+25)	170 ± 3 ^{ab} (+13)	366 ± 5 ^{ab} (+22)	1.5 ± 0.05 ^{ab} (-21)
MnCl ₂	0.9 ± 0.01 ^a (-78)	0.6 ± 0.02 ^a (-79)	5.3 ± 0.10 ^a (+43)	158 ± 4 ^a (+65)	274 ± 3 ^a (+83)	589 ± 6 ^a (+96)	0.5 ± 0.08 ^a (-74)
MnCl ₂ + Molasses	3.0 ± 0.06 ^{ac} (-27)	2.2 ± 0.05 ^{ac} (-21)	3.9 ± 0.06 ^c (+5)	117 ± 3 ^{ac} (+22)	175 ± 4 ^{ac} (+17)	378 ± 4 ^{ac} (+26)	1.2 ± 0.03 ^{ac} (-37)

- Values are expressed as Means ± SE (n= 6).

- Values between brackets show percentage of change from control.

- a: Significant ($P \leq 0.05$) when compared with the control group, b: Significant ($P \leq 0.05$) when compared with the corresponding RAD group, c: Significant ($P \leq 0.05$) when compared with the corresponding MnCl₂ group.

TABLE 2. Effect of sugarcane molasses administration (200mg/100g /day) on malondialdehyde (MDA) and total nitrate/nitrite (NOx) levels, total antioxidant capacity (TAC) and cytochrome c oxidase (COX) activity in the testicular tissues of different animal groups.

Parameters	MDA (nmol/g)	TAC (mg/g)	NOx (nmole/g tissue)	COX (unit/ml)
Control	420 ± 3	28 ± 1.1	532 ± 6	1.80 ± 0.03
Molasses	428 ± 5 (+2)	29 ± 1.5 (+4)	540 ± 7 (+2)	1.76 ± 0.03 (-2)
RAD	590 ± 8 ^a (+40)	13 ± 0.9 ^a (-54)	980 ± 15 ^a (+84)	0.89 ± 0.05 ^a (-51)
RAD + Molasses	461 ± 6 ^{ab} (+10)	26 ± 1.4 ^b (-7)	628 ± 7 ^{ab} (+18)	1.5 ± 0.04 ^{ab} (-17)
MnCl ₂	600 ± 5 ^a (+43)	12 ± 0.7 ^a (-57)	997 ± 10 ^a (+87)	0.64 ± 0.07 ^a (-64)
MnCl ₂ + Molasses	500 ± 4 ^{ac} (+19)	21 ± 1.2 ^{ac} (-25)	589 ± 3 ^{ac} (+11)	1.4 ± 0.04 ^{ac} (-22)

- Values are expressed as Means ± SE (n= 6).

- Values between brackets show percentage of change from control.

- a: Significant ($P \leq 0.05$) when compared with the control group, b: Significant ($P \leq 0.05$) when compared with the corresponding RAD group, c: Significant ($P \leq 0.05$) when compared with the corresponding MnCl₂ group.

TABLE 3. Effect of sugarcane molasses administration (200mg/100g/day) on the concentration levels of iron (Fe), copper (Cu), zinc (Zn), manganese (Mn) and selenium (Se) in the testicular tissue s of different animal groups.

Groups	Elements	Fe (µg/g)	Cu (µg/g)	Zn (µg/g)	Mn (µg/g)	Se (ng/g)
Control		32 ± 1.04	1.5 ± 0.05	26 ± 0.5	2.7 ± 0.8	120 ± 1.1
Molasses		35 ± 1.3 (+9)	1.6 ± 0.04 (+7)	27 ± 0.8 (+4)	2.8 ± 0.9 (+4)	122 ± 1.7 (+2)
RAD		65 ± 1.4 ^a (+103)	0.6 ± 0.04 ^a (-60)	11 ± 0.5 ^a (-58)	1.2 ± 0.9 ^a (-56)	55 ± 2.9 ^a (-54)
RAD + Molasses		40 ± 2.1 ^{ab} (+25)	1.2 ± 0.06 ^{ab} (-20)	29 ± 1.4 ^{ab} (+12)	2.4 ± 0.7 ^b (-11)	118 ± 1.9 ^b (-2)
MnCl ₂		59 ± 1.9 ^a (+84)	0.78 ± 0.03 ^a (-48)	15 ± 1.7 ^a (-42)	4.9 ± 2 ^a (+85)	89 ± 3.4 ^a (-26)
MnCl ₂ + Molasses		36 ± 1.9 ^{ac} (+13)	1.3 ± 0.10 ^{ac} (-13)	24 ± 2.1 ^c (-8)	2.2 ± 0.7 ^{ac} (-19)	110 ± 1.2 ^{ac} (-8)

- Values are expressed as Means ± SE (n= 6).

- Values between brackets show percentage of change from control.

- a: Significant (P≤ 0.05) when compared with the control group, b: Significant (P≤ 0.05) when compared with the corresponding RAD group, c: Significant (P≤ 0.05) when compared with the corresponding MnCl₂ group.

TABLE 4. Effect of sugarcane molasses administration (200mg/100g/day) on the concentration levels of iron (Fe), copper (Cu), zinc (Zn), manganese (Mn), and selenium (Se) in the epididymis of different animal groups.

Groups	Elements	Fe (µg/g)	Cu (µg/g)	Zn (µg/g)	Mn (µg/g)	Se (ng/g)
Control		22 ± 1.1	0.80 ± 0.05	19 ± 0.9	1.90 ± 0.02	99 ± 3
Molasses		25 ± 1.6 ^a (14)	0.84 ± 0.09 ^a (+5)	20 ± 2 (+5)	1.78 ± 0.04 (-6)	102 ± 5 (+3)
RAD		46 ± 1.8 ^a (109)	0.4 ± 0.13 ^a (-50)	10 ± 0.05 ^a (-47)	0.90 ± 0.01 ^a (-53)	45 ± 2 ^a (-55)
RAD+Molasses		28 ± 1.7 ^{ab} (+27)	0.6 ± 0.06 ^{ab} (-25)	16 ± 1.3 ^{ab} (-16)	1.69 ± 0.17 ^b (-11)	81 ± 4 ^{ab} (-18)
MnCl ₂		43 ± 2.1 ^a (+95)	0.5 ± 0.03 ^a (-38)	9 ± 0.7 ^a (-53)	3.09 ± 0.02 ^a (+63)	40 ± 2 ^a (-60)
MnCl ₂ +Molasses		27 ± 1.1 ^a (+23)	0.6 ± 0.01 ^{ac} (-25)	17 ± 2.0 ^c (-11)	2.30 ± 0.07 ^{ac} (+21)	114 ± 6 ^{ac} (+15)

- Values are expressed as Means ± SE (n= 6).

- Values between brackets show percentage of change from control.

- a: Significant (P≤ 0.05) when compared with the control group, b: Significant (P≤ 0.05) when compared with the corresponding RAD group, c: Significant (P≤ 0.05) when compared with the corresponding MnCl₂ group.

TABLE 5. Concentration levels of metals in sugarcane (blackstrap) molasses expressed in µg/g for all metals except Se (ng/g).

Elements	Concentration	Elements	Concentration
Fe	89 ± 2.9	Ca	886 ± 29
Cu	1.9 ± 0.5	Mg	2061 ± 30
Zn	7.5 ± 0.4	Se	1.8 ± 0.08
Mn	5.9 ± 0.3		

All values are expressed as mean ± SE of 6 samples.

Sperm analysis results

The results in Table 6 and Fig. 1 (A, B, C, D, E, F, G, H) illustrate the epididymal sperm abnormalities. The percentage of abnormal sperm was markedly increased in the rats post-radiation or Mn-toxicity (Fig. 2 B), compared

with the control animals. Moreover, findings demonstrated a significant decrease (P≤ 0.05) in sperm count (Fig. 2 A), motility% (Fig. 3 A) and viability % (Fig. 3 B) in the epididymis of the rats post- radiation or Mn-toxicity, compared with the control group.

TABLE 6. Effect of sugarcane molasses administration (200mg/100g b.wt./day) on some sperm morphologic features of different animal groups.

Groups	Abnormal sperm	Tailless head	Headless tail	Misshaped head	Hookless head	Two heads	Total (%)
Control		5 ± 0.1	4 ± 0.1	2 ± 0.1	3 ± 0.10	10 ± 0.11	12
Molasses		7 ± 0.1 ^a	3 ± 0.2	5 ± .0.1 ^a	4 ± 0.7	3 ± 0.16 ^a	11
RAD		25 ± 0.5 ^a	21 ± 1.5 ^a	16 ± 0.7 ^a	27 ± 0.4 ^a	16 ± 0.17 ^a	53
RAD + molasses		13 ± 0.3 ^{ab}	6 ± 0.2 ^b	9 ± 0.1 ^{ab}	13 ± 0.9 ^{ab}	15 ± 0.02 ^{ab}	28
MnCl ₂		35 ± 1.5 ^a	24 ± 0.1 ^a	14 ± 0.9 ^a	29 ± 0.5 ^a	28 ± 0.04 ^a	65
MnCl ₂ + molasses		19 ± 0.1 ^{ac}	11 ± 0.2 ^{ac}	8 ± 0.1 ^{ac}	10 ± 0.6 ^{ac}	13 ± 0.09 ^{ac}	31

- Values are expressed as Means ± SE (n= 6).

- Values between brackets show percentage of change from control.

- a: Significant (P≤ 0.05) when compared with the control group, b: Significant (P≤ 0.05) when compared with the corresponding RAD group, c: Significant (P≤ 0.05) when compared with the corresponding MnCl₂ group.

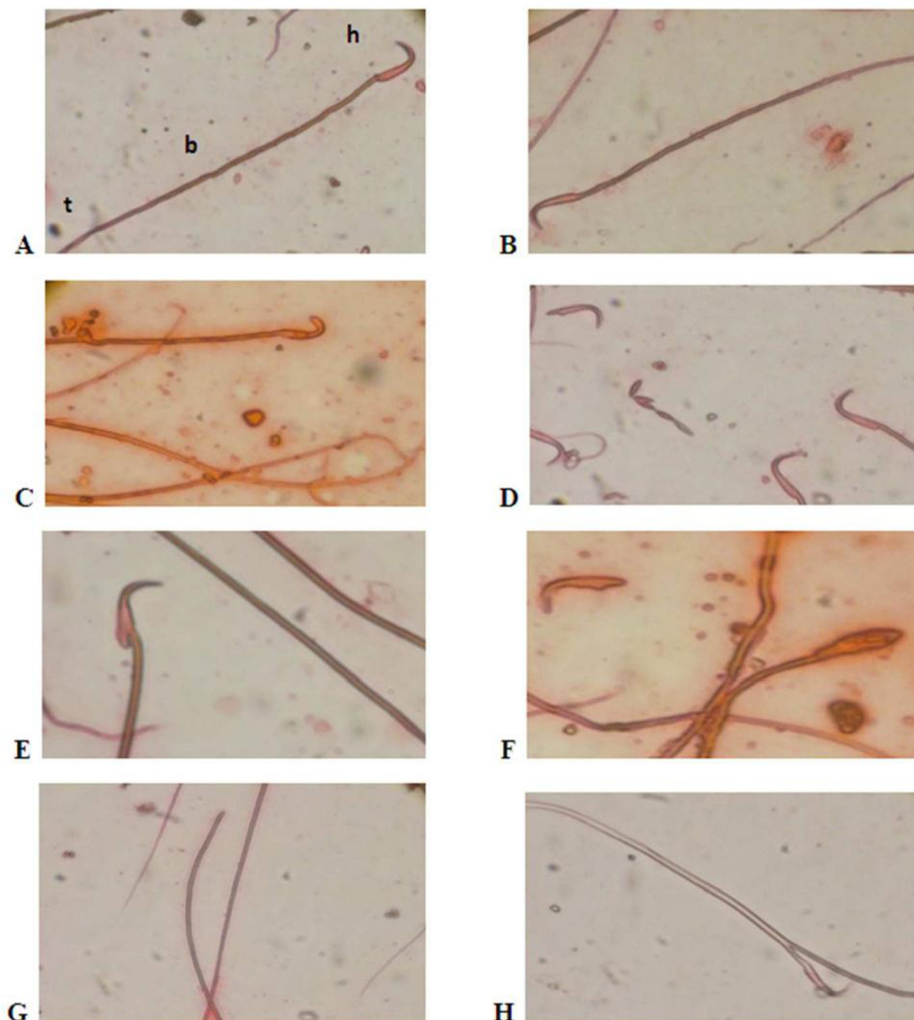


Fig. 1. Photomicrograph showing the effect of sugarcane molasses administration (200mg/100g /day) on the epididymal sperm abnormalities of different animal groups, A and B: Normal sperm with head (h), body (b) and tail (t); C: Abnormal sperm is represented by hook less head; D: Headless tail; E and F: Misshaped head; G: Tailless head; H: Two heads [magnification X400].

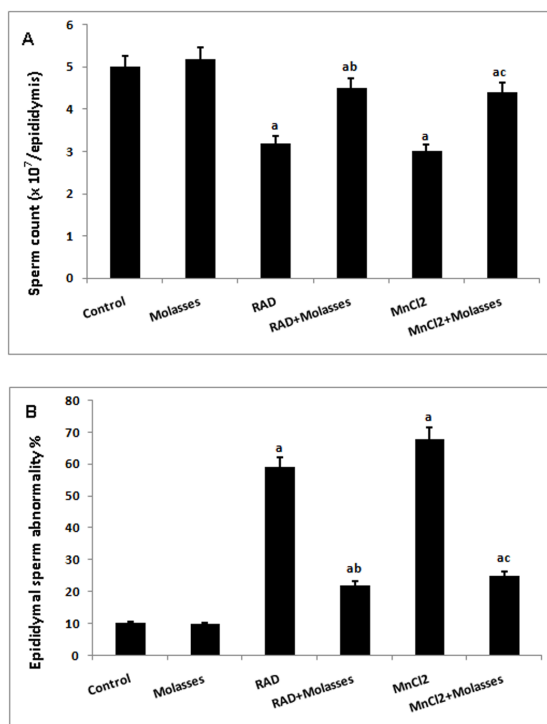


Fig. 2. Effect of sugarcane molasses administration (200mg/100g/day) on the epididymal sperm of different animal groups: A, showed the epididymal sperm count; B, showed the epididymal sperm abnormality % [Values are presented as the mean \pm SE of six rats in each group; a: Significant ($P \leq 0.05$) when compared with the control group, b: Significant ($P \leq 0.05$) when compared with the corresponding RAD group, c: Significant ($P \leq 0.05$) when compared with the corresponding MnCl₂ group].

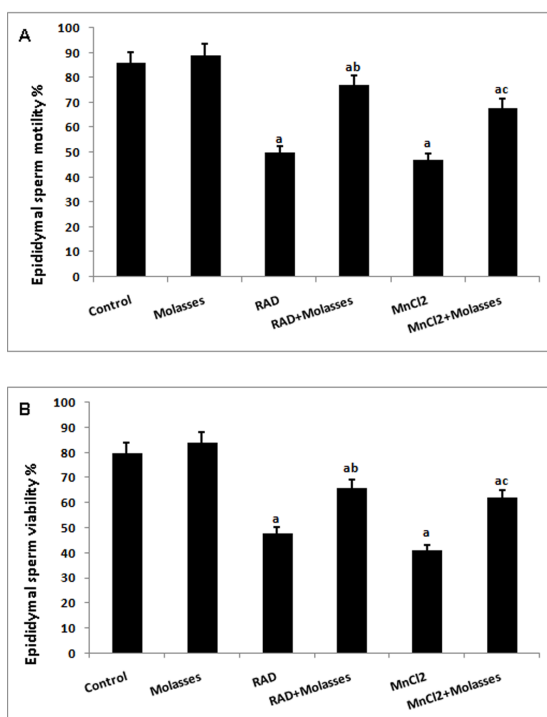


Fig. 3. Effect of sugarcane molasses administration (200mg/100g/day) on the epididymal sperm of different animal groups: A, showed the sperm motility %; B, showed the sperm viability % [Values are presented as the mean \pm SE of six rats in each group; a: Significant ($P \leq 0.05$) when compared with the control group, b: Significant ($P \leq 0.05$) when compared with the corresponding RAD group, c: Significant ($P \leq 0.05$) when compared with the corresponding MnCl₂ group].

Molasses treatment significantly elevated ($P \leq 0.05$) the sperm count, motility % and viability % accompanied by a significant decrease in the sperm abnormalities in the epididymis of rats (Fig. 2 and 3), compared to rats post-radiation or Mn-toxicity.

Discussion

Radiation or excessive manganese levels induce complex changes, including injury in multiple tissues of mammals (Shedid et al., 2019; Abdel-Magied et al., 2019; Zhang et al., 2003; Chen et al., 2006). The present study aims to elucidate the mitigating effect and mechanisms of blackstrap molasses to preserve the integrity of the testicular structure and functions in rats post-radiation or Mn-toxicity. The data showed an elevation of lipid peroxidation level associated with a markedly decreased level of TAC in the serum and testicular tissues. The elevation in lipid peroxidation might result from the free radicals produced in rats post-radiation or Mn-toxicity by attacking the lipids in cell membranes causing peroxidation of the highly polyunsaturated fatty acids that are abundant in the testicular tissue (Guerriero et al., 2014), leading to membrane disorganization, decrease in membrane fluidity, inactivation of critical membrane-bound receptors and enzymes (Mylonas & Kouretas, 1999). Furthermore, the end-products of lipid peroxidation, directly threaten the viability of tissues via their ability to covalently modify molecules that are critical to cell function. The free radicals are produced as a by-product of water radiolysis in the cell post-radiation toxicity (Spitz et al., 2004; Shedid et al., 2017) or produced from the increased manganese inside the cell post Mn-toxicity. The Mn has a tendency to bind to the inner mitochondrial membrane, cause the sequestration of manganese in the mitochondria and interferes with proper respiration, leading to excessive production of ROS by inhibiting the complex I (NADH: ubiquinone oxidoreductase) and the efflux of calcium (Zhang et al., 2003; Harischandra et al., 2019).

The elevation of lipid peroxidation may be explained by the reduction in cytochrome c oxidase activity associated with an elevation in the level of NOx. Brown, 2001 demonstrated that NO binds with cytochrome c oxidase inhibiting its ability to bind oxygen and caused an excessive amount of free radicals. The depletion in TAC might be attributed to the enhanced utilization of the antioxidant system as an attempt to detoxify

the free radicals generated post-radiation (Srinivasan et al., 2008) or Mn-toxicity (Hurley et al., 1984). The depletion might also result from the diminished activity of antioxidant metallo-elements-dependent enzymes (Cu, Zn and Mn-superoxide dismutase), catalase, metallothionein, glutathione, glutathione peroxidase and reductase as well as several selenoproteins (Sorenson, 2002), which might be related to the depletion in metals such as Zn, Cu and Se concentration levels recorded in this work.

In the current study, molasses treatment blocked the reduction of lipid peroxidation which was associated with a significant elevation in the level of total antioxidant capacity. This provides a possible explanation for the protective role of molasses potentially due to the fact that it contains a large amount of phenolic compounds and phenolic acids, mainly salicylic, p-hydroxybenzoic, vanillic cinnamic, coumaric, ferulic, chlorogenic acids and their derivatives and is also rich in flavonoids such as apigenin and luteolin, which exhibit antioxidants and free radicals scavenging activities (Guimarães et al., 2007; Asikin et al., 2016; Yu et al., 2016).

Our finding showed a significant increase of glucose levels in irradiated rats suggesting the possibility that radiation caused the inhibition of insulin secretion, diminished the utilization of glucose by irradiated tissue or increased gluconeogenesis (Ahlersova et al., 1988). Furthermore, the hyperglycemia may be attributed to endocrine abnormalities or to the pancreatic β -cells dysfunction that are weakly protected against the toxicity of free radicals, limiting the capacity for ROS inactivation. Also, Hurley et al. (1984) ascribed the elevation in the glucose level post Mn-toxicity to the disturbance in carbohydrate metabolism by direct effects of Mn on insulin release and gluconeogenesis. Interestingly, molasses treatment resulted in minimization of the increased serum glucose level. The result might be due to the abundance of phytochemicals and minerals in molasses that decreased the load of oxidative stress on pancreatic β cells, lowered the insulin responses and improved insulin sensitivity (Ellis et al., 2016). In addition, the decrease in glucose level might be explained by a delay in the carbohydrates digestion because molasses has a low index of glucose and inhibitory effect on α -amylase, α -glucosidase and glucose transporter activity in the gut (Kong et al., 2016; Zhang et al., 2008).

Trace elements act as cofactors of many enzymes and play an important role in the process of normal spermatogenesis and testicular development. They are indispensable elements in semen of male animals. In the current work, data displayed a depletion in the concentration levels of Cu, Zn, and Se associated with a sharp augmentation in Fe concentration levels in testicular tissue and epididymis of rats post radiation or Mn-toxicity. The depression in Cu, Zn and Se might be attributed to the de novo syntheses of antioxidant enzymes which prevent the formation of O_2^- and hydroxyl radicals (Sorenson, 1992).

The increase in the concentration level of iron post- radiation might result from the inability of bone marrow to utilize the iron available in the diet and released from destroyed cells (Fliedner et al., 1986), while Atkinson et al. (2005) demonstrated that oxidative stress resulting from radiation has been identified as the cause of ferritin degeneration, leading to iron homeostasis disorders with increased free iron levels. Another study by Kitb et al. (1990) indicated that the intracellular elevation of iron might be caused by the disorder of biological functions of red blood cells.

In testicular tissue and epididymis of rats post Mn-toxicity, the elevation in Mn level was also found by Cai et al. (2010) who demonstrated that Mn content in testis increased gradually along with the increase of Mn supplementation, inducing an increase in the expression of caspase-3 mRNA in germ cells. This in turn resulted in an increase in apoptosis of spermatogenic cells and testicular hormones damage.

Molasses treatment could counteract the disturbance in the minerals homeostasis. It is well documented that metals have a vital role in maintaining normal physiology. We detected large amounts of essential minerals in molasses including Ca, Fe, Cu, Mg, Zn, Se and Mn in agreement with Mohamed et al. (1989) who claimed that these metals acted as prosthetic groups for antioxidant metalloenzymes and metallothioneine, preventing accumulation of pathological concentrations of oxygen radicals. The oral administration of molasses post Mn-toxicity that blocked the increased concentration of manganese might be due to the kinetic competition mechanism between iron-rich molasses and manganese for a limited number of binding sites of the cells. This explanation is supported by Davis et al. (1992),

who stated that manganese is inversely related to dietary iron concentrations.

It is well documented that high levels of NO correlate negatively with tissue function (Ohta et al., 2007; Szabo & Thiemermann, 1994). In the present study, the elevation in NOx level of the rats post- radiation or Mn-toxicity might be attributed to the oxidative stress, which in turn, effects macrophages that promote the secretion of pro-inflammatory cytokines, NO, and eicosanoids (Abass et al., 2006). Another mechanism to interpret the elevation of NOx levels is the inflammatory testicular tissue caused by radiation (Shukla et al., 2009) or Mn-toxicity (Du et al., 2015).

The significant reduction in the activity of mitochondrial COX of testicular tissues recorded in the current study might be correlated to the increase of NO level, which binds with COX, inhibiting its ability to bind oxygen and the fact that this enzyme has a greater affinity for NO than for oxygen (Brown, 2001). In addition, the reduction might be due to the excess manganese that interferes with proper respiration, leading to the disturbance in the activities of mitochondrial enzymes (Kwik-Urbe et al., 2003).

In this work, it was shown that molasses treatment exhibited a suppressive effect on NO production and these results are in concordance with Hikosaka et al. (2006) who found that sugarcane extract reduced lipopolysaccharide-induced NO production in the peritoneal macrophages of rats. Moreover, molasses might have decreased the inflammatory responses induced by toxicity (Rahiman, 2011), lowering NO level.

A marked decrease in the serum of testosterone was observed post- radiation or Mn-toxicity as compared to control animals. The depletion might be caused by the inhibition of testicular steroidogenic enzymes such as delta 5,3 beta-hydroxysteroid dehydrogenase ($\Delta 5,3\beta$ -HSD) and 17 beta-hydroxysteroid dehydrogenase (17 β -HSD) responsible for the synthesis of testosterone (Jana et al., 2006). Furthermore, the drop in the level of Zn recorded in this study might be identified as a cause of the decrease in testosterone level, since Zn is essential for testosterone synthesis and spermatogenesis (Omu et al., 2015). Also, the selenium deficiency observed in this study might impair the ability of Leydig cells to synthesize

testosterone in response to LH (Erkekoglu et al., 2011).

The decrease of LH level post-radiation or Mn-toxicity might be caused by the damage in Leydig cells, where luteinizing hormone releasing hormone (LHRH) receptors are located (Sivakumar et al., 2006).

The epididymis is a highly compartmentalized organ with distinct regions (caput, corpus and cauda), its lumen is rich in inorganic ions and organic molecules secreted from its cells to create a unique microenvironment for sperm maturation and acquisition of fertility (Cornwall, 2009). The epididymis contains several metals for its normal functions. Consequently, the reduction in the levels of epididymal Zn, Cu, and Se post-radiation or Mn-toxicity may affect the vital function of epididymal tissue resulting in the alteration in its structural integrity, creating malformation in the stored sperms within it (Hurley, 1984). The decrease in epididymal Zn level might affect the stabilization of sperm chromatin (Bjorndahl & Kvist, 2011), sperm biomembrane and macromolecules integrity as well as sperm viability (James, 1992). The depletion in the concentration level of selenium might also be the reason for the abnormal sperm, in concordance with Shalini & Bansal (2008). Our conclusions that the altered levels of metal might be related to the presence of abnormal sperm associated with reduction in sperm motility and viability percentage is in agreement with Chatterjee et al. (1994), Missy et al. (2000), Zhang et al. (2006). Also, the increase in Fe levels might be the cause of lipid peroxidation in the epididymis and epididymal lumen as reported by others (Aitken et al., 1989).

Conclusion

Blackstrap molasses treatment can mitigate the severity of the oxidative stress induced by toxicity on testis and epididymis, thereby it could be used as a new natural mitigating agent post-radiation or Mn-toxicity.

Disclosure of interest: The authors report no conflicts of interests

References

Abass, A.K., Lichtman, A.H., Pillae, S. (2006) "Basic Immunology: Functions and Disorders of the

Immune System", (English) 4th ed.

Abdel-Magied, N., Abdel Fattah, S.M., Elkady, A.A. (2019) Differential effect of *Taraxacum officinale* L. (dandelion) root extract on hepatic and testicular tissues of rats exposed to ionizing radiation. *Mol. Biol. Rep.* **46**(5), 4893-4907.

Ahlersova, E., Ahlers, I., Molecanova, A. (1988) Serum glucose and liver glycogen in gamma irradiated rats. *Rad. Radiother.* **29**(2), 165-169.

Aitken, R.J., Roman, S.D. (2008) Antioxidant systems and oxidative stress in the testes. *Oxid Med. Cell Longev.* **1**(1), 15-24.

Aitken, R.J., Clarkson, J.S., Fishel, S. (1989) Generation of reactive oxygen species, lipid peroxidation and human sperm function. *Biol. Reprod.* **41**(1), 183-97.

Alahmar, A.T. (2019) Role of oxidative stress in male infertility. *Journal of Human Reproductive Sciences*, **12**(1), 4-18.

Al-Ani, I.M., Al-Khfaji, I.N., Fakhridin, M.B., Mangalo, H.H., Al-Obaidi, S.R. (2009) The effect of lead exposure of mice during pregnancy on the morphology of epididymal and testicular spermatozoa of their offspring. *International Medical Journal Malaysia*, **8**(1), 11-16.

Ali, S.E., El Gedaily, R.A., Mocan, A., Farag, M.A., El-Seedi, H.R. (2019) Profiling metabolites and biological activities of sugarcane (*Saccharum officinarum* Linn.) juice and its product molasses via a multiplex metabolomics approach. *Molecules*, **24**(5), pii: E934.

Asikin, Y., Takahashi, M., Mizu, M., Takara, K., Oku, H., Wada, K. (2016) DNA damage protection against free radicals of two antioxidant neolignan glucosides from sugarcane molasses. *J. Sci. Food Agric.* **96**(4), 1209-1215.

Atkinson, M.J., Spanner, M.T., Rosemann, M., Linzner, V., Muller, W.A., Gossner, W. (2005) Intracellular sequestration of ²²³Ra by the iron storage protein ferritin. *Rad Res.* **164**(2), 230-233.

Bjorndahl, L., Kvist, U.A. (2011) Model for the importance of zinc in the dynamics of human sperm chromatin stabilization after ejaculation in relation to sperm DNA vulnerability. *Syst. Biol. Reprod. Med.* **57**(1-2), 86-92.

- Brown, G.C. (2001) Regulation of mitochondrial respiration by nitric oxide inhibition of cytochrome c oxidase. *Biochim. Biophys. Acta.* **1504**(1), 46-57.
- Cai, X., Wang, G.X., Guo, H. (2010) Effect of manganese on Caspase-3 mRNA regulation in spermatogenic cell and the expression of vimentin on sertoli cell in rats. *Acta Anatomica Sinica.* **41**(3), 400-404.
- Chatterjee, J., De, K., Basu, S.K., Das, A.K. (1994) Alteration of spermatozoal structure and trace metal profile of testis and epididymis of rat under chronic low-level X-ray irradiation. *Biol. Trace Elem. Res.* **41**(3), 305- 319.
- Chen, M.T., Cheng, G.W., Lin, C.C., Chen, B.H., Huang, Y.L. (2006) Effects of acute manganese chloride exposure on lipid peroxidation and alteration of trace metals in rat brain. *Biol. Trace Elem. Res.* **110**(2), 163-177.
- Chyra-Jach, D., Kaletka, Z., Dobrakowski, M., Machoń-Grecka, A., Kasperczyk, S., Birkner, E., Kasperczyk, A. (2018) The associations between infertility and antioxidants, proinflammatory cytokines, and chemokines. *Oxidative Medicine and Cellular Longevity*, **2018**, 19-.
- Copp, R.P., Peebles, D.D., Soref, C.M., Fahl, W.E. (2013) Radioprotective efficacy and toxicity of a new family of aminothiol analogs. *Int. J. Radiat. Biol.* **89**(7), 485-492.
- Cornwall, G.A. (2009) New insights into epididymal biology and function, *Hum. Reprod. Updat.* **15**(2), 213-227.
- Davis, C.D., Malecki, E.A., Greger, J.L. (1992) Interactions among dietary manganese, heme iron, and nonheme iron in women. *Am. J. Clin. Nutr.* **56**(5), 926-932.
- Du, Y., Zhu, Y., Teng, X., Zhang, K., Li, S. (2015) Toxicological effect of manganese on NF- κ B/iNOS-COX-2 signaling pathway in chicken testes. *Biol. Trace Elem. Res.* **168**(1), 227-234.
- Ellis, T.P, Wright, A.G., Clifton, P.M., Ilag, L.L. (2016) Postprandial insulin and glucose levels are reduced in healthy subjects when a standardized breakfast meal is supplemented with a filtered sugarcane molasses concentrate. *Eur. J. Nutr.* **55**(8), 2365-2376.
- Erkekoglu, P., Zeybek, N.D., Giray, B., Asan, E., Arnaud, J., Hincal, F. (2011) Reproductive toxicity of di (2-ethylhexyl) phthalate in selenium-supplemented and selenium-deficient rats. *Drug Chem Toxicol.* **34**(4), 379-389.
- Flidner, T.M., Nothdurft, W., Calvo, W. (1986) The development of radiation late effects to the bone marrow after single and chronic exposure. *Int. J. Radiat. Biol. Relat. Stud. Phys. Chem. Med.* **49**(1), 35-46.
- Guan, Y., Tang, Q., Fu, X., Yu, S., Wu, S., Chen, M. (2014) Preparation of antioxidants from sugarcane molasses. *Food Chem.* **152**, 552-557.
- Guerriero, G., Trocchia, S., Abdel-Gawad, F.K., Ciarcia, G. (2014) Roles of reactive oxygen species in the spermatogenesis regulation. *Front Endocrinol. (Lausanne)*. **5**, 56.
- Guimarães, C.M., Gião, M.S., Martinez, S.S., Pintado, A.I., Pintado, M.E., LBento, L.S., Harischandra D.S., Jin, H., Anantharam, V., Kanthasamy, A., Kanthasamy, A.G. (2015) α Synuclein protects against manganese neurotoxic insult during the early stages of exposure in a dopaminergic cell model of Parkinson's disease. *Toxicol Sci.* **143**(2), 454-468.
- Harischandra, D.S., Ghaisas, S. Zenitsky, G. Jin, H. Kanthasamy, A. Anantharam V., Kanthasamy, A.G. (2019) Manganese-induced neurotoxicity: New insights into the triad of protein misfolding, mitochondrial impairment, and neuroinflammation. *Front Neurosci.* **13**, 654.
- Hikosaka, K., Koyama, Y., Motobu, M., Yamada, M., Nakamura, K., Koge, K., Shimura, K., Isobe, T., Tsuji, N., Kang, C.B., Hayashidani, H., Wang, P.C., Matsumura, M., Hirota, Y. (2006) Reduced lipopolysaccharide (LPS)-induced nitric oxide production in peritoneal macrophages and inhibited LPS-induced lethal shock in mice by a sugar cane (*Saccharum officinarum* L.) extract. *Biosci. Biotechnol. Biochem.* **70**(12), 2853-2858.
- Huang, D. Ou, B., Prior, R.L. (2005) The chemistry behind antioxidant capacity assays. *J. Agric. Food Chem.* **53**(6), 1841-1856.
- Huang, D., Chen, K., Lyu, T., Xia, B, Wang, F.C., Su, C., Zou, Y., Yang, X. (2015) Effects of chronic manganese sulfate toxicity test on myocardial

- ultrastructure and heart organ index of rats. *Zhonghua Lao Dong Wei Sheng Zhi Ye Bing Za Zhi*. **33**(5), 327-331.
- Hurley, L.S., Keen, C.L., Baly, D.L. (1984) Manganese deficiency and toxicity: Effects on carbohydrate metabolism in the rat. *Neurotoxicology*, **5**(1), 97-104.
- IAEA. (1980) Elemental analysis of biological Materials, International Atomic Energy Agency, IAEA, Vienna Technical Reports, 197, 379.
- James, C.E. (1992) "*Text Book of Surgical Physiology*", J. McLedingham and C. Mackay (Eds.), 4th ed., p. 8. Churchill Livingstone, London.
- Jana, K., Jana, S., Samanta, P.K. (2006) Effects of chronic exposure to sodium arsenite on hypothalamo-pituitary-testicular activities in adult rats: possible anestrogenic mode of action. *Reprod. Biol. Endocrinol.* **16**, 4-9.
- Kingston, H.M., Jassie, L.B. (1988) Microwave acid sample decomposition for elemental analysis. *J. Res. Natl. Bur. Stand.* **93**(3), 269-274.
- Kitb, M.A., El-Khatib, A.M., Morsey, A.A., Ramadan, M.I., El-Bassioni, A. (1990) Changes in mineral elements in some tissues of mice following neutron irradiation. *Isopenpaxis*, **26**, 300.
- Kong, F., Yu, S., Zeng, F., Wu, X. (2016) Phenolics content and inhibitory effect of sugarcane molasses on α -glucosidase and α -amylase in Vitro. *Sugar Tech.* **18**(4), 333-339.
- Kwik-Urbe, C.L., Reaney, S., Zhu, Z., Smith, D. (2003) Alterations in cellular IRP-dependent iron regulation by *in vitro* manganese exposure in undifferentiated PC12 cells. *Brain Res.* **973**(1), 1-15.
- Miranda, K.M., Espey, M.G., Wink, D.A. (2001) A rapid simple spectrophotometric method for simultaneous detection of nitrate and nitrite. *Nitric Oxide.* **5**(1), 62-71.
- Missy, P., Lanhers, M., Cunat, L., Joyeux, M. (2000) Effect of sub chronic exposure to manganese chloride on tissue distribution of three essential elements in rats. *Inter. J. Toxicol.* **19**, 313-321.
- Mohamed, A., Awadallah, R., Hassan, A. (1989) Determination of trace elements in Egyptian molasses by instrumental neutron activation analysis. *J. Radioanal. Nucl. Chem.* **129**(2), 453-457.
- Mohammed, A.T., Ebraheim, L.L.M., Metwally, M.M.M. (2018) Ebselen can protect male reproductive organs and male fertility from manganese toxicity: Structural and bioanalytical approach in a rat model. *Biomedicine & Pharmacotherapy*, **102**, 739-748.
- Mylonas, C., Kouretas, D. (1999) Lipid peroxidation and tissue damage. *In Vivo*, **13**(3), 295-309.
- Nayaka, H.M.A., Sathisha, U.V., Manohar, M.P., Chandrashekar, K.B., Dharmesh, S.M. (2009) Cytoprotective and antioxidant activity studies of jaggery sugar. *Food Chemistry*, **115**, 113-118.
- Ohkhawa, H., Ohishi, N., Yogi, K. (1979) Assay for lipid peroxidation in animal tissue by thiobarbituric acid reaction. *Anal. Biochem.* **95**(2), 351-8.
- Ohta, S., Matsuda, S., Gunji, M., Kamogawa, A. (2007) The role of nitric oxide in radiation damage. *Biol. Pharm. Bull.* **30**(6), 1102-1107.
- Omu, A.E., Al-Azemi, M.K., Al-Maghrebi, M., Mathew, C.T., Omu, F.E., Kehinde, E.O. (2015) Molecular basis for the effects of zinc deficiency on spermatogenesis: An experimental study in the Sprague-Dawley rat model. *Indian. J. Urol.* **31**(1), 57-64.
- Rahiman, F. (2011) The effects of artificial and natural sweeteners on various physiological systems, [dissertation]. [Western Cape]: Faculty of Science, University of the Western Cape, 148p.
- Rahiman, F., Pool, E.J. (2010) The effects of *Saccharum officinarum* (sugar cane) molasses on cytokine secretion by human blood cultures. *J. Immunoassay Immunochem.* **31**(2), 148-159.
- Santamaria, A.B., Sulsky, S.I. (2010) Risk assessment of an essential element: Manganese. *Journal of Toxicology and Environmental Health*, **73**, 128-155.
- Shalini, S., Bansal, M.P. (2008) Dietary selenium deficiency as well as excess supplementation induces multiple defects in mouse epididymal spermatozoa: Understanding the role of selenium in male fertility. *Int. J. Androl.* **31**(4), 438-449.
- Shedid, S.M., Saada, H.N., Eltahawy, N.A., Hammad,

- A.S. (2017) Curative role of pantothenic acid in brain damage of gamma irradiated rats. *Ind. J. Clin. Biochem.* **33**(3), 314-321.
- Shedid, S.M., Abdel-Magied, N., Saada, H.N. (2019) Role of betaine in liver injury induced by the exposure to ionizing radiation. *Environ Toxicol.* **34**(2), 123-130.
- Shukla, J., Chatterjee, S., Thakur, V.S., Premachandran, S., Checker, R., Poduval, T.B. (2009) L Arginine reverses radiation-induced immune dysfunction: the need for optimum treatment window. *Radiat. Res.* **171**(2), 180-187.
- Sivakumar, R., Sivaraman, P.B., Mohan-Babu, N., Jainul-Abideen, I.M., Kalliyappan, P., Balasubramanian, K. (2006) Radiation exposure impairs luteinizing hormone signal transduction and steroidogenesis in cultured human leydig cells. *Toxicol. Sci.* **91**(2), 550-556.
- Son, E.W., Lee, S.R., Choi, H.S., Koo, H.J., Huh, J.E., Kim, M.H., Pyo, S. (2007) Effects of supplementation with higher levels of manganese and magnesium on immune function. *Arch. Pharm. Res.* **30**(6), 743-749.
- Sorenson, J.R.J. (1992) Essential metalloelement metabolism and radiation protection and recovery. *Radiation Research Society*, **132**(1), 19-29.
- Sorenson, J.R.J. (2002) Cu, Fe, Mn and Zn Chelates offer a medicinal chemistry approach to overcoming radiation injury. *Current Med. Chem.* **9**(6), 639-662.
- Spitz, D.R., Azzam, E.I., Li, J.J., Gius, D. (2004) Metabolic oxidation/reduction reactions and cellular responses to ionizing radiation: A unifying concept in stress response biology. *Cancer Metastasis Rev.* **23**(3-4), 311-322.
- Srinivasan, M., Sudheer, A.R., Pillai, K.R., Kumar, P.R., Sudhakaran, P.R., Menon, V.P. (2008) Influence of ferulic acid on gamma-radiation induced DNA damage, lipid peroxidation and antioxidant status in primary culture of isolated rat hepatocytes. *Toxicology*, **228**(2-3), 249-258.
- Szabo, C., Thiemermann, C. (1994) Invited opinion: Role of nitric oxide in hemorrhagic, traumatic, and anaphylactic shock and thermal injury. *Shock.* **2**(2), 145-155.
- Takara, K., Matsui, D., Wada, K., Ichiba, T.Y., Nakasone, Y. (2002) New antioxidative phenolic glycosides isolated from kokuto non-centrifugal cane-sugar. *Biosci. Biotechnol. Biochem.* **66**(1), 29-35.
- Tietz, N.W. (1995) (Ed.) "*Clinical Guide to Laboratory Tests*", 3rd ed., W.B. Saunders, Co., Philadelphia, 580p.
- Trinder, P. (1969) Enzymatic colorimetric determination of glucose. *Ann. Clin. Biochem.* **6**, 27.
- World Health Organization (WHO) (1999) Laboratory Manual for the Examination of Human Semen and Sperm-Cervical Mucus Interaction, 4th ed. Cambridge: Cambridge University Press. 17p.
- Wyrobek, A.J., Bruce, W.R. (1978) The induction of sperm shape abnormalities in mice and humans. In: "*Chemical Mutagens, Principles and Methods for their Detection*". A, Hollander and F.J. De Serres (Eds.). Plenum Press, New York, 5, 285p.
- Yu, D., Chen, M.S., Yu, S.J. (2016) Effect of sugarcane molasses extract on the formation of 2- amino-1-methyl-6-phenylimidazo [4,5-b]pyridine (PhIP) in a model system. *Food Chem.* **197**(Pt A), 924-929.
- Zemjanis, R. (1977) Collection and evaluation of semen. In: "*Diagnostic and Therapeutic Techniques in Animal Reproduction*". William and Wilkins company, Baltimore, USA, 242p.
- Zhang, J.H., Liang, C., Ma, J.J., Niu, R.Y., Wang, J.D. (2006) Effects of sodium fluoride and sulfur dioxide on sperm motility and serum testosterone in male rats. *Fluoride*, **39**(2), 126-131.
- Zhang, J.H., Hongbin, Y., Gu, X.L., Liang C, Li, H., Wang, J. (2008) Changes in zinc, iron, copper contents in testis and epididymis of rats exposure to sodium fluoride and sulfur dioxide. *J. Herb. Med. Toxicol.* **2**, 5.
- Zhang, S., Zhou, Z., Fu, J. (2003) Effect of manganese chloride exposure on liver and brain mitochondria function in rats. *Environ Res.* **93**(2), 149-157.

التأثير المحسن لدبس قصب السكر ضد أشعه جاما أو المنجنيز المسبب سميته الخصيه في ذكور الجرذان البيضاء

ناديه عبد المجيد، ناهد عبد العزيز، شرين محمد شديد، امال غريب احمد
قسم بحوث البيولوجيا الإشعاعية - المركز القومي لبحوث و تكنولوجيا الأشعاع - هيئة الطاقة الذرية - القاهرة - مصر.

تهدف الدراسة الحالية إلى تقييم التأثير العلاجي لدبس قصب السكر (المولاس) على سمية وتلف نسيج الخصية المحدث بسبب التعرض للإشعاع أو المنجنيز الزائد. تم تقسيم الجرذان إلى ست مجموعات. المجموعة الأولى: الضابطه (control) والمجموعه الثانيه: الجرذان التي تناولت دبس السكر (200ملجرام/100جرام من وزن الجرذ) لمدة 7 أيام متتاليه والمجموعه الثالثه : الحيوانات التي تعرضت لجرعة واحدة من أشعه جاما قدرها 6 جراي والمجموعه الرابعه: الحيوانات التي تم تعريضها لأشعه جاما ثم تناولت المولاس لمدة 7 أيام متتاليه والمجموعه الخامسه : الجرذان التي تم حقنها بكلوريد المنجنيز كجرعة حادة (100ملجرام/كجم من وزن الجرذ) والمجموعه السادسه: الجرذان التي تم حقنها بالمنجنيز ثم المعالجه بالمولاس لمدة 7 أيام متتاليه.

أظهرت النتائج أن المعالجة بالمولاس لمدة سبعة أيام بعد التسمم بالإشعاع أو المنجنيز نتج عنها حدوث تحسن ملحوظ في المؤشرات الحيوية للتأكسد في مصل الدم وأنسجة الخصية للجرذان ويظهر ذلك في انخفاض مستويات المالونداهيد (MDA) وإجمالي النترات/ النترت (NO_x) مصحوبا بارتفاع ملحوظ في القدره الأجماليه لمضادات الاكسدة (TAC) وكذلك الأرتفاع الملحوظ في السيبتوكروم اوكسينز (COX) وكذلك التحسن الإيجابي في هرمونات الذكوره (Testosterone-FSH-LH) وأظهرت المعالجة أيضا بالمولاس اعاده توزيع للمعادن والعناصر الشحيحه داخل نسيج الخصيه والبريخ (testicular and epididymal tissue) وايضا تقلص التشويهاات بالحيوانات المنويه وزياده حيويتها والقدره على الحركه. ومن النتائج السابقه يمكن اعتبار دبس قصب السكر عامل تخفيف طبيعي جديد في إصابة الخصية الناجم عن السميته بالإشعاع أو المنجنيز.