

The Role of Intra-Arterial Chemotherapy in the Management of Retinoblastoma in Comparison with Other Modalities

GEORGE YASSA, M.Sc.; FAROUK HASSAN, M.D.; AYMAN ZAKARIA, M.D. and AMR A. NASSEF, M.D.

The Department of Interventional and Diagnostic Radiology, Faculty of Medicine, Cairo University

Abstract

Background: Retinoblastoma often presents with advanced intraocular disease and despite conventional treatment with intravenous chemotherapy (IVC) and external beam radiation therapy, may still require enucleation.

Aim of Study: To assess the efficacy of intra-arterial chemotherapy (IAC) in comparison with other modalities in the management of intraocular retinoblastoma.

Material and Methods: Twenty one patients with thirty intra ocular retinoblastomas were included in the study from November 2013 to September 2016. Chemo reduction followed by adjuvant consolidative treatment has replaced external beam radiotherapy as the primary modality of treatment for intraocular retinoblastoma. Patients failed to respond adequately to a standard systemic chemotherapy (i.e., carboplatin, vincristine, and etoposide) with or without other local therapies, are referred for intra-arterial chemotherapy (IAC) to avoid enucleation. The intervention was selective catheterization of the ophthalmic artery and injection of chemotherapy.

Results: The current commonly used treatments for retinoblastoma in our study were IVC and IAC, along with consolidated therapy based on tumor staging. For international classification of retinoblastoma (ICRB) grading, we found a significantly higher success rates for RTB cases treated with IAC as primary or adjuvant therapy compared to other treatment modalities which achieved 90% versus 73.6% for globe salvage, 80% vs 52.6% for solid tumor control, 75% vs 66.6% for subretinal seeds control, 66.7% vs 62.5% for vitreous seeds control respectively.

Conclusion: IAC may be superior to IVC for the treatment of retinoblastoma, with a higher overall success rate and higher globe salvage especially in group D retinoblastoma that failed to respond to systemic chemotherapy and destined for enucleation.

Key Words: Retinoblastoma – Intravenous chemotherapy, intra-arterial chemotherapy – Melphalan – Topotecan.

Introduction

RETINOBLASTOMA is the most common malignant intraocular tumor of childhood Almost 80%

Correspondence to: Dr. George Yassa, The Department of Interventional and Diagnostic Radiology, Faculty of Medicine, Cairo University

of the cases occur before 4 years of age, while 40% of cases occur during infancy. It is a curable cancer if detected at a stage in which it is still contained within the retina, subretinal space or vitreous [1].

The treatment of RTB has evolved substantially over the last few decades and currently, the most commonly employed approach for treating retinoblastoma in developed countries is chemoreduction, a strategy involving neoadjuvant systemic chemotherapy, followed by treatment with focal modalities, such as cryotherapy, laser treatment, or brachytherapy. Laser photocoagulation, cryotherapy, thermotherapy, and plaque radiotherapy remain vitally important in the management of selective RTB [2].

Enucleation, intravenous chemoreduction, intra-arterial chemotherapy, and EBRT are used for more advanced retinoblastoma. EBRT is usually reserved for last alternative treatment because of its numerous side effects and risks for late onset cancers in germline mutation children [3].

IAC was first described by Reese and colleagues in 1950 [4] and was later popularized by Abramson et al., [5]. The procedure involves directly injecting concentrated doses of chemotherapeutic drugs (melphalan, topotecan, or carboplatin) into the ophthalmic artery using a modern microcatheter (Fig. 1), to increase the concentration of chemotherapy drugs 10- to 30-fold at the tumor site. Consequently, the concentration of the drugs in the peripheral blood is minimal. Each eye requires an average of three treatment cycles and each cycle is planned at a 4-week interval. Successful treatment is indicated by a decrease in the size of the tumor. Remaining tumors can be eliminated by local therapies. Previous studies have reported the efficacy and safety of this approach. However, due to the high concentration of the chemical drugs that

are used in IAC, local complications are relatively high [6].

Establishing an accurate diagnosis and staging the disease are the first steps in the management of retinoblastoma to avoid mistreating the patient

with chemotherapy (Fig 2). The grouping is based on specific ophthalmoscopic features, such as the presence of vitreous or subretinal seeding. Each group has a corresponding risk of treatment failure and subsequent enucleation, with the lowest risk in group A and the highest risk in group E.

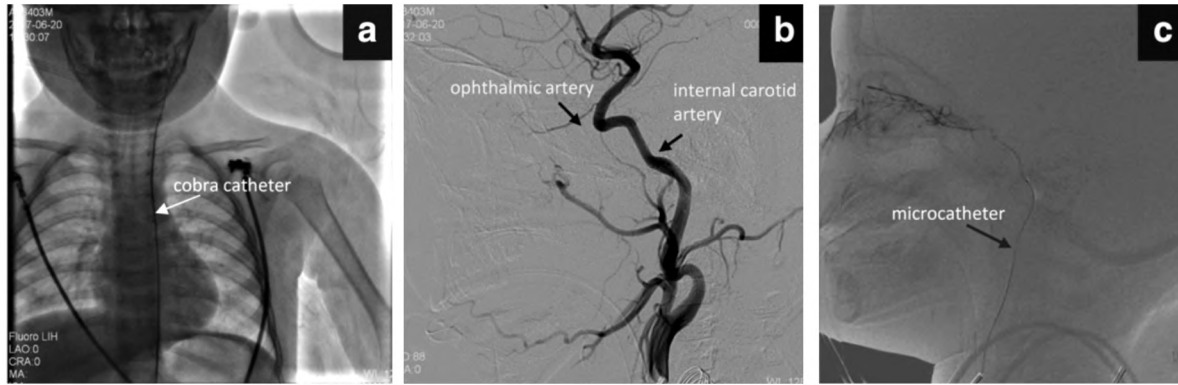


Fig. (1): The technique of intra-arterial chemotherapy (IAC) treatment. (A): An arteriogram was performed to indicate the takeoff of the ophthalmic artery from the internal carotid artery. (B): Using fluoroscopy and roadmap guidance, the microcatheter selectively catheterized the ophthalmic artery. (C): As soon as the microcatheter was in a stable position at the ostium of the ophthalmic artery, then pulse-inject drug (Abramson et al., 2012).

International Classification 2005 (intraocular) <small>Murphree AL, Ophth Clin N Am 18 (2005) : 41-53</small>		Reese-Ellsworth
<p>Group A</p> <ul style="list-style-type: none"> • Tumor \leq 3 mm in height • Tumor \geq 2 DD (3mm) from fovea AND \geq 1 DD (1. mm) from optic nerve • NO vitreous seeding • NO retinal detachment 		<p>Ia Ib IIIa IVb</p>
<p>Group B</p> <ul style="list-style-type: none"> • Tumor mm in height • Retinal detachment \leq 5 mm from edge of tumor OR no retinal detachment • NO vitreous seeding 		<p>Ia, Ib IIa, IIb IIIa, IIIb IVa, IVb</p>
<p>Group C</p> <ul style="list-style-type: none"> • Local, fine limited seeds (i.e. treatable by plaque) • AND/OR • Retinal detachment up to 1 quadrant 		<p>IVa IVb Va Vb</p>
<p>Group D</p> <ul style="list-style-type: none"> • diffuse vitreous and or subretinal seeding and or • Massive non discrete endo e ophytic disease • E ophytic disease and retinal detachment 1 quadrant up to total retinal detachment 		<p>IVa IVb Va Vb</p>
<p>Group E</p> <p>Presence of any one or more of :</p> <ul style="list-style-type: none"> • reversible neovascular glaucoma • Massive intraocular haemorrhage • Anterior to anterior vitreous face • Aseptic orbital cellulitis • Tumour touching the lens • diffuse infiltrating retinoblastoma • Phthisis or prephthisis 		<p>IVa IVb Va Vb</p>

Fig. (2): International Classification of retinoblastoma (Abramson et al., 2015).

Patients and Methods

The current work was a prospective analysis approved by the Faculty of Medicine Ethics committee of the Cairo University; cases were supplied by the Kasr El Ainy and Sheikh Zayed medical hospitals from November 2013 to September 2016, and have given informed consent for their used data. The study included 21 patients with 30 intraocular retinoblastoma, nine female (42.8%) and twelve males (57.2%) with age range at first presentation 5-24 months. Patients were classified according to the original International Classification for Intraocular Retinoblastoma.

Inclusion criteria:

For intra-arterial chemotherapy (IAC) were the presence of viable unilateral or bilateral retinoblastoma in patients aged 4 months or older either newly diagnosed or with partial remission/or relapse after focal therapies including cryotherapy, laser ablation, brachytherapy, and external beam radiotherapy, or the association of them, and/or systemic chemotherapy.

Exclusion criteria were the presences of any of the followings:

- Diffuse infiltrating retinoblastoma.
- Anterior chamber invasion.
- Secondary glaucoma.
- Vitreous hemorrhage.
- Optic nerve infiltration.
- Extra ocular disease extent/intracranial metastatic disease at gadolinium-enhanced magnetic resonance imaging (MRI) of the brain and orbits.
- Patients younger than 4 months and those with abnormal renal or hepatic function, congenital cerebral anomalies, coagulopathy or cardiopathy.

The primary end-point of this study protocol was stable ophthalmoscopic remission at 6 months. The secondary end-points were to avoid enucleation and preserve visual function as well as comparison between side effects and globe salvage rates between patients received IAC and other treatment modalities as IVC with/without other focal therapies.

Response was evaluated by fundoscopy, recorded as the percentage of the initial tumour volume: Complete response (CR) was reported when total regression of the tumour was achieved, very good partial response (VGPR) if regression was >50%, partial response (PR) if regression was <50%,

stable disease (SD) if tumor volume remained unchanged during treatment, and no response (NR) if tumor growth occurred.

Methodology in details:

All children with suspected retinoblastoma undergo a preliminary clinical evaluation in the clinic, at initial visit, consisting of visual acuity assessment, the pupillary examination, slit-lamp examination and indirect ophthalmoscopy. Subsequently, all patients undergo examination under anesthesia (EUA), and fundus photographs (RET-CAM) documenting all lesions. Once the diagnosis is established, the disease is staged based on the clinical and imaging findings, and intraocular retinoblastoma is classified in order to determine appropriate line of treatment.

The main line of treatment used in our study were:

Focal consolidative measures:

These are used in early intraocular tumors (ICRB A-D) following chemoreduction (two to three cycles) or primarily, and include the following options:

- *Laser photocoagulation:* It is employed for tumors not more than 2mm in height and located posterior to equator.
- *Trans pupillary Thermotherapy (TTT):* This is a method of tumor heating, where the aim is to achieve a temperature of 42-60 degrees, which is below the coagulative threshold. It is used for tumors not larger than 3mm in basal dimensions located at the posterior pole or mid-periphery and without any vitreous seeding. It has a synergistic effect with chemotherapy and may be used in conjunction with chemotherapy for large tumors.
- *Cryotherapy:* It is used to treat equatorial or peripheral small tumors that do not exceed 3 mm in diameter and 1.5mm in thickness.
- *Chemo thermotherapy:* All tumors situated at the posterior pole or in the mid-peripheral retina, with a diameter of 15mm or more without vitreous seeding and not suitable for treatment by cryo application or thermotherapy alone, may be treated using a combination of trans pupillary thermotherapy and chemotherapy.

Systemic intravenous chemotherapy:

Systemic chemoreduction is given to the patients in order to reduce tumor volume to allow for therapeutic measures to be more focused, effective and affecting less of the retinal tissues not harboring tumor anymore. It is also given to resolve retinal detachment, prevent new tumors, prevent

pinealoblastoma, preserve visual acuity and reduce second cancers.

The most common chemotherapy protocol used currently consists of vincristine, etoposide and

carboplatin (Table 1). Adequate tumor reduction requires two to six cycles of chemotherapy. Therefore; it is believed that less than six cycles of chemoreduction may not be sufficient to completely destroy sub-retinal seeds.

Table (1): Various chemotherapy protocols for retinoblastoma (Shields et al.,) [7].

Chemotherapy drug	Dose	Schedule
<i>Intravenous chemotherapy:</i>		
Carboplatin (C)	560mg/M2 in 120 cc/M2 D51/4NS IVSS over 60min	Day 0 of each cycle (18.6mg/kg for patients o-36 months of age)
Etoposide (E)	150mg/M2 in 150 cc/M2 D51/4NS IVSS over 60min	Days 0 and 1 of each course (5mg/kg for patients o-36 months of age)
Vincristine (V)	1.5mg/M2 IVSS over 15 minutes	Day 0 of each cycle (0.05mg/kg for patients o-36 months of age). Maximum vincristine dose not to exceed 2mg.
<i>Antiemetic drug:</i>		
Ondansetron	0.45mg/kg IVSS (maximum dose 24mg) prior to therapy	Days 0 and 1 of each cycle, with Dexamethasone 0.25mg/kg IVSS prior to therapy days 0 and 1 of each cycle.
Phenergen	0.5mg/kg p.o. h.s. on	Day 0 and then every 6h prn with emesis.
Diphenhydramine	1 mg/kg p.o. h.s.	Day 0 and then every 6h.

Therapy continues every 4 weeks for a total of six cycles. Prior to institution of each subsequent cycle, the absolute neutrophil count must be 4750 cells/ml and platelets must be 475 000 cells/ml.

The presence of retinal detachment did not preclude the use of IVC but caution is advised to withhold consolidation therapy with thermotherapy until the subretinal fluid resolves.

Intra-arterial chemotherapy (IAC):

Ophthalmic artery melphalan injection was performed following a published method by Abramson et al., [8]. All procedures were performed on an outpatient basis. Intravenous heparin was administered to prevent thrombosis, initially as a bolus of 75 IU/kg, followed by a continuous infusion of 10-15 IU/kg/hr. The cannulation was performed under general anaesthesia. The femoral artery was punctured to place a 4F introducer sheath (Terumo, Tokyo, Japan) in the primitive iliac artery. Following the Seldinger technique, a 4F (1.3-mm diameter) catheter (Vertebral; Terumo, Tokyo, Japan) and a 0.035-inch hydrophilic polymercoated guide wire (Radiofocus; Terumo) was used and placed in the cervical portion of the internal carotid artery ipsilateral to the treated eye. Using fluoroscopy and road mapping, the ophthalmic artery arising from the internal carotid artery was then superselectively catheterized using a flow-directed 1.5F microcatheter (Marathon Flow directed microcatheter, Covidien, Irvine, CA, USA) over a 0.08-inch hydrophilic Mirage microguide

wire (Covidien, Irvine, CA, USA) and inserted coaxially through the guide catheter and placed into the proximal portion (1-2mm) of the ophthalmic artery. The external carotid artery and its anastomoses were also selectively catheterized. The tip of the microcatheter has been manually modified in some cases according to the geometry of the internal carotid artery and ophthalmic arterial ostium.

Then, a superselective angiogram was performed to check the patency of the different branches of the ophthalmic artery and to check for choroido-retinal enhancement. In case of selection of the ophthalmic artery was not feasible other alternative techniques were used as selection of ipsilateral middle meningeal artery anastomosis to the orbit to determine whether the orbital branch was well developed.

Melphalan was reconstituted within 30min of the procedure, diluted in 30ml of saline and infused by pulsatile fashion using a pump during 30min at a rate of 1ml/min. Drug dosage was selected according to patient weight and age according to published criteria. Catheter position was checked during infusion. At the end of infusion, a third Omnipaque angiography verified the patency of the ophthalmic artery, the microcatheter was withdrawn and a fourth angiography verified cerebral arterial flow. Then, the guide and introducer catheters were removed, and the femoral artery compressed for 10min.

The child was monitored for 6 hours before discharge. A sterile dressing over the cannulation wound in the leg was maintained for 2 days. Oral aspirin (40mg) was advised for 2 weeks, and topical ophthalmic application of antibiotic-steroid ointment and cycloplegic eye drops was recommended for 2 weeks. Blood counts were performed prior to IAC and 1 and 10 days after each treatment.

Radiotherapy:

Retinoblastoma is a radiosensitive tumor and radiotherapy is used in various stages of retinoblastoma. For intraocular tumors, radiotherapy may be delivered as.

Plaque therapy (brachytherapy):

It is indicated in cases of peripheral tumors up to 15mm in diameter and 7-8-mm thick, possibly with localized vitreous invasion over the tumor.

External beam radiotherapy:

EBRT has mostly been replaced by aggressive chemoreduction and focal consolidative therapy for intraocular disease. But, it still remains useful in cases of very large or multiple tumors, unsuitable for other focal treatment modalities (thermotherapy, cryo-ablation, radioactive plaque or chemo-thermotherapy) and after failure of other techniques. A dose of 45 Gray is delivered to the target volume by two electron beams over 5 weeks, with fractions of 1.8 (for children under 12 months old) to 2Gy (for children over 12 months).

However, radiation damage to the ocular structures can be challenging to manage and may induce secondary cancers.

Enucleation:

Primary enucleation is the choice of treatment for unilateral group E and D intraocular retinoblastoma, or for cases of intraocular retinoblastoma that have failed on chemotherapy and conservative treatment. Further, enucleation is carried out in most cases of overt orbital disease regional extension, pre-auricular or cervical lymph node extension (stage III) following two to three cycles of neoadjuvant chemotherapy (NACT).

Results

Statistical analysis was performed for 21 patients with 30 intra ocular retinoblastoma divided on two study groups. First group of 10 patients scheduled for super selective ophthalmic artery infusion of melphalan (3 females, 7 males; age range at first treatment, 8-24 months) in comparison with data of second group of 11 patients (6 females,

5 males; age range at first treatment, 5-24 months) who underwent other modalities of treatment.

Bilateral retinoblastomas were found in 9 patients (43%) and unilateral lesions were found in 12 patients (57%). IAC was performed in 66.7% of bilateral cases (n=6) and 33.3% (n=4) of unilateral cases while other treatment options were the preferred treatment for 33.3% (n=3) of bilateral retinoblastoma and 66.7% (n=8) of unilateral retinoblastoma.

Regarding the grading of intra ocular retinoblastoma included in our study according to ICRB they were classified as follows: Group A represents 13.3% (n=4), group B 6.7% (n=2), group C 10% (n=3), group D 53.3% (n=16) and finally group E represents 16.7% (n=5).

IAC was performed in 62.5% (n=10 lesions) of group D retinoblastoma while the rest of group D, and other groups (A, B, C and E) were treated with other treatment options.

The primary treatment options in our study were; enucleation which represented 3.5% (n=1), IAC 3.5% (n=1), TTT represented 10% (n=3), intra venous systemic chemotherapy in combination with IAC represented 30% (n=9) and IVC in combination with other modalities represented 53% (n=16) (Table 2).

Concerning the adjuvant treatment modalities in our study, TTT was the most commonly used adjuvant treatment accounts for 50% (n=15 lesions) as well as was the preferred treatment modality in conjunction with IAC as 66.7% of cases treated with TTT underwent IAC (n=10 lesions). Other adjuvant therapies included EBR which represented 13.3% (n=4), brachytherapy 10% (n=3) while 26.7% of our cases (n=8) didn't receive any additional adjuvant therapies (Table 3).

After completion of treatment regimens for our patients comparison between our designed study groups for assessment of tumor response were as follows (with total 29 intra ocular retinoblastoma as one RTB was initially cured by enucleation and wasn't included in our study groups):

Complete response was achieved in 40% of RTB cases treated with IAC (n=4 lesions) compared to 26.3% (n=5) for RTB treated with other treatment options. Very good partial response (VGPR) represented 40% of RTB cases treated with IAC (n=4 lesions) compared to 26.3% (n=5) for RTB treated with other treatment options. Partial response

represented 10% (n=1) versus 21% (n=4) and No response 10% (n=1) versus 26.3% (n=5) in cases treated with IAC versus other modalities respectively (Table 4).

Cases of RTB treated with IAC achieved higher rates of globe salvage and solid tumor control compared with RTB cases treated with other modalities which represents 90% (9 out of 10 RTB) versus 73.6% (14 out of 19 RTB) and 80% (8 out

of 10 RTB) versus 52.6% (10 out of 19 RTB) respectively (Table 5).

Sub-retinal seeds and vitreous seeds were also controlled better in cases treated with IAC compared to the other study group as IAC achieved 75% (3 out of 4 RT) compared to 66.6% (6 out of 9 RTB) in sub-retinal seeds control and 66.7% (4 out of 6 RTB) versus 62.5% (5 out of 8 RTB) in vitreous seeds control (Table 5).

Table (2): Primary Treatment modalities.

	IAC	Others	Total	p-value
<i>Primary treatment:</i>				
Enucleation	Count 0	1	1	0.253
	%		3.5%	0.147
IAC	Count 1	0	1	
			3.5%	
IVC	Count 9	16	25	
	30%	53%	83%	
TTT	Count 0	3	3	
			10%	
Total	Count 10	20	30	
			100%	

Table (3): Adjuvant Treatment modalities.

	IAC	Others	Total	p-value
<i>Adjuvantive treatment:</i>				
Brachy therapy	Count 0	3	3	0.003
	%		10%	
EBR	Count 0	4	4	
			13.3%	
None	Count 0	8	8	
			26.7%	
TTT	Count 10	5	15	
	% within study group 100%	25%	50%	
Total	Count 10	20	30	

Table (4): Tumor response after treatment completion.

	IAC	Others	Total	p-value
<i>Tumour response:</i>				
CR	Count 4	5	9	0.631
	% within study group 40%	26.3%		0.614
VGPR	Count 4	5	9	
	% within study group 40%	26.3%		
PR	Count 1	4	5	
	% within study group 10.0%	21.0%		
NR	Count 1	5	9	
	% within study group 10%	26.3%		
Total	Count 10	19	29	

Table (5): Solid tumor control and Globe salvage.

Feature	Other modalities (n=19 RTB)	IAC (n=10 RTB)
<i>Tumor control (n/total (%)):</i>		
Solid tumor control (CR&VGPR)	10/19 (52.6%)	8/10 (80%)
Subretinal seed control	6/9 (66.6%)	3/4 (75%)
Vitreous seed control	5/8 (62.5%)	4/6 (66.7%)
<i>Globe salvage in each group of RB (n/total (%)):</i>		
Group A	4/4 (100%)	0/0 (0)
Group B	2/2 (100%)	0/0 (0)
Group C	3/3 (100%)	0/0 (0)
Group D	4/6 (66.7%)	9/10 (90%)
Group E	1/4 (25%)	0/0 (0)
Overall	14/19 (73.6%)	9/10 (90%)

Table (6): treatment complications.

	IAC	Others	Total	p-value
<i>Adverse events:</i>				
Palbebral edema	Count 2	0	2	0.136
	% from total 40%		28.6%	0.079
	% within study group			
Palbebral edema & mild ptosis	Count 1	0	1	
	% from total 20%		14.3%	
	% within study group			
Radiation retinopathy	Count 0	2	2	0.136
	% from total		28.6%	
Retinal atrophy	Count 1	0	1	
	% from total 20%		14.3%	
	% within study group			
Vascular spasm	Count 1	0	1	
	% from total 20%		14.3%	
	% within IAM			
Total	Count 5	2	7	
	(71.4%)	(28.6%)		

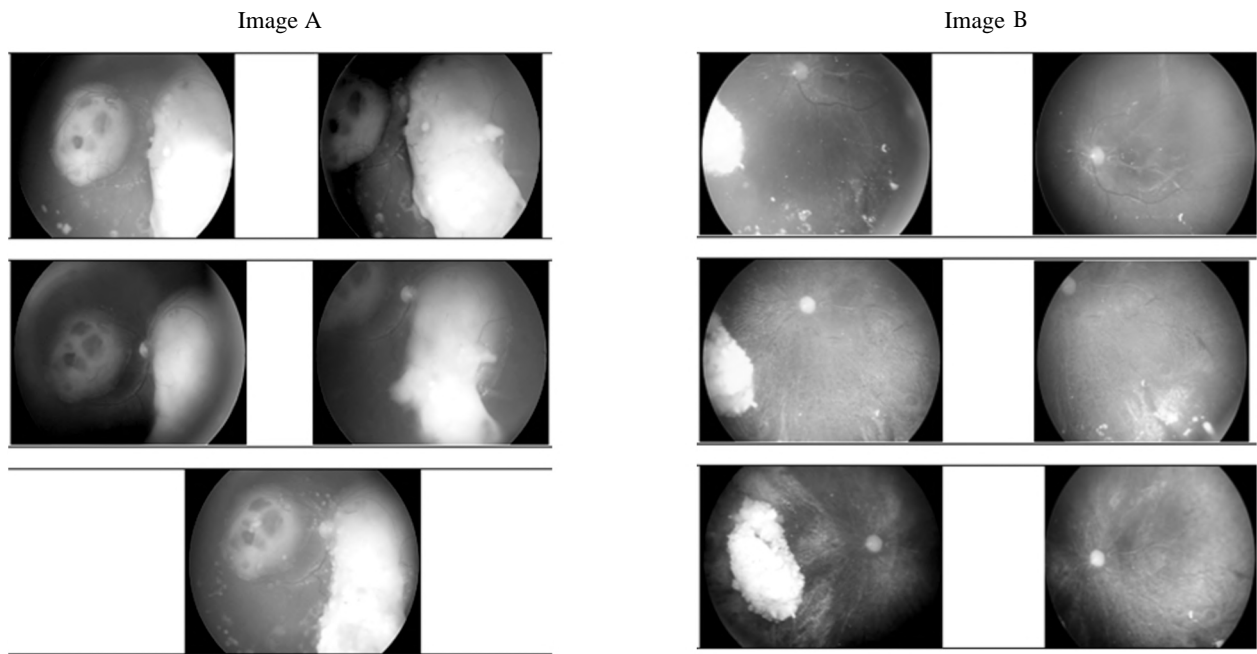


Fig. (3): Male patient 36 months old with bilateral retinoblastoma more advanced in left eye, age at first presentation 24 months with no history of inheritance. Image (A): Left eye stage E, 15mm in maximum diameter Retcam wide viewing angle images showing macular & nasal masses with diffuse seeds, tumor regressed following systemic chemoreduction, follow up for 11 months reveal recurrent resistant mass with active seeds prior to enucleation. Image (B): Right eye stage D RTB 10.5mm in maximal diameter retcam wide viewing angle images showing nasal RB with distant vitreous & subretinal seeds, regressed after 6 cycles chemotherapy and TTT with 3 sessions of IAC, follow-up for 11 months reveal stable mass. No treatment complications were noted.

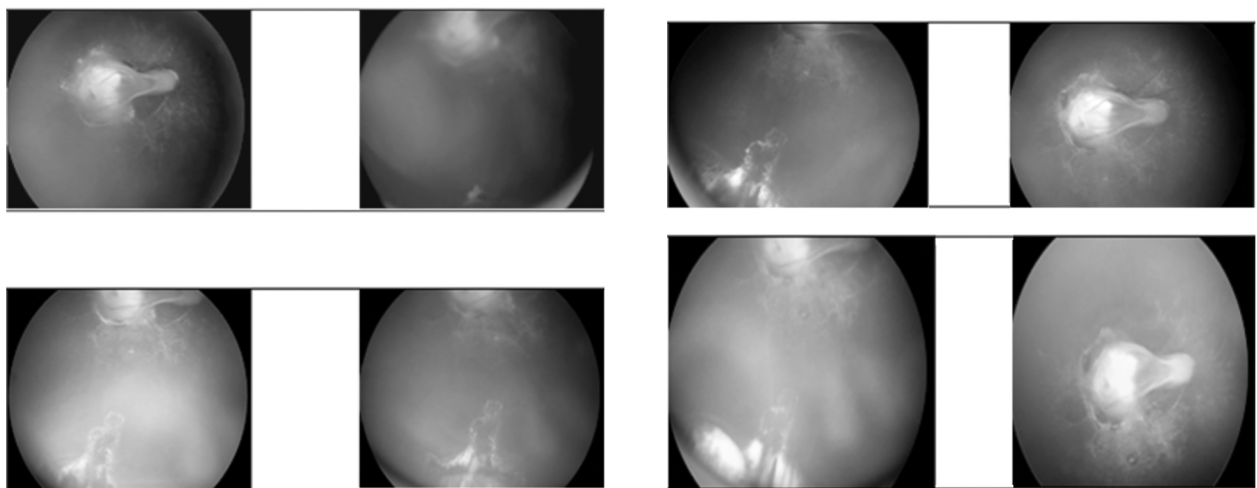


Fig. (4): Female patient 24 months old with unilateral retinoblastoma in right eye, age at first presentation 12 months. No history of inheritance. Retacam wide viewing angle images showing macular RB maximum diameter 7.5mm with inferotemporal vitreal and subretinal seeds, tumor regression is noted after 6 cycles of chemotherapy. After repeated TTT and cryotherapy 4 sessions, power 500 time 4 min per session. Follow-up for 12 months reveal regressed inactive stable mass with no residual seeds. No treatment complications were noted.

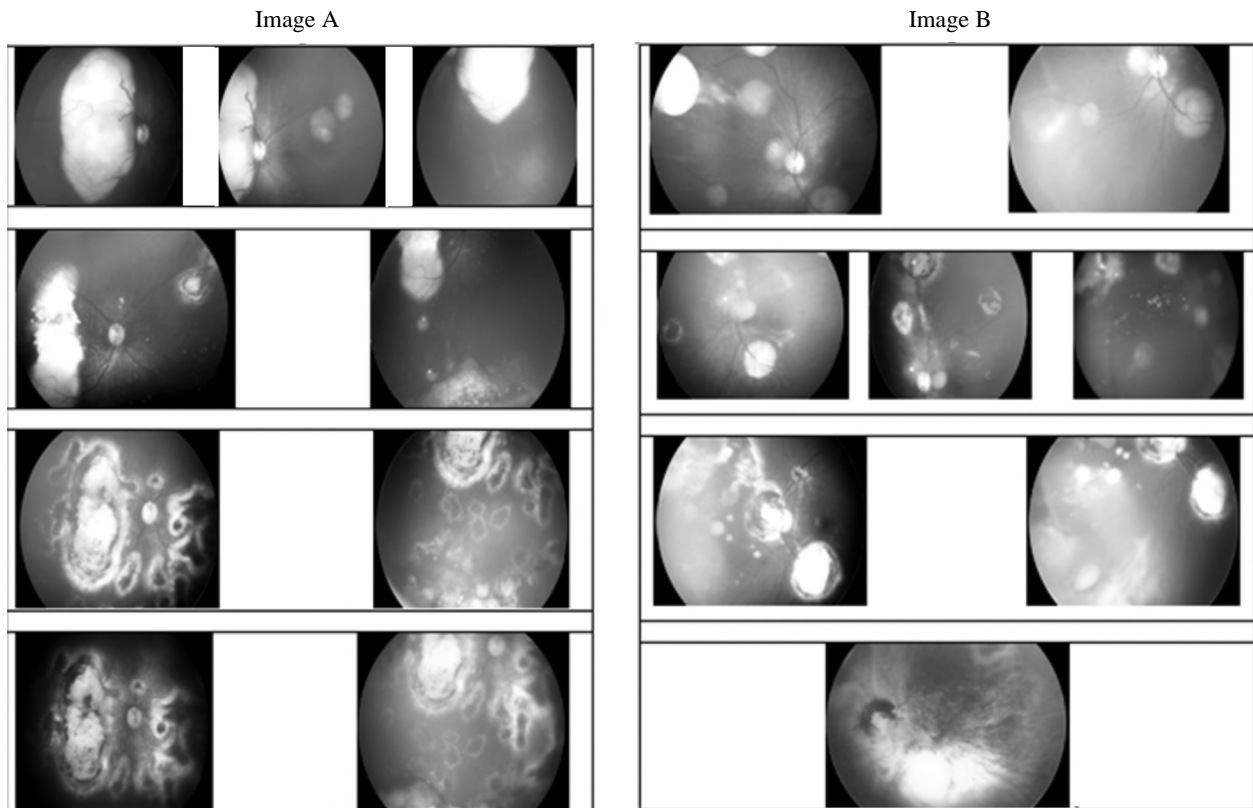


Fig. (5): Female patient 36 months old with bilateral retinoblastoma more advanced in left eye, age at first presentation 18 months. No history of inheritance. Image (A): Right eye stage A RTB: Retacam wide viewing angle images showing A: OD macular mass with superonasal smaller mass with sub-retinal & vitreal seeds initial treatment was TTT 6 sessions power 500 for 8 minutes follow-up for 12 months reveal regressed tumor with calcific seeds. Image (B): Left eye: Retacam wide viewing angle images showing OS stage D RTB with multiple masses with diffuse seeds. Initial treatment was 6 cycles chemotherapy with IAC 3 sessions follow-up for 12 months reveal regressed Inactive foci, treatment complication in left eye was mild palpebral edema.

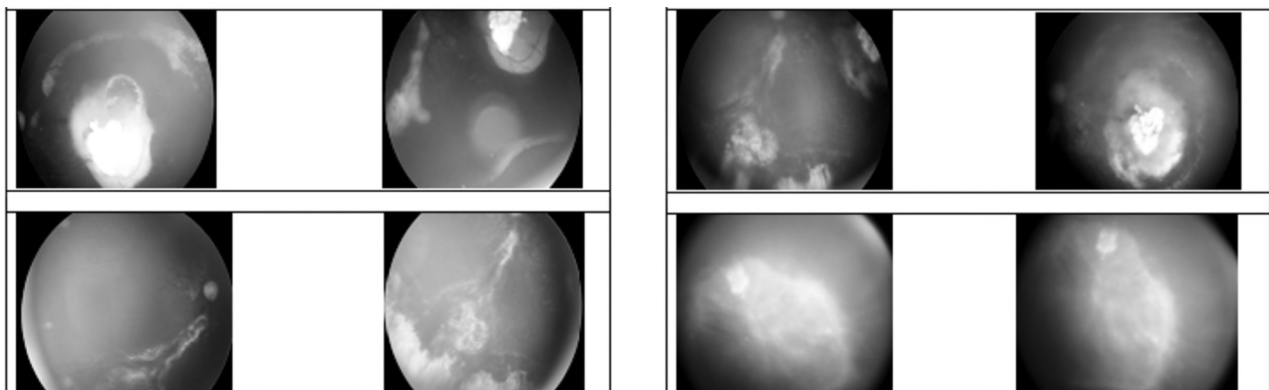


Fig. (6): Female patient 29 months old with unilateral retinoblastoma in right eye, age at first presentation 22 months. No history of inheritance. Retacam wide viewing angle reveal: Cystic macular RB 10 mm in diameter and 4.5mm from optic nerve with diffuse vitreous & sub-retinal seeds primary treatment 6 cycles chemotherapy, TTT 4 sessions power 500 for 5 minutes with 4 sessions IAC, follow-up for 6 months reveal flat scar with regressed tumor, disappearance of seeds and diffuse vitreous haze treatment complication was retinal atrophy.

Discussion

The current commonly used treatments for retinoblastoma include IVC and IAC, along with consolidated therapy based on tumor staging. For ICRB grading, we found a significantly higher globe salvage rate for group D eyes in patients who received IAC compared with those who received IVC, while no statistical differences were found in groups A,B,C, and E eyes. IAC was associated with a slightly higher overall success rate than IVC.

There is debate in the literature on the risks and benefits of IVC versus IAC for retinoblastoma management. In our analysis, we compared outcomes for retinoblastoma either newly diagnosed or with partial remission/or relapse after focal therapies including cryotherapy, laser ablation, brachytherapy, and external beam radiotherapy, or the association of them, and/or systemic chemotherapy.

To our knowledge, there are few studies to comparatively analyze the outcomes of IVC versus IAC for retinoblastoma based on the ICRB. Most previous series have explored single-regimen chemotherapy such as IVC alone or IAC alone, often focusing on results of the entire group as a first-line or second-line therapy.

Despite our attempt for uniformity in this cohort, there were important differences in the 2 groups (IVC vs IAC) because the eyes managed with IAC demonstrated a greater number of group D eyes (37.5% vs 62.5%), larger tumors with greater mean diameter (14 vs 18mm), and greater thickness (7 vs 10mm). Furthermore, in the IAC group, there was a greater frequency of tumor-related vitreous seeds (40% vs 60%) and total retinal detachment (25% vs 40%).

Even with these more advanced features, overall globe salvage and solid tumor control was higher in IAM group versus IVC achieving 90% vs 73.6% and 80% vs 52.6% respectively. IAC performed significantly better in globe salvage for group D eyes (90% vs 66.7%). This information regarding IAC superiority in salvaging group D eyes is important because most children with unilateral sporadic retinoblastoma present with group D or E eyes (Table 5).

Many of the group D eyes in database, particularly those evaluated before 1994, were managed with enucleation, but more recently, IVC and IAC have generally been employed. Based on this study, globe salvage for group D eyes can be achieved

with IAC in approximately 90% of properly selected cases, and enucleation can possibly be avoided. Most group E eyes have been and continue to be managed with enucleation, particularly because of relatively poor control with chemotherapy (IVC and IAC) and risks for metastatic disease [9].

These results were in agreement with Shields et al., that discussed IAC treatments in an array of patients, including unilateral and bilateral cases and first-line and second-line therapies. First-line IAC has been reported to provide 72% globe control. Second-line IAC has been shown to achieve globe salvage in 62% to 80% of eyes after initial IVC or other therapies [10].

In our study, the outcomes of globe salvage of groups A to C achieved 100% (Table 5); however results may not be reliable because of relatively small number of patients number included in our study. Overall, IAC had significant advantages over IVC in globe salvage of group D eyes and a better overall success rate. However, in approximately most of the group E eyes, treatment with IAC or IVC was unsuccessful, and the eyes eventually had to be removed.

Our patients treated with IAC underwent 2,3 or a maximum of 4 treatments per eye. We agree that the number of treatments should not exceed six to one eye, at a maximum dose of 6 mg/ml per treatment per eye or 8mg/ml per treatment in tandem therapy [11]. It has been demonstrated that the retinal function may persist and even recover after super-selective ophthalmic artery chemotherapy infusion [12].

Some studies have reported adverse events associated with IVC; however, most adverse events would disappear after symptomatic treatment. Rational chemotherapy drug use was essential to reduce the occurrence of adverse events in IVC treatment. In contrast, despite the advantages regarding tumor control, IAC carried a higher risk for potential local complications because of the high concentration of chemical drugs in the eye. The main temporary IAC related complications that have been reported include eyelid edema, blepharo-ptosis, forehead hyperemia, and forehead hyperpigmentation, with a mean remission of two weeks to four months [13].

Moreover, IAC-induced vascular events, including vascular injury, spasm, obstruction, and a series of related organ ischemic lesions, deserve attention. However we only encountered few complication regarding treatments modalities which occurred only in 7 patients and were as follow palberal

edema 28.6% (n=2), palpebral edema and mild ptosis 14.3% (n=1), radiation retinopathy 28.6% (n=2), retinal atrophy 14.3% (n=1) and vascular spasm 14.3% (n=1) (Table 6).

Finally, there is no universal agreement on the role of IAC versus IVC for retinoblastoma. An opinion reported from 4 major centers in Europe, South America, and North America found agreement in preference for IAC for unilateral retinoblastoma. However, there was disagreement for bilateral retinoblastoma because some preferred tandem IAC, whereas others favored IVC. Furthermore, IAC is only available at specialized centers. Internationally, particularly in developing nations, the role of IAC remains negligible because of technical and financial concerns [14].

Conclusion

IAC has emerged as a remarkably effective strategy for treating retinoblastoma. IAC is effective as both primary and secondary treatment. Given its reported safety and high efficacy, it is expected that IAC will replace conventional strategies and will become a first-line option, even for tumors amenable to other strategies. IAC has allowed eyes that would have been enucleated in the past to be salvaged, with the vast majority of treated patients today retaining their eyes.

References

- 1- BAKHSHI S. and BAKHSHI R.: Genetics and management of retinoblastoma. *Journal of Indian Association of Pediatric Surgeons*, 12: 109-15, 2007.
- 2- MARTIN N.E., KIM J.W. and ABRAMSON D.H.: Fibrin Sealant for Retinoblastoma: Where Are We? *Journal of Ocular Pharmacology & Therapeutics*, 24: 433-8, 2008.
- 3- SHIELDS C.L. and SHIELDS J.A.: Retinoblastoma management: Advances in enucleation, intravenous chemoreduction, and intra-arterial chemotherapy. *Curr. Opin. Ophthalmol.*, 21: 203 -212, 2010.
- 4- REESE A.B., HYMAN G.A., MERRIAM G.R. Jr., FORREST A.W. and KLIGERMAN M.M.: Treatment of retinoblastoma by radiation and triethylenemelamine. *AMA Arch. Ophthalmol.*, 53 (4): 505-13, 1954.
- 5- ABRAMSON D.H., MARR B.P., DUNKEL I.J., BRODIE S., ZABOR E.C., DRISCOLL S.J. and GOBIN Y.P.: Intra-arterial chemotherapy for retinoblastoma in eyes with vitreous and/or subretinal seeding: 2-year results. *Br. J. Ophthalmol.*, 96: 499-502, 2012.
- 6- ABRAMSON D.H., FABIUS A.W., ISSA R., FRANCIS J.H., MARR B.P., DUNKEL I.J. and GOBIN Y.P.: Advanced unilateral retinoblastoma: The impact of ophthalmic artery chemosurgery on enucleation rate and patient survival at MSKCC. *PLoS One.*, 10: e0145436.
- 7- SHIELDS C.L., KALIKI S., AL-DAHMAH S., ROJANAPORN D., LEAHEY A., GRIFFIN G., et al.: Management of advanced retinoblastoma with intravenous chemotherapy then intra-arterial chemotherapy as alternative to enucleation. *Retina.*, 33 (10): 2103-9. doi: 10.1097/IAE.0b013e318295f783PMID: 23873161, 2013.
- 8- ABRAMSON D.H., DANIELS A.B., MARR B.P., FRANCIS J.H., BRODIE S.E., DUNKEL I.J. and GOBIN Y.P.: Intra-arterial chemotherapy (ophthalmic artery chemosurgery) for group D retinoblastoma. *PLoS One.*, 11: e0146582.
- 9- C.L. SHIELDS, S. Kaliki, D. ROJANAPORN, S. AL-DAHMAH, C.G. BIANCIOTTO, and J.A. SHIELDS: "Intravenous and intra-arterial chemotherapy for retinoblastoma: what have we learned?" *Current Opinion in Ophthalmology.*, vol. 23, no. 3, pp. 202-209, 2012.
- 10- SHIELDS C.L., MANJANDAVIDA F.P., LALLY S.E., PIERETTI G., AREPALLI S.A., CAYWOOD E.H., JABBOUR P. and SHIELDS J.A.: Intra-arterial chemotherapy for retinoblastoma in 70 eyes: Outcomes based on the international classification of retinoblastoma. *Ophthalmology*, 121: 1453-60, 2014.
- 11- ABRAMSON D.H., DUNKEL I.J., BRODIE S.E., MARR B. and GOBIN Y.P.: Bilateral superselective ophthalmic artery chemotherapy for bilateral retinoblastoma: Tandem therapy. *Arch. Ophthalmol.*, 128: 370-372, 2010.
- 12- CHEN M., JIANG H., ZHANG J., SHEN G., JIANG Y., LI H. and LIU Z.: Outcome of intraarterial chemotherapy for retinoblastoma and its influencing factors: A retrospective study. *Acta. Ophthalmol.*, 95: 613-8, 2017.
- 13- FABIAN I.D., NAEEM Z., STACEY A.W., CHOWDHURY T., DUNCAN C., REDDY M.A. and SAGOO M.S.: Long-term visual acuity, strabismus, and nystagmus outcomes following multimodality treatment in group D retinoblastoma eyes. *Am. J. Ophthalmol.*, 179: 137-44, 2017.
- 14- DIMARAS H., CORSON T., COBRINIK D., et al.: Retinoblastoma. *Nature Reviews Disease Primers*. 1502. Published online August 27, 2015

دور الحقن الشرياني للعلاج الكيماوي في علاج ورم الشبكية في الأطفال مقارنة بأساليب العلاج الأخرى

على مدار السنوات الماضية، شهد علاج ورم الشبكية في الأطفال تحولاً كبيراً للعلاج المحافظ عن العلاج الإشعاعي والكيماوي. في منتصف تسعينات القرن الماضي، أدخل العلاج الكيماوي عن طريق الوريد، وحقق معدلات عالية بشكل غير متوقع في السيطرة على الورم والحفاظ على العين في أكثر من ٩٠٪ في العينين ذات المراحل الأولى (مجموعة أ، ب و ج) وحوالي ٥٠٪ لمن لديهم مراحل متأخرة (مجموعة د و ه).

ظل إستئصال العين علاجاً مهماً لعلاج الحالات الأكثر تقدماً (المجموعة ه) ذو الإنتشار الكبير في العين أو حالات الأكثر عرضة لإنتشار الثانويات. في منتصف إلى أواخر الألفينات، ظهر الحقن الكيماوي عن طريق الشريان كعلاج لورم الشبكية في الأطفال وحقق نجاحاً في السيطرة على الحالات المتقدمة نسبياً والتي كانت تستلزم عادة إستئصال العين. على مدى السنوات الطويلة إستخدم العلاج الكيماوي عن طريق الوريد، وفي السنوات الماضية إستخدم الحقن الكيماوي عن طريق الشريان. لا زال هناك جدل عن ما هو العلاج الأنسب للحالات الأحادية والحالات الثنائية لأورام الشبكية في نفس المريض.

إستخلاصاً من ذلك نؤكد على أن الحقن الكيماوي عن طريق الشريان لمرضى ورم الشبكية في الأطفال هو آمن متى تم بواسطة أطباء الأشعة التداخلية لأوعية المخ والأعصاب الذين يجيدون تشخيص وعلاج أمراض الأوعية الدموية بالرأس. دواء الميلفان المحقون في الشريان المغذى للعين يتيح الحفاظ على عيوناً كثيرة كان يتم إستئصالها بالرغم من المعدلا المنخفضة للآثار الجانبية لإستخدام هذه التقنية وقد تم ملاحظة نتائج أفضل في العينين المعالجة بعد الشفاء الجزئي أو بعد الأنتكاسة عن العينين التي تعالج للمرة الأولى والتي تستفيد أكثر من إضافة أدوية أخرى بجانب الميلفان.