

## An Analytic Study of Nerve Regeneration between End-to-End and End-to-Side Neurorrhaphy: An Experimental Study in Rats

SHERIF M. AMR, M.D.\*; ASHRAF N. MOHARRAM, M.D.\*; AYMAN M. MANSOUR, M.D.\*; MOAMEN S. KHALAF, M.Sc.\*\*; MOHAMED H.E. ABORAS, M.Sc.\*\*; BAHAAELDIN S. ABDELWAHED, M.Sc.\*\*; OMAR A. SHALABY, M.Sc.\*\* and REDA A. SHETA, M.Sc.\*\*

*The Department of Orthopedic Surgery\*, Microsurgery Lab, the Animal House Lab and the Department of Histology\*\*, Faculty of Medicine, Cairo University*

### Abstract

**Background:** In peripheral nerve injury, end-to-side neurorrhaphy involves cooptation of the distal stump of a transected nerve to the trunk of an adjacent donor nerve. It has been proposed as an alternative technique when the proximal stump of an injured nerve is unavailable or the nerve gap is too long to be bridged by a nerve graft. End-to-side neurorrhaphy was first documented in the 19th century [1]. However; the technique has not been a clinical routine for almost a century. In early 1990s, Viterbo et al., [2] demonstrated successful nerve regeneration and muscle re-innervation in a rat end-to-side neurorrhaphy model.

**Aim of Study:** A prospective experimental study was done to study, evaluate, and compare the histological results of neurorrhaphy in rats using end-to-end, end-to-side and end-to-side long contact neurorrhaphy. Thereby presenting a different techniques and for the first time a comparative analytic study for the end-to-side long contact neurorrhaphy.

**Material and Methods:** The experiment carried out on 74 male rats, divided into three groups. After two months all rats were evaluated histologically with immunohistochemistry staining.

**Results:** The repaired grafts from the three groups were obtained from the animals for histological examination.

**Conclusion:** End-to-side neurorrhaphy presently does not replace a sound primary nerve suture. It should be seen as an excellent, viable option when planning to address difficult peripheral nerve injuries.

**Key Words:** End-to-end neurorrhaphy – End-to-side neurorrhaphy – Long contact – End-to-side neurorrhaphy – Histological analysis.

### Introduction

**END-TO-SIDE** neurorrhaphy was first documented in the 19th century [1]. However, the technique

has not been a clinical routine for almost a century. In early 1990s, Viterbo et al., [2] demonstrated successful nerve regeneration and muscle re-innervation in a rat end-to-side neurorrhaphy model. Immunocytochemical staining and retrograde nerve tracing confirmed the presence of regenerated axons in the attached nerve [3]. Most studies favor direct end-to-end neurorrhaphy in favor of other techniques. End-to-end nerve repair, when circumstances allow, yields the best results regardless of timing [4]. As a continuation of previous serial clinical studies done by the two senior authors of this study [5,6,7] in establishing end-to-side neurorrhaphy in brachial plexus injuries, we attempted to focus on histological outcome of end-to-side neurorrhaphy techniques.

### Patients and Methods

From May 2013 till July 2016 this prospective animal experimental study was carried out on 74 male rats weighing on average 100-150 grams. Out of 74 rats 14 rats were excluded; 8 died early and late post operatively and 6 were excluded due to surgical site auto injury and destruction by the rats themselves. All rats included were free of visible signs of infection through their lives at the time of the experiment.

**Anesthesia:** An intraperitoneal injection of a Ketamine-Xylocaine solution (90mg/kg-10mg/kg) was used. Supplemental doses may be used, over the course of surgical procedure to maintain anesthesia.

**Rats grouping:** The animals were divided randomly into three groups with 20 animals per group according to the operative procedure:

**Correspondence to:** Dr. Sherif M. Amr, The Department of Orthopedic Surgery, Microsurgery Lab, the Animal House Lab, Faculty of Medicine, Cairo University

- *Group 1:* End-to-end neuroorrhaphy between the proximal end of femoral nerve and distal end of the sciatic nerve (n=20).
- *Group 2:* Standard end-to-side neuroorrhaphy between the proximal end of femoral nerve and distal end of the sciatic nerve (n=20).
- *Group 3:* Long contact end-to-side neuroorrhaphy between the proximal end of femoral nerve and distal end of the sciatic nerve (n= 20).

*Surgical procedure:* Rats were immobilized in the supine position on a corkboard. By making 3-4cm length incision (Fig. 1) started from the mid inguinal point downwards and laterally on the thigh. The femoral nerve was exposed, followed by muscle splitting to localize and dissect the sciatic nerve.

Using 9/0 nylon sutures, the three different techniques were used to repair the cut nerves.

*Surgical steps:* It usually takes about 40- 60 minutes to finish the surgical procedure including the anesthesia time. At first we identified the intact femoral and sciatic nerves. Then the femoral nerve is dissected free, as well as the sciatic nerve. The cut proximal femoral nerve is sutured to the distal cut femoral nerve either:

- End-to-end.
- End of femoral nerve to side of the sciatic nerve.
- Long contact femoral to side of sciatic nerve (Fig. 2).

The prepared nerves are now sutured together, making sure that the neuroorrhaphy and the nerves are not impinge on any structures, not kinked, and free of any tension when attached to each other. Great care was taken not to damage the underlying axons while doing epineural widow in end-to-side and long contact end-to-side techniques. Three to four (with only one stitch end were kept long about 1 cm to make latter identification easy) epineural sutures using 9/0 Prolene are placed in position, suturing the proximal and distal nerves using 2.5 X-3 X microscope magnification.

Sciatic nerve cut Proximal. (postponing this step making suturing of end-to-side and long contact end-to-end more easy). The wound is closed interrupted with prolene 4/0.

After a period of two months the rats were sacrificed to retrieve the nerve segment proximal and distal to repair. Nerve segment were labeled with prolene 3/0 at both ends with identifying

distal from proximal ends with different stitches length. Afterwards specimens were sent for histological analysis.

*Histological analysis:* The repaired grafts from the three groups were obtained from the animals for histological examination. The harvested nerves were cut transversely 1cm distal to the repair and they were fixed in 10% formol saline, washed then gradually dehydrated. Tissues were then cleared in xylene followed by impregnation then embedding to obtain paraffin blocks. These were cut to obtain 5-6  $\mu$ thick sections to be stained by:

- Hematoxylin and Eosin.
- Immunohistochemically staining for: Neurofilaments protein antibodies (catalog number is MS-359-R7). Neurofilaments are intermediate filaments of neurons and their processes. It is protein triplets composed of three major subunits of MW 68kDa, 155kDa, and 200kDa. It labels neurons, neuronal processes, and peripheral nerves.

*Immunostaining:* Paraffin sections were deparaffinized, rehydrated and washed. After washing, inactivation of endogenous peroxidase was performed and sections were washed again. No pre-treatment was required for retrieving the epitopes. The primary antibody for neurofilament protein was applied over sections for 30 minutes. Immunohistochemical staining was completed by the use of ultravision detection system ABC kit (catalogue number TP- 015- HD). DAB (3,3 di-aminobezidinetetrahydrochloride) as chromogen was applied for each slide and the slides were incubated for 5 minutes at room temperature. Counterstaining was done using Mayer's Hematoxylin (catalogue number TA- 060- MH). Negative control was used as reference; this was done by following the steps of immunostaining but omitting the step of the primary antibody. Positive immunoreactivity appeared as brown deposits.

*Morphometric study:* The area of positive immunohistochemical staining was measured in the neurofilament sections. This was performed for the specimens from all animals of all groups involved in the study. Measurements were done in five non overlapping fields at X 400 magnification in a field area of 7286.783  $\mu$ m<sup>2</sup> for every subject using Leica Qwin500C ® image analyzer computer system (England) present in Histology Department, Faculty of Medicine, Cairo University. Images were captured live on the screen from sections under a light microscope (Olympus ® BX-40, Olympus Optical Co.Ltd., Japan). Binary images were generated by color thresholding for the brown

color then the area of these binaries is measured by the Lecia Qwin @500 software. This is done for every field of the five fields for each subject to obtain a mean area for each. Mean area percent is the relation between the areas of positivity marked by the binary images to the field area which is 7286.783  $\mu\text{m}^2$ . Results obtained were subjected for statistical analysis.

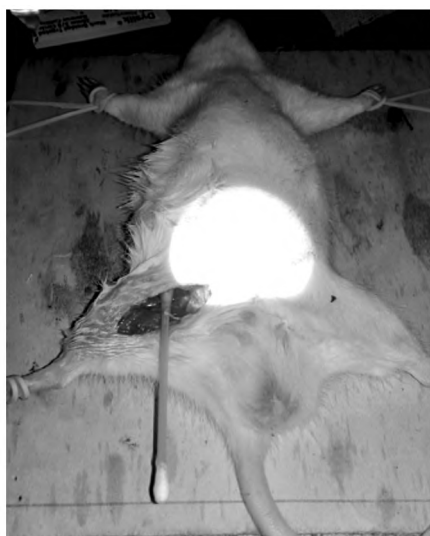

Fig. (1): The surgical incision.

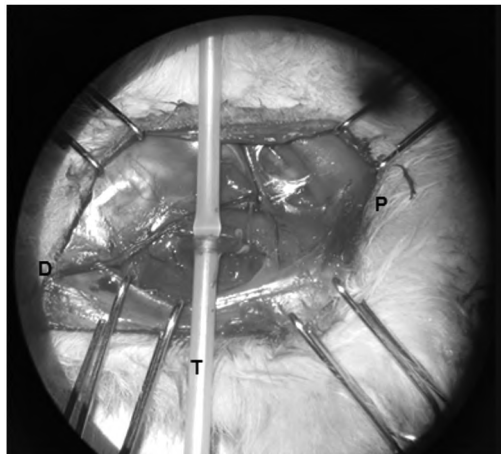


Fig. (2): Microscopic picture of long contact end-to-side neurorrhaphy with redundant femoral nerve before taking the slackness, suturing the nerve, and the severing the sciatic nerve just proximal to the repair. Proximal, D; distal, T; plastic tube, blue arrow pointed at sciatic nerve and green arrows point at femoral nerve before and after the anastomosis.

## Results

The area of positive immuno staining was measured in neurofilament Immunohistochemical stained sections. This was performed for the specimens from all animals of all groups involved in the study 1cm distal to repair site. Measurements were done in five non overlapping fields at X 400 magnification in a field area of 7286.783  $\mu\text{m}^2$  for every

subject. After taking the average of the five reading for every subject, data were plotted in (Table 1) which shows the surface area percentage of positive immuno staining neurofilament for all the subjects.

- *Group A*: End-to-end neurorrhaphy between the proximal end of femoral nerve and distal end of the sciatic nerve (n=20).
- *Group B*: End-to-side neurorrhaphy between the proximal end of femoral nerve and distal end of the sciatic nerve (n=20).
- *Group C*: Long contact end-to-side neurorrhaphy between the proximal end of femoral nerve and distal end of the sciatic nerve (n=20).

Statistical analysis was conducted using statistical package for the social sciences (SPSS) for windows, version 22 (SPSS, Inc., Chicago, IL). The current test involved one independent variable was the (tested groups); between subject factor which had three levels (group A, group B, group C). In addition, this test involved one tested dependent variable (neurofilaments surface area 1cm distal to the repair site). Prior to final analysis, data were screened for normality assumption, homogeneity of variance, and presence of extreme scores. This exploration was done as a pre-requisite for parametric calculations of the analysis of difference.

Descriptive analysis using histograms with the normal distribution curve showed that the neurofilaments surface area was normally distributed and not violates the parametric assumption for the measured dependent variable. Additionally, testing for the homogeneity of covariance revealed that there was no significant difference with  $p$ -values of  $>0.05$ . The box and whiskers plots of the tested variable to detect the outliers were done. One way ANOVA (Analysis of variance) was used to compare the tested variables of interest at different tested groups. With the initial alpha level set at 0.05.

### Dependent variable:

As presented in (Table 1), and illustrated in (Chart 1) the mean  $\pm$  SD values of neurofilaments surface area in the "group A", "group B", and "group C" were  $17.91 \pm 1.73$ ,  $11.16 \pm 2.31$ , and  $14.45 \pm 1.71$  respectively. The one way ANOVA revealed that there were significant differences in the mean values of surface area of neurons among three groups ( $p=0.0001^*$ ). As well as, multiple pairwise comparison tests (Post hoc tests) revealed that there was significant difference between (group A Vs. group B) with ( $p<0.05$ ) and this significant

increases in neurofilaments surface area in favor to group A.

Additionally, there was significant difference between (group A Vs. group C) with ( $p < 0.05$ ) and this significant reduction in neurofilaments surface area in favor to group A. Finally, there was significant difference between (group B Vs. group C) with ( $p < 0.05$ ) and this significant increase in neurofilaments surface area site in favor to group C.

This mean that group B has lower neurofilaments surface area than other groups (A,C) (Chart 1).

Table (1): The surface area percentage of positive immunostaining neurofilament for all the 60 specimens. Group A represents end-to-end neurorrhaphy, group B represents standard end-to-side neurorrhaphy, group C represents Long contact technique end-to-side neurorrhaphy.

Group A Field #	Area%	Group B Field #	Area%	Group C Field #	Area%
1	16.85	1	8.34	1	15.33
2	15.3	2	8.85	2	17.13
3	20.65	3	12.68	3	14.18
4	20.49	4	9.28	4	12.52
5	16.37	5	11.53	5	12.51
6	15.5	6	15.7	6	13.06
7	19.25	7	13.1	7	16.9
8	18.13	8	10.3	8	17.13
9	17.57	9	10.05	9	15.98
10	20.42	10	12.9	10	13.34
11	15.96	11	8.53	11	14.86
12	18.98	12	12.9	12	13.35
13	17.94	13	15.35	13	12.89
14	16.99	14	9.76	14	15.76
15	19.08	15	11.15	15	13.89
16	18.59	16	8.9	16	12.96
17	17.8	17	14.47	17	12.53
18	20.07	18	9.99	18	14.39
19	15.87	19	10.85	19	17.31
20	16.39	20	8.67	20	13.09
Mean	17.91%	Mean	11.17%	Mean	14.45%
SD	1.736	SD	2.315	SD	1.716

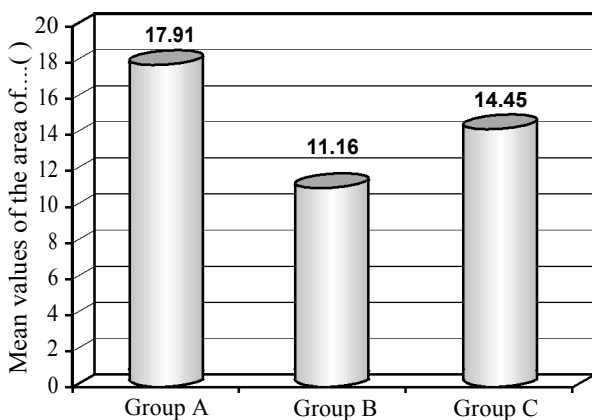


Chart (1): Mean values of the of neurofilaments surface area at different groups.

### Discussion

This study confirming that there is nothing more useful than direct, end-to-end nerve repair, when circumstances allow. Long contact end-to-side neurorrhaphy is more histologically superior to end-to-side neurorrhaphy. To our knowledge there is no other studies showing histological superiority of long contact end-to-side neurorrhaphy over standard end-to-side neurorrhaphy.

In 2003 Hayashi et al., [8] study was of the first ones to assess collateral sprouting occurs following end-to-side neurorrhaphy Using sample size of 15 rats divided into 3 groups, the sciatic nerve was transplanted between the left and right median nerves either end-to-end or end-to-side in three different groups. Histolgal analysis after 60 days concluded that nerves regenerate by collateral sprouting from the donor nerves following end-to-side neurorrhaphy.

In a histological study conducted by De Sá et al., [9] using the peroneal and the sciatic nerve rats, in sample size of 28 rats divided into 4 groups, they concluded that end-to-side repair is not as efficient as the conventional end-to-end nerve repair.

Histolgal analysis done after 56 days which was retrieved 10mm distal to repair. According to this results, a quite satisfactory morphologic regeneration occurred 8 weeks after an end-to-side nerve repair.

Along wih De Sá et al., [9] study, Kanit Sananpanich et al., [10] emphasized the same superiority of end-to-end over end-to-side in 24 rats but after 3 months.

Bontioti et al., [11] also showed superiority of end-to-end neurorrhaphy over end-to-side neurorrhaphy in sample size of 34 rats.

As early as 1994, Lundborg et al., [12] . Using similar histological technique to our study also emphasized collateral sprouting following end-to-side neurorrhaphy.

In contrast to the fore mentioned experimental studies, end-to-side was not done extensively in humans until 1988, in which year Ulrich Mennen [13] emphysized good clinical results in 22 patient suffering variety of nerve injuries, all was treated with end-to-side neurorrhaphy.

The two senior authors of this study [5-7] also established end-to-side neurorrhaphy in brachial plexus injuries with fair results.

**Conclusion:**

Direct, end-to-end nerve repair, when circumstances allow, yields the best results.

End-to-side neurotaphy presently does not replace a sound primary nerve suture. It should be seen as an excellent, viable option when planning to address difficult peripheral nerve injuries. In the future Long contact end-to-side could replace end-to-side neurotaphy in situations like avulsed brachial plexus roots. There were no added difficulties while doing the Long contact technique end-to-side neurotaphy. Although long contact end-to-side is better than end-to-end neurotaphy, further clinical studies are needed to validate our study.

**References**

- 1- PAPALIA I., GEUNA S., D'ALCONTRES F.S. and TOS, P.: Origin and history of end-to-side neurotaphy. *Microsurgery*, 27 (1): 56-61, 2007.
- 2- VITERBO F., HOSHINO K. and MAZZONI A.: Two end-to-side neurotaphies and nerve graft with removal of the epineural sheath: Experimental study in rats. *British Journal of Plastic Surgery*, 47 (2): 75-80.
- 3- XIONG G., LING L., NAKAMURA R. and SUGIURA Y.: Retrograde tracing and electrophysiological findings of collateral sprouting after end-to-side neurotaphy. *Hand Surgery*, 8 (02): 145-150, 2003.
- 4- WEBER R.A. and DELLON A.L.: Nerve lacerations: repair of acute injuries. *Hand Surgery*, 1, 819-45, 2004.
- 5- AMR S.M. and MOHARRAM A.N.: Repair of brachial plexus lesions by end-to-side side-to-side grafting neurotaphy: Experience based on 11 cases. *Microsurgery*, 25 (2): 126-146. Chicago, 2005.
- 6- AMR S.M., ESSAM, A.M., ABDEL-MEGUID, A.M., KHOLEIF A.M., MOHARRAM A.N. and EL-SADEK R.E.: Direct cord implantation in brachial plexus avulsions: Revised technique using a single stage combined anterior (first) posterior (second) approach and end-to-side side-to-side grafting neurotaphy. *Journal of brachial plexus and peripheral nerve injury*, 4 (01): e43-e59. Chicago, 2009.
- 7- AMR S.M., MOHARRAM A.N. and ABDEL-MEGUID K.M.: Augmentation of partially regenerated nerves by end-to-side side-to-side grafting neurotaphy: Experience based on eight late obstetric brachial plexus cases. *Journal of Brachial Plexus and Peripheral Nerve Injury*, 1 (01): e20-e31, 2006.
- 8- HAYASHI A., YANAI A., KOMURO Y., NISHIDA M., INOUE M. and SEKI T.: Collateral sprouting occurs following end-to-side neurotaphy. *Plastic and Reconstructive Surgery*, 114 (1): 129-137, 2004.
- 9- J. DE SÁ J.M.R., MAZZER N., BARBIERI C.H. and BARREIRA A.A.: The end-to-side peripheral nerve repair: functional and morphometric study using the peroneal nerve of rats. *Journal of Neuroscience Methods*, 136 (1): 45-53, 2004.
- 10- SANAPANICH K., MORRISON W.A. and MESSINA A.: Physiologic and morphologic aspects of nerve regeneration after end-to-end or end-to-side coaptation in a rat model of brachial plexus injury. *The Journal of Hand Surgery*, 27 (1): 133-142, 2002.
- 11- BONTIOTI E., KANJE M., LUNDBORG G., and Dahlin L.B.: End-to-side nerve repair in the upper extremity of rat. *Journal of the Peripheral Nervous System*, 10 (1): 58-68, 2005.
- 12- LUNDBORG G., ZHAO Q., KANJE M., DANIELSEN N. and KERNS J.M.: Can sensory and motor collateral sprouting be induced from intact peripheral nerve by end-to-side anastomosis?. *The Journal of Hand Surgery: British & European Volume*, 19 (3): 277-282, 1994.
- 13- MENNEN U.: End-to-side nerve suture in the human patient. *Hand Surgery*, 3 (01): 7-15, 1998.

## دراسة تحليلية لنمو الأعصاب بين إعادة توصيل الأعصاب عن طريق التوصيل بين نهايات الأعصاب المقطوعة والتوصيل بين إحدى النهايات المقطوعة وجانب الطرف الآخر؛ دراسة معملية على الفئران

بالرغم من أن إعادة توصيل الأعصاب عن طريق التوصيل المباشر بين نهايات الأعصاب المقطوعة يعطى أحسن النتائج إلا أنه في بعض الأحيان لا يكون الأمر كذلك.

في تلك الأحوال يمكن أستعمال طرق بديلة مثل التوصيل بين إحدى النهايات المقطوعة وجانب الطرف الآخر أو التوصيل الطويل بين إحدى النهايات المقطوعة وجانب الطرف والآخر.

الغرض من هذه الرسالة المعملية هو تقييم ومقارنة النتائج الهستولوجية للنمو العصبى بين إعادة توصيل الأعصاب عن طريق التوصيل بين نهايات الأعصاب المقطوعة والتوصيل بين إحدى النهايات المقطوعة الآخر أو التوصيل الطويل بين إحدى النهايات المقطوعة وجانب الطرف والآخر والتوصيل الطويل بين إحدى النهايات المقطوعة وجانب الطرف والآخر على الفئران.