

An Unusual Presentation of Impacted Laryngeal Foreign Body in an Adult

Case
Report

S. Suzana, Maithrea N., Noraziana F., S. Mazlina

Department of Otorhinolaryngology, Hospital Sultanah Nora Ismail, Malaysia

ABSTRACT

Introduction: Foreign body is a rare occurrence in adults, and the larynx is the least common site of a foreign body to be impacted. Furthermore, the usual presentation includes dysphagia, chronic cough, hoarseness or dyspnea. This is an ENT emergency requiring prompt diagnosis and treatment. However, we report a case in which an adult patient had an impacted laryngeal foreign body with very benign symptoms of 1-month duration.

Case report: We present a case of a 53-year-old Orang Asli with the chief complain of sore throat for a month duration. He had history of foreign body ingestion about a month ago. Otherwise, he has no odynophagia, dysphagia, change of voice or shortness of breath. Flexible nasopharyngolaryngoscope revealed a fish bone embedded at the right false cord. Airway was not compromised. The foreign body was successfully removed under general anaesthesia without any complications.

Conclusion: Foreign body in airway is a life-threatening event. It can cause upper airway obstruction. Impacted laryngeal foreign body may present with commonplace symptoms, as seen in our case. A complete history is important in order to make a diagnosis and eventually come into prompt management.

Key Words: Foreign bodies, larynx, pharyngitis

Received: 8th July 2019, **Accepted:** 27th July 2019

Corresponding Author: S. Suzana, M.D, Department of Otorhinolaryngology, Hospital Sultanah Nora Ismail, Malaysia, **Tel.:** 0134333688, **E-mail:** ssuzana36@gmail.com

ISSN: 2090-0740, November 2019 Vol.20, No.3

INTRODUCTION

Laryngeal foreign bodies commonly present in the pediatric age group and are comparatively rare in adults^[1]. In the majority of adult cases, it occurs in the elderly; or in patients with impaired neurological function, excessive alcohol consumption, psychiatric disease or following trauma. The most common site of foreign body to be lodged is at the bronchi, followed by trachea and larynx^[2]. Common presenting complaints include dysphagia, chronic cough, hoarseness or dyspnea^[3]. A foreign body in the aerodigestive tract is an ENT emergency, requiring prompt removal, with frequent sequelae if left untreated. We report a case of impacted laryngeal foreign body in an adult who only had a sensation of persistent sore throat for a month.

CASE PRESENTATION

A 53-year-old male Orang Asli, who was a smoker of but a teetotaler, presented to our department with a chief complaint of sore throat for 1 month. He had underlying chronic obstructive pulmonary disease but no history of dysphagia, odynophagia, fever, cough, voice changes,

dyspnea or stridor. There was no history of prior psychiatric illness or neurological deficit. This was the first time he sought medical attention for his current complaint. On further history, he mentioned an alleged fish bone ingestion 1 month prior but had dismissed it as the pain resolved the following day.

On examination, he was well, afebrile, alert and orientated. He was not in respiratory distress and there was no stridor. Patient was adentulous, but intraoral examination was otherwise unremarkable. There was no neck swelling palpable and lungs auscultation finding was equal air entry bilaterally. Flexible nasopharyngolaryngoscope revealed a fish bone embedded at the right false cord (Figure 1). Bilateral true cord mobile and airway was not compromised. There was also no edematous mucosa surrounding the right false cord where the foreign body embedded. On the lateral view of neck X-ray done noted there was a radio opaque linear shadow over the C5 level (Figure 2). Removal of the foreign body was done under general anaesthesia via endotracheal intubation (Figure 3). Post-operative clinical course was uneventful and patient was discharged well with a course of oral antibiotic. He was well and asymptomatic on routine follow up.

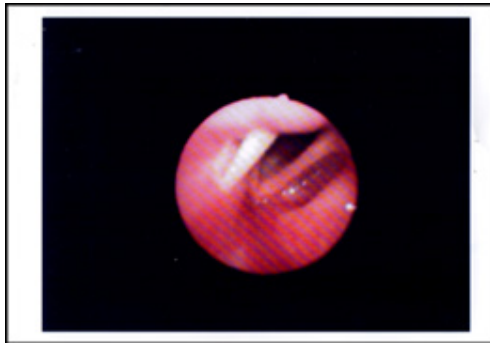


Fig. 1: The fish bone embedded at the right false cord. Airway not compromised and there was no edematous mucosa surrounding it

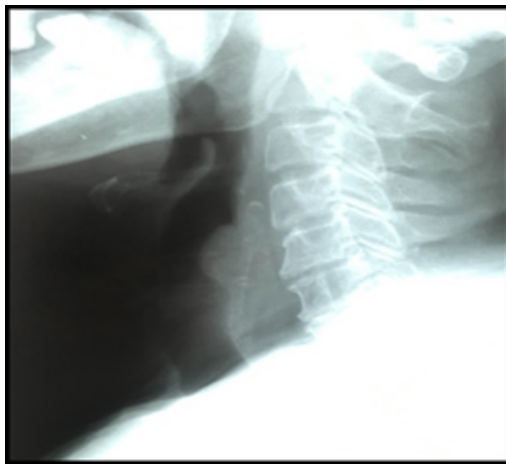


Fig. 2: A linear radio opaque shadow seen at the level C5 on the lateral view of neck X-ray

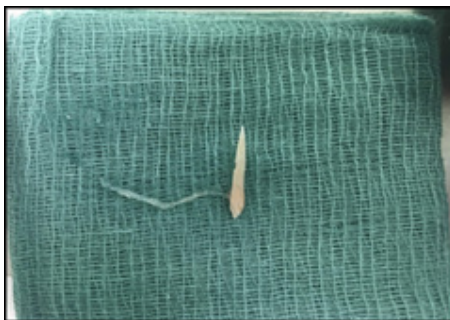


Fig. 3: The fish bone that has been successfully removed

DISCUSSION

Inhalation of a foreign body in airway is a life-threatening event. Foreign body in aerodigestive tract are usually found in paediatric age group (up to 3-4 years old) compared to in an adult^[1]. This is due to in these age groups children are having lacks of molar teeth together with their high index of curiosity^[2]. Meanwhile in adults, it commonly occurred in elderly patients or one with underlying impaired neurological function, excessive alcohol consumption, psychiatric disease or following

trauma^[3]. The most common sites of a foreign body are at bronchi (83%), followed by trachea (12%) and larynx (2.9%)^[2]. The larynx is being the uncommon site due the presence of laryngeal sphincters and cough reflex. Laryngeal foreign bodies are very rare as most inhaled objects pass into bronchus. The most common site for that is the right bronchus as it is more vertical, shorter and wider^[4]. Aspiration of foreign bodies in all airway locations have been reported in literature^[5].

The lack of the symptoms is the reason for the late treatment and management. The lists of the commonest foreign bodies are such as nuts, seeds, teeth, erasers, pencils, safety pins, whistles, tracheostomy tubes, fish bones, chicken bones, stones, earrings, plastic toys, but no report of drug protector in sane adult^[6].

Foreign body in airway can results in partial or complete airway obstruction. Airway foreign bodies are most safely removed under the general anaesthesia. As usual practice an elective tracheostomy will be performed before extracting the foreign body in upper airway. Emergency or elective tracheostomy should be done in order to prevent any intraoperative or postoperative catastrophic event in view of presence of the edematous mucosa surroundings due to the impacted foreign body itself or due to manipulation of foreign body removal^[7]. However, we did not perform tracheostomy in our case due to there is no edematous surrounding mucosa and patient was not in distress provided the vital signs also stable.

CONCLUSION

Impacted laryngeal foreign body may present with commonplace symptoms, as seen in our case. As such, the utility of a thorough history taking is of paramount importance, as is a plain soft tissue x-ray of the lateral neck which will demonstrate the foreign body if it is radiopaque. It also important to have a high index of suspicion for foreign body aspiration or ingestion in adentulous patients due to the lack of sensation afforded by dentures. Foreign bodies in aerodigestive tract require prompt diagnosis and treatment to prevent unnecessary complications.

CONFLICT OF INTERESTS:

There are no conflicts of interest

REFERENCES

1. M. K, R. W. Pediatric foreign bodies and their management. *Curr Gastroenterol Rep.* 2005;7(3 PG-212-8):212-8.
2. Kansara AH, Shah H V., Patel MA, Manjunatharao S V. Unusual case of laryngeal foreign body. *Indian J Otolaryngol Head Neck Surg.* 2007;59(1):63-5.

3. Kam JC, Doraiswamy V, Dieguez JF, Dabu J, Cholankeril M, Govind M, *et al.* Foreign body aspiration presenting with asthma-like symptoms. *Case Rep Med.* 2013;
4. Samarei R. Survey of Foreign Body Aspiration in Airways and Lungs. *Glob J Health Sci.* 2014;6(7):130–5.
5. Mahmoud M, Imam S, Patel H, King M. Foreign body aspiration of a dental bridge in the left main stem bronchus. *Case Rep Med.* 2012;2012.
6. Figueiredo RR, Machado WS. Foreign body aspiration through tracheotomy: a case report. *Braz J Otorhinolaryngol.* 2005;71(2):234–6.
7. .Ngamdu Y, Sandabe M, Kodiya A, Isa A, Garandawa H. Delayed and Unusual Presentation of Impacted Laryngeal Foreign Body in Adult. *J Case Reports* 2014;4(1): 68–71.