

EFFECT OF COMBINATION TREATMENT OF CANDESARTAN AND CURCUMIN ON TRAUMATIC BRAIN INJURY IN MICE

BY

Sarah A. Baraka¹, Samar Saad Eldeen Azab², Azza Sayed Mohamed Awad³, Ebtihal El-demerdash²

FROM

¹*pharmacology & Toxicology department, faculty of pharmacy Ahram Canadian university.*

²*Pharmacology & Toxicology department, faculty of pharmacy Ain-shams University.*

³*Pharmacology & Toxicology department, faculty of pharmacy AL –Azhar university.*

ABSTRACT

Traumatic brain injury (TBI) is a severe condition and a major cause of death and disability, particularly in young adults. Traumatic brain injury invokes a complex inflammatory, oxidative and apoptotic responses. The present experimental study was designed to assess the effect of combination treatment of curcumin and candesartan on TBI in mice. Mice were classified into six groups (Sham, TBI and TBI post-treated with vehicle, curcumin, candesartan or combination of curcumin + candesartan for 7 days), n=12 each. Mice were anesthetized and then placed under a weight-drop device. The animals were killed by cervical dislocation, brains were rapidly isolated and homogenized. Traumatic brain injury group showed significant increment in MDA, TNF-Alpha, caspase-3 as compared to sham group and these effects were significantly ameliorated by curcumin, candesartan or their combination treatment. Also total antioxidant capacity (TAC) decreased markedly in the TBI group and increased significantly by concurrent treatment with curcumin &/or candesartan. Furthermore, histopathological examination confirmed these findings. Collectively these findings indicate that curcumin and candesartan have potential anti-inflammatory, anti-apoptotic and antioxidant effects. Accordingly, curcumin or candesartan might be employed as a therapeutic agent for TBI and their combination succeeded in adding better effects than the individual drugs.

Keywords

Curcumin, Candesartan, traumatic brain injury, anti-oxidant, anti-apoptotic, anti-inflammatory.

Introduction

Traumatic brain injury is described as an acquired injury to the brain from an external source (**Roebuck-Spencer & Cernich, 2014**). Head injury and trauma are considered as serious complications which contribute to increased patient mortality and long-term disability (**Sharma & Vavilala, 2012**).

Two main stages have been categorised in the development of brain damage after injury to the head: (a) Primary damage is caused by mechanical factors (impact) and

occurs immediately at the moment of injury, taking the form of surface contusions, laceration and intracranial haemorrhage. (b) Secondary injury is delayed and is produced by complicating processes that are initiated at the moment of impact but do not present clinically for a period of hours to days after impact. The development of the secondary injury in TBI is a complex process including oxidative stress, glutamate excitotoxicity, inflammatory damage (Wang et al., 2005). As a result of the multiple mechanisms initiated by brain injury that lead to neuronal dysfunction, it would seem that a drug that have multimodal action to combat the harmful secondary cascades would be advantageous to treat recovery from TBI.

Curcumin (diferuloylmethane) is a polyphenol responsible for the yellow color of turmeric, a curry spice, which is extracted from the rhizome *Curcuma longa* (Kiuchi et al., 1993). Curcumin has shown several therapeutic effects such as anti-inflammatory, anti-oxidant, anticarcinogenic, anti-thrombotic, and cardiovascular protective effects (Goel et al., 2008). Curcumin penetrates the blood-brain barrier effectively because of its low molecular weight (Kim et al., 2008). The effect of curcumin was studied in rats following intraperitoneal treatment, 30 min after middle cerebral artery occlusion (MCAO), indicating its neuroprotective potential in ischemia, which has been suggested to be mediated through its antioxidant activity (Thiyagarajan & Sharma, 2004).

The Renin-angiotensin system (RAS) plays an essential role in the regulation of blood pressure homeostasis in peripheral vasculature (Petrillo & Ondetti, 1982). However, RAS is not only established in peripheral vasculature but also in CNS (McKinley et al., 2003). In the brain, the activation of Ang II type 1 receptors (AT1R) by Ang II regulates many physiological functions, these include: the control of the cerebral circulation, the integrity of the blood-brain barrier, central sympathetic activity, hormonal production and release, the response to stress, and the regulation of the brain's innate immune response. On the other hand, excessive stimulation of AT1R in the brain is associated with brain ischaemia, excessive inflammation (Saavedra, 2012), increasing oxidative stress, and endothelial dysfunction (Ozacmak et al., 2007; Savoia & Schiffrin, 2007).

Candesartan, a compound blocking central AT1 receptor stimulation by Ang II when administered systemically (Seltzer et al., 2004), is one of the Angiotensin receptor blockers (ARBs), which are neuroprotective, anti-inflammatory, and vasodilatory attacking three potentially devastating sequelae of TBI (Benigni et al., 2010). Candesartan reverses cerebrovascular inflammation and brain ischemia (Zhou et al., 2005). It was also able to reduce lipid peroxidation due to its antioxidative effect (Tota et al., 2009).

The present study was undertaken in mice treated with oral curcumin, candesartan, and their combination after head injury to comprehensively evaluate their potential neuroprotective effects with respect to inflammation, oxidative stress, apoptosis following an experimental model of weight drop brain injury in mice.

Materials and methods:

Animals

Adult male albino mice with a body weight of (35-40 g) were used. They were obtained from animal house of national research center (Giza-Egypt). Mice

were housed individually in polycarbonated cages in a standard animal house maintained at temperature (25 ± 2 °C), humidity (60-70%) and light cycles (12hr light/ 12hr dark). Animals were allowed a free access to water and palliated standard mouse show diet. They were left for initial adaptation period for one week before any experimental manipulation. All procedures were done according to guidelines of ethical Committee, faculty of Pharmacy, Ain Shams University.

Experimental groups

The Mice were randomly divided into 6 groups (n=12) as follows; a control (Sham operation group) which was subjected to all the model procedures except TBI, a TBI group, and TBI groups administered the vehicle only, curcumin, candesartan or combination. Curcumin and candesartan were administered orally once daily for 7 days after induction of trauma at the dose of 100 (Shukla et al., 2008) and 1 mg/kg/day (Groth et al., 2003) respectively.

Drug treatment

Candesartan, was supplied from Pharaonia Pharmaceuticals, Pharo Pharma (Egypt), as a crystalline solid. Candesartan was suspended in 0.8% (v/v) tween 80. A dose of (1 mg/kg/day) orally was used for seven days after TBI induction. Curcumin, (Sigma Chemicals, St, Louis, MO, USA). Curcumin was suspended in 0.8% (v/v) tween 80. The suspension was administered to animals orally (100 mg/kg/day) for 7 days.

Surgical procedures and weight drop brain injury model

For the production of brain injury, we used the weight drop technique according to Albert-Weißberger (Albert-Weißberger et al., 2012) with some modifications. The animals were lightly anesthetized with diethyl ether. Body temperature was monitored with a rectal probe and kept between 37.0 and 37.5 °C with a heating pad. A midline longitudinal scalp incision was made and the skull was exposed. After identification of the right parietal cortex at bregma-3.5 and 3.5 mm lateral to the midline, as impact area, a weight of 75 g was released and dropped from a height of 10 cm with a final impact of 0.01 Joule onto the skull.

Estimation of biochemical parameters

Brain tissue preparation

The mice were decapitated under ether anesthesia. The skull was cut open and the brain was exposed from its dorsal side. The whole brain was quickly removed and cleaned with chilled normal saline on the ice. A 10% (w/v) homogenate of brain samples in 0.03M sodium phosphate buffer (pH 7.4) was prepared by using a stainless steel homogenizer (Universal Lab. Aid MPW-309, Mechanika Precyzyjna, Poland).

Determination of Lipid Peroxides

Malondialdehyde, a product of lipid peroxidation is one of the thiobarbituric acid reactive substances (TBARS). The colorimetric determination of TBARS is based on the reaction of MDA with TBA at low pH, and at high temperature. The resultant pink colored product is extracted by n-butanol, and the absorbance is determined spectrophotometrically at 535 nm. Malondialdehyde is expressed as nanomoles/mg protein (Mihara & Uchiyama, 1978).

Protein estimation

The protein concentration was estimated by the use of Lowry method (**LOWRY et al., 1951**). This method is based on measuring a chromophore derived from the reduction of the phosphomolybdate-phosphotungstate reagent (Folin-Ciocalteu) by protein bound copper. The protein concentration was expressed as mg protein/ ml of tissue homogenate.

Determination of total antioxidant capacity (TAC)

Total antioxidant capacity (mmol/mg protein) was measured spectrophotometrically according to the kit of (BIO-Diagnostics, Egypt) at 505 nm. The method is performed by the reaction of antioxidants in the sample with a defined amount of exogenously provided hydrogen peroxide (H_2O_2), where the antioxidant in the sample eliminate a certain amount of the provided H_2O_2 . The residual H_2O_2 is determined colorimetrically by an enzymatic reaction which involves the conversion of 3,5-dichloro-2-hydroxy benzensulphonate to a colored product (**Koracevic et al., 2001**).

Determination of Tumor necrosis factor alpha (TNF- α) Content

Tumor necrosis factor- α content was measured by Enzyme-linked Immunosorbent Assay (ELISA) kit (Quantikine®, USA), Catalog Number RTA00, SRTA00, PRTA00. The results were expressed as (pg/mg protein). TNF- α present is bound by a monoclonal antibody. After washing away any unbound substances, an enzyme-linked polyclonal antibody specific for rat TNF- α is added to the samples (**Juhász et al., 2013**).

Determination of caspase-3 content

Caspase-3 content was determined according to the ELISA kit [Cusabio Biotech Co., Hubei Province.China]. The results were expressed as (ng/mg protein) (**Zobeiri et al., 2013**).

Histopathological assessment

Two brains were taken from each group and fixed in 10% formolaldehyde for 24hr. Washing was done in distilled water then serial dilutions of alcohol (methyl, ethyl and absolute ethyl) were used for dehydration. Specimens were cleared in xylene and embedded in paraffin at 56 °C in hot air oven for 24hr. Paraffin bees wax tissue blocks were prepared for sectioning at 4 microns thickness by microtome. The obtained tissue sections were collected on glass slides, deparafinized, stained by hematoxylin & eosin stain for routine examination using light electric microscope (**Banchroft et al., 1996**).

Statistical Analysis

Differences between obtained values (means \pm SEM, n = 12) were carried out for parametric data by one way analysis of variance (ANOVA) followed by the Tukey-Kramer's test for multiple comparison. A probability level of less than 0.05 was accepted as being significant in the used statistical tests. Instat software 2003, version 3.06 (GraphPad software, Inc., San Diego, USA) was used to carryout all the statistical tests.

Results

Effect of curcumin, candesartan and their combination on MDA and TAC after traumatic brain injury in mice

Traumatic brain injury caused a significant increase in MDA level in brain tissues, when compared to sham group (2.037 ± 0.27 vs 1.036 ± 0.056 nmol/mg protein). The high level of MDA was significantly ($P < 0.05$) decreased by curcumin, candesartan and combination treatment in mice exposed to brain trauma (1.098 ± 0.090 , 1.035 ± 0.13 and 1.066 ± 0.12 nmol/mg protein) respectively (Fig. 1a). On the other side, TBI caused a significant decrease in the activity of TAC in brain tissue when compared with sham group (0.267 ± 0.023 vs 2.83 ± 0.176 mmol/mg protein) (Fig. 1b). The post treatment of mice exposed to TBI with curcumin or candesartan showed significant increase in the activity of TAC upon comparison with TBI group (1.6 ± 0.212 , 1.04 ± 0.16 mmol/mg protein) respectively. Furthermore, the combined treatment significantly enhanced TAC activity as compared to candesartan alone (1.88 ± 0.15 mmol/mg protein).

Fig.1.

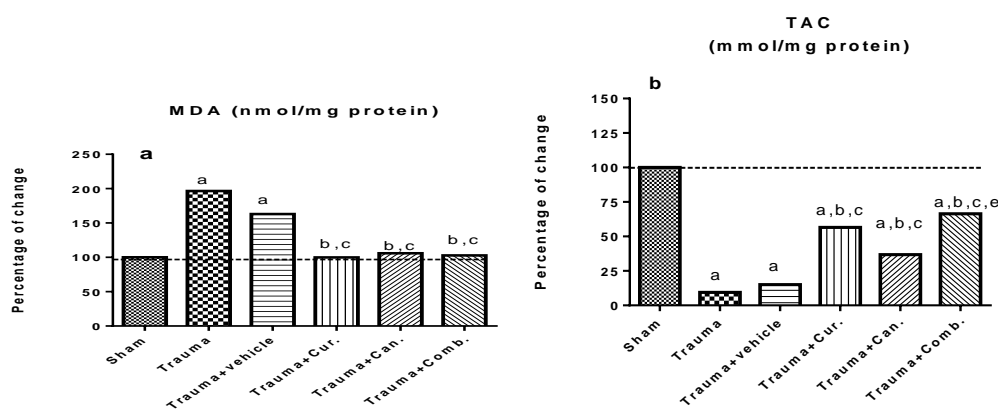


Fig. 1. Effect of curcumin, candesartan and their combination on MDA (a) and TAC (b) and after TBI in mice. Values were given statistically significant at $p < 0.05$, ^a: significant difference from sham group, ^b: significant difference from TBI group, ^c: significant difference from TBI + vehicle group, ^d: significant difference from cur + TBI group, ^e: significant difference from can + TBI group.

TBI: Traumaic brain injury ; **Cur:** Curcumin; **Can:** Candesartan.

Effect of curcumin, candesartan and their combination on tumor necrosis factor alpha (TNF- α) after traumatic brain injury in mice

Traumatic brain injury caused a significant elevation in TNF- α in brain tissue when compared with sham group, (127.05 ± 5.84 vs 31.77 ± 1.690 pg/mg protein). Tumor necrosis factor- α content is significantly decreased after the administration of curcumin or candesartan as compared to corresponding TBI group (90.6 ± 8.708 , 69.78 ± 5.56 vs. 127.05 ± 5.84 pg/mg protein) respectively (Fig. 2). The combination regimen successfully enhanced curcumin therapeutic effect and was able to normalize TNF- α content (54.35 ± 5.42 pg/mg protein).

Fig.2.

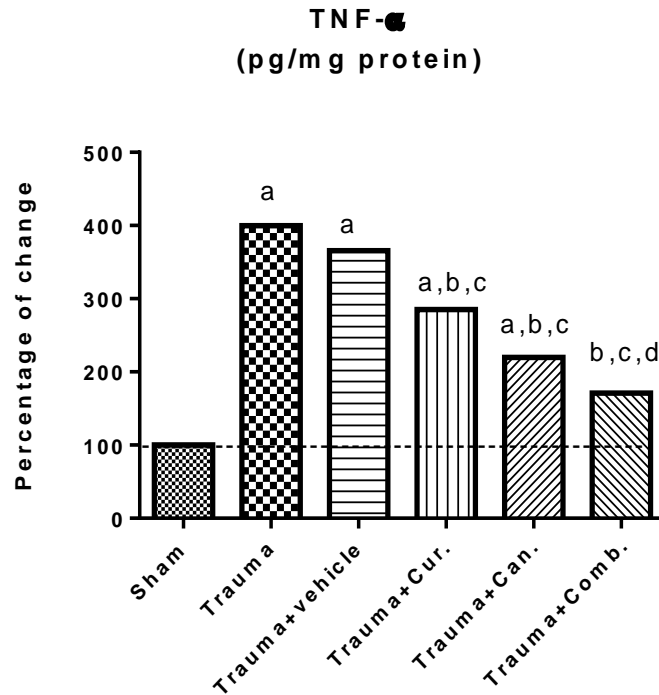


Fig. 2. Effect of curcumin, candesartan and their combination on TNF- α after TBI in mice. Values were given statistically significant at $p < 0.05$, ^a:significant difference from sham group, ^b: significant difference from TBI group, ^c: significant difference from TBI +vehicle group, ^d: significant difference from cur + TBI group, ^e: significant difference from can + TBI group.

TBI: Traumaic brain injury ; **Cur:** Curcumin; **Can:** Candesartan.

Effect of curcumin, candesartan and their combination on caspase-3 after traumatic brain injury in mice

Brain tissue exposed to TBI showed a great elevation in caspase-3 (10.473 ± 0.380 ng/mg protein) as compared to sham group (1.025 ± 0.011 ng/mg protein). However, administration of curcumin or candesartan after TBI significantly decreased caspase-3 content in brain tissue (6.192 ± 0.422 , 5.32 ± 0.498 ng/mg protein) respectively as compared to TBI. The combination showed an enhanced effect (3.43 ± 0.338 ng/mg protein) which significantly differ from curcumin or candesartan alone (**Fig.3**).

Fig.3.

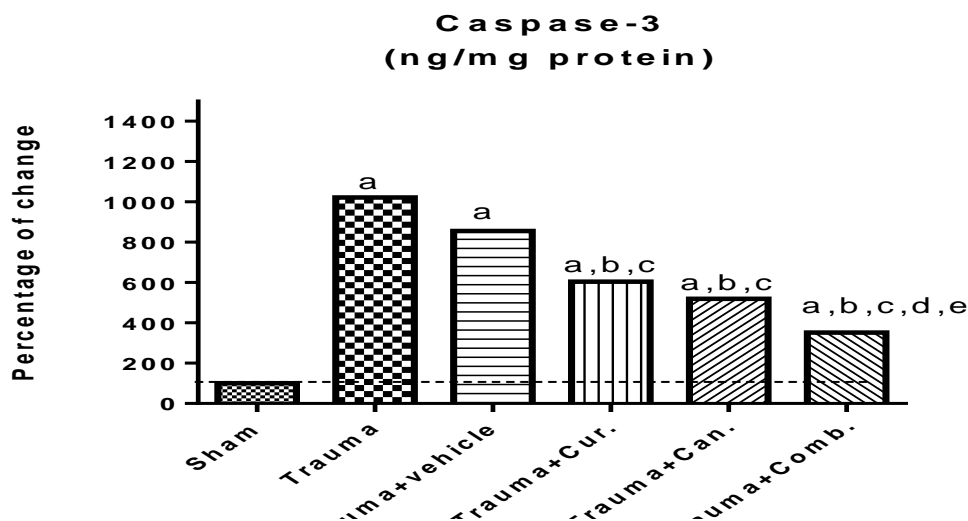


Fig. 3. Effect of curcumin, candesartan and their combination on caspase-3 after traumatic brain injury in mice. Values were given statistically significant at $p < 0.05$, ^a:significant difference from sham group, ^b: significant difference from TBI group, ^c: significant difference from TBI +vehicle group ^d: significant difference from cur + TBI group, ^e: significant difference from can + TBI group.

TBI: Traumaic brain injury ; **Cur:** Curcumin; **Can:** Candesartan.

Effect of curcumin, candesartan and their combination on histopathological changes after traumatic brain injury in mice

In the present study, photomicrographs of mice brain in sham group revealed normal histopathological structures (**Figure 4.A**). However, the brain of TBI group showed focal eosinophilic plaques formation associated with encephalomalacia especially in striatum of the cerebrum (**Figure 4.B**). Also, few focal small eosinophilic plaques were detected in the TBI group which was given the vehicle in striatum of the cerebrum (**Figure 4.C**).

Brain sections obtained from animals with TBI treated with curcumin showed a decrease in plaques formation with mild focal encephalomalacia (**Figure 4.D**). Likewise, treatment with candesartan nearly normalized some of histopathological variations induced by TBI (**Figure 4.E**). Furthermore, when curcumin was administered concomitantly with candesartan, it retarded the deleterious action of TBI and resulted in a decrease in encephalomalacia and plaques formation (**Figure 4.F**).

The severity of the histopathological alterations in brain tissue of different experimental groups was microscopically scored blindly by an independent histopathologist and the scores are presented in (**Table 1**).

Fig.4.

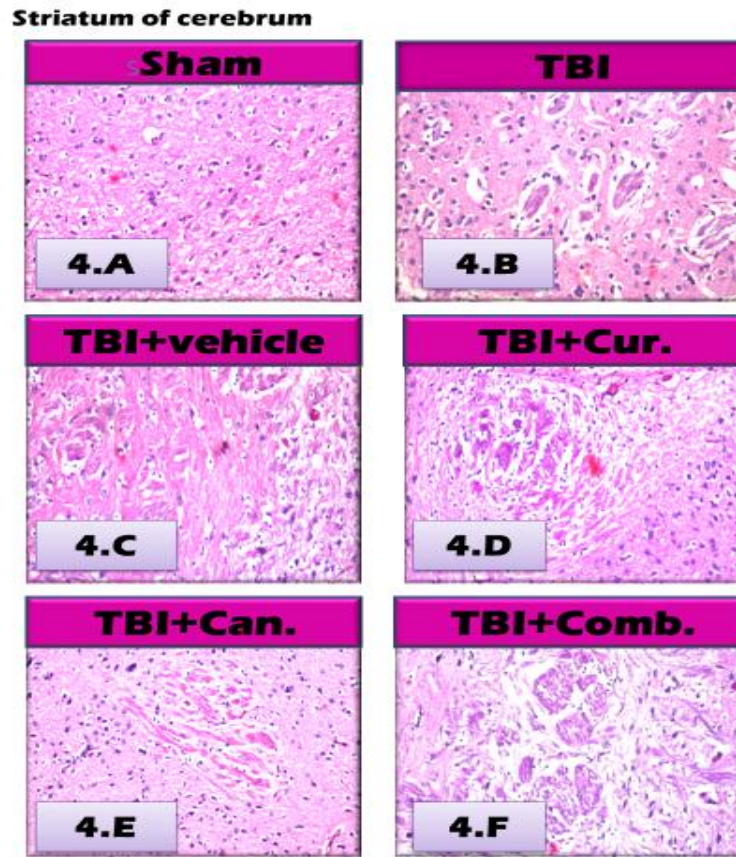


Fig.4. Representative photomicrographs of brain sections stained by H&E (magnification X40), showing the effect of curcumin, candesartan and their combination on histopathological changes after traumatic brain injury in mice.

4.A: Transverse section taken from a brain of mouse in sham group showing normal histological structures (H&E×40).

4.B: Transverse section taken from a brain of mouse in TBI group showing focal eosinophilic plaques formation in striatum of cerebrum (H&E×40).

4.C: Transverse section taken from a brain of mouse in TBI + vehicle group showing focal few small eosinophilic plaques formation in the striatum of the cerebrum (H&E×40).

4.D: Transverse section taken from a brain of mouse in TBI + curcumin group showing a decrease in plaques formation with mild focal encephalomalacia in striatum of the cerebrum (H&E×40).

4.E: Transverse section taken from a brain of mouse in TBI + candesartan group showing normalization in some of histopathological variations induced by TBI (H&E×40).

4.F: Transverse section taken from a brain of mouse in TBI + combination group showing normal histological structure with a decrease in encephalomalacia and plaques formation (H&E×40).

Tab. 1. Scoring the severity of the histopathological alterations in brain tissue of different experimental groups

Histopathological alteration in brain	Experimental group					
	Sham	Trauma (TBI)				
		Nothing	+ Vehicle	+ Cur.	+ Can.	+ Comb.
Encephalomalacia	-	+++	++	+	-	-
Eosinophilic	-	+++	++	+	+	-

TBI: Traumaic brain injury ; **Cur:** Curcumin; **Can:** Candesartan ; **Comb:** Combination.

+++ : Severe histopathological alteration

++ : moderate histopathological alteration

+ : mild histopathological alteration

- : nil histopathological alteration

Discussion

Head injury and trauma are considered as serious complications which contribute to increased patient mortality and long-term disability (**Sharma & Vavilala, 2012**). The search for an effective therapy to treat TBI patients has been ongoing for many years. A multifunctional approach is more likely to be effective after TBI because it is becoming increasingly recognized that the sequelae of events after TBI is so complex (**Loane & Faden, 2010; Marklund & Hillered, 2011**). The present study suggests that the treatment with candesartan, curcumin and their combination attenuate cerebral damage and decrease inflammatory, oxidative and apoptotic responses following TBI in mice.

The enhanced oxidative stress due to increased generation of free radicals has been reported during brain injury (**Slemmer et al., 2008**). An increase in the levels of oxygen and hydroxyl radicals following TBI has also been shown (**Nishio et al., 1997**). In our study, Increased MDA level was observed in injured mice which indicated that the balance between oxidant and antioxidant agents changed on behalf of pro-oxidation in the brain homogenates of traumatic mice. The present study showed a marked reduction in MDA content with candesartan, curcumin and combination treated groups. This therapeutic effect is in accordance with a previous study, where candesartan was able to reduce lipid peroxidation product MDA and elevate antioxidant glutathione (GSH) in mice after intracerebral streptozotocin (IC STZ) administration (**Tota et al., 2009**). The antioxidative action of candesartan is due to blockade of Ang II binding to AT1 receptors which activates NADPH oxidase (**Griendling et al., 1994**). NADPH oxidase plays a pivotal role in the development of oxidative stress as it uses NADH and/or NADPH as substrates for the production of superoxide anion (**Griendling et al., 2000**). Candesartan has also been reported to decrease NADPH oxidase expression and lipid peroxidation, decrease brain injury, and improve neurologic function in combined rat model of diabetes induced cerebral ischemia (**Kusaka et al., 2004**).

Moreover, The protective effect of curcumin against cerebral ischemia in rats has been reported by Thiyagarajan and Sharma (**Thiyagarajan & Sharma, 2004**).

Curcumin has also been shown to reduce oxidative damage and amyloid pathology in Alzheimer's disease (**Thiyagarajan & Sharma, 2004**). Also, the neuroprotective efficacy of curcumin in attenuating 3-nitropropionic acid (a fungal toxin) and lead induced neurotoxicity has been reported (**Kumar et al., 2007**). The neuroprotective effect of curcumin was associated with its antioxidant potential in these studies (**Merrell et al., 2009**). The antioxidant activity of curcumin may be due to the presence of two electrophilic α , β -unsaturated carbonyl groups in its structure, which can react with nucleophiles such as glutathione. Hence, curcumin has the potential to inhibit lipid peroxidation and neutralize reactive oxygen and nitric-oxide-based free radicals (**Butterfield & Lauderback, 2002**). In the present study TBI was associated by depletion of TAC, however candesartan, curcumin treated groups ameliorated this depletion. Furthermore, the combined treatment significantly enhanced TAC activity as compared to candesartan alone.

Traumatic brain injury can activate several inflammatory pathways. Accordingly, an elevated levels of TNF- α were found in the traumatic mice of this study. This is in agreement with a study which reported that TNF- α mRNA and protein are elevated in the early period after experimental TBI (**Riva-Depaty et al., 1994**). In addition, high TNF- α levels were also observed in the clinical setting of TBI patients (**Csuka et al., 1999; Goodman et al., 1990**). Early up regulation of neuronal TNF- α expression after TBI was found to contribute to subsequent neurological dysfunction (**Knoblach et al., 1999**). All the treated groups showed a reduced levels of TNF- α . The combination regimen successfully enhanced curcumin effect in reducing TNF- α and was able to normalize its content. The activity of candesartan and curcumin might be attributed to their anti-inflammatory property and our results were consistent with previous reports. For instance, curcumin is found to have anti-inflammatory effect by inhibiting COX-2, and iNOS (**Menon & Sudheer, 2007**), and suppressing TNF- α , IL-1 β . This effect is most likely mediated through its ability to reduce the release of ROS by stimulated neutrophils (**Kim et al., 2005**). The candesartan anti-inflammatory effect might be mediated by AT1 receptor blockade, which decreased inflammation-induced activation of transcription factors regulating expression of multiple inflammatory genes (**Quan & Banks, 2007**), such as NF- κ B and also inhibiting iNOS and COX-2 (**Benicky et al., 2011**).

Furthermore, it was found in this study, that TBI was associated with massive increase in caspase-3 as compared to the sham group. These results supported the previous studies that also showed caspase-3 activation in both neurons and glia following head injury (**Emery et al., 1998; Springer et al., 2000**). These changes were significantly ameliorated by candesartan or curcumin treatment. Moreover, the combination of both drugs increased their anti-apoptotic effect as compared to their effect alone.

Previous studies have shown that curcumin has an anti-apoptotic effect, both against dexamethane-induced apoptosis in rat thymocytes and chemotherapy-induced apoptosis in breast cancer cells (**Jaruga et al., 1998; Somasundaram et al., 2002**). The anti-apoptotic effects of curcumin are related to the suppression of NF- κ B, TNF- α , and interleukins (**Aggarwal, 2004; Kunnumakkara et al., 2007**). Here we have demonstrated that curcumin, effectively inhibits caspase-3 activation and also ameliorates apoptosis induced by TBI, which is in harmony with previous studies (**Uğuz et al., 2015**). Additionally, concurrent treatment of animals with curcumin, candesartan

and their combination significantly ameliorated the deleterious effect of TBI on brain tissue using the histopathological examination observed by hematoxylin and eosin stain and that may be counted to their multi neuroprotection and cytoprotection effects.

In conclusion, the present study suggests for the first time potential therapeutic benefits of candesartan, curcumin and their combination in an experimental model of TBI at a dose of (1 mg/kg & 100 mg/kg) respectively. Their therapeutic effects became evident from the present results in which they managed the TBI induced biochemical and histopathological alterations. This may be attributable to their prominent role in attenuating oxidative stress, inflammation and apoptosis. As both the drugs shares the effect over some common and some different pathways, their combined treatment enhances some of their neuroprotective effect. These results provided a rationale for testing the efficacy of the combination of both drugs, where our study provides a promising evidence that this combination could be used in the multifunctional management of traumatic brain injury.

Conflict of interest:

The authors declare that they have no potential conflicts of interest

References:

- Aggarwal, B. B. (2004).** Nuclear factor- κ B: The enemy within. *Cancer Cell*, 6(3): 203-208.
- Albert-Weißenberger, C., Várrallyay, C., Raslan, F., Kleinschnitz, C., & Sirén, A.L. (2012).** An experimental protocol for mimicking pathomechanisms of traumatic brain injury in mice. *Exp. Transl. Stroke Med.*, 4(1):1
- Bancroft, J. D., Stevens, A., Turner, D. R. (1996).** *Theory and Practice of Histological Technique.* (4th ed.). Churchill Livingstone, N.Y., London, San Francisco, Tokyo.
- Benicky, J., Sánchez-Lemus, E., Honda, M., Pang, T., Orecna, M., Wang, J., ... Saavedra, J. M. (2011).** Angiotensin II AT(1) receptor blockade ameliorates brain inflammation. *Neuropsychopharmacology*, 36(4): 857–870.
- Benigni, A., Cassis, P., & Remuzzi, G. (2010).** Angiotensin II revisited: new roles in inflammation, immunology and aging. *EMBO Mol. Med.*, 2(7): 247–257.
- Butterfield, D. A., & Lauderback, C. M. (2002).** Lipid peroxidation and protein oxidation in Alzheimer's disease brain: potential causes and consequences involving amyloid β -peptide-associated free radical oxidative stress. *Free Radical Biol. Med.*, 32(11): 1050–1060.
- Csuka, E., Morganti-Kossmann, M. C., Lenzlinger, P. M., Joller, H., Trentz, O., & Kossmann, T. (1999).** IL-10 levels in cerebrospinal fluid and serum of patients with severe traumatic brain injury: Relationship to IL-6, TNF-alpha, TGF-beta1 and blood-brain barrier function. *J. Neuroimmunol.*, 101(2): 211–221.

- Emery, E., Aldana, P., Bunge, M. B., Puckett, W., Srinivasan, A., Keane, R. W., ... Levi, A. D. (1998). Apoptosis after traumatic human spinal cord injury. *J. Neurosurg.*, 89(6): 911–920.
- Goel, A., Kunnumakkara, A. B., & Aggarwal, B. B. (2008). Curcumin as “Curecumin”: From kitchen to clinic. *Biochem. Pharmacol.*, 75(4): 787–809.
- Goodman, J. C., Robertson, C. S., Grossman, R. G., & Narayan, R. K. (1990). Elevation of tumor necrosis factor in head injury. *J. Neuroimmunol.*, 30 (2-3): 213–217.
- Griendling, K. K., Minieri, C. A., Ollerenshaw, J. D., & Alexander, R. W. (1994). Angiotensin II stimulates NADH and NADPH oxidase activity in cultured vascular smooth muscle cells. *Circ. Res.*, 74(6): 1141–1148.
- Griendling, K. K., Sorescu, D., & Ushio-Fukai, M. (2000). NAD(P)H oxidase: role in cardiovascular biology and disease. *Circ. Res.*, 86(5): 494–501.
- Groth, W., Blume, A., Gohlke, P., Unger, T., & Culman, J. (2003). Chronic pretreatment with candesartan improves recovery from focal cerebral ischaemia in rats. *J. Hypertens.*, 21 (11): 2175–2182.
- Jaruga, E., Bielak-Zmijewska, A., Sikora, E., Skierski, J., Radziszewska, E., Piwocka, K., & Bartosz, G. (1998). Glutathione-independent mechanism of apoptosis inhibition by curcumin in rat thymocytes. *Biochem. Pharmacol.*, 56(8): 961–965.
- Juhász, K., Buzás, K., & Duda, E. (2013). Importance of reverse signaling of the TNF superfamily in immune regulation. *Expert Rev. Clin. Immunol.*, 9(4): 335–348.
- Kim, G.Y., Kim, K. H., Lee, S. H., Yoon, M. S., Lee, H. J., Moon, D. O., ... & Park, Y. M. (2005). Curcumin inhibits immunostimulatory function of dendritic cells: MAPKs and translocation of NF-kappa B as potential targets. *J. Immunol.*, 174(12): 8116–8124.
- Kim, S. J., Son, T. G., Park, H. R., Park, M., Kim, M. S., Kim, H. S., ... & Lee, J. (2008). Curcumin stimulates proliferation of embryonic neural progenitor cells and neurogenesis in the adult hippocampus. *J. Biol. Chem.*, 283(21): 14497–14505.
- Kiuchi, F., Goto, Y., Sugimoto, N., Akao, N., Kondo, K., & Tsuda, Y. (1993). Nematocidal activity of turmeric: synergistic action of curcuminoids. *Chem. Pharm. Bull.*, 41(9): 1640–1643.
- Knobloch, S. M., Fan, L., & Faden, A. I. (1999). Early neuronal expression of tumor necrosis factor-alpha after experimental brain injury contributes to neurological impairment. *J. Neuroimmunol.*, 95(1-2): 115–125.

- Koracevic, D., Koracevic, G., Djordjevic, V., Andrejevic, S., & Cosic, V. (2001).** Method for the measurement of antioxidant activity in human fluids. *J Clin Pathol*, 54(5): 356–361.
- Kumar, P., Padi, S. S. V, Naidu, P. S., & Kumar, A. (2007).** Possible neuroprotective mechanisms of curcumin in attenuating 3-nitropropionic acid-induced neurotoxicity. *Methods Find. Exp. Clin. Pharmacol.*, 29(1): 19–25.
- Kunnumakkara, A. B., Guha, S., Krishnan, S., Diagaradjane, P., Gelovani, J., & Aggarwal, B. B. (2007).** Curcumin potentiates antitumor activity of gemcitabine in an orthotopic model of pancreatic cancer through suppression of proliferation, angiogenesis, and inhibition of nuclear factor- κ B-regulated gene products. *Cancer Res.*, 67(8): 3853–3861.
- Kusaka, I., Kusaka, G., Zhou, C., Ishikawa, M., Nanda, A., Granger, D. N., ... Tang, J. (2004).** Role of AT1 receptors and NAD(P)H oxidase in diabetes-aggravated ischemic brain injury. *Am. J. Physiol. Heart Circ. Physiol.*, 286(6): H2442–H2451.
- Loane, D. J., & Faden, A. I. (2010).** Neuroprotection for traumatic brain injury: Translational challenges and emerging therapeutic strategies. *Trends Pharmacol. Sci.*, 31(12): 596–604.
- Lowry, O. H., Rosebrough, N. J., Farr, A. L., & Randall, R. J. (1951).** Protein measurement with the Folin phenol reagent. *J. Biol. Chem.*, 193(1): 265–275.
- Marklund, N., & Hillered, L. (2011).** Animal modelling of traumatic brain injury in preclinical drug development: Where do we go from here? *Br. J. Pharmacol.*, 164(4): 1207–1229.
- McKinley, M. J., Albiston, A. L., Allen, A. M., Mathai, M. L., May, C. N., McAllen, R. M., ... Chai, S. Y. (2003).** The brain renin-angiotensin system: Location and physiological roles. *Int. J. Biochem. Cell Biol.*, 35: 901-918.
- Menon, V. P., & Sudheer, A. R. (2007).** Antioxidant and anti-inflammatory properties of curcumin. In *The molecular targets and therapeutic uses of curcumin in health and disease* (pp. 105-125).
- Merrell, J. G., McLaughlin, S. W., Tie, L., Laurencin, C. T., Chen, A. F., & Nair, L. S. (2009).** Curcumin-loaded poly(ϵ -caprolactone) nanofibres: diabetic wound dressing with anti-oxidant and anti-inflammatory properties. *Clin. Exp. Pharmacol. Physiol.*, 36(12): 1149–1156.
- Mihara, M., & Uchiyama, M. (1978).** Determination of malonaldehyde precursor in tissues by thiobarbituric acid test. *Anal. Biochem.*, 86(1): 271–278.

- Nishio, S., Yunoki, M., Noguchi, Y., Kawauchi, M., Asari, S., & Ohmoto, T. (1997).** Detection of lipid peroxidation and hydroxyl radicals in brain contusion of rats. *Acta Neurochir. Supplement*, 70, 84–86.
- Ozacmak, V. H., Sayan, H., Cetin, A., & Akyildiz-Igdem, A. (2007).** AT1 receptor blocker candesartan-induced attenuation of brain injury of rats subjected to chronic cerebral hypoperfusion. *Neurochem. Res.*, 32(8): 1314–1321.
- Petrillo, E. W., & Ondetti, M. A. (1982).** Angiotensin converting enzyme inhibitors: Medicinal chemistry and biological actions. *Med. Res. Rev.*, 2(1): 1–41.
- Quan, N., & Banks, W. A. (2007).** Brain-immune communication pathways. *Brain. Behav. Immun.*, 21(6): 727–735.
- Riva-Depaty, I., Fardeau, C., Mariani, J., Bouchaud, C., & Delhaye-Bouchaud, N. (1994).** Contribution of peripheral macrophages and microglia to the cellular reaction after mechanical or neurotoxin-induced lesions of the rat brain. *Exp. Neurol.*, 128: 77–87.
- Roebuck-Spencer, T., & Cernich, A. (2014).** Epidemiology and societal impact of traumatic brain injury. In *Handbook on the Neuropsychology of traumatic brain injury*, (pp. 3–23).
- Saavedra, J. M. (2012).** Angiotensin II AT(1) receptor blockers as treatments for inflammatory brain disorders. *Clin. Sci. (London, England :1979)*, 123(10): 567–590.
- Savoia, C., & Schiffrin, E. L. (2007).** Vascular inflammation in hypertension and diabetes: molecular mechanisms and therapeutic interventions. *Clin. Sci.*, 112(7): 375–384.
- Seltzer, A., Bregonzio, C., Armando, I., Baiardi, G., & Saavedra, J. M. (2004).** Oral administration of an AT1 receptor antagonist prevents the central effects of angiotensin II in spontaneously hypertensive rats. *Brain Res.*, 1028(1): 9–18.
- Sharma, D., & Vavilala, M. S. (2012).** Perioperative management of adult traumatic brain injury. *Anesthesiol. Clin.*, 30: 333–346.
- Shukla, P. K., Khanna, V. K., Ali, M. M., Khan, M. Y., & Srimal, R. C. (2008).** Anti-ischemic effect of curcumin in rat brain. *Neurochem. Res.*, 33: 1036–1043.
- Slemmer, J. E., Shacka, J. J., Sweeney, M. I., & Weber, J. T. (2008).** Antioxidants and free radical scavengers for the treatment of stroke, traumatic brain injury and aging. *Curr. Med. Chem.*, 15: 404–414.
- Somasundaram, S., Edmund, N. A., Moore, D. T., Small, G. W., Shi, Y. Y., & Orłowski, R. Z. (2002).** Dietary curcumin inhibits chemotherapy-induced apoptosis in models of human breast cancer. *Cancer Res.*, 62(13): 3868–3875.

- Springer, J. E., Azbill, R. D., Nottingham, S. A., & Kennedy, S. E. (2000).** Calcineurin-mediated BAD dephosphorylation activates the caspase-3 apoptotic cascade in traumatic spinal cord injury. *J. Neurosci.*, 20: 7246–7251.
- Thiyagarajan, M., & Sharma, S. S. (2004).** Neuroprotective effect of curcumin in middle cerebral artery occlusion induced focal cerebral ischemia in rats. *Life Sci.*, 74(8): 969–985.
- Tota, S., Kamat, P. K., Awasthi, H., Singh, N., Raghubir, R., Nath, C., & Hanif, K. (2009).** Candesartan improves memory decline in mice: involvement of AT1 receptors in memory deficit induced by intracerebral streptozotocin. *Behav. Brain Res.*, 199: 235–240.
- Uğuz, A. C., Öz, A., & Nazıroğlu, M. (2015).** Curcumin inhibits apoptosis by regulating intracellular calcium release, reactive oxygen species and mitochondrial depolarization levels in SH-SY5Y neuronal cells. *J. Recept. Signal Transduct. Res.*, 36(4):395-401.
- Wang, L., Shi, J. X., Yin, H. X., Ma, C. Y., & Zhang, Q. R. (2005).** The Influence of Subarachnoid Hemorrhage on Neurons: An Animal Model. *Ann. Clin. Lab. Sci.*, 35(1): 79–85.
- Zhou, J., Ando, H., Macova, M., Dou, J., & Saavedra, J. M. (2005).** Angiotensin II AT1 receptor blockade abolishes brain microvascular inflammation and heat shock protein responses in hypertensive rats. *J. Cereb. Blood Flow Metab.*, 25(7): 878–86.
- Zobeiri, F., Salami, S., Sadrkhanlou, R., & Peirouvi, T. (2013).** Role of mitochondria in ciprofloxacin-induced apoptosis in murine sperm cells. *Reprod. Sci.*, 20(9): 1090–1095.

تأثير الجمع بين علاج الكانديسارتان والكركومين على إصابات الدماغ في الفئران للسادة الدكتورة

سارة أحمد بركة¹، سمر سعد الدين عزب² عزة سيد محمد عوض³، ابتهاج الدمرداش²

م

¹ قسم الأدوية و السموم، كلية الصيدلة – جامعة الأهرام الكندية.

² قسم الأدوية و السموم، كلية الصيدلة – جامعة عين شمس.

³ قسم الأدوية و السموم، كلية الصيدلة – جامعة الأزهر.

تعد إصابات الدماغ بمثابة حالة طبية قاسية وأحد الأسباب الرئيسية في الوفاة والعجز وخصوصاً في صغار الشباب. وينتج عن إصابات الدماغ إستجابات معقدة تشمل الإلتهابات والأكسده و الموت المبرمج للخلايا العصبية. تسعى الدراسة التجريبية الحالية إلى تقييم تأثير الجمع بين علاج الكركومين والكانديسارتان على إصابات الدماغ في الفئران. تم تقسيم الفئران إلى ست مجموعات وهما (المجموعة الضابطة، ومجموعة إصابات الدماغ، ومجموعة إصابات الدماغ المُعالجة بالحمال، أو بالكركومين، أو بالكانديسارتان، أو الكركومين +الكانديسارتان) لمدة 7 أيام، العدد= 12 لكل منهما. تُخدر الفئران ومن ثم تُوضع تحت جهاز إسقاط الوزن لإحداث الأصابة. ثم تُقتل الحيوانات عن طريق خلع الرقبه، ويُفصل المخ سريعاً. تُظهر مجموعة إصابات الدماغ زيادة ملحوظة في محتوى مالون داي الدهايد، عامل ألفا نخر الورم، كاسبيز-3 بالمقارنة مع المجموعة الضابطة. وقد تم تحسين تلك الآثار بشكل كبير بفعل الكركومين والكانديسارتان او علاج الجمع بينهما. كما انخفضت إجمالي القدرة المضادة للأكسدة، بشكل ملحوظ في مجموعة إصابات الدماغ، و ارتفعت بشكل ملحوظ عن طريق العلاج بالكركومين أو الكانديسارتان او الجمع بينهما. ولقد أكد الفحص الهستوباثولوجي هذه النتائج المطروحة. و أخيراً تُشير هذه النتائج إلى تأثير الكركومين والكانديسارتان المضاد للإلتهابات، والمضاد لموت الخلايا المبرمج والمضادة للأكسدة. وفقاً لذلك، يمكن استخدام الكركومين أو الكانديسارتان باعتبارهما عاملاً علاجياً لإصابات الدماغ. وقد نجح نظام الجمع بين العقارين في إضافة تأثيرات أفضل من العقاقير الفردية.

كلمات البحث الرئيسية: الكركومين، الكانديسارتان، إصابات الدماغ، مضاد للأكسدة، مضاد لموت اخلايا المبرمج، مضاد للإلتهاب.