



## Minimal Invasive Computer Assisted Dental Reconstruction of Atrophic Maxilla by Zygomatic Implants Combined with Conventional Implants

Ahmed I. Basyoni<sup>1\*</sup>, Susan A. Hassan<sup>2</sup>, Nahed M. Adly<sup>3</sup>

Codex : 03/2001

azhardentj@azhar.edu.eg

http://adjg.journals.ekb.eg

DOI: 10.21608/adjg.2019.7517.1077

### ABSTRACT

**Purpose:** The aim of this study was to evaluate and apply a minimal invasive approach for reconstruction of atrophic maxilla using computer-guided implant surgery by zygomatic implants combined with conventional implants. **Material and methods:** 10 patients with severely atrophic edentulous upper arch were included in this study, each patient had 2 conventional implants placed in the anterior maxilla, and 2 zygomatic implants on either sides placed in the zygomatic bone. In all patients a computer guided approach using a computer guided stent was used for drilling the conventional and zygomatic implants. All patients followed a clinical and radiographic follow up **Results:** Zygomatic Implants success was 90.0% while conventional implants success was 80.0%. The mean  $\pm$  standard deviation values of coronal deviation were  $3.24 \pm 1.9$  mm for Zygomatic implants and  $2.9 \pm 2.5$  mm for conventional implant. The mean  $\pm$  standard deviation values of apical deviation for were  $4.2 \pm 2.5$  mm for zygomatic implants and  $2.6 \pm 2.5$  mm for conventional implants. The mean  $\pm$  standard deviation values of bone implant contact for zygomatic implant were  $19.5 \pm 5.3$  mm, the bone covering the zygomatic implant laterally were  $6 \pm 2.3$  mm, the minimum distance from the orbit were  $5.6 \pm 3.2$  mm. General satisfactions for the treatment was 8.6. **Conclusion:** The use of zygomatic implants combined with conventional implants using virtual computer guided planning and surgery was useful for reconstruction of atrophic maxilla allowing an accurate, safe, graft less, less invasive surgery and provided a high patient satisfaction.

### KEYWORDS

Minimal invasive;  
zygomatic implant;  
computer assisted.

### INTRODUCTION

The number of edentulous patients searching and asking for rehabilitation increased during the last decade. previously, patients

1. B.D.S 2003, M.Sc. 2010, private practice, Cairo

2. Professor Of Oral and Maxillofacial Surgery Department, Faculty of Dental Medicine for girls, AL-Azhar University.

3. Lecturer of Oral and Maxillofacial Surgery , Faculty of Dental Medicine for girls, AL-Azhar University.

\* Corresponding author Email: drahmedismailbasyoni@gmail.com

with edentulous maxillae and mandibles were rehabilitated with complete dentures, but they always were dissatisfied.

Dental surgeons started using other techniques to restore the edentulous atrophic maxilla with osseointegrated dental implants.

The maxilla is a very difficult arch to restore with dental implants due to its shape and form<sup>(1)</sup>.

Therefore, different solutions were invented to solve this problem, like tilted implants, Sinus lifting, use of pterygoid implants, the use of short implants and zygomatic implants<sup>(2)</sup>.

Branemark invented the first zygomatic implants to anchor the implants to the zygomatic bone that is free from bone regeneration or remodeling. The main indication of zygomatic implants was to rehabilitate patients suffering from maxillectomy. The indication of zygomatic implant started to expand to cover the patients suffering from atrophic maxillae<sup>(1)</sup>.

With the installation of zygomatic implants bilaterally in the molar/ premolar regions of the maxilla, installing of two to four regular dental implants in the premaxilla region<sup>(3)</sup>.

Minimal invasive surgery has many advantages as having minimal postoperative bleeding, pain, swelling, surgery time and healing time.<sup>(4)</sup> The accelerated growth of computer guided surgery and minimal invasive surgery is very clear making it a new gold standard for dental implant surgeries<sup>(5)</sup>.

## PATIENTS AND METHODS

### Study Design

The present study was conducted on 10 patients; the patients were selected from the outpatient clinic, Oral and Maxillofacial Surgery Department, Faculty of Dental Medicine for Girls, Al-Azhar University. The implants were placed in patients who required complete rehabilitation of their atrophic edentulous maxilla, Each patient had 2 conventional implants

placed in the anterior maxilla, and 2 zygomatic implants on either sides placed in the zygomatic bone.

They were selected according to the following criteria

### Inclusion criteria

1. Patients with severely atrophic edentulous upper arch (Cawood class IV, V, VI) that could not be restored with other type of treatment.
2. Patients who had at least 8-12 mm vertical bone height in anterior maxilla to allow installation of at least 2 conventional implants.

### Exclusion criteria

1. Patients with any systemic disease that might interfere with dental implants placement and/or osseointegration e.g. uncontrolled diabetes, hypertension and osteoporosis, etc.
2. Heavy smoker (> 20 cigarettes daily) and patients with history para-functional habits (e.g. clenching or bruxism, etc.) were also excluded.
3. Intraoral pathological lesion, related to maxilla, maxillary sinus and zygoma.
4. Acute sinusitis

### Implants used in the study

The implants used were from Dentoflex (Dentoflex Comércio e Indústria de Materiais Odontológicos, São Paulo, Brazil)

- 1- The implants used in the premaxilla were **Implant flex**
- 2- The implants used for posterior implant were **Implant Zygomatic**

### Radiograph (type and protocol)

During this study all radiographic settings were fixed, A preoperative panoramic radiograph was made, Post-operative panoramic radiograph interval was done at the day after surgery and then 3 months and 6 months.

For CBCT a preoperative CBCT was taken using the Dual scan protocol, Postoperative CBCT was made one month after surgery.

### Virtual planning

After merging the CBCT with the Denture CBCT, the planning of the implants positions using the in2guide Ondemand3D App (Ondemand3D Technology Inc. 310 Goddard Way, Suite 250 Irvine, CA 92618 USA ), and the 3D Printer was used for fabrication of the surgical guide(ENVISIONTEC, INC. 15162 S. Commerce Dr. Dearborn, MI 48120, USA). The Dicom files obtained from the

CBCT scan were loaded to in2guide Ondemand3D App, Two virtual implant models in the software implant library were used to represent the posterior (Zygomatic) and anterior (conventional) implants respectively. The desired implant sites were identified through the software to achieve the best prosthetic and functional position possible. Fig(1)

After accepting the implant position, the virtual guide was designed with the in2guide Ondemand3D App. and the guide was fabricated. The virtual implant file was then sent to the additive manufacturing machine for guide fabrication.

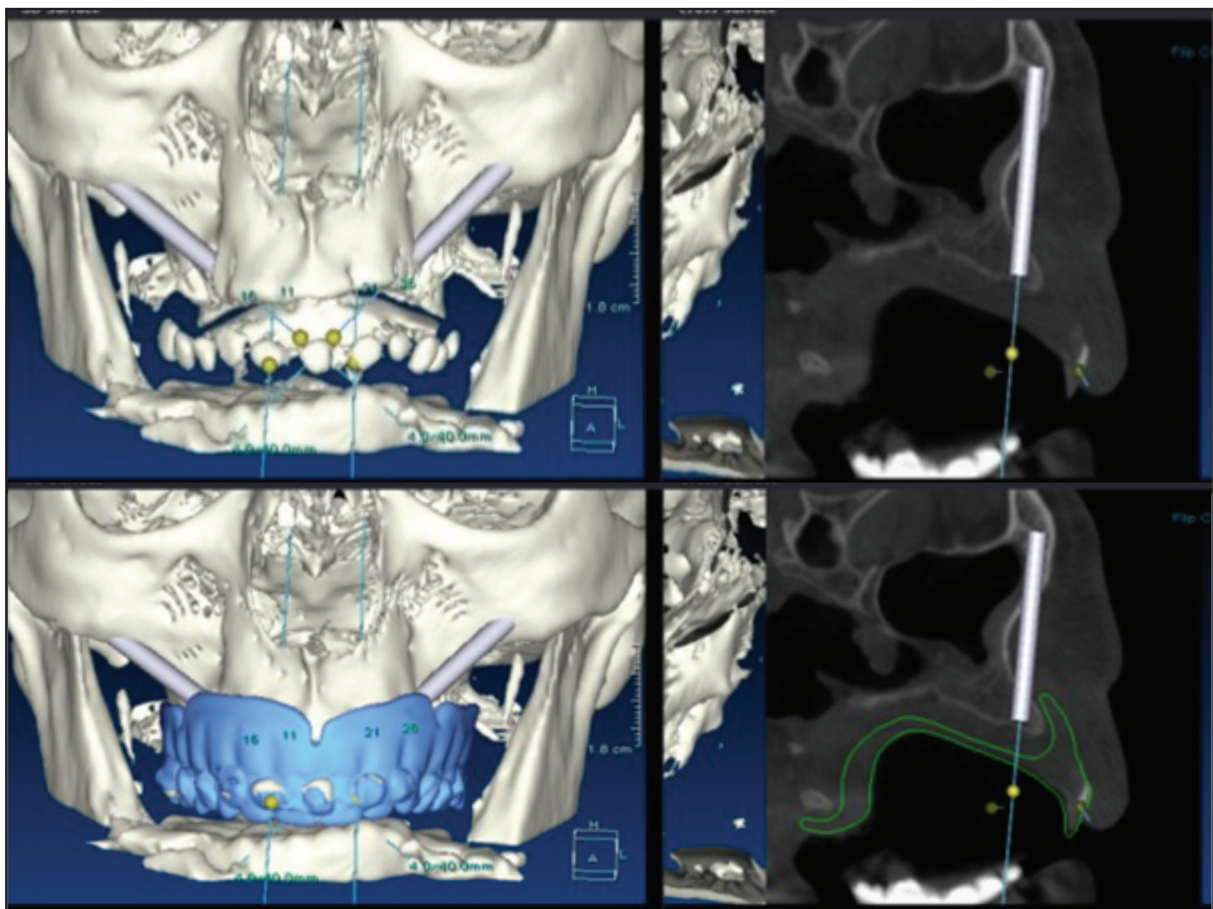


Figure (1) Showing different views and steps for the implant planning in the software by inserting the appropriate size implant and checking its position surgically as in Fig a and prosthetically as in fig b by checking its position in the bone in different sections and also with the help of the denture already merged in the CBCT

### Surgical guide fabrication

The 3D virtual stent was processed and the 3D Printer used for fabrication of the surgical guide: Envision Tech. using e shell 600 material which is a CE certified and class- IIa biocompatible resin according to ISO 10993.

During this process the virtual stent was sliced to multiple layers and the stent is built using Direct light projection technology to build the stent from light cure resin material.

### Surgical Guide Fixation

The surgical stent was inserted inside the patient's mouth; it was adapted and held in place by the anchoring screws.

### Surgical procedure

#### Flap Design and Reflection

Vestibular incision from canine to first maxillary molar area was performed just over the margin of the surgical guide connected with another incision extended till the inferior aspect of the zygomatic bone.

The flap was reflected to expose the lateral wall of the maxillary sinus as well as the Zygomatic process anteriorly inferiorly and superiorly up to infraorbital foramen and its posterior border the flap was retracted from the superior border of zygoma. (fig2)

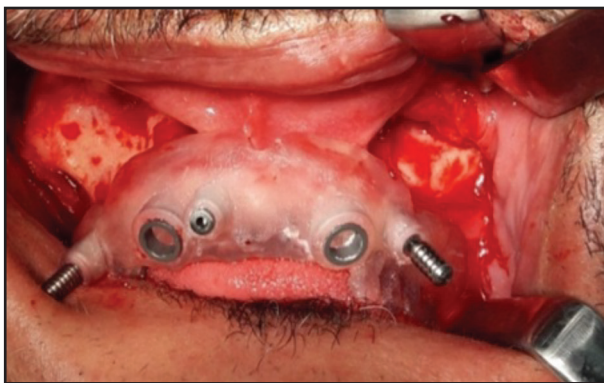


Figure (2) Showing the flap design after its reflection

### Preparation of the implant bed and implant insertion:

#### Zygomatic implants

Implant osteotomy was performed using two sequential drills (2.70 mm Tri-Helical Boom Drill, 2.9 mm zygomatic drill). Every drill has a specially designed "drill guide" that was slightly larger than drill diameter. e.g (The inner diameter of the drill guide was 2.8 for the 2.7 drill and the inner diameter of the drill guide was 3 for the 2.9). The implants were carried on by their fixture mount and inserted manually into position at the prepared osteotomy site till their tip reached the superior border of zygoma. The fixture mount was removed.

When all implants were secured in place, the covering screw was inserted and screwed over the implant .

#### Conventional implants

Implant osteotomy was performed with three sequential drills(2.3, 2.8 and 3.5 mm) Also according to the system used every drill had a specially designed "drill guide. The inner diameter of the drill guide was 2.4, 2.9, and 3.6mm for the 2.3, 2.8 and 3.5 drills respectively; After finishing the osteotomy for the implants, the implants were carried on by their fixture mount and inserted manually into position at the prepared osteotomy site. The fixture mount was removed.

#### Wound closure

The surgical wound was irrigated with sterile saline then the flap was repositioned back and sutured with 3-0 vicryl suture in a continuous suture manner.

#### Post-operative Clinical assessment

The follow-up schedule was the day after the operation, 1 week, 1 month, 3 months and 6 months.

#### Post-operative Radiographic assessment

Sequential digital panoramic radiograph taken for all cases at the predetermined time intervals

(1 day, 3 months and 6 months) for evaluation of osseointegration following implant placement.

Also a postoperative CBCT was made one month after surgery for comparison of the planned and actual position of the implants

### **Evaluation of patient satisfaction**

A simplified evaluation of patient satisfaction was done for the study patient after at least 3 month from the prosthesis delivery.

### **Statistical Analysis:**

Statistical Analysis was made using SPSS version 20 for windows (SPSS INC.,Chicago,IL, USA).

Numerical data were explored for normality by checking the data distribution and using Kolmogorov-Smirnov and Shapiro-Wilk tests.

For parametric data, paired t-test was used to compare between the two implant types. For non-parametric data, Wilcoxon signed-rank test was used to compare between the two implant types. Qualitative data (Success rate) were presented as frequencies and percentages. McNemar's test was used to compare between the two implant types.

## **RESULTS**

### **Demographic data**

The present study was conducted on 10 patients; 5 males (50 %) and 5 females (50%). The mean  $\pm$  standard deviation values of age were  $41.9 \pm 14.9$  years with a minimum of 20 and a maximum of 61 years old. Each patient received 4 Implants giving a total of 40 implants

### **Success and Failure**

The follow up was done after one week, one month, 3 months and 6 months. All patients showed mild swelling in the first week that gradually decreased and disappeared completely after 2 weeks.

All patients showed excellent soft tissue healing at incision lines without dehiscence except the failed implant cases. No postoperative complications or bleeding, no swelling, no numbness, no sinus infection, no oroantral communication, no eyelid congestion, no chronic pain, no encroachment of critical anatomic structure was detected either clinically or radiographically.

All Implants showed high initial stability immediately and at 6 months they showed excellent stability and perfect solid ring sound on tapping with a solid instrument except for the failure cases which showed mobility and dull ring sound on tapping. The successful implants were 34/40 giving a success rate of 85.0 % for both Zygomatic and conventional implants.

Zygomatic implants success rate was 90% (18/2) while conventional implants success rate was 80% (16/4)

### **Coronal Deviation**

The coronal deviation of the actual implant position from the plan was found to be of mean  $\pm$  standard deviation values of for Zygomatic implants were  $3.24 \pm 1.9$  mm with a minimum of 0.0 and a maximum of 6.2 mm. (fig 3)

The mean  $\pm$  standard deviation values of coronal deviation for conventional implants were  $2.9 \pm 2.5$  mm with a minimum of 0.4 and a maximum of 9.9mm .

### **Apical Deviation**

The apical deviation of the actual implant position from the plan was found to be of mean  $\pm$  standard deviation values for zygomatic implant were  $4.2 \pm 2.5$  mm with a minimum of 0.0 and a maximum of 9.8 mm. The mean  $\pm$  standard deviation values of apical deviation were  $2.6 \pm 2.5$  mm with a minimum of 0.5 and a maximum of 8.4

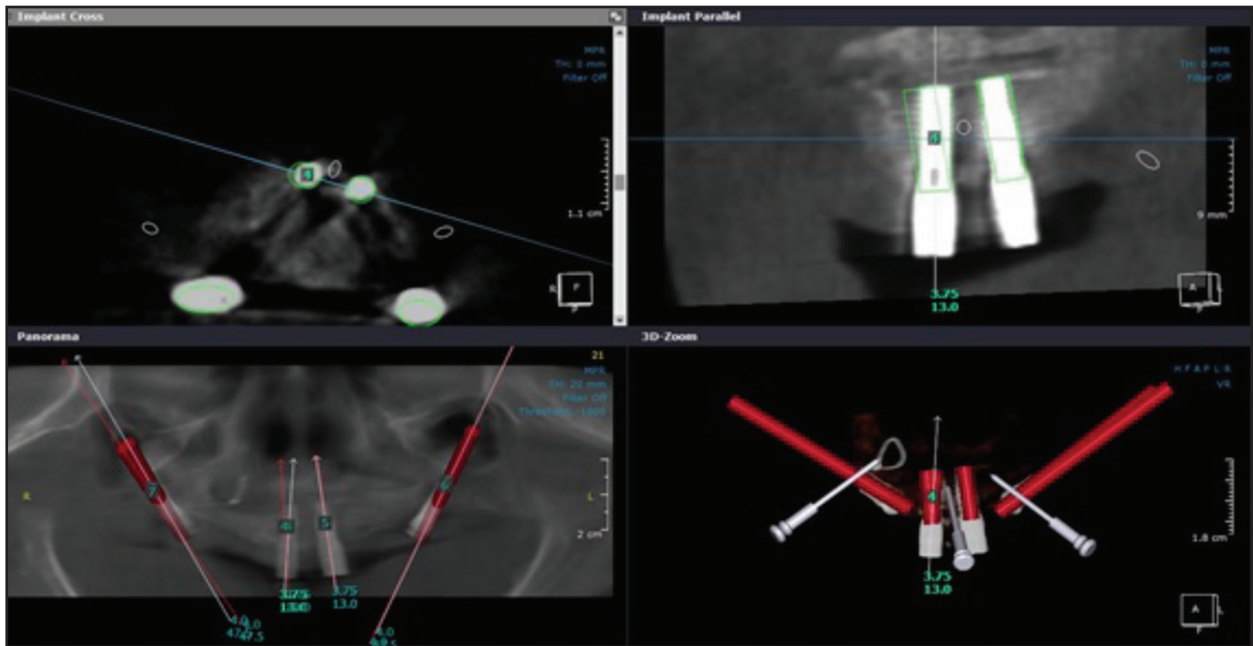


Figure (3) Showing the steps of software calculation for coronal deviation

### Bone to implant contact

The mean ± standard deviation values of BIC cd were 19.5 ± 5.3 mm with a minimum of 12.5 and a maximum of 34.6 mm.(fig 4)

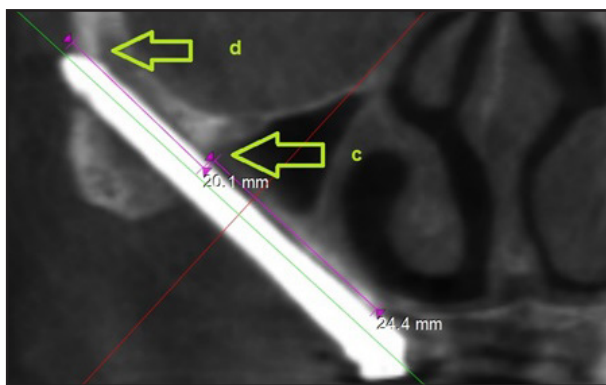


Figure (4) Showing the intramalar length

### Amount of bone covering Zygomatic implant laterally

The mean ± standard deviation values of average bone covering the zygomatic implant laterally were 6 ± 2.3 mm with a minimum of 1.4 and a maximum of 9.5 mm

### Minimum distance to Orbit

The mean ± standard deviation values of the minimum distance from the orbit were 5.6 ± 3.2 mm with a minimum of 1.1 and a maximum of 11.5 mm.

### Evaluation of patient satisfaction

The results from the patient satisfaction questionnaire showed general satisfactions for the treatment was 8.6.

### DISCUSSION

The computer-guided surgery is proving to be a better approach compared to classical surgical and prosthodontic procedures. With all advantages of being minimally invasive, it also enhances the prosthetics result and makes the surgery a prosthetically driven surgery<sup>(5)</sup>.

Various studies have confirmed survival rates of almost 98%-100% for zygomatic implants. And proved that the zygomatic bone is excellent for the anchorage of implants<sup>(2)</sup>.

The zygomatic implants was also proved to be a perfect solution for patients suffering from

atrophic maxillas and want to prevent bone grafting (Graftless solution)<sup>(6)</sup>.

The patients selected in the present study suffered from severely atrophic edentulous upper arch (Cawood class IV, V, VI)

In this study computer guided surgery was done using a special software that was used for planning of the implants positions (in2guide Ondemand3D App), and the 3D Printer was used for fabrication of the surgical guide ( Envision Tech)

Computer guided planning allows precise and accurate placement of zygomatic implants and conventional implants in the most appropriate position which differ from one patient to other following the guidelines advocated by several studies to achieve successful results<sup>(5,7,8)</sup>.

The flap design used in this study included 2 incision lines, one vestibular incision from canine to first maxillary molar area was performed just over the margin of the surgical guide previously fixed in its position continued by a releasing incision extended along the inferior aspect of the zygomatic bone to provide adequate exposure of zygomatic process superiorly up to its posterior border in addition to the lateral wall of the maxillary sinus. There was no need to retract palatal flap as the surgical guide was precisely fixed on the palatal mucosa and the drilling was done through the preplanned holes in the surgical guide.

The main advantages of this flap over the classical Branemark flap was, good visibility, decreased intraoperative bleeding, no postoperative need for palatal stent to stabilize the palatal flap, less pain, less swelling and discomfort, early and faster healing of soft tissue and enhance the quality of life<sup>(4)</sup>.

From the statistical analysis of the study, Zygomatic implants success rate was 90.0% while conventional implants success rate was 80.0%, lower success rate of the conventional implants in the present study could be attributed to poor bone

quality and also due to the difference in flexibility and length of the conventional implants and the zygomatic implants which leads to concentration of the load on the conventional implants.

Through the clinical follow-up periods at 1, 3 and 6 months, all successful cases showed absence of pain as well as no pus or bleeding on probing for both zygomatic and conventional implants, the failed zygomatic implant case appeared after 3 months with failure of oseointegration to the zygomatic bone ( the case was suffering before the surgery from a previous accident with several fractures in the maxilla and the zygoma which may be reason plus he was a smoker), while the failed conventional implant cases showed within the follow-up with pain, bleeding on probing and failure of oseointegration which is most probably due to the bad quality and quantity of the remaining alveolar bone in the premaxilla in most of the cases.

Regarding the anchorage of the zygomatic implant inside the zygomatic bone which is the main factor for success of zygomatic implant and was the main priority during virtual planning and surgery. All zygomatic implants fulfilled the anchorage requirement for good anchorage in zygomatic bone with mean  $19.5 \pm 5.3$  mm , with a minimum 12.5 mm and a maximum 34.6 mm. Thus 50% of the zygomatic implant length was anchored in the zygoma .This was achieved by maximizing the anchorage during the virtual planning to increase the success. This is in agreement with the results which showed BIC of  $15.3 \pm 5.6$  mm (range, 4.9 to 32.9 mm) in the zygomatic bone. On average,  $35.9\% \pm 11.7\%$  (range, 12.2% to 67.3%) of the implant came into contact with the zygomatic bone<sup>(9,10)</sup>.

The amount of bone covering the zygomatic implant laterally is a very important factor for success which shows a mean  $\pm$  standard deviation of  $6 \pm 2.3$  mm with a minimum of 1.4 and a maximum of 9.5 mm, the safety of the orbit was also evaluated by measuring the distance between the implant and the inferior lateral orbital wall, the mean  $\pm$  standard

deviation values were  $5.6 \pm 3.2$  mm with a minimum of 1.1 and a maximum of 11.5 mm.

In order to measure the accuracy of virtual computed planning of the implants, an overlap of the planned and post-operative position was made using the same planning software and it was found that, there was apical and coronal deviation. The mean  $\pm$  standard deviation values of coronal deviation for zygomatic implant were  $3.4 \pm 1.9$  mm with a minimum of 0.0 and a maximum of 6.2 mm. While the mean  $\pm$  standard deviation values of coronal deviation for conventional implants were  $2.9 \pm 2.5$  mm with a minimum of 0.4 and a maximum of 9.9 mm.

Regarding the apical deviation the mean  $\pm$  standard deviation values of apical deviation for zygomatic implant were  $4.2 \pm 2.5$  mm with a minimum of 0.0 and a maximum of 9.8 mm. and also the mean  $\pm$  standard deviation values of apical deviation for conventional implants were  $2.6 \pm 2.5$  mm with a minimum of 0.5 and a maximum of 8.4 mm. These results were in accordance with study made a study on human cadavers and found that the biggest deviation was 2.7 mm<sup>(12)</sup>. These results were also agreed with the results<sup>(13-17)</sup>.

From experience gained in this study, deviation between the planned and post-operative position of zygomatic implant could be attributed to more than one factor

The multiple steps including hardware, software, and surgery procedure which affected the accuracy. The shift of long zygomatic drill within the key during drilling with difficulty in manipulation and working under stress as a result of posterior location of point of entry at premolar molar area especially with patient with limited mouth opening or patients who have teeth in the lower jaw. Minute deviation between the drill and the key with the long drills used for zygomatic implants, this small deviation in the coronal area due to shifting of the drill in the key which may be reflected with relatively larger deviation in apical. The nature of Zygomata bone

(compact bone and its shape) which leads to the slippage of the initial drill at the zygomatic surface. The minor change in the surgical guide position during the operation with all cases may be due to the atrophic ridge and the compressibility of the soft tissue present over atrophic ridge. The surgical guide used in this study controlled the entry point but did not control the drill direction especially at the zygomatic bone.

Regarding the general satisfaction for the treatment the average was 8.6 which is close to the results<sup>(18)</sup> which was 9 which shows good satisfaction of the patient to the treatment.

## CONCLUSIONS

Based on the findings of the present study the following conclusions could be drawn.

1. The use of zygomatic implants combined with conventional implants in a minimal invasive approach was useful for reconstruction of atrophic maxilla with a high success rate over 90%.
2. Virtual computer guided planning and surgery allows accurate, safe less invasive surgery as it saves time, money, effort of operation team and decreases the need for of highly skilled and trained operator in complex surgeries as it simplifies and enhances the accuracy of the total operation.
3. Zygomatic implant offered a graftless solution with decrease in the number of operation, cost of the operation as well as recovery time.
4. The guide in this study provided control for entry point for drilling but did not control the exit point to the zygomata, so the partially guided approach used in this study provided a chance to correct any error from the guide during drilling and reduced the complexity of the implant placement and increases the safety for vital structures, so the use other surgical guides that can overcome this problem should be used .



5. Zygomatic implants provided a high patient satisfaction with treatment as high as (8.6), thus improving the quality of life which could be further promoted by using the flapless technique with immediate loading.

## REFERENCES

1. 1- Ishak MI, Abdul Kadir MR, Sulaiman E, Abu Kasim NH. Finite element analysis of different surgical approaches in various occlusal loading locations for zygomatic implant placement for the treatment of atrophic maxillae. *Int J Oral Maxillofac Surg* 2012; 41: 1077–89.
2. 2- Davo R, Malevez C, Rojas J. Immediate function in the atrophic maxilla using zygoma implants: A preliminary study. *J Prosthet Dent* 2007; 97: S44-S51.
3. 3-Block MS, Haggerty CJ, Fisher GR. Nongrafting Implant Options for Restoration of the Edentulous Maxilla. *J Oral Maxillofac Surg* 2009; 67:872-81.
4. 4-Doan N, Du Z, Crawford R, Reher P, Xiao Y. Is flapless implant surgery a viable option in posterior maxilla? A review *Int. J Oral Maxillofac Surg* 2012; 41: 1064–71.
5. 5-Papaspyridakos P, White GS, Lal K.: Flapless CAD/CAM-guided surgery for staged transition from failing dentition to complete arch implant rehabilitation: A 3-year clinical report. *J Prosthet Dent.*2012; 107:143-50.
6. 6-Schmidt BL, Pogrel MA, Young CW, Sharma A. Reconstruction of extensive maxillary defects using zygomatic implants. *J Oral Maxillofac Surg.* 2004; 62: 82-9.
7. 7-Eitan M, Adi L, Horia B, Ziv M. Full-Mouth Implant-supported Rehabilitation with a Flapless Surgical Technique: A Treatment Approach using Computer-assisted Oral Implant Surgery. *IJOICR* 2001; 2: 171-5.
8. 8-Xiaojun C, Ming Y, Yanping L, Yiqun W, Chengtao W. Image guided oral implantology and its application in the placement of zygoma implants. *Comput Methods Programs Biomed.* 2009; 93:162-73.
9. 9-Balshi TJ, Wolfinger GJ, Shuscavage NJ, Balshi SF. Zygomatic bone-to-implant contact in 77 patients with partially or completely edentulous maxillas. *J Oral Maxillofac Surg.* 2012;70:2065-9.
10. 10-BertosQuílez J, Guijarro-Martínez R, Aboul-HosnCentenero S, Hernández-Alfaro F. Virtual quad zygoma implant placement using cone beam computed tomography: sufficiency of malar bone volume, intraosseous implant length, and relationship to the sinus according to the degree of alveolar bone atrophy. *Int J Oral Maxillofac Surg.*2018; 47:252-61.
11. 11-Vrielinck L, Politis C, Schepers S, Pauwels M, Naert I. Image-based planning and clinical validation of zygoma and pterygoid implant placement in patients with severe bone atrophy using customized drill guides. Preliminary results from a prospective clinical follow follow-up study. *Int J Oral Maxillofac Surg.*2003; 32:7–14.
12. 12-Van Steenberghe D, Malevez C, Van Cleynenbreugel J, BouSerhal C, Dhoore E, Schutyser F et al. Accuracy of drilling guides for transfer from three-dimensional CT-based planning to placement of zygoma implants in human cadavers. *Clin Oral Implants Res.* 2003; 14:131–6.
13. 13-Wittwer G, Adeyemo WL, Schicho K, Gigovic N, Turhani D, Enislidis G. Computer-guided flapless trans-mucosal implant placement in the mandible: A new combination of two innovative techniques. *Oral Surg Oral Med Oral Pathol Oral Radiol Endod.*2006;101:718–23.
14. 14-Cristache CM, Gurbanescu S. Accuracy Evaluation of a Stereolithographic Surgical Template for Dental Implant Insertion Using 3D Superimposition Protocol. *Int J Dent.* 2017.
15. 15-Giordano M, Ausiello P, Martorelli M. Accuracy evaluation of surgical guides in implant dentistry by non-contact reverse engineering techniques. *Dent Mater.*2012;28: 178-85.
16. 16-Moon SY, Lee KR, Kim SG, Son MK. Clinical problems of computer-guided implant surgery. *Maxillofac Plast Reconstr Surg.* 2016; 24;1-15
17. 17-Lanis A, Padiál-Molina M, Gamil R, Alvarez del Canto O. Computer-guided implant surgery and immediate loading with a modifiable radiographic template in a patient with partial edentulism: A clinical report. *J Prosthet Dent.*2015;114:328-34.
18. 18-Almeida PHT, Salvoni AD, França, FMG. Evaluation of satisfaction of individuals rehabilitated with zygomatic implants as regards anesthetic and sedative procedure: A prospective cohort study. *Ann Med Surg (Lond).* 2017; 1;22-9.