



Available online at Journal Website  
<https://ijma.journals.ekb.eg/>



## Original article

# Surgical Treatment of Unstable Pelvic Ring Fracture by Anterior Plating of Sacroiliac Joint

Mohamed Mustafa Elmenawy; Fathy Hamza Salama; Samir Ahmed El-Shoura; Ammar Fathy Abd-ELhamied Hussein

Department of Orthopedics, Damietta Faculty of Medicine, Al-Azhar University, Egypt

**Corresponding author: Ammar Fathy Abd-ELhamied Hussein**

Email: [ammarfathy1@domazhermedicine.edu.eg](mailto:ammarfathy1@domazhermedicine.edu.eg)

Received at: November 27, 2019; Revised at: December 21, 2019; Accepted at: January 6, 2020; Available online at: January 6, 2020

DOI: [10.21608/ijma.2020.20216.1046](https://doi.org/10.21608/ijma.2020.20216.1046)

## ABSTRACT

**Background:** Pelvic ring fractures is not uncommon, and represented a challenge in their fixation. Anterior plating of sacroiliac joint seems to have less good outcome and low complications rate when compared to other approaches.

**Aim of the work:** The aim of this work is to assess the results of surgical treatment of unstable pelvic ring fractures with stabilization of sacroiliac joint with anterior plating, the results assessed clinically and radiologically.

**Patients and methods:** Fifteen patients with unstable pelvic ring fractures were included. All underwent full history taking, clinical and radiological evaluations and scheduled for anterior plating of sacroiliac joint. All were followed up for at least 15 months postoperatively.

**Results:** Radiologically, 53.3% had anatomic, 20.0% had moderate and 26.7% had nearly anatomic results. Clinically, satisfaction was reported by 80.0%. The union was achieved in 86.7% and no complications was reported among 80.0%. Complications were significantly associated with non-satisfactory outcome, and radiological outcome was significantly associated with AO-OTA classification.

**Conclusion:** Anterior pelvic plating combined with percutaneous sacroiliac joint screw fixation is effective treatment for unstable pelvic ring fractures with high success rate and low complications.

**Keywords:** Fractures; Pelvic ring; Fixation; Anterior; Plate.

This is an open access article under the Creative Commons license [CC BY] [<https://creativecommons.org/licenses/by/2.0/>]

Please cite this article as: Elmenawy MM, Salama FH, El-Shoura SA, Hussein AFA. Surgical Treatment of Unstable Pelvic Ring Fracture by Anterior Plating of Sacroiliac Joint. IJMA 2020; 2[1]: 241-246.

## INTRODUCTION

Pelvic fractures accounts for 1% to 3% of all skeletal fractures and are responsible for 2% of hospital admissions for orthopedic treatment.<sup>[1]</sup> High speed motor car accidents are responsible for increased number of patients with severe injuries associated with pelvic fractures. Mortality rate-associated with pelvic fractures reported to be 8.6 to 19.1%; the rate increased to 18.0% to 25.0% in complicated fractures with unstable ring fracture or concomitant soft tissue trauma <sup>[2]</sup>. The management of pelvic fractures had been improved over years. However, the associated mortality rate continues to be around 10.0%, and this is due to associated head trauma or massive liver or pelvic bleeding<sup>[3,4]</sup>.

Pelvic fractures peaks in the second, third and fourth decades of life, then in patients older than sixty-five years [A bimodal pattern]<sup>[5]</sup>. Fracture severity ranged from benign avulsions to severe fracture dislocations with complete pelvic disruption. However, most of injuries are stable, as they are due low energy injury, occur in younger patients who withstand avulsion of tendon-bone complex, or occur in elderly patients fallen from a standing position <sup>[6]</sup>. Most low energy pelvic fractures are relatively easy to be treated with rest, analgesics and stretching, until the discomfort has abated sufficiently to allow resumption of normal activities. Thus, complex pelvic trauma is defined as a pelvic fracture with a significant concomitant soft tissue injury in the pelvic region [neurovascular, urogenital and visceral. <sup>[7]</sup> Air bags and seatbelts were added to vehicles to guard against serious injuries. However, certain types of injuries still happen with increasing relative frequency. Disruption of symphysis pubis associated with fracture of the sacrum is one of such injuries, lead to a vertical unstable Tile C-type pelvic injury. <sup>[8]</sup>

Open pelvic fractures are due to direct communication between fracture and either the exterior by a drain or pack used in initial treatment, or direct communication between the fracture and any of vagina, rectum or perineum. Passive procedure in the form of waiting for self-tamponade is not an effective intervention in severe cases of complex pelvic injuries, as it could be associated with rupture of all para-pelvic compartments. Currently, complex pelvic injuries require early, aggressive surgical treatment with hemostasis.

Further advancements in in open reduction and internal fixation [ORIF] of the pelvis concentrates on reduction of additional soft tissue injury and implants fracture<sup>[9]</sup>

## AIM OF THE WORK

The aim of this work is to assess the results of surgical treatment of unstable pelvic ring fractures with stabilization of sacroiliac joint with anterior plating, the results assessed clinically and radiologically.

## PATIENTS AND METHOD

In this study fifteen patients suffered from unstable pelvic ring fracture were operated upon with anterior plating of sacroiliac joint in the Department of Orthopedics at Damietta, Al-Azhar University hospital. The injury was due to traffic accident in 9, fall from a height in 4 and crashed from falling objects in 2 cases, the duration of follow up ranged from June 2016 to September 2019. Patient with the following criteria were included in the study: Age between 20 and 60 years; within 2 weeks of trauma, of grades B2, B3, C1, C2 or C3 according to AO-OTA classification, and closed fractures. On the other side, exclusion criteria were: open fractures, B1 according to AO-OTA classification, old age or neglected fracture for more than 2 weeks. Before being included to the study, the patients were asked to sign an informed consent to participate after the nature of the study had been explained. In addition, the study protocol was approved by the local research and ethics committee of our institution. All patients were submitted to full history taking [personal history, complaints, past and family history]. In addition, all underwent full clinical and radiological evaluation. Initially, radiologic assessment was in the anterior-posterior and inlet-outlet views of pelvis. Three-dimensional pelvis CT scan was routinely carried out to obtain more information about fracture pattern and to help designing the operative plan.

**Operative procedure:** General anesthesia used for all patients, in supine position, on a radiolucent table. The injured leg freely draped, both knees and hips slightly flexed aiming to relax the iliopsoas muscle. The modified Stoppa-4 approach was used. From anterior superior iliac supine (ASIS) to posterior part of iliac crest and up to the flank, a long incision was made. The

dissection continued down to mark between gluteus medium and abdominal muscles. Incision was then created through such avascular line, abdominal muscles were raised, iliopsoas separated off from the top of the crest to the inner table. Exposure of the inner wall of iliac crest was achieved and iliacus muscle swept away by posterior dissection to reach the SI joint and ala of the sacrum. The pelvic prim was reached by inferior dissection of iliacus muscle. One Homan retractor was inserted into the anterior sacral ala and a second retractor over the prim to provide additional exposure. Anteriorly, we secure SJ joint by approaching it over the iliac wing, with direct vision, reduction and fixation of short plates and screws. The surgical fixation achieved by a two or three holes 3.5 mm DCP, placed across SI joint anterior aspect; two three-hole plates spanning from the anterior surface of sacral ala to internal

iliac fossa and 4.0 mm fully threaded cancellous bone screws were used. Repair of the wound was achieved layer by layer, and a suction drain was left. Early walking was encouraged 2-3 days after operation with the usage of a wheelchair or crutches, when the pain was tolerated. Matta and Saucedo grading system was used for postoperative radiographic evaluation. The grades were: anatomic, nearly anatomic, moderate and poor. On the other side, the sacroiliac screw location was grades as adequate or inadequate. Overall radiologic outcomes were assessed by union time and quality of reduction. Radiological measures of the residual displacement of the pelvic ring was calculated from the difference in the height of femoral head from a line perpendicular to the long axis of the sacrum.

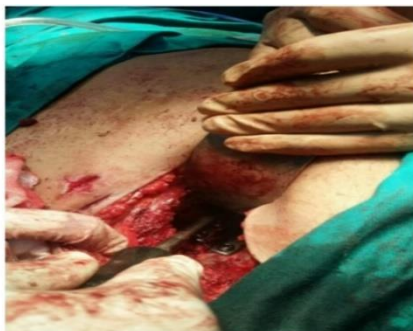

Figure [1]: Approach for anterior plating for sacroiliac joint disruption

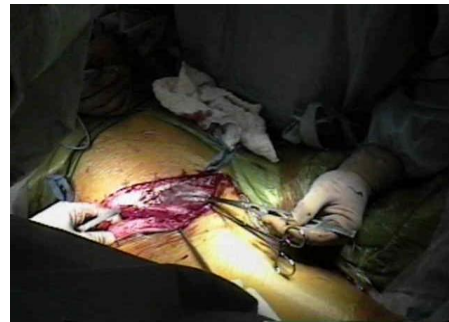

Figure [2]: Ilioinguinal approach for sacroiliac joint

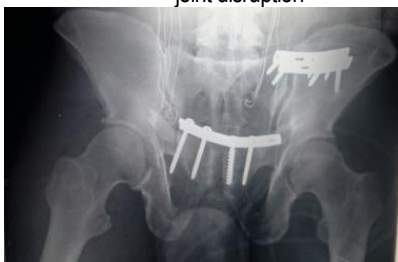

Figure [3]: The prebent plate was applied on the disrupted anterior ring

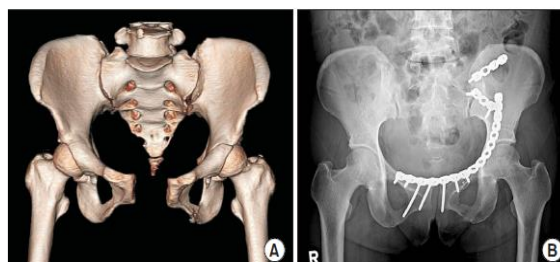


Figure [4]: [A] Unstable injury of the pelvic ring reported in a female, aged 43- year. [B] Stable anterior ring fixation with posterior fixation could increase stability of the whole pelvis.

## RESULTS

The average time between injury and surgery was 4.2 days [range, 1-11]. Four patients [26.6%] underwent surgery during the first 24 hours after injury, while 10 patients [66.6%] underwent surgery with the 10 days after injury. The fixation was tried as early as possible. Remaining 1 patient [6.7%] operated at the day 11 after injury and the delay was due to severe combined injuries and unfitness for surgery at the time of injury. The patient age ranged

from 20 to 60 years, the mean age was 41.2 years; three patients were younger than or equal to 30 years; 3 were from 30 to 40 years; 5 were from 31 to 40 years and 4 were older than 50 years. Twelve patients [76.7%] out of 15 patients had associated injuries [urinary bladder injury] or other site fractures [distal radius]. The follow up period was less than 15 months for 3 patients, 15 to 25 months for 7 patients, 26 to 30 months for 3 patients and 31 to 35 months for 2 patients. Table [1] represented

outcome among studied populations.

Radiologically, 8 [53.3%] had anatomic, 3[20.0%] had moderate and 4[26.7%] had nearly anatomic results. Clinically, satisfactory outcome was reported by 12 patients [80.0%] [Excellent in 8 patients and good in 4]; the clinical outcome was moderate in 2 patients and poor in one patient. The union was reported in 13 patients [86.7%] and non-union was reported in 2 patients [13.3%]. No complications was reported among 12 patients [80.0%], while each of anterior plate breakage, postoperative infection and screw loosening was reported in one patient [6.7%]. Table [2] presented the relation between clinical outcome and other

variables. No significant association was observed between clinical outcome and each of patient age, sex, the healing, AO-OTA classification, or mechanism of injury. However, complications was significantly associated with non-satisfactory outcome. In addition, radiological outcome was significantly associated with AO-OTA classification, when nearly anatomic outcome was reported in B3 and C1; and moderate outcome was associated with C2 and C3 grades. Otherwise, no significant association was reported between radiological results and mechanism of injury [Table 3]. Pre- and postoperative results of a 48 years old male patient who had AO type C1-3 fractures were presented in figures 5 to 7

**Table [1]:** Outcome among studied populations

Variables		Statistics
Radiologic results	Anatomic	8[53.3%]
	Moderate	3[20.0%]
	Nearly anatomic	4[26.7%]
Clinical results	Satisfactory	12[80.0%]
	Non-satisfactory	3[20.0%]
Clinical results grading	Excellent	8[53.3%]
	Good	4[26.7%]
	Moderate	2[13.3%]
	Poor	1[6.7%]
Healing	Union	13[86.7%]
	Non union	2[13.3%]
Complications	No complications	12[80.0%]
	Anterior plate breakage	1[6.7%]
	Postoperative infection	1[6.7%]
	Screw loosening	1[6.7%]

**Table [2]:** Relation between clinical outcome and different variables

Variables		Clinical results		Test	P
		Satisfactory [12]	Non-satisfactory [3]		
Age	≤30 y	2 [16.7%]	1[33.3%]	1.66	0.64
	31-40y	2[16.7%]	1[33.3%]		
	41-50y	4[33.3%]	1[33.3%]		
	>50y	4[33.3%]	0 [0.0%]		
Sex	Male	8[66.7%]	2 [66.7%]	0.001	1.0
	Female	4 [33.3%]	1[33.3%]		
Healing	Union	11 [91.7%]	6[66.7%]	1.29	0.25
	Non union	1[8.3%]	1[33.3%]		
AO-OTA classification	B2	4[33.3%]	1[33.3%]	1.87	0.59
	B3	4[33.3%]	1[33.3%]		
	C1	3[25.0%]	0 [0.0%]		
	C2	1[8.3%]	0 [0.0%]		
	C3	0 [0.0%]	1[33.3%]		
Mechanism of injury	Traffic accident	7[58.3%]	2 [66.7%]	0.59	0.74
	Fall from a height	3[25.0%]	1[33.3%]		
	Crash from falling objects	2[16.7%]	0 [0.0%]		
Complications	None	11[91.7%]	1[33.3%]	9.27	0.026*
	Plate leakage	1[8.3%]	0 [0.0%]		
	PO infection	0 [0.0%]	1[33.3%]		
	Screw loosening	0 [0.0%]	1[33.3%]		



Table [3]: Relation between radiological results and AO-OTA classification and mechanism of injury

Variables		Radiological results			Test	Value
		Anatomic	Moderate	Nearly anatomic		
AO-OTA classification	B2	5[62.5%]	0[0.0%]	0[0.0%]	15.50	0.044*
	B3	2[25.0%]	1[33.3%]	2[50.0%]		
	C1	1[12.5%]	0[0.0%]	2[50.0%]		
	C2	0[0.0%]	1[33.3%]	0[0.0%]		
	C3	0[0.0%]	1[33.3%]	0[0.0%]		
Mechanism of injury	Traffic accident	5[62.5%]	2[66.7%]	2[50.0%]	0.97	0.91
	Fall from a height	2[25.0%]	1[33.3%]	1[25.0%]		
	Crash from falling objects	1[12.5%]	0[0.0%]	1[25.0%]		

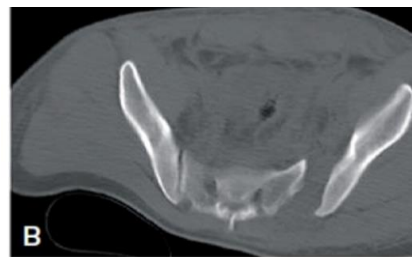
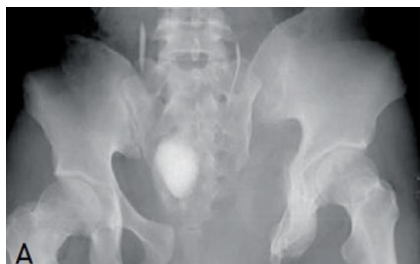

Figure [5]: show preoperative anteroposterior [A] & lateral [B] views of the pelvis.

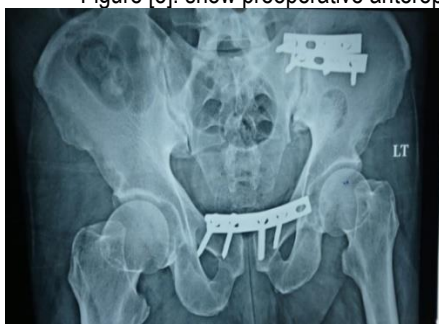

Figure [6]: show post reduction and fixation AP view.

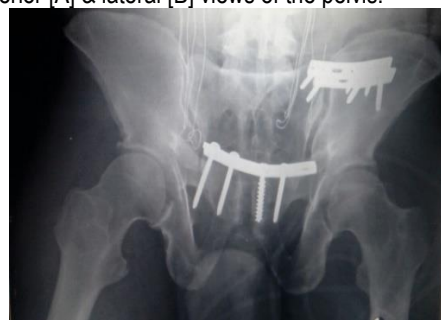

Figure [7]: show AP views after 3 month of fixation.

### DISCUSSION

The pelvic ring is very important portion of the skeleton and serves two main functions: protects the viscera and confers stability to support the body weight<sup>[10]</sup>. Pelvic injuries account from 10.5 to 29% mortality rates because of complications due to displacement of the pelvic ring, which is usually associated with multiple injuries and significant blood loss because of hemorrhage from iliac arteries or presacral venous plexus. The clinical examination of a critically injured patient is usually limited. Thus, diagnostic radiographs represent an efficient means to determine the appropriate plan of care<sup>[11]</sup>. Comparable to results of the present work, Choy et al.<sup>[12]</sup> included thirty-two patients [21 males and 11 females; mean age 41 years]. B2 was

reported in 11, B3 in 8, C1 in 9, C2 in 2 and C3 in 2 cases. The mechanisms of injury were traffic accident, fall from a height and crashed from falling objects in 20, 9 and 3 patients respectively. Seventeen patients [53%] had associated injuries or other site fractures; the average duration between injury and surgery was 4.2 days [range 0-11]. Elmanawy<sup>[13]</sup> found that males represented 80% of studied subjects. Their patient's ages ranged from 20 to 50 years. All patients presented with acute pelvic pain with a history of a road traffic accident in 90% and falling from height in 10%.

In the present work the outcome radiological was anatomic in 53.3%, but clinical outcome was satisfactory among 80.0%, and poor outcome was reported only in one subject [6.7%] and union

healing was reported in 86.7% and complications was reported among 3 patients [20%]; and complications was associated significantly with non-satisfactory clinical outcome. In addition, radiological outcome was significantly associated with AO-OTA classification. In line with these results, Choy et al.<sup>[12]</sup> reported that the clinical results excellent (16 patients), good (10 cases), moderate (4 patients) and poor among 2 patients. The 2 out of 7 moderate reductions had poor functional outcome with residual neurologic complaints. Also, they said that all fractures but 3 patients were united within 16<sup>th</sup> postoperative week. Three non-unions reported at anterior pubic ramus. Among them, one of type C2 non-union occurred with a plate breakage. Since it was asymptomatic, further interventions were not required. They reported screw loosening among 3 cases, 2 of anterior plate breakage and 1 of postoperative infection. Sagi et al.<sup>[14]</sup> reported that anterior plating for the vertically unstable pelvic fractures increases the stability of the fixation construct. Thus, there were no further displacement reported among any patient after further displacement after initial fixation and high rate of satisfactory results was obtained. These results confirmed in the present work. **Pohlemann<sup>[15]</sup>** believe that the initial injury severity is closely co-related with radiologic and clinical data. We could not confirm such results, and it may be explained by small number of cases included in the present work.

We could conclude that, anterior pelvic plating combined with percutaneous sacroiliac joint screw fixation is an effective therapeutic possibility for unstable pelvic ring fractures since it has shown a high rate of functional success and a low complications rate.

#### **Financial and Conflict of interest disclosure**

Authors declare that there was no conflict of interest.

#### **REFERENCES**

1. **Stahel PF, Hammerberg EM.** History of pelvic fracture management – a review. *World J Emerg Surg.* **2016;** 11:8. [DOI:10.1186/s13017-016-0075-4].

2. **Papakostidis C, Giannoudis PV.** Pelvic ring injuries with haemodynamic instability: efficacy of pelvic packing, a systematic review. *Injury.* **2009;** 40[4]: 53–61. [DOI: 10.1016/j.injury.2009.10.037].

3. **Schmal H, Markmiller M, Mehlhorn AT, Sudkamp NP.** Epidemiology and outcome of complex pelvic injury. *Acta Orthop Belg.* **2005;** 71[1]:41–7. [PMID:15792206].

4. **Halawi MJ.** Pelvic ring injuries: Emergency assessment and Management. *J Clin Orthop Trauma* **2015;** 6: 252-8. [DOI: 10.1016/j.jcot.2015.08.002].

5. **Hak DJ, Smith WR, Suzuki T.** Management of hemorrhage in life threatening pelvic fracture. *J Am Acad Orthop Surg.* **2009;** 17:447–57. [DOI: 10.5435/00124635-200907000-00005].

6. **Khurana B, Sheehan SE, Sodickson AD, Weaver MJ.** Pelvic ring fractures: what the orthopedic surgeon wants to know. *Radiographics.* **2014;** 34[5]:1317–33. [DOI: 10.1148/rg.345135113].

7. **Trainham L, Rizzolo D, Diwan A, Lucas T.** Emergency management of high-energy pelvic trauma. *JAAPA.* **2015;** 28:28–33. [DOI: 10.1097/01.JAA.0000473359.00222.a0].

8. **Galluzzo M, Gaudino F, Addeo G.** Pelvic Trauma: Bone. Chapter 20, in: V. Miele, M. Trinci [eds.], *Diagnostic Imaging in Polytrauma Patients,* Springer International Publishing AG. **2018;** 7:433-50.

9. **Woodley SJ, Kennedy E, Mercer SR.** Anatomy in practice: the sacrotuberous ligament. *N Z J Physiother.* **2005;** 33: 91–4.

10. **Wan Faisham WI, Nawaz AH, Joehaimey J, Sallehuddin AY, Wan Z.** Anterior stabilization of sacroiliac joint for complex pelvic injuries. *Malays J Med Sci.* **2009;** 16:47–51. [PMID: 22589666].

11. **Suzuki T, Hak DJ, Ziran BH, Adam AS, Stahel PF, Smith RW.** Outcome and complications of posterior transiliac plating for vertical unstable sacral fracture. *Injury* **2009;** 40:405–9. DOI:10.1016/j.injury. 2008. 06.039.

12. **Choy WS, Kim KJ, Lee SK, Park HJ.** Anterior Pelvic Plating and Sacroiliac Joint Fixation in Unstable Pelvic Ring Injuries. *Yonsei Med J.* **2012;** 53 [2]: 422-6.

13. **Elmanawy M, Elshoura S, Youssef S, Salama F.** Treatment of sacroiliac joint disruption with anterior stabilization. *Egypt Orthop J.* **2015;** 4:45-51. [DOI: 10.4103/1110-1148.163148].

14. **Sagi HC, Militano U, Caron T, Lindvall E.** A comprehensive analysis with minimum 1-year follow-up of vertically unstable transforaminal sacral fractures treated with triangular osteosynthesis. *J Orthop Trauma.* **2009;** 23[5]:313–9. [DOI:10.1097/BOT.0b013e3181a32b91].

15. **Pohlemann T, Culemann U, Tosounidis G, Kristen A.** [Application of the pelvic C-clamp]. *Unfallchirurg.* **2004;** 107[12]:1185–91. [English abstract] [DOI:10.1007/s00113-004-0896-6]