

The Potential Effect of Vitamin D against Bone Loss and Vascular Calcification in Ovariectomized Rats: Possible Association with Serum Nitric Oxide

¹Gehan Elwakeel, ¹Gehan A. Shaker, ¹Mohammad Ghalwash, ²Mohamed Youssef, ²Sara Eldusoky

¹Department of Medical Physiology, Faculty of Medicine, Mansoura University, Egypt, 35516

²MERC, Faculty of Medicine, Mansoura University, Egypt, 35516

Received: 27 August 2019
Accepted: 22 Nov 2019
Available online: 1 Jan 2020

Abstract

Many epidemiological studies have shown an association between osteoporosis and peripheral vascular disease in postmenopausal women. So the aim of the present study is to investigate the possible effect of vitamin D against postmenopausal bone loss and vascular calcification in adult rats. **Methods:** 24 female Sprague Dawley rats were divided into 4 groups (N = 6 per group): Group I: control sham-operated rats. Group II: sham operated rats treated with vitamin D. Group III: control ovariectomized (OVX) rats. Group IV: OVX rats treated with vitamin D, rats were injected with 0.04 µg/kg calcitriol active vitamin D intraperitoneally (calcitriol) 3 times a week for 4 weeks. Serum level of estradiol, calcium, phosphorus and osteoblastic markers (alkaline phosphatase and osteocalcin) were measured. Serum levels of lipid profile, parathormone and nitric oxide were also evaluated. The bone and the aortic wall were prepared for histopathological study. In comparisons to the ovariectomized rats, active vitamin D caused significant attenuation of the bone loss, biomechanical fragility and delayed the onset of vascular calcification in the aortic wall. Also it improved the lipid profile, serum nitric oxide levels and suppressed parathyroid hormone level. **Conclusion:** The administration of vitamin D has a beneficial effect on the bone quality and also a delaying effect on the onset of aortic vascular calcification in ovariectomized rats, with suggestion of possible association with serum nitric oxide.

Keywords

- vitamin D
- Bone loss
- Vascular calcification
- Nitric oxide

Corresponding Author: Gehan Elwakeel, Department of Medical Physiology, Faculty of Medicine, Mansoura University, Egypt, Email: gehanelwakeel19@gmail.com; Mob. +201005583338

INTRODUCTION

Osteoporosis is a chronic bone disease, characterized by increased bone fragility and risk of fractures. The density of bone mineralization is also rapidly reduced with disruption of bone microarchitecture and alteration of the amount of various non-collagenous bone proteins (1). Vascular calcification is currently accepted as an actively regulated process similar to bone formation involving many complex cell-related and chemical events involving the active participation of a number of calcification inducers/promoters and inhibitors (2). Many epidemiological studies have shown an association between osteoporosis, coronary heart disease, stroke, and peripheral vascular disease in the elderly or postmenopausal women. These results indicate that osteoporosis and atherosclerosis might be linked by common risk factors or pathological mechanisms (3).

Vitamin D is a multifunctional hormone that exerts effects on most of the organ systems (4, 5). Calcitriol or 1, 25-dihydroxyvitamin D is the active form of vitamin D, formed by dual hydroxylation in the liver and kidney. Active vitamin D metabolites exert biological activities mainly through the vitamin D receptor (VDR) (6). Circulating 1, 25-dihydroxyvitamin D, acting through VDR, can enhance the intestinal absorption of calcium and phosphate, while can also suppress the biosynthesis of parathyroid hormone (7). It appears likely that autocrine, paracrine, and endocrine functions of vitamin D can influence vascular structure, functions, and remodeling (8).

Nitric oxide (NO) is an important molecule produced by endothelium which plays a

variety of vital roles in humans such as reproduction, inflammation, vasodilation, cardiac function, oxidative stress, gene transcription, translation, and posttranslational modifications of the proteins (9, 10). Exercise and mental stress reduce bioactivity of NO which leads to constriction of coronary arteries. Reduced NO level also facilitates vascular inflammation which may cause oxidation of lipoproteins and foam cell formation, the precursor of atherosclerotic plaque (11). The disturbance of its endothelial function may lead to hypercholesterolemia, systemic hypertension, diabetes, congestive heart failure, atherosclerosis, pulmonary hypertension, estrogen deficiency, hyperhomocysteinemia, and aging (12).

Vitamin D respond to nitric oxide synthases (NOs) gene which suggests that both molecules have functional association (13). The active vit D (1, 25-dihydroxyvitamin D) regulates the production of NO and /or expression of inducible NOs (iNOs) in different cells including endothelial cells, osteoblasts, astrocytes (14, 15).

Because of the wide spread usage of vitamin D in postmenopausal women to preserve the bone mass and because of the close association between bone density and peripheral artery disease. This work was provided to investigate the possible protective role of vitamin D against osteoporosis and vascular calcification in ovariectomized rats and aiming to clarify a possible mechanism involving nitric oxide.

Material and Methods

Experimental animals:

This study was carried on 24 Sprague Dawley female rats (medical experimental

Research Center) aged about Six month. They were maintained under standard conditions of temperature 22 ± 2 °C with regular 12 h light/12 h dark cycle and allowed free access to standard laboratory food and water. All experimental procedures were performed in accordance with guidelines of the institutional animal care and use committee of Mansoura University.

Ovariectomy:

Six month-old female Sprague Dawley rats (180 ± 20 g) were used. After a week of acclimatization, rats were subjected to an ovariectomy operation. 12 rats were anesthetized with thiopental sodium (30mg/kg, i.p.), an incision of about 10 mm was made in each of the dorsal flank regions of the rat to expose ovaries. The fallopian tubes were sutured at the most distal ends and ovaries were excised. The other 12 rats in sham-operated groups were subjected to the same procedure, anesthetized, laparotomized and sutured without excising their ovaries to serve as sham non-OVX control. The incisions were sutured and dressed with povidone iodine for 7 d.

Experimental plan:

Rats were divided into four groups (6 rats per group). Group I: control sham-operated rats. Group II: sham operated rats treated with vitamin D. Group III: control ovariectomized (OVX) rats. Group IV: OVX rats treated with vitamin D. Vitamin D was administered intraperitoneally 3 times a week for four weeks in the form of 0.04 mg/Kg calcitriol (16). Control animals received vehicle alone by oral gavage.

At the end of the four weeks of the study all rats were sacrificed by an overdose of anesthesia. Blood was collected by cardiac puncture for biochemical measurements. The

collected blood was allowed to clot and centrifuged at 7000 r.p.m. for 15 minutes. The serum samples were separated carefully and stored at -20 °C for subsequent biochemical assay.

Tissue harvesting for histopathology

Histopathology of the aortic wall

After euthanasia, the thorax was opened under the xiphoid process and the anterior chest wall was removed. An incision was made in the right atrium to provide an outlet for blood and perfusate. The left ventricle was then punctured with 21-G needle inserted in the direction of the left ventricular out flow tract. The needle was attached to a perfusion system that provided initial perfusion with normal saline at 100 mmHg. The saline perfusion was continued until the outflow from right atrium incision was clear and liver appeared exsanguinated.

The animal then perfused with 70% ethanol for 3 minutes and ascending aorta was harvested from annulus to the origin of brachiocephalic trunk. Ascending aorta (AAO), is a portion of the aorta commencing at the upper part of the base of left ventricle. The harvested tissue was fixed in 70% ethanol for 24 hours at 4 °C and embedded in paraffin. Horizontal sections (3-5 μ m thick) were cut for hematoxylin and eosin (H & E) staining, and then examined using light microscopy.

Histopathology of Bone Microarchitecture

The left femur was removed, dissected free of soft tissue, and fixed with 10% neutral buffered formalin for 24 hour at room temperature, dehydrated in 95% ethanol, and then embedded in paraffin. Horizontal sections (5 μ m thick) were cut for hematoxylin and eosin (H & E) staining, and then examined using light microscopy. The

thickness of the trabeculae in the lower end of the bone (epiphysis) was measured using a calibrated ocular micrometer.

Biochemical analysis

Serum lipid profile including total cholesterol, Low density lipoprotein (LDL) and high density lipoprotein (HDL) was assayed using calorimetric kit. Total cholesterol (CHOD – POD – Enzimatico colorimetrico), Triglycerides (GPO – POD. Enzymatic colorimetric), LDL (cholesterol LDL reactiveo precipitante, polivinil sulfato, polietilenglicol), HDL (Enzchronm TMAF assay kit). The serum calcium level was assayed using calorimetric kit (France). Serum phosphorus level was assayed using calorimetric kit. Serum vitamin D level was assayed using calorimetric vit D kit (05894913190V7 <http://e-Ladoc-roche.com>).

The markers of osteoblastic activity were measured in serum such as alkaline phosphatase and osteocalcin using alkaline phosphates kit (Quimica Clinica Aplicada, Spain) and osteocalcin – ELISA kit (Biosource, Europe S.A.) respectively (17).

Detection of parathormone using ELISA kit

Serum parathormone level was assayed using (Elisa kit (α b23093) (18). It is sandwich ELISA using a biotinylated detection antibody and streptavidin-HRP. Sandwich ELISAs allow for the detection and quantification of an analytic in a sample by using known analyte concentrations as standards and plotting absorbance of known concentrations versus known standard concentrations. This allows calculating the amount of analyte present in the sample (18).

Detection of estradiol using ELISA kit

Serum estradiol level was assayed using estradiol ELISA kit (NeoDin Ca./Ltd, Korea).

Serum specimens were stored refrigerated at (2 °C) for up to (2°C – 8 °C) for 5 days to one month. If storage time exceeds 5 days, store frozen at (-20 °C) for up to one month. Reagent preparation: 20X Enzyme conjugate: Prepare 1X working solution at 1:20 with assay diluents (e.g. Add 0.1 ml of the E2 enzyme conjugate concentrate to 1.9 ml of assay diluents). Wash Buffer: Prepare 1X Wash Buffer by adding the contents of the bottle (25 ml, 20X) to 475 ml of distilled or deionized water, and store at room temperature (20 – 25 °C).

Assay procedure: Dispense 25 μ L of standard, specimens and controls into appropriate wells. Dispense 100 μ L of working reagent of Estradiol enzyme conjugate into each well. Mix well by shaker for 10 – 20 seconds. Incubate at room temperature (20 – 25 °C) for 120 minutes. Remove liquid from wells and wash wells three times with 300 μ L of 1X wash buffer. Blot on absorbance paper or paper towel. Dispense 100 μ L of reagent into each well. Gently mix for 10 seconds. Incubate at room temperature (20 – 25 °C) for 30 minutes. Stop the reaction by adding 50 μ L of Stop solution to each well and gently mix for 30 seconds. Read absorbance at 450 nm with a micropalte reader within 15 minutes.

Detection of osteocalcin using ELISA kit

Osteocalcin ELISA kit applies the competitive enzyme immunoassay technique utilizing a polyclonal anti-OC antibody and an OC-HRP conjugate. The assay sample and buffer are incubated together with OC-HRP conjugate in pre-coated plate for one hour. After the incubation period, the wells are then incubated with a substrate for HRP enzyme. The product of the enzyme-substrate reaction forms a blue colored complex. Finally, a stop solution is added to stop

the reaction, which will then turn the solution yellow. The intensity of color is measured spectrophotometrically at 450 nm in a microplate reader. The intensity of the color is inversely proportional to the OC concentration since OC from samples and OC-HRP conjugate compete for the anti-OC antibody binding site. Since the number of sites is limited, as more sites are occupied by OC from the sample. Fewer sites are left to bind OC-HRP conjugate. A standard curve is plotted relating the intensity of the color (OD) to the concentration of standards. The OC concentration in each sample is interpolated from this standard curve (17).

Detection of NO using colorimetric assay kit

Nitric oxide serum level was assayed using colorimetric kit (Biodiagnostic and research reagents). **Dilution of standard:** Dilute 2 mmol/L standard sodium nitrite solution with deionized water to a serial concentration. The recommended dilution gradient is as follows: 300, 200, 150, 100, 40, 20, 10, 0 $\mu\text{mol/L}$. **Pre-treatment:** the standard tube put 200 μL of Different concentrations of sodium nitrite (μL) and 200 μL of the serum sample in sample tube. Then add 200 μL reagent 1 and 100 μL reagent 2 to both standard and sample tube, Mix fully and stand for 15 min at room temperature, centrifuge it at 3100 g for 10 min. Take 160 μL of the supernatant for the following procedure. Then put 80 μL of Chromogenic reagent, Mix thoroughly for 2 min, stand for 15 min at room temperature, measure the OD of each well with micro-plate reader immediately at 550 nm wavelength.

Statistics analysis

Statistical analysis was performed using SPSS package 20. The data were presented as mean \pm standard deviation of the mean ($X \pm SD$). The means of the different groups were compared globally using the analysis of variance ANOVA. P value <0.05 were considered significant.

Results

The current study revealed significant increase in the levels of total cholesterol, LDL, HDL and triglycerides level in the ovariectomy group (group III), as compared to all other groups (group I, II). Note specially the marked improvement of all the parameters in the ovariectomized rats administered vitamin D (group IV) from the beginning of the study (table 1 & fig 1A).

In the present study, there was significant decrease in both vitamin D and nitric oxide levels in the ovariectomy group (group III) as compared to all other groups. Whereas the ovariectomized group treated with vitamin D (group IV) showed significant increase in the serum nitric oxide level. There was also significant increase in level of vitamin D the ovariectomized group treated with vitamin D (group IV) and the sham group treated with vitamin D (group II) as compared to the sham group (group I) (table 2).

The serum estradiol level was decreased significantly in the ovariectomy group as compared to the sham group (group I). Also there was significant decrease in the serum estradiol level in the ovariectomy group treated with vit D (group IV) and the sham group treated with vit D (group II) as compared to sham group (group I) but still significantly higher than that in ovariectomy group (group III) (table 2).

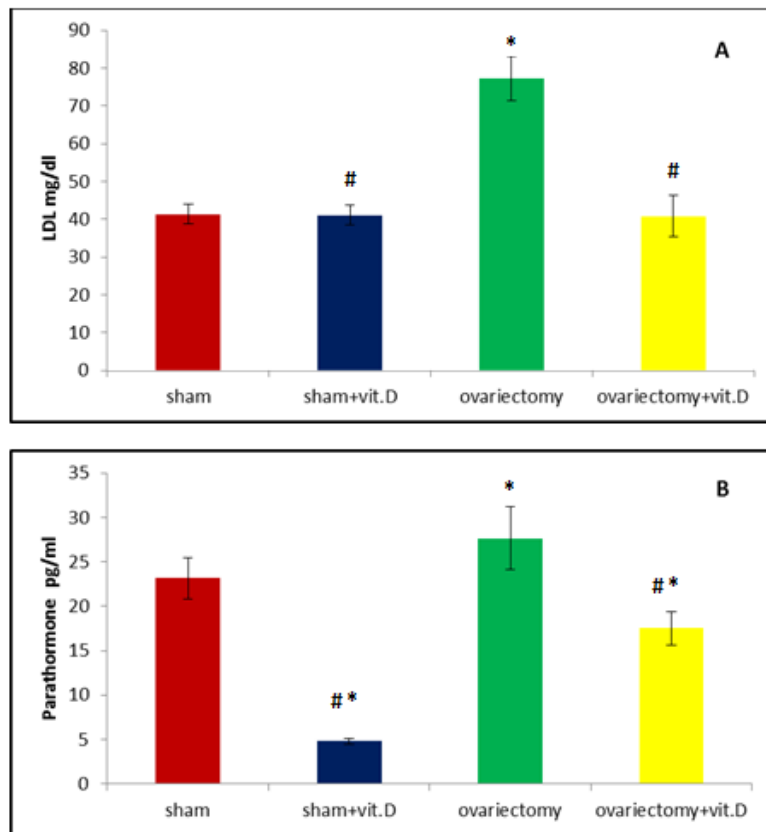


Figure 1: A) serum level of LDL mg/dl in different experimental groups. B) serum parathormone level in different experimental groups. *significant compared to sham group, # significant compared to ovariectomy group.

Table (1): Effect of vitamin D on lipid profile in ovariectomized rats

	I Sham	II Sham + vit D	III OVX	IV OVX + vit D
Chol (mg/dl)	95.83±6.33	105.50±3.08*	109.33±4.36*	58.50±4.18*,#
LDL (mg/dl)	41.33±2.58	41.00±2.60#	77.16±5.84*	40.83±5.45#
HDL (mg/dl)	41.00±2.60	41.16±2.85#	49.81±1.48*	44.50±3.08#
TG (mg/dl)	60.83±2.31	60.50±5.04#	131.50±7.39*	78.83±4.30#

The data represent the mean ± standard error (n = 6). OVX: ovariectomy, vit D: vitamin D. *significant compared to sham group. # significant compared to ovariectomy group. P < 0.05 is considered significant.

Table (2): Effect of vit D on serum level of nitric oxide and estradiol in ovariectomized rats

	I Sham	II Sham + vit D	III OVX	IV OVX + vit D
Vit D (ng/ml)	29.66±2.16	87.50±3.08#,*	15.45±1.66*	58.50±4.79#,*
NO (mmol/L)	4.36±1.89	13.29±1.88*	3.92±1.60	14.03±1.08#
Estradiol (pg/ml)	54.66±3.38	41.66±3.20#,*	16.00±3.03*	28.50±1.87#,*

The data represent the mean ± standard error (n = 6). OVX: ovariectomy, vit D: vitamin D. *significant compared to sham group. # significant compared to ovariectomy group. P < 0.05 is considered significant.

The current study revealed significant decrease in both calcium and phosphorus level in the ovariectomy group (group III) as compared to all other groups. Meanwhile sham treated with vit D (group II) revealed significant increase in these two parameters as compared to the sham group (group I) (table 3). Whereas, it was found that the

As regard serum osteocalcin and alkaline phosphatase levels there were significant increase in these two parameters in the ovariectomy group (group III) as compared to the sham group (group I) (table 3). However there was significant decrease in the alkaline phosphatase level in the sham group treated with vitamin D (group II) and the ovariectomy group treated with vitamin D (group IV) as compared the ovariectomy group (group III), but still significantly higher than that in the sham group (group I). Also the osteocalcin level was significantly decreased in the ovariectomy group treated with vitamin D (group IV) as compared the ovariectomy group (group III), but still higher as compared to the sham group (group I) (table 3).

As regard the histopathological study of bone it was revealed that, in sham operated group

parathormone level significantly increased in the ovariectomy group (group III) as compared to all the other groups. Also there was significant decrease in the parathormone level in the sham group treated with vit D (group II) and the ovariectomy group treated with vit D (group IV) as compared to the sham group (group I) (fig 1 B).

(group I) showed normal average sized cortical bone trabeculae enclosing marrow spaces (fig 2 A). Meanwhile in ovariectomy group (group III) showed small sized cortical bone trabeculae enclosing wide erythropoietic marrow spaces (fig 2 B). Whereas in ovariectomy treated with vitamin D group (group IV) showed average sized cortical bone trabeculae compared to the control group (group I) (fig 2 C).

Histopathology of the aortic wall revealed that, in sham operated group (group I) showed showing normal section prepared aortic a wall from the aorta (fig 3 A). But in ovariectomy group (group III) showed section prepared from aortic wall reveal early signs of calcification (fig 3 B). Whereas in ovariectomy treated with vitamin D group (group IV) showed section prepared from the aortic wall reveal normal aortic wall (fig 3 C).

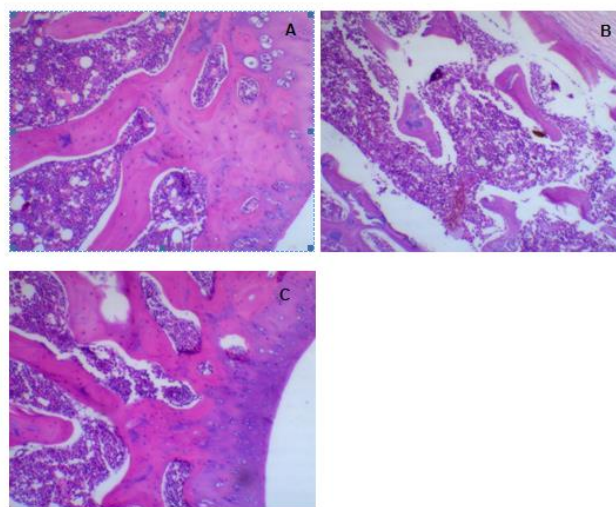


Figure 2: **A)** group I : average sized cortical bone trabeculae enclosing marrow spaces (H& E). **B)** group III : small sized cortical bone trabeculae enclosing wide erythropoietic marrow spaces (H& E). **C)** group IV : average sized cortical bone trabeculae compared to the control group (I) (H&E).

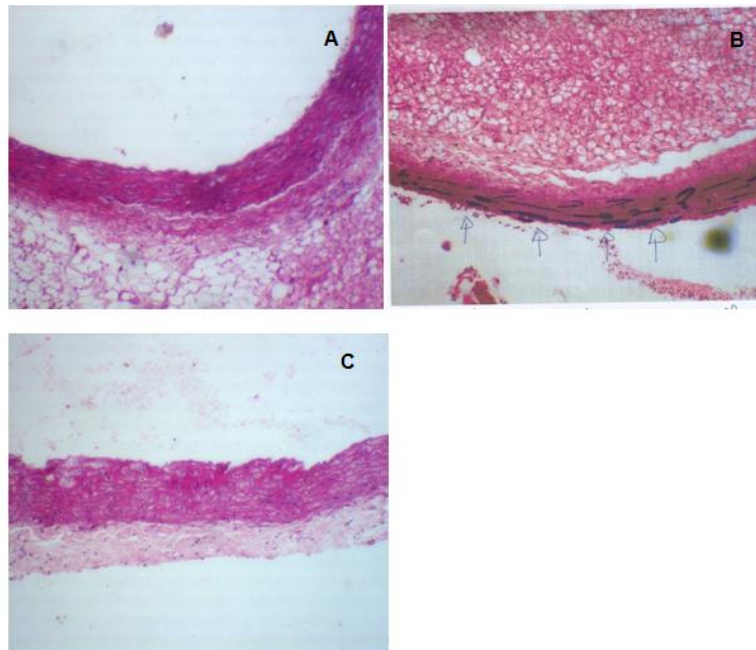


Figure 3: A) group I : showing normal section prepared aortic a wall from the aorta (H & E). B) group III : section prepared from aortic wall showing early signs of calcification (arrows) (H & E). C) group VI : section prepared from the aortic wall : showing normal aortic wall (H & E)

Table (3): Effect of vitamin D on osteoporosis related biochemical indices in ovariectomized rats

	I Sham	II Sham + vit D	III OVX	IV OVX + vit D
Ca ⁺² (mg/dl)	9.08±0.28	10.81±0.79 ^{#,*}	8.15±0.18 [*]	8.93±0.30
PO ₄ (mg/dl)	7.76±0.30	9.41±0.43 ^{#,*}	5.16±0.33 [*]	8.58±0.38 ^{#,*}
Alk P (I.U/ml)	242.0±7.94	273.16±4.87 ^{#,*}	312.33±19.83 [*]	266.0±12.06 ^{#,*}
Osteocalcin (ng/dl)	45.86±6.55	47.83±3.78 [#]	84.58±6.2 [*]	55.76±6.06 ^{#,*}

The data represent the mean ± standard error (n = 6). OVX: ovariectomy, vit D: vitamin D, Alk P: alkaline phosphatase. *significant compared to sham group, # significant compared to ovariectomy group. P < 0.05 is considered significant

Discussion

Although the most effective method to reduce the rate of post menopausal bone loss is estrogen replacement therapy, it may be accompanied by side effects. Considerable attention has been given to the nutritional factors that can prevent estrogen deficiency associated bone loss. The (ovariectomized) OVX rat model has been used in our work because of its ability to

simulate the various clinical human syndromes deriving from osteoporosis (19).

Based on the values of histopathological analysis of bone microarchitecture in OVX rats, signs of osteoporosis were observed in sections from the femur and also signs of vascular calcification in the aortic wall. Signs of osteoporosis included small sized cortical bone trabeculae enclosing wide erythropoietic marrow spaces. These features are in line with a previous

finding in osteoporotic femoral head and neck of senile persons (20). Also by histopathological analysis of the aortic wall, there was early sign of calcification. It seems that the duration was not so enough to produce extensive calcification. These features are in line with previous findings of Kiel et al., 2001 (21). Who demonstrated that osteoporotic patients have a higher incidence of arterial calcification and their lateral lumbar spinal radio graphs reveal dense calcium deposits of the aorta situated directly adjacent to osteopenic vertebrae.

However histopathological studies from ovariectomized rats receiving vitamin D (0.04 µg/kg of calcitriol injected intraperitoneal 3 times a week for one month) showed near average sized bone trabeculae compared to the sham group. Also there was nearly absent Ca^{+2} deposits in the aortic wall. Vitamin D deficiency was observed in our work in the ovariectomized rats as a significant decrease in its level as compared with the sham group. These results agree with Simsek et al., 2005 (22). Vitamin D deficiency in case of estrogen deficiency could be mediated by an impairment of 25-hydroxy vitamin D1 α -hydroxylase (1-OHase) activity (23). This effect could be either due to an alteration of the protein stability of renal 1-OHase or a change in rate of protein translation by ovariectomy (24). The mature osteoclast release enzymes to breakdown bone matrix ultimately releasing calcium and other minerals into the circulation. If the serum free Ca^{+2} level remains low, the parathyroid gland is stimulated. Release of parathyroid hormone (PTH) causes increased renal reabsorption of Ca^{+2} and also stimulates osteoclast production (25).

Vascular calcification is a complex process that induces stiffening of the vessel wall and reduces vascular compliance (26). In animal models, it has been established that vitamin D plays an active role in arterial hardening and endothelial function. Vitamin D influence cardiovascular function through direct action via vitamin D receptors (VDRs) and indirect action on circulating hormones and calcium (27). The role of vitamin D as a protective factor against vascular calcification was shown by (28) who showed that vitamin D deficiency as a complication of chronic kidney disease (CKD) is associated with vascular calcification, while vitamin D supplements increase the survival in those patients.

The indirect protective role of vitamin D against vascular calcification could be mediated by its ability to effectively suppress secondary hyperparathyroidism (29). High parathyroid hormone (PTH) level may contribute to the development of the intimal calcification (atherosclerosis). In animal study showed elevated PTH induces endothelial to chondrogenic transition in aortic endothelial cells (30). Also PTH can promote Ca^{+2} deposition in the aortic wall (31). Active vitamin D improves insulin resistance and down regulates renin expression by suppressing renin gene transcription (32). Both the activation of renin angiotensin aldosterone system and insulin resistance induces cell endothelial dysfunction, proliferation of vascular smooth muscle and atherosclerosis (33).

The direct protective role of vitamin D against vascular calcification occurs through activation of VDRs. That demonstrated by reduction of serum cholesterol level and inhibition of foam cells and cholesterol efflux in

macrophages, through activation of cholesterol 7 α hydroxylase, decrease of oxidative LDL uptake by foamy cells and decrease of atherosclerotic plaque formation (34). Active vitamin D directly influences VSMC regeneration through VDRs (35). Research has shown that vitamin D protects vessel walls against damage caused by inflammation by increasing the expression of anti-inflammatory cytokines, such as IL-10 and by decreasing expression of proinflammatory molecules e.g., tumour necrosis factor α (TNF α) and IL-6 (36). Vitamin D is also involved in the down-regulation of plaque destabilizing enzymes like matrix metalloproteinase-9 (MMP-9) (37) as well as the C-reactive protein (38).

Our biochemical results were found to corroborate the bone histopathological changes. Both serum osteocalcin and alkaline phosphatase levels were significantly increased in the ovariectomized group as compared to the sham group and there levels were significantly decreased by vitamin D administration of OVX rats. Osteocalcin and alkaline phosphatase are considered markers of bone turnover. In general, their serum levels are elevated in diseases of high bone turnover rate as osteoporosis (39). Osteocalcin is synthesized by osteoblasts and is a major characterized non collagenous protein in mature human bone. Elevated level of osteocalcin may be associated with increased activity of osteoblast (40). Alkaline phosphatase is increased in postmenopausal osteoporosis as a secondary response to elevated bone resorption (41).

The decline in the serum estrogen in OVX rats is in agreements with Kim et al., 2012 (42) who discussed the main mechanism of the bone loss in OVX rats to be estrogen deficiency.

Estrogen deficiency accelerates turnover of bone metabolism accompanied with increasing bone formation and resorption. In conditions of estrogen deficiency, there is increased production of inflammatory cytokines, as interleukines: IL-1, IL-6, IL-11 and tumour necrosis factors (TNF), these factors stimulate osteoclasts formation. Estrogen has antiresorptive effect as it promotes bone formation by regulating osteoblast proliferation, differentiation and activity and it stimulates the production of antiosteoclastogenic factors including Interleukin-1 receptor antagonist (43). Also Estrogen deficiency increases the stromal production of receptors activator of NF κ B ligand (RANKL) and macrophage colony stimulating factor (M-CSF) (44). Receptors activator of NF κ B ligand (RANKL) promotes osteoclast formation and function, whereas M-CSF is one of the major regulators of osteoclast formation and function (45). Estrogen up-regulates osteoprotegin (OPG) mRNA levels. OPG suppresses bone resorption by sequestering RANKL (46).

In our work as observed histopathological findings of calcium deposits in the aortic wall in OVX rats. This could be attributed also to estrogen deficiency. The estrogen protective effect against vascular calcification could be mediated by upregulation of osteoprotegrin (OPG) mRNA levels which is able to sequester RANKL. RANKL is produced by many cells like vascular smooth muscle cells (VSMCs) might contribute to the atherosclerotic process through triggering endothelial cells (EC) proliferation and stimulating monocyte metalloproteinase 9 (MMP-9) activity. Thus promoting an osteogenic differentiation program in VSMCs that leads to the synthesis of bone proteins and matrix calcification within the

arterial vessels (47). However OPG, antagonizes RANKL actions in bone tissue, is constitutively produced by VSMCs and may be induced by inflammatory modulators or down regulated by anti-inflammatory stimuli in VSMCs and endothelial cells. Elevated OPG levels help protection against arterial damage and vascular calcification and/or possibly represent counter regulatory attempts to offset the effects of a RANKL increase (48).

In the present work, administration of vitamin D to ovariectomized rats produced significant increase in serum level of nitric oxide. Whereas in ovariectomized group there was no significant changes in serum NO level as compared to the sham group. So as a support of our results that, in conditions of estrogen deficiency, the cytokines produced as interleukin-1Beta, interleukin 6 and tumour necrosis factors alpha (IL-1B, IL-6 and TNF α) induce nitric oxide (NO) production in various cell types (49). However it has been suggested that estrogen increased endothelial nitric oxide synthase activity in osteoblast like cells and endothelial cells (50). Wimalawansa, 2000 (51) reported that nitric oxide donor alleviates ovariectomy induced bone loss. In postmenopausal women, estrogen replacement therapy caused an increase in NO levels; whereas quitting estrogen replacement therapy decreased NO levels significantly (52). So our findings could be explained as that in OVX group without vitamin D supplementation: the induced NO production by cytokines balance the decreased NO due to estrogen deficiency. This may not cause a change in total NO levels and/or in the state of estrogen insufficiency, inducible nitric oxide synthase stimulation by cytokines may be insufficient.

The increase in NO serum level by administration of vit D observed in our work agrees with Morris and Selvraj, 2014 (53) who reported that active vitamin D (1,25 dihydroxy vitamin D) regulates the production of NO and or expression of inducible NOS (iNO) in different cells including endothelial cells, osteoblasts, microglial cells and macrophages. Reduced NO level facilitates vascular inflammation which cause oxidation of lipoproteins and foam cells formation, the precursor of atherosclerotic plaque (54). The disturbance of its endothelial function may lead to hypercholesterolemia, atherosclerosis (55).

Malek and Shata, 2014 (56) reported that adding vitamin D to the diet of atherosclerotic rabbits, significant increase was noted in NO production, so that vitamin D has antiatherosclerotic effects and stimulate NO production which attenuates the inflammatory atherosclerotic process.

Endothelial dysfunction is caused by a reduction in nitric oxide bioavailability in VDR deficient mice (57) additionally Ding et al., 2015 (58) suggested that VDRs up regulates eNO synthase protein expression, an important enzyme that contributes to the pathogenic process of atherosclerosis. The molecular mechanism by which chronic calcitriol administration can restore vascular function by normalizing the endothelial expression of COX-2 and thromboxane-prostanoid receptors thereby preventing the reduction of NO generation that is induced by thromboxane prostanoid receptor activation (59). Finally, the attenuated NO production in aortic endothelial cells from ovariectomized rats can be restored following short term treatment with calcitriol.

Administration of vitamin D to ovariectomized rats caused significant increase in serum level of Ca^{+2} and phosphorus as compared to ovariectomized rats. The decreased calcium and phosphorus level in ovariectomized rats are in agreement with Hassan et al. 2013 (60). The impairment of intestinal Ca^{+2} absorption by estrogen deficiency has been attributed to either a decrease in serum 1,25 dihydroxy vitamin D3 levels or direct effect of estrogen on intestinal Ca^{+2} transport (61). Studies of the mechanism of action of vitamin D on intestinal transport of Ca^{+2} have suggested that vitamin D affects energy independent step of Ca^{+2} transport possibly by increasing the permeability of the mucosal cell to Ca^{+2} (62).

Serum level of parathyroid hormone (PTH) was increased significantly in ovariectomized rats while vitamin D administration caused a significant decrease in its level. The increased PTH level in ovariectomized rats is in agreement with Elkomy and Elsaied, 2015 (63). Evidence of osteoporosis resulting from ovariectomy was indicated by the present elevation of PTH level. The elevated level of parathormone causes additional loss of bone mass in estrogen deficient animals beyond the rapid loss associated with ovariectomy. Decreased estrogen level in females increases the sensitivity of bones to the action of PTH leading to bone resorption with lowering bone mass (64). In addition hypovitaminosis D brings about an increment in PTH secretion which may contribute to vascular calcification, resulting in endothelial and vascular growth dysfunction (65). The suppressed level of PTH by administration of vitamin D observed in

our work is in agreement with Mizobuchi et al., 2007 (66).

In our present work the administration of vitamin D improved the lipid profile in ovariectomized rats in which there were significant decrease in total cholesterol, LDL, HDL, and triglycerides. These findings suggest that vitamin D insufficiency is associated with dyslipidemia. The estrogen lowering effect of cholesterol was demonstrated by Washburn et al., 1993 (67), also pharmacological doses of estrogen up regulated LDL receptors in rat livers. However LDL binding in human liver homogenates is correlated with serum estrogen concentrations, also the regulation of the LDL receptors has been shown to involve both transcriptional and post transcriptional (68) mechanisms. Also by Black et al, 1994 (69), the antiestrogens tamoxifen and reloxifene act as estrogen agonists in the liver, causing a decreasing in total cholesterol in rats and LDL in humans. The improvement of HDL and triglycerides level after administration of vitamin D agrees with Wehr et al., 2011 (70). This might be explained by the suppressive effect of vitamin D on serum PTH concentration. Because elevated PTH concentrations are accompanied by a decrease in plasma post heparin lipolytic activity (71). The reduction in serum PTH may have decreased serum triglycerides via increased peripheral removal (70).

Although the lowering effect of vitamin D on HDL could be considered an adverse effect yet we must note that in contrast to humans the rat HDL is the predominant form of cholesterol in plasma, comprising about 60-70% of the total cholesterol level (72). Surprisingly it has been demonstrated by Mayret-Mesquiti et al., 2007 (73)

that NO synthesis was significantly reduced with increased levels of triglycerides and cholesterol. So giving the significant improvement of serum NO level with vitamin D administration in our study this may highlights a mechanism of the lowering effect of vitamin D on cholesterol level to be through elevating NO serum level. Another mechanism may involve activation of VDRs by active vitamin D. Because VDRs suppress the activation of cholesterol 7 α hydroxylase which is the rate limiting enzyme in bile and which reduces the serum cholesterol concentration (74).

In conclusion: Estrogen deficiency state induced by ovariectomy in rats associated with bone loss and aortic wall calcification. That could be explained by associated dyslipidemia and the lowered vitamin D and NO levels whereas the elevated PTH level that disturb the calcium and phosphorus homeostasis. The administration of vitamin D has a beneficial effect on the bone quality and also a delaying effect on the onset of aortic vascular calcification in ovariectomized rats, with suggestion of possible improvement of serum nitric oxide levels that ameliorate endothelial dysfunction and prevent atherosclerosis with intimal calcification.

References:

1. **Kim DG, Navalgund AR, Tee BC, Noble GJ, Hart RT, Lee HR.** Increased variability of bone tissue mineral density resulting from estrogen deficiency influences creep behavior in a rat vertebral body. *Bone*; 51(5): 868-75. 2012.
2. **Bikle DD, Stesin A, Halloran B, Steinbach L, Recker R.** Alcohol-induced bone disease: relationship to age and parathyroid hormone levels. *Alcohol Clin. Exp. Res.* 17: 690 – 695. 1993.
3. **Omura Y, Nishio Y, Kashiwagi A.** Osteoporosis and atherosclerosis. *Clin Calcium*; 17(3): 346–53. 2007.
4. **Somjen D, Weisman Y, Kohen F, et al.** 25-hydroxyvitamin D3-1 α -hydroxylase is expressed in human vascular smooth muscle cells and is upregulated by parathyroid hormone and estrogenic compounds. *Circulation*, 111: 1666–1671. 2005.
5. **Rebsamen MC, Sun J, Norman AW, et al.** 1 α , 25-dihydroxyvitamin D3 induces vascular smooth muscle cell migration via activation of phosphatidylinositol 3-kinase. *Circ Res.*; 91: 17–24. 2002.
6. **Dusso AS, Brown AJ, Slatopolsky E.** Vitamin D. *Am J Physiol Renal Physiol*; 289: F8–28. 2005.
7. **Sowah D, Fan X, Dennett L, Hagtvedt R, and Straube S.** Vitamin D levels and deficiency with different occupations: A systematic review. *BMC Public Health*, 17(1): articleno.h14. 2017.
8. **Holick MF.** Vitamin D deficiency. *The New England Journal of Medicine*, 7 (1): 266–281. 2007.
9. **Brune B, Dimmeler S, Vedia LMY and Lapetina EG.** Nitric Oxide: A signal for ADP-Ribosylation of proteins. *Life sciences*, 54(2): 61-76. 1994.
10. **Liu XB, Hill P, and Haile DJ.** Role of the ferroportin iron responsive element in iron and nitric oxide dependent gene regulation.

- Blood Cells, Molecules & Diseases, 24(2): f1h-f26, 2002.
11. **Cannon RO 3rd**. Role of nitric oxide in cardiovascular disease: focus on the endothelium. *Clinical Chemistry*, 55(8) part2:1809-1819. 1998.
 12. **Dawson TM and Snyder SH**. Gases as biological messengers: Nitric oxide and carbon monoxide in the brain. *The Journal of Neuroscience*, 14(9): 5147-5159. 1994.
 13. **Willems HME, Van Den Heuvel EGHM, Carmeliet G, Schaafsma A, Klein-Nulend J, and Bakker AD**. VDR dependent and independent effects of 1, 25-dihydroxyvitamin D on nitric oxide production by osteoblasts. *Steroids*, 77(1-2): 126-131. 2012.
 14. **Molinari C, Uberti F, Grossini et al E**. 1,25-dihydroxycholecalciferol induces nitric oxide production in cultured endothelial cells. *Cellular Physiology and Biochemistry*, 27(6): 661-668. 2011.
 15. **Van Der Meijden K, Bakker AD, Van Essen HW et al**. Mechanical loading and the synthesis of 1,25(OH)2D in primary human osteoblasts. *The Journal of Steroid Biochemistry and Molecular Biology*, 1h6: f2-f4. 2016.
 16. **Mizobuchi M, Finch JL, Martin DR, Slatopolsky E**. Differential effects of vitamin D receptor activators on vascular calcification in uremic rats. *Kidney Int.*, 72(6): 709-15. 2007.
 17. **Rosenguist C, Qvist P, Bjarnason N, Christiansen C**. Measurement a more stable region of osteocalcin in serum by ELISA with two monoclonal antibodies. *Clin Chem*; 41: 1439-45. 1995.
 18. **Lopez MF, rezai T, Sarracino DA, Prakash A, Krastins B, et al**. Selected reaction monitoring-mass spectrometric immunoassay responsive to parathyroid hormone and related variants. *Clin Chem* 56: 281-290. 2010.
 19. **Comelekoglu U, Bagis S, Yalin S, et al**. Biomechanical evaluation in steoporosis: ovariectomized rat model. *Clin Rheumatol*; 26: 380-4. 2007.
 20. **Ionovici N, Mogoanta L, Grecu D, Bold A, Tarnia DN, Enache SD**. Histological study of the femoral head and neck microscopic architecture in persons with senile osteoporosis. *Rom J Morphol Embryol*; 45: 127-32. 2004.
 21. **Kiel D, Kauppila L, Cupples L, Hannan M, O'Donnell C, Wilson P**. Bone loss and the progression of abdominal aortic calcification over a 25 year period: the Framingham Heart Study. *Calcif Tiss Int.*; 68: 271-276. 2001.
 22. **Simsek, G., Hzun, H, Aydin, S, karter, Y. et al**. The role of nitric oxide on bone metabolism in ovariectomized rats following chronic ethanol intake. *Life sciences* 76: 1965-1974. 2005.
 23. **Block GA, Klassen PS, Lazarus JM et al**. Mineral metabolism, mortality, and morbidity in maintenance hemodialysis. *J Am Soc Nephrol*; 15: 2208-2218. 2004.
 24. **Inoue T, Kawashima H**. 1, 25-Dihydroxyvitamin D3 stimulates 45 Ca²⁺-uptake by cultured vascular smooth muscle cells derived from rat aorta. *Biochem Biophys Res Commun*; 152: 1388-1394. 1988.

25. **Holick MF.** Vitamin D: important for prevention of osteoporosis, cardiovascular heart disease, type 1 diabetes, autoimmune diseases, and some cancers. *South Med J.*; 98: 1024–7. 2005.
26. **Lanske B and Razzaque MS.** Vitamin D and aging: old concepts and new insights. *J Nutr Biochem*; 18: 771–777. 2007.
27. **Raymond MA, Desormeaux A, Labelle A, et al.** Endothelial stress induces the release of vitamin D-binding protein, a novel growth factor. *Biochem Biophys Res Commun*; 338: 1374-1382. 2005.
28. **Davies MR and Hruska KA.** Pathophysiological mechanisms of vascular calcification in end-stage renal disease. *Kidney Int*; 60: 472– 479. 2001.
29. **Bas A, Lopez I, Perez J et al.** Reversibility of calcitriol-induced medial artery calcification in rats with intact renal function. *J Bone Miner Res*; 21: 484–490. 2006.
30. **Brown AJ, Dusso AS, Slatopolsky E.** Vitamin D analogues for secondary hyperparathyroidism. *Nephrol Dial Transplant*; 17(Suppl 10): 10–19. 2002.
31. **Tentori F, Hunt WC, Stidley CA et al.** Mortality risk among hemodialysis patients receiving different vitamin D analogs. *Kidney Int*; 70: 1858–1865. 2006.
32. **Tiryaki O, Usalan C, and Sayiner ZA.** Vitamin D receptor activation with calcitriol for reducing urinary angiotensinogen in patients with type 2 diabetic chronic kidney disease. *Renal Failure*, 38 (2): 222–227. 2016.
33. **Kjekshus J, Apetrei E, Barrios V et al.** Rosuvastatin in older patients with systolic heart failure. *New England Journal of Medicine*, 357 (22): 2248–2261. 2007.
34. **Oh J, Weng S, Felton SK et al.** 1, 25(OH)₂ vitamin D inhibits foam cell formation and suppresses macrophage cholesterol uptake in patients with type 2 diabetes mellitus. *Circulation*, 120 (8): 687–698. 2009.
35. **Wong MSK, Leisegang MS, Kruse et al. C.** Vitamin D promotes vascular regeneration. *Circulation*, 130 (12): 976–986. 2014.
36. **Zittermann A, Schleithoff SS, Koerfer R.** Putting cardiovascular disease and vitamin D insufficiency into perspective. *Br J Nutr.*; 94: 483–492. 2005.
37. **Khalili H, Talasaz AH, Salarifar M.** Serum vitamin D concentration status and its correlation with early biomarkers of remodeling following acute myocardial infarction. *Clin Res Cardiol.*; 101: 321–327. 2012.
38. **Carlson N, Mah R, Aburto M, Peters MJ, Dupper MV, Chen LH.** Hypovitaminosis D correction and high sensitivity C-reactive protein levels in hypertensive adults. *Perm J*; 17: 19-21. 2013.
39. **Indumati V and Patil V.** Biochemical markers of bone remodeling in osteoporosis-current concepts. *J Clinical Diag Res*; 4: 2089-97. 2010.
40. **Jagtap VR, Ganu JV, Nagane NS.** BMD and serum intact osteocalcin in postmenopausal osteoporosis women. *Indian J Clin Biochem*; 26(1): 70-3. 2011.
41. **Nawawi HM, Yazid TN, Ismail NMN, Mohamad AR, Nirwana S, Khalid BAK.** Serum bone specific alkaline phosphatase and urinary deoxypyridinoline in postmenopausal

- osteoporosis. *Malaysian J Pathol*; 23(2): 79 - 88. 2001.
42. **Kim DG, Navalgund AR, Tee BC, Noble GJ, Hart RT, Lee HR.** Increased variability of bone tissue mineral density resulting from estrogen deficiency influences creep behavior in a rat vertebral body. *Bone*; 51(5): 868-75. 2012.
43. **Lindsay R and Cosman F.** Estrogens and osteoporosis in osteoporosis (2nd edition) by Marcus et al., published by Academic press San Diego pp: 577-595. 2001.
44. **Mundy GR, Boyce BE, Yoneda T, Bonewald LE and Roodman GD.** Cytokines and bone remodeling. In osteoporosis ed. R. Marcus D, Feldman and J Kelsey, pp: 301-13 Sand Diego, CA: Academic Press Inc. 2001.
45. **Martin TJ, and Rodan GA.** Coupling of bone resorption and formation during bone remodeling. In osteoporosis (2nd edition) by Marcus et al., published by Academic press, San Diego pp: 405-422. 2001.
46. **Hofbauer LC and Schoppet M.** Clinical implications of the osteoprotegerin/ RANKL/ RANK system for bone and vascular diseases. *JAMA*, 292 (4): 490-5. 2004.
47. **Horowitz M and Jika RL.** Colony stimulating factors in bone remodeling. In cytokines and bone metabolism. (M.Gowen, d.), (RC Press, Boca Roton, FL, pp: 185-227. 1992.
48. **Malyankar U, Scatena M, Suchland K, Yun T, Clark E, Giachelli C.** Osteoprotegerin is an avb3-induced, NF-kB-dependent survival factor for endothelial cells. *J Biol Chem.*; 275: 20959–20962. 2000.
49. **Damoulis PD and Hauschka PV.** Nitric oxide acts in conjunction with proinflammatory cytokines to promote cell death in osteoblasts. *J. Bone Miner. Res.* 12: 412 – 422. 1997.
50. **Hishikawa K, Nakaki T, Marumo T, Suzuki H, Kato R, Saruta T.** Up-regulation of nitric oxide synthase by estradiol in human aortic endothelial cells. *FEBS Lett.*, 360: 291 – 293. 1995.
51. **Wimalawansa SJ.** Nitroglycerin therapy is as efficacious as standard estrogen replacement therapy (Premarin) in prevention of oophorectomy-induced bone loss: a human pilot clinical study. *J. Bone Miner. Res.*, 15: 2240 – 2244. 2000.
52. **Cicinelli E, Ignorro LJ, Matteo GM.** Effects of estrogen replacement therapy on plasma levels of nitric oxide in postmenopausal women. *Am. J. Obstet. Gynecol.*, 180: 334 – 339. 1999.
53. **Morris A and Selvaraj RK.** In vitro 2h-hydroxycholecalciferol treatment of lipopolysaccharide-stimulated chicken macrophages increases nitric oxide production and mRNA of interleukin1beta and 10. *Veterinary Immunology and Immunopathology*, 161(3-4): 265–270. 2014.
54. **Mayret-Mesquiti M, P´erez-M´endez O, Rodr´iguez ME et al.** Hypertriglyceridemia is linked to reduced nitric oxide synthesis in women with hypertensive disorders of pregnancy. *Hypertension in Pregnancy*, 26(4): 423-431. 2007.
55. **Dawson TM and Snyder SH.** Gases as biological messengers: Nitric oxide and

- carbon monoxide in the brain. *The Journal of Neuroscience*, 14(9): 5147–5159. 1994.
56. **Malek HA and Shata A.** Elect of a high dose of vitamin D on a rabbit model of atherosclerosis. *International Journal of Immunopathology and Pharmacology*, 27(2): 196 – 201. 2015.
57. **Andrukhova O, Slavic S, Zeitz U, et al.** Vitamin D is a regulator of endothelial nitric oxide synthase and arterial stiffness in mice. *Mol Endocrinol*; 28: 53-64. 2014.
58. **Ding Y, Liao W, Yi Z, Xiang W, He X.** Cardioprotective role of vitamin D receptor in circulating endothelial cells of ApoE-deficient mice. *Int J Clin Exp Med*; 8: 5065-5074. 2015.
59. **Yu L, Tomlinson JE, Alexander ST, Hensley K, Han CY, et al.** Etelcalcetide, A Novel Calcimimetic, Prevents Vascular Calcification in A Rat Model of Renal Insufficiency with Secondary Hyperparathyroidism. *Calcif Tissue Int*, 101(6):641-653. 2017.
60. **Hassan HA, El Wakf AM, El Gharib NE.** Role of phytoestrogenic oils in alleviating osteoporosis associated with ovariectomy in rats. *Cytotechnology*. <http://dx.doi.org/10.1007/s10616-012-9514-6>. 2013.
61. **Kalu DN and Orhii PB.** Calcium absorption and bone loss in ovariectomized rats fed varying levels of dietary calcium. *Calcif Tissue Int*, 65: 73–77. 1999.
62. **Bolscher MT, Netelenbos JC, Barto R, Van Burren LM, Van der Vijgh WJF.** Estrogen regulation of intestinal calcium absorption in the intact and ovariectomized adult rat. *J Bone Miner Res*, 14: 1197–1202. 1999.
63. **ELkomy MM and Elsaid FG.** Anti-osteoporotic effect of medial herbs and calcium supplementation on ovariectomized rats. , 72: 81-88. 2015.
64. **Krivosi'kov Z, Krajcovicova-Kudla'ckova' M, Spustova' V, Stefi'kova' K, Valachovicova' M, Blazi'cek P, Nmcova' T.** The association between high plasma homocysteine levels and lower bone mineral density in Slovak women: the impact of vegetarian diet. *J. Eur. Nutr.*, 49: 147–153. 2010.
65. **Rostand SG.** Vitamin D, blood pressure, and African Americans: toward a unifying hypothesis. *Clin J Am Soc Nephrol*; 5: 1697–1703. 2010.
66. **Mizobuchi M, Fich JL, Martin DR and Slatopolsky E.** Differential effects of vitamin D receptor activators on vascular calcification in uremic rats. , 72: 709-715. 2007.
67. **Washburn SA, Adams MR, Clarkson TB, Adelman SJ.** A conjugated equine estrogen with differential effects on uterine weight and plasma cholesterol in the rat. *Am J Obstet Gynecol*, 169: 251–256. 1993.
68. **Gold E, Stapley S, Goulding A.** Tamoxifen and norethisterone: effects on plasma cholesterol and total body calcium content in the estrogen-deficient rat. *Horm Metab Res*, 26: 100–103. 1994.
69. **Black LJ, Sato M, Rowley ER, Magee DE, Bekele A, Williams DC, Cullinan GJ, Bendele R, Kauffman RF, Bensch WR, Frolik CA, Termine JD, Bryant HU.** Raloxifene (LY139481 HCl) prevents bone

- loss and reduced serum cholesterol without causing uterine hypertrophy. *J Clin Invest*, 93: 63–69. 1994.
70. **Wehr E, Pieber TR and Obermayer-Pietsch B.** Effect of vitamin D3 treatment on glucose metabolism and menstrual frequency in polycystic ovary syndrome women: a pilot study. *J endocrinol Invest*, 34: 757-763. 2011.
71. **Mahmoudi T, Gourabi H, Ashrafi M, Yazdi RS, Ezabadi Z.** Calciotropic hormones, insulin resistance, and the polycystic ovary syndrome. *Fertil Steril*, (in press) 2009.
72. **Lundeen SG, Carver JM, Mckean ML, Winnerker RC.** Characterization of the Ovariectomized Rat Model for the Evaluation of Estrogen Effects on Plasma Cholesterol Levels. *Endocrinology society*, 138: 1552-1558. 1997.
73. **Mayret-Mesquiti M, P´erez-M´endez O, Rodr´ıguez ME et al.** Hypertriglyceridemia is linked to reduced nitric oxide synthesis in women with hypertensive disorders of pregnancy. *Hypertension in Pregnancy*, 26(5): 52f–5f1. 2007.
74. **Chiang JYL.** Bile acids: regulation of synthesis. *Journal of Lipid Research*, 50(10): 1955–1966. 2009.