



Journal homepage:

<http://www.bsuef.edu.eg/bsujournals/JVMR.aspx>

Online ISSN: 2357-0520

Print ISSN: 2357-0512



Original Research Article

***Taraxacum Officinale* (Dandelion) Roots Extract Mitigates Doxorubicin-Induced Hemato-Cardiotoxicity in Male Albino Rats**

Dina R. S. Gad El-Karim*

* Department of Pathology and Clinical Pathology, Faculty of Veterinary Medicine, Alexandria University, Egypt.

ABSTRACT

The present study was designed to evaluate the probable ameliorative effect of dandelion extract against doxorubicin hemato-cardiotoxicity. To accomplish this study, four groups of male albino rats (n=7) were used as follow, Group I: served as a control group, Group II: received dandelion extract (200 mg/ kg), Group III: received doxorubicin (2.5 mg/kg) and Group IV: received dandelion extract and doxorubicin identically to groups II and III. Doxorubicin was administrated 3times/week for two consecutive weeks, while dandelion extract was administrated daily for two consecutive weeks before doxorubicin administration and continued during doxorubicin treatment. The results illuminated that, administration of doxorubicin has a deleterious effect on both of blood cellular components and cardiac tissues, which was indicated by significant pancytopenia (decrease in all blood cell types), elevated serum cardiac enzymes activity (CK-MB and LDH), increased serum level of cardiac-related proteins (troponin I, atrial natriuretic peptide (ANP) and B-type natriuretic peptide (BNP) with a depletion of cardiac tissues antioxidant (GSH, and SOD enzyme) and elevated lipid peroxide (MDA) level in this tissues. Co-administration of dandelion extract with doxorubicin significantly alleviated its hemato-cardiotoxic effect which was reflected positively on hemato-biochemical changes and cardiac histopathological alterations.

ARTICLE INFO

Article history:

Received 24/7/2019

Accepted 29/10/2019

Online 2/11/2019

Keywords:

ANP, BNP,

Dandelion,

Doxorubicin,

Hemato-cardiotoxicity,

Rats.

Corresponding author: Dina R. S. Gad El-Karim, Department of Pathology and Clinical Pathology, Faculty of Veterinary Medicine, Alexandria University, Egypt.

Email: gaddidi@yahoo.com.

Tel: +201117476977.

1. Introduction

Doxorubicin (DXR) is a quinone-containing antineoplastic antibiotic that is used for treatment of several types of cancer as leukaemias, Hodgkin's and non-Hodgkins lymphomas, bladder, lung, ovarian and breast cancers, but, its clinical usage has been restricted due to cardiomyopathy and heart failure associated with its administration (Booser and Hortobagyi, 1994; Jansen et al., 2002; Wattanapitayakul et al., 2005). Generally, the target of DXR is the DNA of the actively dividing cells; DXR intercalates within DNA base pair and arresting cell replication in the G2 phase (Vendramini et al., 2010; Tacar et al., 2012), also, it inhibits the activity of some nuclear enzymes, such as DNA and RNA-polymerase plus DNA-topoisomerase II which are collectively implicated in DNA replication and transcription (Gonzalez et al., 2005; Hynek et al., 2012). Doxorubicin cardiotoxicity has been suggested to occur due to the generation of superoxide free-radical (Wang et al., 1980; Nagi and Mansour, 2000) and through reduction of oxygen by NADPH, superoxide radicals are then converted to hydrogen peroxide (H₂O₂) by super oxide dismutase enzyme (antioxidant enzyme), later, the former is further reduced to extremely reactive hydroxyl radical (OH), which rapidly react with cellular polyunsaturated fatty acids yielding lipid hydroperoxide and the net results is cell membrane oxidative damage (Mimnaugh et al., 1985). Heart is more sensitive to doxorubicin oxidative damage due to the high affinity of doxorubicin for phospholipid cardiolipin of the inner mitochondrial membrane of cardiomyocytes besides its low capacity of peroxide detoxification (Doroshov et al., 1980). Doxorubicin cardiotoxicity can be reflected on myocyte structure in form of damaged microtubules, dilatation of the sarcoplasmic reticulum, sarcoplasmic vacuolization, sarcomere disruption, loss of myofibrils and mitochondrial injury (Cassidy et al., 1998; Saeki et al., 1998). As the oxidative damage has been implicated in progression of doxorubicin cardiotoxicity, several types of free

oxygen radicals scavengers (especially medicinal plants extracts) have been evaluated to elucidate their role in attenuation of such effect (Wattanapitayakul et al., 2005). Nowadays, medicinal plants and their extracts are considered as alternatives to traditional therapies (antibiotics, chemotherapies and even vaccines) (Harikrishnan et al., 2011). Dandelion (*Taraxacum officinale*) as a medicinal plant was native to European area but now it is widely distributed throughout the northern temperate zones of the world and it is considered as a rich source of minerals and vitamins especially iron, calcium, vitamins A and C (Ali., 1989). Several active ingredients have been isolated from dandelion different parts including quercetin, taraxacoside, phytosterol, caffeic acid, chlorogenic acid, luteolin, and luteolin 7-glucosides (Rauwald and Huang 1985; William et al., 1996; Hu and kits, 2005). Besides its powerful antioxidant effect (especially hydroxyl radicals scavenging ability) and hypolipidemic effect (Kang et al., 2002; Kim et al., 2008; Choi et al., 2010), dandelion has been used for treatment of several affections in folk medicine including inflammation, hepatic disorders, several diseases of women such as breast and uterine cancers (Williams et al., 1996). Relatively, less has been studied the effect of dandelion on attenuation of cardiomyocytes oxidative damage, so this work aimed to evaluate the potential cardioprotective effect of dandelion against doxorubicin-induced cardiotoxicity.

2. Material and Methods

2.1. Preparation of plant extract

Taraxacum officinale roots (FRONTIERS, Natural Products Co., USA) was sent to Herbarium of the department of Biology, Faculty of Sciences, Alexandria University for processing, 100 g of the roots were powdered ground and extracted with 80% ethanol using an ultrasonic homogenizer (Biologics, Inc, USA) at low temperature (below 25°C), the extract was evaporated and lyophilized under reduced pressure to give about 13g of light brown semi-solid residues which kept at 4° C till its usage.

2.2. Experimental animals and treatment protocol

Twenty eight male Wistar albino rats, about 180-200g body weight and 7-8 weeks old were obtained from the closed bred colony of Medical Research Institute, Alexandria University, Egypt were used to complete this experiment. They were housed into four separate metal cages under controlled environmental conditions (55-60% RH and 24-27 °C temperature) with 12 h light/ dark cycle. Standard laboratory diet and water *ad-libitum* were provided. They were kept without any treatment for two weeks as an acclimatization period and observed carefully during this period to make sure of their freedom from any apparent health problem. After this period, the animals were randomly divided into 4 groups (7/each) and treated as follow: Group I (control) injected with 1 ml of physiological saline by intraperitoneal (I/P) route. Group II (dandelion) received dandelion roots extract orally by gastric intubation at dose level of 200 mg/kg B. Wt. (Modaresi and Resalatpour, 2012) daily for 4 consecutive weeks. Group III (DXR) injected with 2.5 mg/ kg B. Wt. of doxycyclin (I/P) (BMC Pharmaceuticals Co., Cairo, Egypt) 3 times/weekly for 2 consecutive weeks to ensure a cumulative dose of 15mg/kg B.Wt. (Arafa *et al*, 2014). Group IV (DXR+dandelion) was administrated with dandelion extract (200 mg/kg) daily for two consecutive weeks before DXR injection (2.5 mg/kg) and continued daily for other two consecutive weeks in a combination with DXR. Twenty four hours after the last doses administration, blood samples were collected from retro-orbital plexus using capillary tubes and under light ether anesthesia, then all the animals were euthanized by cervical dislocation, heart was collected from each animal after necropsy.

2.3. Hematological studies

EDTA anti-coagulated blood samples were collected for determination of RBCs count, total leukocytic count (TLC), differential leukocytic count (granulocytes, monocytes and lymphocytes count) and platelets count using

special automated blood cells counter for animals samples (Exigo®, Sweden).

2.4. Serum biochemical analysis

Coagulated blood samples were centrifuged at 1000×g for 10 min. to separate serum aliquots which were kept frozen at -4 °C for later analysis of activity of CK-MB and LDH enzymes using commercially available kits (Biomed Diagnostic, Egypt), in addition to serum concentration of troponin I, atrial natriuretic peptide (ANP) and B-type natriuretic peptide (BNP) using specific highly reactive ELISA kits (Spectrum Diagnostics, Egypt; NOVUS, Canada).

2.5. Oxidant-Antioxidant studies

About 1 gm of cardiac tissues was dissected, washed with deionized water and perfused with phosphate buffer saline (PBS) and then homogenized by addition of PBS (9:1) by the aid of tissue homogenizer (Glas-Col®, China), homogenates were centrifuged for 30 min. at 10,000 × g using cooling centrifuge, supernatant fluid was separated, filtered and kept at -80°C for subsequent detection of tissues content of malondialdehyde (MDA) (Aebi, 1984), reduced glutathione (GSH) (Beutler *et al.*, 1963), in addition to tissues activity of superoxide dismutase enzyme (SOD) (Ukeda *et al.*, 1997) using commercially available kits (Biodiagnostic, Egypt and abnova, Taiwan). Protein content of cardiac tissues was detected using Bradford's reagent (Sigma-Aldrich, USA).

2.6. Histopathological evaluation

After collection, cardiac tissues were fixed in 10% formalin solution and histopathological sections were prepared with a thickness of 5 µm using paraffin embedding technique (Bancroft and Stevens, 1996), examined and imaged under light microscope.

2.7. Semiquantitative simple grading system for cardiac histopathological changes

In brief, five random fields from each animal cardiac tissues histopathological section were examined (×100), the grade of the recorded lesions severity was determined depending on the percentage of the affected area to the entire section and recorded as follow: (-): absence of

lesion, (+): for mild degree of the detected lesions (5–25%), (++): for moderate lesions degree (26–50%) and (+++): for severe degree of the lesions ($\geq 50\%$).

2.8. Statistical analysis

Statistical analysis was performed using One-way analysis of variance (ANOVA) to detect the effect of different treatment on the different assessed parameters using SPSS[®] system software.

3. Results

3.1. Hematological changes

As shown in Table 1, DXR-treated animals group recorded a significant decrement ($p < 0.05$) in RBCs count, TLC, differential leukocytic count and platelets count when compared to control group. But, administration of dandelion extract with DXR efficiently alleviated this decrease in the previously listed hematological parameters except for platelets count. Administration of dandelion alone to the rats revealed a significant increase in TLC, granulocytes and monocytes counts as compared to control group.

Table 1. The effect of different treatments on some hematological parameters

	Groups			
	Control	Dandelion	DXR	DXR+dandelion
RBCs ($\times 10^6/\mu\text{L}$)	7.70 \pm 0.22 ^a	7.85 \pm 0.30 ^a	5.19 \pm 0.15 ^c	6.93 \pm 0.11 ^b
TLC ($\times 10^3/\mu\text{L}$)	8.53 \pm 0.31 ^b	8.87 \pm 0.25 ^a	5.05 \pm 0.24 ^d	6.68 \pm 0.19 ^c
GRA ($\times 10^3/\mu\text{L}$)	2.04 \pm 0.10 ^b	2.24 \pm 0.14 ^a	1.18 \pm 0.09 ^d	1.55 \pm 0.07 ^c
Monocytes ($\times 10^3/\mu\text{L}$)	1.23 \pm 0.13 ^b	1.54 \pm 0.09 ^a	0.77 \pm 0.05 ^d	1.02 \pm 0.09 ^c
Lymphocytes ($\times 10^3/\mu\text{L}$)	5.12 \pm 0.20 ^a	5.11 \pm 0.15 ^a	2.97 \pm 0.19 ^c	4.00 \pm 0.15 ^b
Platelets ($\times 10^3/\mu\text{L}$)	603.20 \pm 21.50 ^a	608.40 \pm 23.84 ^a	457.60 \pm 16.76 ^b	459.40 \pm 21.53 ^b

-All the values are expressed as mean \pm SD

-Means within the same raw of different litters are significantly different at ($P < 0.05$).

-Dandelion: dandelion-treated group; DXR: doxorubicin-treated group; DXR+dandelion: doxorubicin and dandelion-treated group.

3.2. Serum biochemical changes

In comparison with control group, serum activity of LDH and CK-MB enzymes showed a significant increase ($p < 0.05$) in DXR-treated animals, which was accompanied by significant elevation in serum level of troponin-I, ANP and BNP in the same animals group. Fortunately, combination between dandelion extract and DXR significantly ameliorated these serum biochemical changes related to administration of DXR.

Compared to control group, administration of dandelion extract as a sole treatment to the animals significantly decreased serum activity of the evaluated cardiac enzyme (LDH, CK-MB) and serum level of ANP and BNP (Table 2).

3.3. Cardiac oxidant-antioxidant changes

As illustrated in Table 2, cardiac level of MDA was significantly elevated ($p < 0.05$) in DXR-treated rats group which was associated with a

significant depletion of GSH content and inhibition of SOD enzyme activity when compared to control animals group. Co-administration of dandelion extract with DXR showed an excellent antioxidant effect and significantly mitigated the altered

oxidant-antioxidant changes. Also, administration of dandelion alone significantly boosted cardiac antioxidant state and decreased cardiac MDA in comparison with control group.

Table 2. The effect of different treatments on serum cardiac biomarkers enzymes and some cardiac oxidative parameters

	Groups			
	Control	Dandelion	DXR	DXR+dandelion
CK-MB (U/L)	175.90±5.85 ^c	172.80±6.16 ^d	543.60±5.94 ^a	333.80±5.90 ^b
LDH (U/L)	584.60±4.77 ^c	575.40±4.34 ^d	1648.20±16.86 ^a	1249.40±18.78 ^b
Troponin (U/L)	10.50±0.78 ^c	9.94±0.80 ^c	21.36±1.20 ^a	15.38±0.78 ^b
ANP (pg/ml)	177.70±8.71 ^c	172.80±7.26 ^d	255.60±9.90 ^a	203.40±4.98 ^b
BNP (pg/ml)	65.40±3.80 ^c	61.60±3.72 ^d	94.20±2.91 ^a	75.60±4.95 ^b
MDA (µmol/g protein)	34.90±1.89 ^c	30.40±1.60 ^d	84.70±2.26 ^a	54.10±2.89 ^b
GSH (nmol/g protein)	16.06±1.25 ^b	18.42±1.11 ^a	6.64±0.58 ^d	10.72±0.55 ^c
SOD (U/mg protein)	35.16±2.74 ^b	41.76±2.05 ^a	19.52±1.89 ^d	25.56±1.12 ^c

-All the values are expressed as mean ±SD

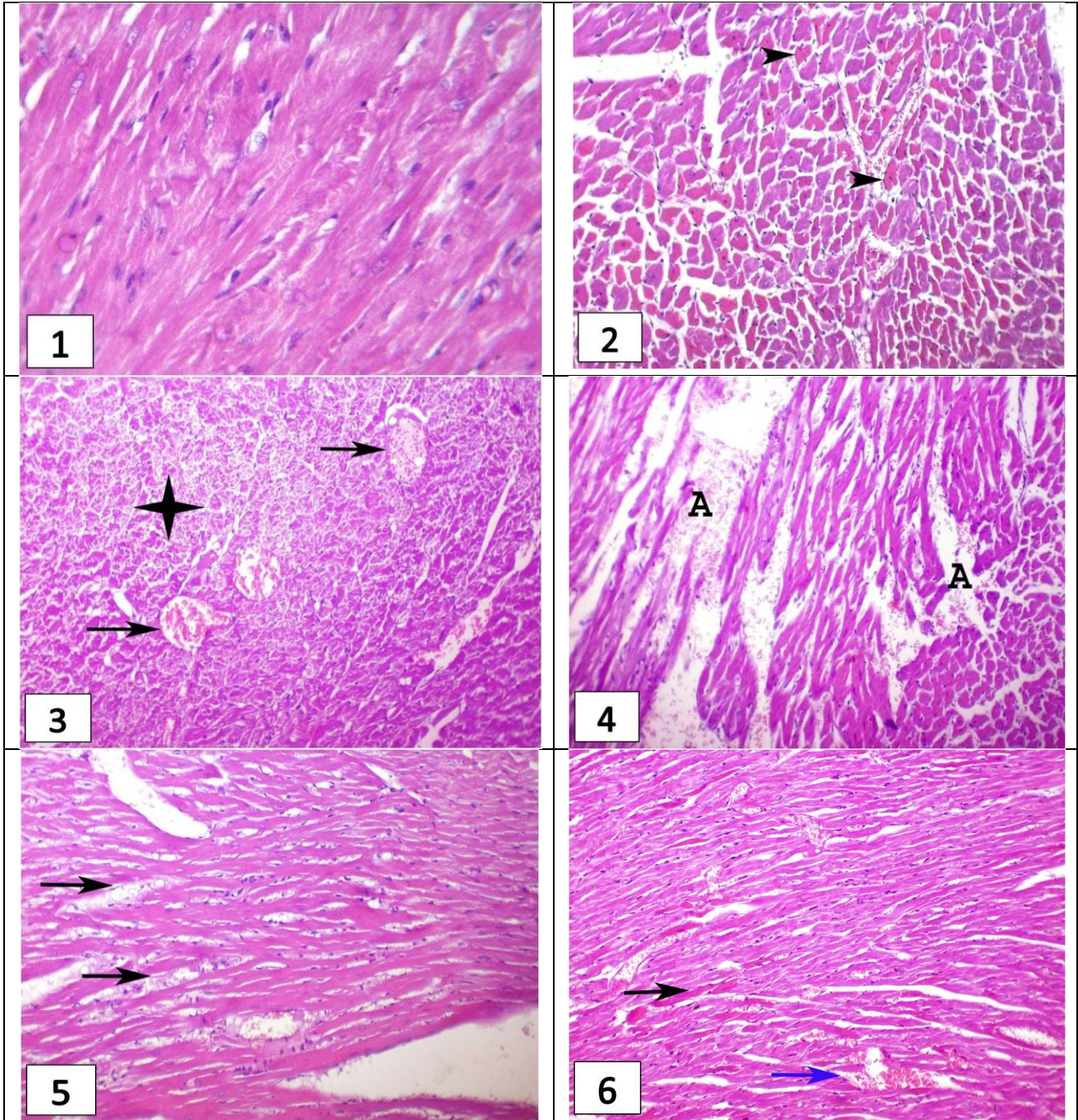
-Means within the same raw of different litters are significantly different at (P < 0.05).

-Dandelion: dandelion-treated group; DXR: doxorubicin-treated group; DXR+dandelion: doxorubicin and dandelion-treated group.

3.4. Histopathological alterations

Examination of representative heart sections of differently-treated animals groups by light microscope revealed normal histological architectures and details of cardiomyocytes in both of control and dandelion extract-treated groups (Fig. 1), while DXR-treated group showed and intensively eosinophilic cardiomyocytes (Fig. 2), widely distributed sarcoplasmolysis and hemorrhage (Fig. 3). On the other hand, DXR+dandelion-treated group exhibited vacuolation of some cardiomyocytes which were

infiltrated with inflammatory cells (Fig. 5) in addition to congestion of cardiac blood vessels with presence of minimal hyalinized cardiomyocytes (Fig. 6). Table 3 illustrating the grades of the detected histopathological lesions of different animals groups using simple semiquantitative scoring system which confirmed the ameliorative role of dandelion extract on the presented cardiac lesions caused by DXR administration.



1-Photomicrograph of a section in the heart muscle from the control group showing apparently normal cardiac myocytes ($\times 400$), **2-** Photomicrograph of a section in the heart muscle from the DXR group showing dark acidophilic sarcoplasm of cardiomyocytes (arrow heads) ($\times 200$), **3-** Photomicrograph of a section in the heart muscle from the DXR group showing widespread sarcolemma lysis (asterisk) and congestion of blood vessels (arrows) ($\times 200$), **4-** Photomicrograph of a section in the heart muscle from the DXR group showing cardiomyocytolysis with extravasation of blood between muscle fibers (A) ($\times 200$), **5-** Photomicrograph of a section in the heart muscle from DXR+dandelion group showing vacuolation of cardiomyocytes with mild inflammatory cells infiltration (arrows) ($\times 200$), **6-** Photomicrograph of a section in the heart muscle from DXR+dandelion group showing congestion of blood vessels (blue arrow) and segmental hyalinization of cardiomyocytes (black arrow) ($\times 200$).

Table 3. The score of detected cardiac lesions in male Wistar albino rats of different experimental groups

Scored lesions	Incidence ¹ and Severity ² of histopathological Lesions							
	Doxorubicin (DOX)-treated rats				DOX+ Dandelion-treated rats			
	Absent (-)	Mild (+)	Moderate (++)	Severe (+++)	Absent (-)	Mild (+)	Moderate (++)	Severe (+++)
Heart								
1-Hypereosinophilic cardiomyocytes	0	0	4	3	1	4	2	0
2-Sarcoplasolysis	1	1	2	3	0	5	1	1
3-Cardiomyocytolysis with hemorrhage.	0	1	1	5	2	4	1	0
4-Congestion of blood vessels.	0	0	6	1	0	5	2	0
5-Hyalinization of cardiomyocytes.	0	1	5	1	0	4	2	1
6-Cardiomyocytes necrosis with mononuclear inflammatory cells infiltration.	0	2	3	2	0	4	3	0

¹Number of rats with lesions per total examined (7 rats).

²Severity of lesions was graded by estimating the percentage area affected in the entire section.

4. Discussion

Doxorubicin (DXR) is an as an effective anthracycline antibiotic against different types of malignancy (Booser and Hortobagyi, 1994; Gianni et al., 2008); however, doxorubicin-induced oxidative tissues damage would restrict its clinical usage (Nagi and Mansour, 2000; Fadillioglu and Erdogan, 2003; Fadillioglu et al., 2004; Wattanapitayakul et al., 2005). Furthermore, generation of superoxide free radical (Nagi and Mansour, 2000) and hydroxyl free radicals (Malisza and Hasinoff, 1995) have been suggested to be the main ROS implicated in DXR toxicity, so, our study focused on the possible ameliorative effect of dandelion extract as an antioxidant against DXR-induced hemato-cardiotoxicity. Concerning hematological findings, the significant decrement in RBCs count may be attributed to that lipids of erythrocytic membrane are more prone to peroxidation by free radicals (as those generated by

doxorubicin) (Chiu et al., 1982), resulting in its gradual damage which end with hemolysis of RBCs (Lee and Lee, 1997), erythrocytic destructive effect of doxorubicin has been earlier reported by Malarkodi et al., 2004). While, doxorubicin-associated granulocytopenia and monocytopenia might be a result of pronounced marrow depression caused by administration of doxorubicin (Falkson et al., 1985; Tsang et al., 2007). On the other hand, doxorubicin-induced lymphopenia could be explained based on the ability of doxorubicin to destroy the population of mature lymphocyte and elimination its precursors (Steele, 2002), depleting lymphocyte number in peripheral blood stream, thymus, spleen and lymph nodes (Pourtier-Manzanedo et al., 1995). The resultant leucopenia and lymphopenia upon treatment with doxorubicin was previously reported by Merzoug et al. (2014); Jaćević et al. (2018). The proved mitigation in hematological results upon combination of

dandelion with doxorubicin may be due to the potent antioxidant effect of dandelion (Choi et al., 2010; Kenny et al., 2014; Tan et al., 2017) which may stabilize erythrocytic membranes preventing its destruction and preventing lymphocytic DNA damage. Also, dandelion can stimulate production of interleukin-1 (IL-1) (Koo et al., 2004) which can ameliorate doxorubicin hematotoxicity (Eppstein et al., 1989) through its ability to increase colony stimulating factors (CSFs) (Ridgway et al., 1988; Schwartz et al., 1989), enhancing the marrow cells to enter into S, G2 and M phases and increase the reactivity of the precursor cells to GM-CSF (Neta et al., 1987) which collectively increase marrow leukocytic production. Serum level of CK-MB, LDH enzymes and troponin-I is considered as highly specific biomarkers for assessment of cardiac function as the magnitude of its elevation may reflect the severity of myocardiocytes membrane damage and loss of integrity (Latimar et al., 2003; Rohilla et al., 2012). The indicated oxidative stress generated by administration of DXR is supposed to be implicated in myocardial damage and release of these enzymes which in turn increased their level in serum of DXR-treated rats (Nagi and Mansour, 2000; Yu et al., 2013; Chen et al., 2015; Zhang et al., 2015; Khafaga and El-Sayed, 2017). In contrast, co-administration of dandelion with DXR to the rats significantly decreased the elevated serum level of the assessed myocardial enzymes and troponin-1, this cardioprotective action of dandelion may be owed to its previously proved antioxidant effect. In parallel, cardiac natriuretic peptides include atrial natriuretic peptide (ANP) and B-type natriuretic peptide (BNP) are assuming in the clinical evaluation of cardiac function (Clerico, 2002; Panteghini, 2004), specifically, ANP is secreted preferentially from atrial cardiomyocytes, while BNP is produced and secreted mainly in the left ventricle but also right ventricle can produce BNP in response to cardiac diseases (Struthers, 2002; Kay et al., 2003) and this may be an acceptable explanation for their level significant elevation in DXR-treated rats relying on the potential cardiotoxic effect of doxorubicin (Daugaard et al., 2005; Urbanova et al., 2008). Treatment with

dandelion significantly lowered serum level of these peptides (ANP, BNP) and this may illuminate and prove cardioprotective effect of dandelion as an antioxidant against DXR-induced oxidative myocardial damage. The results of our study recorded a significant increment in cardiac tissues content of MDA (lipid peroxide) with a depletion of enzymatic and non-enzymatic antioxidants (SOD and GSH) of DXR-treated rats which may reflect and confirm the oxidative stress status evoked through the treatment with DXR (Yu et al., 2013; Chen et al., 2015; Sun et al., 2015; Zhang et al., 2015; Khafaga and El-Sayed, 2017). Remarkably, treatment with dandelion effectively decreased cardiac MDA content and boosted the activity and/or content of different evaluated cardiac antioxidants, the eventual mechanism by which dandelion attenuated DXR-induced cardiotoxicity may be concluded in its powerful antioxidant effect in scavenging of the free radicals which mediate lipid peroxidation and tissues antioxidant exhaustion (Choi et al., 2010; Kenny et al., 2014; Tan et al., 2017). Finally, histopathological examination has confirmed the biochemical and tissue-oxidative alteration related to doxorubicin cardiotoxicity, as treatment with doxorubicin evoked various histopathological changes in the tissues of the heart including, sarcoplasmolysis, cardiomyocytolysis and hemorrhage. These changes are mostly associated with oxidative stress induced by doxorubicin administration causing apoptosis and necrosis of cardiomyocytes (Minotti et al., 2004; Zhang et al., 2009). Co-administration of dandelion extract with doxorubicin, extensively ameliorated DOX-induced cardiotoxicity, and this effect is suggested to be related to the previously mentioned antioxidant and free radicals scavenging activity of dandelion extract.

5-Conclusion

In conclusion, our study illuminated that dandelion extract has a great potency to ameliorate DXR-related hemato-cardiotoxicity through its prospective powerful antioxidant activity, thus, dandelion extract could be used as a protective agent during treatment with DXR to prevent its probable hemato-cardiotoxicity.

References

- Aebi H. (1984). Catalase in vitro. *Methods Enzymol.*, 105: 121-6.
- Ali Z (1989). *Medicinal Plants*. 1st ed. Tehran University Press, Tehran: Iran.
- Arafa MH, Mohamed NS, Atteia HH, Abdelaziz HR (2014). Protective effect of resveratrol against doxorubicin-induced cardiac toxicity and fibrosis in male experimental rats. *J. Physiol. Biochem.*, 70(3): 701-711.
- Bancroft JD, Stevens A (1996). *Theory and Practice of Histological Technique*. 4th ed. Churchill Livingstone.
- Booser DG, Hortobagyi GN (1994). Anthracycline antibiotics in cancer therapy-focus on drug resistance. *Drugs.*, 47: 223-258.
- Beutler E, Duron O, Kelly MB (1963). Reduced glutathione determination. *J. Lab. Clin. Med.*, 61:882.
- Cassidy SC, Chan DP, Rowland DG, Allen HD (1998). Effects of doxorubicin on diastolic function, contractile reserve, and ventricular-vascular coupling in piglets. *Pediatr. Cardiol.*, 19:450-457.
- Chen CT, Wang ZH, Hsu CC, Lin HH, Chen JH (2015). In vivo protective effects of diosgenin against doxorubicin-induced cardiotoxicity. *Nutrients.*, 7:4938-4954.
- Chiu D, Lubin B, Shohet SB (1982). Peroxidative reactions in red cell biology. In Pryor WP ed. *Free Radicals in Biology*, 4th Ed. New York: Academic Press., 115-153.
- Choi U, Lee O, Yim JH, Cho C, Rhee YK, Lim S, Kim Y (2010). Hypolipidemic and Antioxidant Effects of Dandelion (*Taraxacum officinale*) Root and Leaf on Cholesterol-Fed Rabbits. *Int. J. Mol. Sci.*, 11: 67-78.
- Clerico A (2002). Pathophysiological and clinical relevance of circulating levels of cardiac natriuretic hormones: are they merely markers of cardiac disease? *Clin. Chem. Lab. Med.*, 40:752-760.
- Daugaard G, Lassen U, Bie P, Pedersen EB, Jensen KT, Abildgaard U, Hesse B, Kjaer A (2005). Natriuretic peptides in the monitoring of anthracycline induced reduction in left ventricular ejection fraction. *Euro. J. Heart Failure.*, 7(1): 87-93.
- Doroshov JH, Locker GY, Myers CE (1980). Enzymatic defenses of the mouse heart against reactive oxygen metabolites: alterations produced by doxorubicin. *J. Clin. Invest.*, 65:128-135
- Eppstein DA, Kurahara CG, Bruno NA, Terrell TG (1989). Prevention of Doxorubicin-induced Hematotoxicity in Mice by Interleukin 1. *Cancer Res.*, 49: 3955-3960.
- Fadillioglu E, Erdogan H (2003). Effects of erdosteine treatment against doxorubicin-induced toxicity through erythrocyte and plasma oxidant/antioxidant status in rats. *Pharmacol. Res.*, 47: 317-322.
- Fadillioglu E, Oztas E, Erdogan H, Yagmurca M, Sogut S, Ucar M, Irmak MK (2004). Protective Effects of Caffeic Acid Phenethyl Ester on Doxorubicin-induced Cardiotoxicity in Rats. *J. Appl. Toxicol.*, 24: 47-52.
- Falkson G, Klein B, Falkson H (1985). Hematological toxicity: experience with anthracyclines and anthracenes. *Exp. Hematol.*, 13(16): 64-71.
- Gianni L, Herman EH, Lipshultz SE, Minotti G, Sarvazyan N, Sawyer DB (2008). Anthracycline cardiotoxicity: from bench to bedside. *J. Clin. Oncol.*, 26:3777-3784.
- Gonzalez ID, Saez RS, Rodilla EM (2005). Hypersensitivity reactions to chemotherapy drugs. *Allergy & Clin. Immunol.*, 15: 161-181.
- Harikrishnan R, Balasundaram C, Heo M (2011). Impact of plant products on innate and adaptive

- immune system of cultured finfish and shellfish. *AQUACULTURE.*, 317 : 1-15.
- Hu C, Kitts DD (2005). Taraxacum officinale (Dandelion) flower extract suppress both reactive oxygen species and nitric oxide prevents lipid oxidation in vitro. *Photomed.*, 2005: 588-597.
- Hynek D, Krejcova L, Zitka O, Adam V, Trnkova L, Sochor J (2012). Electrochemical Study of Doxorubicin Interaction with Different Sequences of Double Stranded Oligonucleotides, Part II. *Int. J. Electrochem. Sci.*, 7: 34-49.
- Jensen BV, Skovsgaard T, Nielsen SL (2002). Functional monitoring of anthracycline cardiotoxicity: a prospective, blinded, long-term observational study of outcome in 120 patients. *Ann. Oncol.*, 13: 699-709.
- Kang MJ, Shin SR, Kim KS (2002). Antioxidant and free radicals scavenging activity of water extract from Dandelion (*Taraxacum officinale*). *Korean J. food Preserv.*, 9 (2): 253-259.
- Kay JD, Trichon BH, Kisslo K, Gehring T, Harrison JK, Wang A, Tapson V, Newby LK, Bashore TM (2003). Serum brain natriuretic peptide levels cannot differentiate pulmonary disease from left-heart failure if the right ventricle is dilated. *Circulation.*, 108(17): 397.
- Kenny O, Smyth TJ, Hewage CM, Brunton NP (2014). Antioxidant properties and quantitative UPLC-MS/MS analysis of phenolic compounds in dandelion (*Taraxacum officinale*) root extracts. *Free Radicals and Antioxidants.*, 4 (1):55-61.
- Khafaga AF, El-Sayed YS (2017). All-trans-retinoic acid ameliorates doxorubicin-induced cardiotoxicity: in vivo potential involvement of oxidative stress, inflammation, and apoptosis via caspase-3 and p53 down-expression. *Naunyn-Schmiedeberg's Arch. Pharmacol.*, 387:921-933.
- Kim Y, Rho J, Kim K, Cho C, Rhee Y, Choi U (2008). Phenolic content and ROS scavenging activity of dandelion. *Korean J food Preserv.*, 15 (3): 325-331.
- Koo H, Hong S, Song B, Kim C, Yoo Y, Kim H (2004). *Taraxacum officinale* induces cytotoxicity through TNF-alpha and IL-1 alpha secretion in Hep G2 cells. *Life Sci.*, 74(9): 1149-1157.
- Latimer KS, Mahaffey EA, Prasse KW (2003). *Veterinary Laboratory Medicine, Clinical Pathology*. 4th Ed. Iowa State Press: USA.
- Lee SK, Lee BM (1997). Oxidation of erythrocyte protein and lipid, and hemolysis in rabbit red blood cells treated with benzo [a] pyrene or adriamycin. *J. Toxicol. Environ. Health.*, 51: 557-569.
- Malarkodi KP, Sivaprasad R, Varalakshmi P (2004). Effect of lipoic acid on the oxidoreductive status of red blood cells in rats subject to oxidative stress by chronic administration of adriamycin. *Human & Experim. Toxicol.*, 23: 129-135.
- Malisza KL, Hasinoff BB (1995). Production of hydroxyl radical by iron (III)-anthraquinone complexes through self-reduction and through reductive activation by the xanthine oxidase/hypoxanthine system. *Arch. Biochem. Biophys.*, 321:51-60.
- Merzoug S, Toumi ML, Tahraoui A (2014). Quercetin mitigates Adriamycin-induced anxiety and depression-like behaviors, immune dysfunction, and brain oxidative stress in rats. *Naunyn-Schmiedeberg's Arch. Pharmacol.*, 387:921-933.
- Mimnaugh EG, Trush MA, Bhatnagar M, Gram TE (1985). Enhancement of reactive oxygen-dependent mitochondrial membrane lipid peroxidation by the anticancer drug adriamycin. *Biochem Pharmacol.*, 34: 847-856.

- Minotti G, Menna P, Salvatorelli E, Cairo G, Gianni L (2004). Anthracyclines: molecular advances and pharmacologic developments in antitumor activity and cardiotoxicity. *Pharmacol. Rev.* 56:185–229.
- Modaresi M, Resalatpour N (2012). The Effect of Taraxacum officinale Hydroalcoholic Extract on Blood Cells in Mice. *Advances in Hematology*, doi:10.1155/2012/653412.
- Nagi MN, Mansour MA (2000). Protective Effect of Thymoquinone Against doxorubicin-Induced cardiotoxicity in Rats: A possible Mechanism of Protection. *Pharmacol. Res.*, 41(3): 284-289.
- Neta R, Szein BM, Oppenheim JJ, Gillis S, Douches DS (1987). The In Vivo Effects of Interleukin 1. I. Bone Marrow Cells Are Induced to Cycle after Administration of Interleukin 1. *J. Immunol.*, 139: 1861–1866.
- Panteghini H (2004). Role and Importance of Biochemical Markers in Clinical Cardiology. *Euro. Heart J.*, 25(14): 1187-1196.
- Pourtier-Manzanedo A, Didier A, Froidevaux S, Looor F (1995). Lymphotoxicity and myelotoxicity of doxorubicin and SDZ PSC 833 combined chemotherapies for normal mice. *Toxicol.*, 99: 207–217.
- Rauwald HW, Huang JT (1985). Taraxacosides a type of Acylated Gamma-butyrolactone from Taraxacum officinale. *Phytochem.*, 31: 1557-1559.
- Ridgway DD, Borzy SM, Bagby CM (1988). Granulocyte Macrophage Colony-Stimulating Activity Production by Cultured Human Thymic Nonlymphoid Cells Is Regulated by Endogenous Interleukin 1. *Blood.*, 72: 1230–1236.
- Rohilla A, Khan MU, Khanam R (2012). Cardioprotective potential of simvastatin in the hyperhomocysteinemic rat heart. *J. Adv. Pharm. Technol. Res.*, 3:193–198.
- Saeki K, Obi I, Ogiku N, Shigekawa M, Imagawa T, Matsumoto T (1998). Doxorubicin directly binds to the cardiac typeryanodine receptor. *Life Sci.*, 19: 450–457.
- Schwartz NG, Patchen LM, Neta R, MacVittie TJ (1989). Radioprotection of Mice with Interleukin 1: Relationship to the Number of Spleen Colony-Forming Units. *Radiat. Res.*, 119: 101–112.
- Steele TA (2002). Chemotherapy-induced immunosuppression and reconstitution of immune function. *Leuk. Res.*, 26:411–414.
- Struthers AD (2002). Introducing a new role for BNP: as a general indicator of cardiac structural disease rather than a specific indicator of systolic dysfunction only. *Heart.* 87:97–8.
- Sun R, Liu Y, Li SY, Shen S, Du XJ, Xu CF, Cao ZT, Bao Y, Zhu YH, Li YP, Yang XZ (2015). Co-delivery of all-trans-retinoic acid and doxorubicin for cancer therapy with synergistic inhibition of cancer stem cells. *Biomaterials.*, 37:405–414.
- Tacar O, Sriamornsak P, Das CR (2013). Doxorubicin: an update on anticancer molecular action, toxicity and novel drug delivery systems. *Royal Pharmaceutical Society 2013 J. Pharma&Pharmacol.*, 65: 157–170.
- Tan X, Sun Z, Chen S, Chen S, Huang Z, Zhou C, Zou C, Liu Q, Ye H, Lin H, Ye C, Wang A (2017). Effects of dietary dandelion extracts on growth performance, body composition, plasma biochemical parameters, immune responses and disease resistance of juvenile golden pompano *Trachinotus ovatus*. *Fish & Shellfish Immunol.*, 66: 198-206
- Tsang YW, Chi KH, Hu CJ, Tseng CL, Tseng FW, Wang YS (2007). Chemotherapy-induced immunosuppression is restored by a fermented soybean extract: a proof of concept clinical trial. *Nutr. Res.*, 27: 679–684.

- Ukeda H, Maeda S, Ishii T, Sawamura M (1997). Spectrophotometric assay for superoxide dismutase based on tetrazolium salt 3'--1--(phenylamino)-carbonyl--3,4-tetrazolium]-bis(4-methoxy-6-nitro) benzenesulfonic acid hydrate reduction by xanthine-xanthine oxidase. *Anal.Biochem.*, 251: 206-9.
- Urbanova D, Urban L, Danova K, Simkova I (2008). Natriuretic peptides: biochemical markers of anthracycline cardiac toxicity?. *Oncology Research Featuring Preclinical and Clinical Cancer Therapeutics.*, 17(2): 51-58.
- Vendramini V, Sasso-Cerri E, Miraglia SM (2010). Amifostine reduces the seminiferous epithelium damage in doxorubicin-treated prepubertal rats without improving the fertility status. *Rep. Biol. Endocrinol.*, 8 (3): 1-13.
- Jačević V, Dragojević-Simić V, Tatomirović Ž, Dobrić S, Bokonjić D, Kovačević A, Nepovimova E, Vališ M, Kuća K (2018). The Efficacy of Amifostine against Multiple-Dose Doxorubicin-Induced Toxicity in Rats. *Int. J. Mol. Sci.*, 19: 2370-2382.
- Wang YM, Madanat FF, Kimball JC, Gleiser CA, Ali MK, Kaufman MW, van Eys J (1980). Effect of vitamin E against adriamycin-induced toxicity in rabbits. *Cancer Res.*, 40: 1022–1027.
- Wattanapitayakul SK, Chularojmontri L, Herunsalee A, Charuchongkolwongse S, Niumsukul S, Bauer JA (2005). Screening of Antioxidants from Medicinal Plants for Cardioprotective Effect against Doxorubicin Toxicity. *Basic & Clin. Pharmacol. Toxicol.*, 96: 80–87.
- Williams CA, Goldstone F, Greeham J (1996). Flavonoids, cinnamic acids and coumarins from the different tissues and medicinal preparations of *Taraxacum officinale*. *Phytochemistry.* 42: 121–127.
- Yu X, Cui L, Zhang Z, Zhao Q, Li S (2013). Alpha-linolenic acid attenuates doxorubicin-induced cardiotoxicity in rats through suppression of oxidative stress and apoptosis. *Acta.Biochim.Biophys.Sin.Shanghai.*, 45:817–826.
- Zhang YW, Shi J, Li YJ, Wei L (2009). Cardiomyocyte death in doxorubicin-induced cardiotoxicity. *Arch. Immunol. Ther. Exp.*, 57: 435–445.
- Zhang T, Xiong H, Dahmani FZ, Sun L, Li Y, Yao L, Zhou J, Yao J (2015). Combination chemotherapy of doxorubicin, all-trans retinoic acid and low molecular weight heparin based on self assembled multi-functional polymeric nanoparticles. *Nanotechnology.*, 26 (14):145101.