

Correlating the Volume of Diced Cartilage Grafts and the Gain in Nasal Dorsal Height Following Nasal Dorsum Augmentation

NADA A. MAHMOUD, M.D. and KARIM S. MASSOUD, M.D.

The Department of Plastic, Burn and Maxillofacial Surgery, Faculty of Medicine, Ain Shams University, Cairo, Egypt

ABSTRACT

Background: Dorsal nasal depression can be corrected by various methods. In this study we aim to correlate the height gain in the nasal dorsum with a fixed amount (1ml) of diced cartilage grafts wrapped in deep temporal fascia used for dorsal nasal correction.

Patients and Methods: In this study included 14 patients with dorsal nasal depression treated by one ml of diced cartilage grafts wrapped in 20 X 40mm deep temporal fascial graft. We correlated the gained height with a determined amount of diced cartilage grafts.

Results: The results were documented to correlate the gained height in the nasal dorsum. Results were evaluated objectively and subjectively.

Conclusion: Our findings show that there is a correlation between the gained height of the nasal dorsum and the amount of diced cartilage grafts used in nasal dorsal augmentation. This preliminary finding needs further investigation on larger patients' population and variable amount of cartilage grafts to validate these data.

Key Words: Rhinoplasty – Nasal reconstruction – Saddle nose – Diced cartilage – Nasal dorsum – Temporal fascia.

INTRODUCTION

Many types of graft materials have been used in rhinoplasty procedures and are still being used to fix nasal dorsum irregularities and provide support for the nasal dorsum [1].

Although cartilage grafts are the most commonly used grafts in rhinoplasty, they are not free of complications. They tend to warp to original shapes, even many years after implantation, which lead to visible deformities. Diced cartilage grafts were implemented to overcome these problems [2].

Diced cartilages had been used by many authors [2-5]. However, one or 2 years post-operatively, diced cartilages may become noticeable through nasal skin. To avoid these problems and to obtain a smoother surface, the use of diced cartilage

wrapped in surgicell or fascia had been described [5,6].

The predictability of clinical outcome with these diced grafts still conflicting. The degree of crushing is an important factor in cartilage viability and clinical predictability. Slight crushing causes variable amounts of chondrocyte proliferation with preserving viability. This level of crushing can produce over growth than required to a specific defect. However, as the severity of crushing increases, cartilage viability, chondrocyte proliferation, and predictability of clinical outcome all decrease, which may explain why surgeons have recommended some degree of overcorrection when using crushed cartilage material in the nasal dorsum [7].

So, the adequate amount of diced cartilage required to deal with dorsal nasal irregularity still confusing and implemented to individual surgeon judgement.

The aim of this study is to correlate the dorsal height gained in relation to a determined volume (1ml) of the diced cartilage graft wrapped in 20 X 40mm deep temporal fascial graft inserted to nasal dorsum.

PATIENTS AND METHODS

This study included 14 patients between February 2015 and June 2017 in Ain Shams University Hospitals. Patients included in the study had moderate dorsal nasal depression. Severe cases that required structural support and syndromic patients were excluded from the study. All patients included in the study were psychologically stable.

Pre-operative evaluation including history and clinical examination were done. Frontal and profile photos were taken pre-operatively. Pre-operative measurements were documented, and informed consent was obtained.

Operative technique: All patients were operated upon under general anesthesia with addition of local anesthesia (mixture of xylocaine 1% with adrenaline 1:100 000). The area to be augmented was marked on the nasal dorsal skin before infiltration of local anesthesia. Open rhinoplasty approach was used in all patients to gain exposure of the underlying bony and cartilaginous framework.

The graft source included septal cartilage, conchal cartilage, and cartilage trimmed from the lateral crura. The harvested cartilage was diced into 0.5-to 1-mm cubes using a No. 11 blade and packed into the cylinder of a 1-ml syringe.

Harvesting of the temporal fascia through a curved 3-cm temporal incision was done above the root of the helix and 2 to 3cm behind the anterior hairline. The incision was placed parallel to hair follicles to avoid the risk of alopecia. The superficial temporal fascia was incised down to the glistening white surface of deep temporal fascia. A rectangle of deep temporal fascia measures 40 X 20mm was harvested and placed in a saline-soaked gauze.

After harvesting, the fascia was wrapped around a catheter 1-mm in diameter and secured in place using 5-0 PDS sutures. In this manner, formation of a hollow, sleeve-like sheath was formed. The fascial cylinder was then filled with one milliliter of diced cartilage. Then the fascial graft containing the diced cartilage was inserted to fit the recipient site defect with molding of the graft to create the

desired contour. Suturing of both ends was done to close the cylinder and to prevent extrusion of the inserted diced cartilage Fig. (1).

The nasal incision was closed with application of septal splint (in case of septal cartilage graft). The donor site of the temporal fascia was closed in layers. Steri-strips and external nasal splinting were placed over the nasal dorsum to maintain the graft in position for 1 week.

In the post-operative period, the patient is nursed in semi sitting position. Short course of antibiotics was prescribed for 3 days. The sutures were removed on the 5th day, the nasal splint on the 7th day, and the septal splint on the 14th day. Any complications including graft infection, contour irregularity and post-operative deformity were documented as well as patient satisfaction. At 6 months, post-operative measurements and subjective assessment were recorded.

Assessment of results: Pre-operative measurements and photos were obtained to determine the height of nasal dorsum; a line was marked representing the base of the nose extending between a point at the inner canthus and another point at the alar base. The middle point of this line was known as (Point A). Another line was drawn from the radix to the supra-tip point representing the nasal dorsum. A point at the middle of this line was marked as (Point B). The A-B line was marked and measured representing the height of nasal dorsum Fig. (2). Post-operative measurements of line (A-B) were taken at 6 months post-operatively.




Fig. (1): A) Temporal fascia 40 X 20 was harvested, B) Wrapped around a catheter 1ml in diameter, C) Fascia closed at one end using 5-0 PDS sutures, D) Diced cartilage prepared and put into 1ml insulin syringe, E) Filling the temporal sleeve with the diced cartilage, F) Closure of the other end.

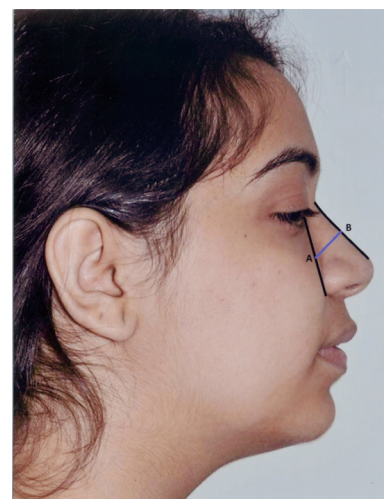

Fig. (2): First drawing a line between the inner canthus and alar base, point (A) is at the middle of this line. Another line is drawn from the radix to the supra tip point, point (B) is at its middle. (A-B) line is drawn to detect the gain of nasal height.

The measurements of line (A-B) were compared pre and post-operatively to assess the gained height after dorsal augmentation with diced cartilage. Then, we correlate between the amount of diced cartilage grafts injected and the height gained in the nasal dorsum. Data were analyzed using Statistical Program for Social Science (SPSS) version 20.0. Quantitative data were expressed as mean ± Standard Deviation (SD). The tests used were *t*-test, and *p*-value test when *p*-value was <0.05 it considered significant.

In addition to objective assessment, aesthetic outcome was subjectively evaluated by overall patient satisfaction score (four-point scale: Excellent, good, fair and poor).

RESULTS

This study included 14 patients (9 females and 5 males). Patients' age ranged from 21-45 years with a mean of 33.7 years. In 9 patients, the etiology was post traumatic without dorsal nasal scar and in 5 patients, the cause was post rhinoplasty. All the 14 cases received 1ml of diced cartilage graft wrapped in 20 X 40mm deep temporal fascia.

All patients had an uneventful post-operative period without major complication recorded. Edema subsided 2-4 weeks post-operatively.

The A-B line measurements recorded pre-operatively and 6 months post-operatively (Table 1). Correlating the above results revealed that application of 1mm of diced cartilage wrapped in 20 X 40mm temporal fascia achieved 4-5mm gain in dorsal nasal height. The difference between pre and post-operative nasal dorsum was statistically significant. The *p*-value was <0.05.

Table (1): Pre-operative and post-operative measurements of A-B line and correlation between the amounts of diced cartilage injected and gained height.

No.	(A-B) line pre-op. (mm)	(A-B) line post-op. (mm)	The gained dorsal height (mm)	<i>P</i> -value
1	17	21	4	0.037
2	17.5	21	4.5	0.025
3	17	22	5	0.018
4	16	20	4	0.035
5	16	21	5	0.020
6	16.5	20.5	4	0.036
7	17	22	5	0.018
8	17	21	4	0.037
9	16.5	21	4.5	0.024
10	16	20	4	0.035
11	16	21	5	0.020
12	17	22	5	0.018
13	16.5	21	4.5	0.024
14	17	21.5	4.5	0.025
Mean & SD	16.64 (SD 0.497)	21.07 (SD 0.646)	4.50 (SD 0.438)	<0.05

Subjective assessment revealed that dorsal nasal elevation and smooth continuity of the nasal dorsum could be achieved in all patients with overall satisfactory results. The patient's satisfaction score was excellent in 7 patients, good in 5 patients, and fair in 2 patients (Fig. 3).

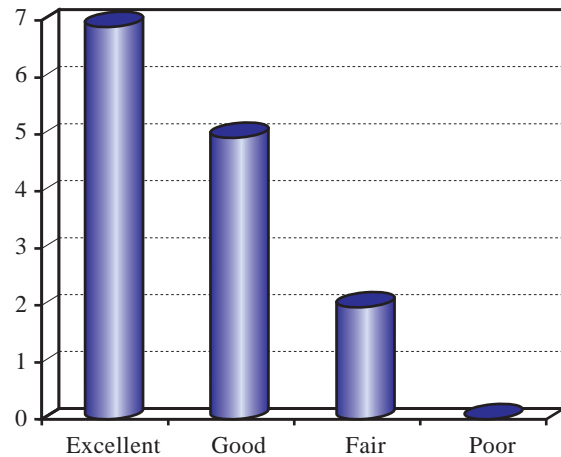


Fig. (3): Post-operative subjective assessment score chart.

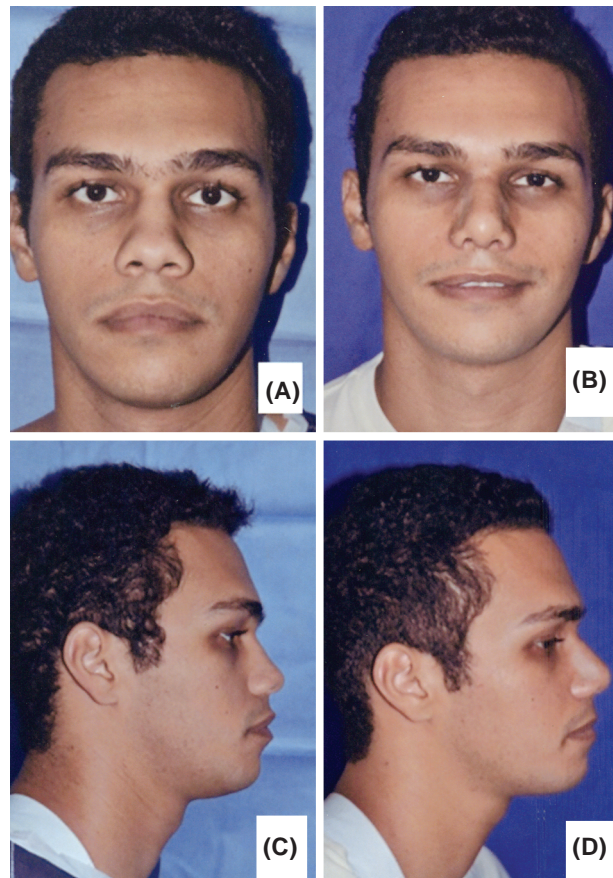


Fig. (4): A male patient 22 years old with moderate nasal depression. There is a 5mm gained dorsal height, (A,B) Pre & post-operative anteroposterior views, (C, D) Pre & post-operative lateral views.

DISCUSSION

Rohrich et al., [8] used naso-facial analysis to assess the nasal dorsum. They stated that, from the lateral view, the dorsum should be equal to a line drawn from the radix to the tip-defining points in male. However, in female, the dorsum should be along a line approximately 2mm more posterior, but still parallel. Any irregularities in this line either above or below can represent hump or depression.

The use of diced cartilage grafts had been popularized over the past decade. The small fragments of cartilage allow easy manipulation and help surgeons to avoid cartilage graft associated complications specially warping commonly seen when single and larger solid-cartilage grafts are inserted [4].

Moreover, diced cartilage grafts revascularize faster than solid grafts due to the increased surface area available for vascularization. The main challenges with this method of grafting are adequately controlling the insertion of the composite graft onto the nasal dorsum and maintaining the stability of position post-operatively. Wrapping the diced cartilage into a sleeve of temporal fascia could address these challenges [6].

Erol's technique [6] utilized small pieces of diced cartilage wrapped in surgicel. It was placed on the bony roof in primary or secondary rhinoplasty. It formed a smooth surface that could be manipulated via external manual pressure. Common complications reported with this technique were early post-operative swelling and resorption of the graft beyond the expected amount.

Many authors [4,9-15] have used composite grafts consisting of fragmented and crushed conchal cartilage wrapped with temporal fascia for reconstruction of nasal dorsum deformities. The temporal fascia has excellent survival and acts as neo perichondrium (when surrounding the diced cartilage). It provides a pliable dorsal graft with minimal visibility and a smooth transition between dorsum and lateral nasal subunits, without the risk of warping.

Although satisfactory results could be achieved from the use of diced cartilage, none of the authors studied the correlation between amount of cartilage graft inserted and the gained height for nasal dorsum. This point of research is very helpful to guide surgeon for the required amount of cartilage graft and the desired elevation in nasal dorsum.

Nicolae and colleagues [16] simulated dorsal nasal augmentation using dental impression material. This work helped to establish the degree of desired augmentation of the nasal dorsum. In addition, to estimate the approximate dimensions and contour of the chondro-fascial graft.

In our work, we used variable amount of diced cartilage to manage different dorsal nasal defects. However, we found that most of these patients (14 patients) had received 1 cubic milliliter of diced cartilage. The other volumes were sporadic and variable, so it was difficult to reach a valuable data from these heterogenous patients' population. Therefore, we concentrated our study on the most frequently used volume of cartilage graft.

The other point, we used a fascial graft with a fixed measure 40 X 20mm as described before [9] to avoid the differences in length of nasal dorsum. Any patients with very long or very short nose that needed different sizes of temporal fascial grafts were not included in the study. Furthermore, these dimensions are comparable to the length of nasal dorsum in most of our patient's population.

Our results showed that application of 1ml of diced cartilage graft in a 40 X 20mm deep temporal fascial graft could produce a gain of 4-5mm in dorsal nasal height. This preliminary finding can be used as a guide to predict the elevation of nasal dorsum in response to a determined volume of dice cartilage graft application. From practical point of view, these measures of the temporal fascial graft and diced cartilage graft fit to most of clinical cases that require dorsal augmentation.

This work has some limitations including the small patient's population and the use of only a fixed volume of cartilage graft. Further studies on larger patient's population with longer follow-up periods are warranted. Also, the use of different volumes of cartilage graft in different sizes of fascial grafts, in different nasal lengths are other important points of research not yet explored. The goal of all these points is to reach an equation that can predict the gain of dorsal nasal height in response to different volumes of diced cartilage grafts in different nasal lengths. This study represents an early step in this road which is not sufficiently explored.

Conclusion:

Application of 1ml of diced cartilage graft in a 40 X 20mm deep temporal fascial graft could produce a gain of 4-5mm in dorsal nasal height. This preliminary finding can be used as a guide to

objectively predict the gain in nasal dorsal height in response to a determined volume of diced cartilage graft. Clinically, these measures can fit to most of clinical cases that require dorsal augmentation. There are many points are needed in this field of research including the use of different volumes of diced cartilage graft in different sizes of fascial grafts and in different nasal lengths.

REFERENCES

- 1- Tarhan E., Cakmak O., Ozdemir B.N., Akdogan V. and Suren D.: Comparison of alloderm, fat, fascia, cartilage and dermal grafts in rabbits. Arch. Facial Plast. Surgery, 10: 187-93, 2008.
- 2- Peer L.A.: Diced cartilage grafts. Arch. Otolaryngol., 38: 156, 1943.
- 3- Young F.: Autogenous cartilage grafts. Surgery, 10: 7, 1941.
- 4- Daniel R.K. and Calvert J.W.: Diced cartilage grafts in rhinoplasty surgery. Plast. Reconstr. Surg., 113: 2156-71, 2004.
- 5- Wilflingseder P.: Cranioplasties by means of diced cartilage and split rib grafts. Minerva Chir., 38: 837-43, 1983.
- 6- Erol O.: The Turkish delight: A pliable graft for rhinoplasty. Plast. Reconstr. Surg., 105: 2229-41, 2000.
- 7- Ozcan Cakmak, M.D.; Sema Bircan, M.D.; Fuat Buyuklu, M.D.; Ilhan Tuncer, M.D.; Teoman Dal, M.D. and Levent Naci Ozluoglu, M.D.: Viability of Crushed and Diced Cartilage Grafts Arch. Facial Plast. Surg., 7: 21-6, 2005.
- 8- Rohrich R., Muzaffar A. and Janis J.: Component Dorsal Hump Reduction: The Importance of Maintaining Dorsal Aesthetic Lines in Rhinoplasty. Plastic and reconstructive surgery, Vol. 114, No. 5, 1298-308, 2004.
- 9- Daniel R.K.: The role of diced cartilage grafts in rhinoplasty. Aesthetic Surg. J., 26 (2): 209-13, 2006.
- 10- Daniel R.K.: Diced cartilage grafts in rhinoplasty surgery: Current techniques and applications. Plast. Reconstr. Surg., 122 (6): 1883-91, 2008.
- 11- Daniel R.K.: Rhinoplasty: Dorsal grafts and the designer dorsum. Clin. Plast. Surg., 37 (2): 293-300, 2010.
- 12- Guerrerosantos J., Trananino C. and Guerrerosantos F.: Multifragmented cartilage wrapped with fascia in augmentation rhinoplasty. Plast. Reconstr. Surg., 117 (3): 804-12, 2006.
- 13- Kelly M.H., Bulstrode N.W. and Waterhouse N.: Versatility of diced cartilage-fascia grafts in dorsal nasal augmentation. Plast. Reconstr. Surg., 120 (6): 1654-9, 2007.
- 14- Gerbault O. and Aiach G.: Diced cartilage wrapped in deep temporal aponeurosis (DC-F): A new technique in augmentation rhinoplasty [in French]. Ann. Chir. Plast. Esthet., 54 (5): 477-85, 2009.
- 15- Unlü R.E., Altun S., Inozu E. and Koc M.N.: Diced cartilage grafts in rhinoplasty surgery: Current techniques and applications. Plast. Reconstr. Surg., 124 (2): 666, 2009.
- 16- Antohi N., Isac C., Stan V. and Ionescu R.: Dorsal Nasal Augmentation with "Open Sandwich" Graft Consisting of Conchal Cartilage and Retroauricular Fascia. Aesthet. Surg. J., Sep., 32 (7): 833-45. Doi: 10.1177/1090820 X 12456196, 2012.