

## Evaluation of Deformities, Procedures and Cosmetic Outcomes of Post-Bariatric Mammoplasty

FOUAD M. GHAREEB, M.D.; DALIA M. ALSAKA, M.D.; AHMED T. NASSER, M.D. and MAHMOUD M. ELREFAI, M.B.B.Ch., M.Sc.

*The Department of Plastic Surgery, Faculty of Medicine, Menoufia University, Egypt*

### ABSTRACT

**Objectives:** The aim of this work is to evaluate the different modalities of post-bariatric breast reshaping in females and their aesthetic outcomes and rate of complications.

**Background:** The post-bariatric breast is a real problem after massive weight loss especially in females. Different modalities for the reshaping of post-bariatric breast were used.

**Patients and Methods:** This a prospective cohort study statistical technique, descriptive statistics as numbers and percentages were used, conducted over 20 post-bariatric breast patients requesting breast contouring in the period from January 2016 to January 2019. Operations were done in Menoufia University and Railways Hospitals. Patient's age ranged from 21-49 years. A total of 20 procedures were performed; reduction mammoplasty in 5 patients, auto augmentation in 8 patients, augmentation mastopexy in 5 patients, and implant augmentation in 2 patients.

**Results:** Patient's satisfaction was measured by aesthetic rating scale as follow; 1- Very satisfied, 2- Satisfied, 3- Fair, and 4- Dissatisfied regarding improvement in size, shape, and quality of scar. 14 patients were very satisfied (70%), 4 patients were satisfied (20%), and 2 patients were fairly satisfied (10%). And out of the 20 patients, the overall complication rate was 30%.

**Conclusion:** Breast auto augmentation for breast reshaping in post bariatric patients is an ideal and long life technique comparable to other techniques used to address this issue.

**Keywords:** *Aesthetic outcome – Breast deformities – Breast reshape – Post-bariatric.*

### INTRODUCTION

Many people all over the world are suffering from obesity and its sequel [1]. The patients usually start a slimming process that is commonly followed by a Massive Weight Loss (MWL) which require a body contouring processes to treat excess inelastic skin especially in the areas of breast, arms, abdomen and thighs [2].

Breast deformities in post-bariatric surgeries are different from those of non surgical post bari-

atric histologically [3]. The post bariatric breast is characterized by excess inelastic skin, ptosis, loss of upper pole fullness, medialization of the nipples, volume depletion, and the presence of the lateral chest wall rolls [4].

According to Pittsburgh rating scale, post bariatric breast is classified into 3 categories, each category should be treated by a suitable method. Grades I/II or severe macromastia needs to be treated by traditional mastopexy, reduction, and augmentation techniques. Grade III or moderate volume loss or constricted breast needs to be treated by traditional mastopexy with or without augmentation, and severe lateral roll and or severe volume loss with loose skin are treated by parenchymal reshaping techniques with dermal suspension, consider auto augmentation as shown in the (Table 1) [5].

The time of surgery is preferable to be performed when the weight of the patient, and consequently the Body Mass Index (BMI), is stable for at least 6 months or after 1.5 years [6].





The degree of ptosis and their management determine the surgical technique used [7]. For ptosis of the Nipple-Areola Complex (NAC) <3cm, and a distance <5cm from the NAC to the inframammary fold, and no excess in the inferior pole of the breast, regular silicone breast augmentation is indicated. For ptosis of the NAC <3cm, with a distance >5cm from the NAC to the inframammary fold, and moderate excess both above and below the NAC, periareolarmastopexy is indicated. For more severe cases, the ptosis of the NAC >3cm, the distance from the NAC to the inframammary fold is >5cm, and a considerable tissue excess above and below the NAC, mastopexy with or without augmentation is indicated [8].

Complications of mastopexy may be major like thromboembolic events, bleeding, infected seroma, infected wound, abscess, or minor complications like hematoma, seroma, wound dehiscence, unfavorable scar, fat necrosis, asymmetry, nipple and or areola loss, and silicon implant complications including contracture, rupture, double bubble,

wrinkling or Anaplastic Large Cell Lymphoma (ALCL) [9].

In this work, we evaluated the different modalities of post bariatric breast reshaping in females in reference to the aesthetic outcome and rate of complications.

Table (1): Pittsburgh rating scale.

Scale	Deformity	Photo	Procedure
0	<ul style="list-style-type: none"> <li>• Normal</li> </ul>		<ul style="list-style-type: none"> <li>• None</li> </ul>
1	<ul style="list-style-type: none"> <li>• Ptosis grade I/II or severe macromastia.</li> </ul>		<ul style="list-style-type: none"> <li>• Traditional mastopexy, reduction, or augmentation techniques.</li> </ul>
2	<ul style="list-style-type: none"> <li>• Ptosis grade III or moderate volume loss or constricted breast.</li> </ul>		<ul style="list-style-type: none"> <li>• Traditional mastopexy ± augmentation.</li> </ul>
3	<ul style="list-style-type: none"> <li>• Severe lateral roll and/or severe volume loss with loose skin.</li> </ul>		<ul style="list-style-type: none"> <li>• Parynchomal reshaping techniques with dermal suspension, consider autoaugmentation</li> </ul>

**PATIENTS AND METHODS**

First the approval of Menoufia Ethics Committee for the study proposal was taken. All patients gave a written informed consent before inclusion into the study. The study is a descriptive prospective cohort study as numbers and percentages were used, sample size did not calculate in the present study as it was a descriptive study that was Linked to a study time not a study sample. The time of our study lasted from January 2016 to January 2019. This study involved 20 post bariatric female breast patients requesting breast contouring. Operations were done in Menoufia University and Railways Hospitals. Patient's demographic data included all patients with an age ranging from 21 to 49 years old. Their BMI ranged from 24 to 32kg/m<sup>2</sup> with a mean BMI of 28.9kg/m<sup>2</sup>. Fifteen patients (75%) lost weight through bariatric surgery while five (25%) patients lost weight through diet control and exercise. All patients have a stable weight for a period ranged from 12-24 months. All patients underwent pre-operative evaluation in the form of history taking, thorough examination, laboratory investigations, ultrasonography, mammography for women above 40 years, photographic evaluation and documentation. The breast was examined for Quality and amount of skin laxity, breast volume, and degree of ptosis. Pittsburgh's classification was applied to the patients included in this study. Out of the 20 patients; 10 of them were Pittsburgh I, 7 of them were classified as Pittsburgh II, and lastly, 3 patients were Pittsburgh grade III. Pre-operative marking was done before surgery to ensure the choice of the right plan. A total of 20 procedures were performed; reduction mammoplasty in 5 patients, auto-augmentation mastopexy in 8 patients 6 of them were by dermal suspension technique as shown in Fig. (3), implant augmentation mastopexy in 5 patients, and pure implant augmentation in 2 patients.

*Statistical analysis:*

All data were collected, tabulated and statistically analyzed using SPSS 19.0 for windows (SPSS Inc., Chicago, IL, USA) & MedCalc 13 for windows (MedCalc Software BVBA, Ostend, Belgium).

**RESULTS**

Different techniques were used; reduction mammoplasty in 5 patients (25%) and augmentation mastopexy with implant in 5 patients (25%) and auto augmentation mastopexy in 8 patients (40%) and augmentation with silicone implant (10%) (Table 2).

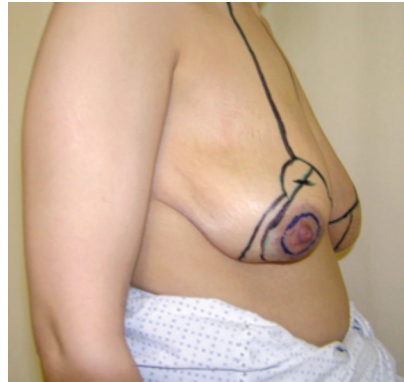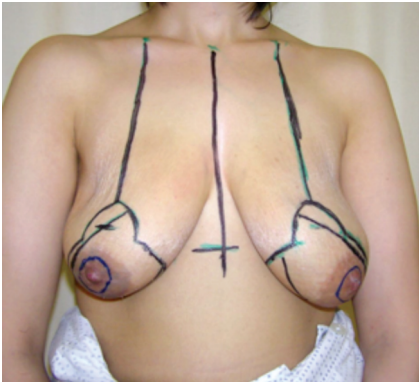Pre and post-operative photographic evaluation was done. Patient's satisfaction regarding improvement in size, shape, and asymmetry and NAC position and size were analyzed. Satisfaction was rated in the form of; 1- Very satisfied, 2- Satisfied, 3- Fair, and 4- Dissatisfied and regarding improvement in size, shape, and NAC position and size and symmetry and scars and were analyzed. Pre and post-operative photos were analyzed by another 2 plastic surgeons. A scale of 1- Excellent, 2- Good, 3- Fair, 4- Poor was used, the patients were analyzed for degree of ptosis correction, correction of asymmetry. Any complications like a hematoma, and seroma were recorded. Post-operative data analysis revealed that fifteen patients (70%) were very satisfied, four patients were moderately satisfied (20%), and two patients were somewhat satisfied (10%). The fully satisfied patients were 7 auto-augmentation, 4 implant augmentation, 3 of reduction mammoplasty and 1 of augmentation mastopexy. Of the twenty patients the overall complication rate was 30% (6 patients). Regarding the rate of complications it was found that, one patients (5%) developed hypertrophic scar that was managed by silicone sheets and fractional CO<sub>2</sub>, one patient (5%) developed post-operative hematoma that was managed with repeated evacuation and dressing, one patient (5%) developed partial loss of areola and she was managed with debridement and healed by secondary intention, one patient (5%) developed post-operative seroma that was managed conservatively and serial follow-up by ultrasound, and lastly one patient (10%) developed wound dehiscence at junction of T shape after wise pattern technique. Most of the previous complications were recorded in non auto-augmentation patients (Table 3). Different techniques were used in breast reshape (Figs. 1-3).

Table (2): Different operative techniques used.

Number	%	Operative techniques
5	25	<ul style="list-style-type: none"> <li>• Augmentation mastopexy with implant</li> <li>• Inferior pedicle. Wise pattern (4)</li> <li>• Superior pedicle (1)</li> </ul>
8	40	<ul style="list-style-type: none"> <li>• Autoaugmentation mastopexy</li> <li>• Dermal suspension-Wise pattern (6)</li> <li>• Lejour technique (2)</li> </ul>
5	25	<ul style="list-style-type: none"> <li>• Reduction mammoplasty</li> <li>• Implant augmentation</li> <li>• Inferior pedicle-wise pattern technique</li> </ul>
2	10	<ul style="list-style-type: none"> <li>• Inframammary approach</li> </ul>

Table (3): Relationship between type of operation and complication rate.

Operation	Complications	
	No	30%
Auto-augmentation mastopexy (N=8)	1	5
Reduction (N=5)	2	10
Augmentation with implant (N=2)	1	5
Augmentation mastopexy with implant (N=5)	2	10



Pre-operative photos of case 1 grade 2, superior medial mastopexy

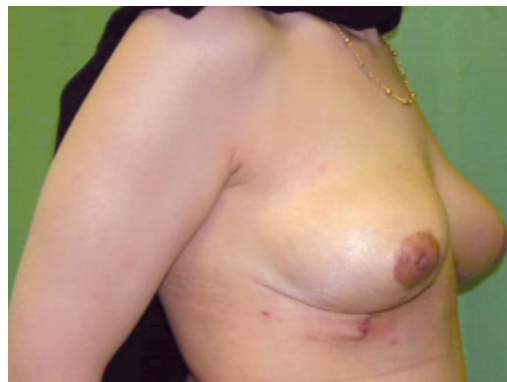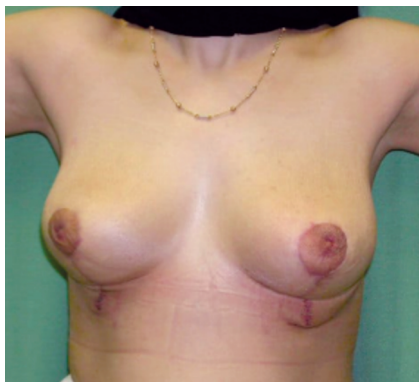
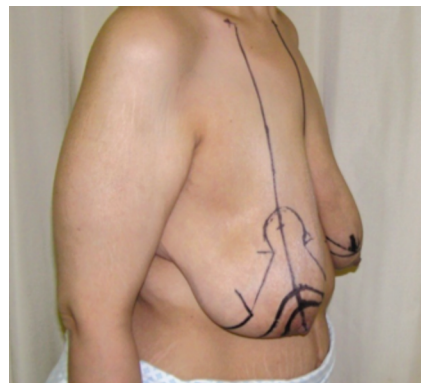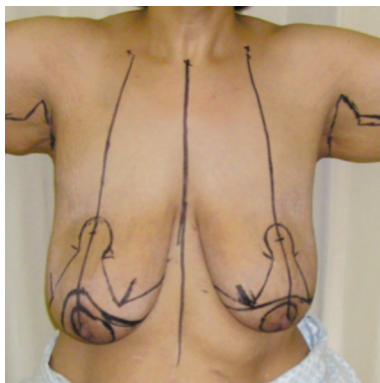


Fig. (1A,B): Post-operative photos of the case, superior medial auto augmentation mastopexy.



Pre-operative photos of case 2 grade 3, auto augmentation mastopexy-wise pattern technique

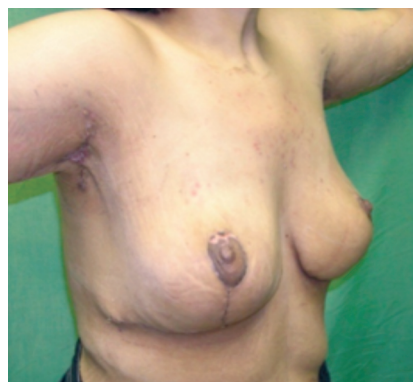
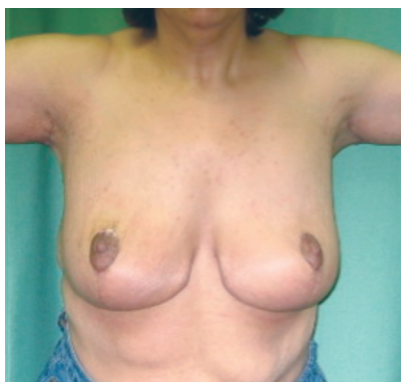
Fig. (2A,B): Post-operative photos of case 2, auto augmentation mastopexy-wise pattern technique.

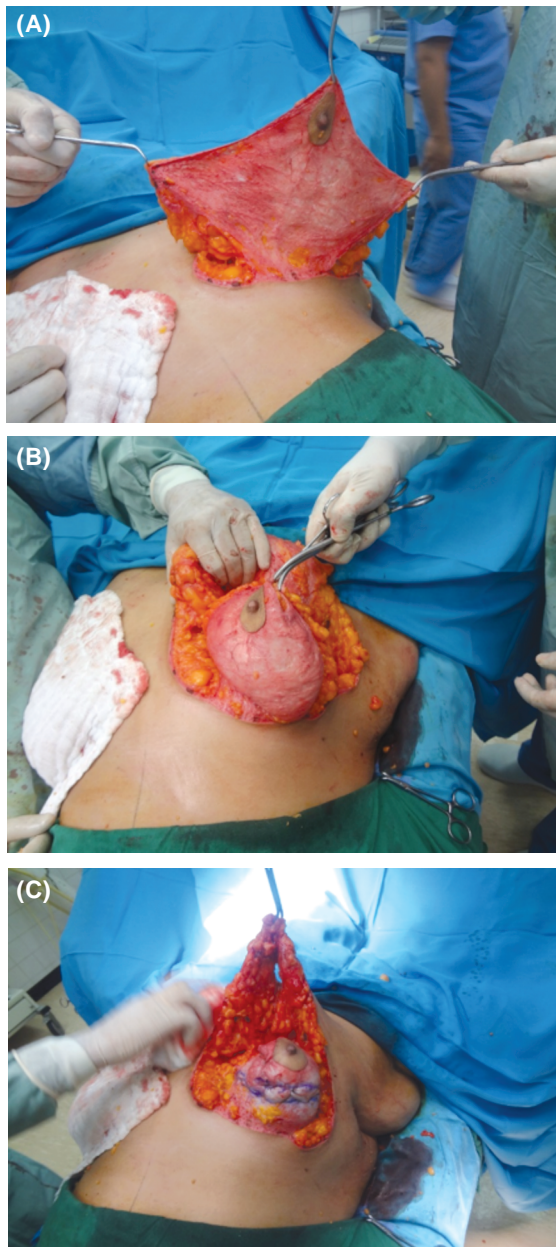


Fig. (3A,B,C): Dermal suspension technique showing. (A) Extended wise pattern technique and (B) Fixation of the pedicle at second rib level and (C) Plication of the pedicle to decrease the line from NAC to IMF.

## DISCUSSION

Breast deformities that develop after massive weight loss are variable depending on the rate of weight reduction, the general health and fitness, the familial and gender-specific fat depositions, the skin elasticity and its relation to underlying fascia, and lastly the muscular status and skeletal form. These changes will affect the breast foot print and breast shape, and the adjacent tissues [10]. Breast reshaping is a great challenge to achieve high satisfaction with little complications.

The evaluation of the degree of skin elasticity was described to be either good versus poor quality. The presence of thin skin, striae, loss of adherence to the breast parenchyma and loss of recoil all indicate poor skin quality [11]. For patients with poor skin, dermal suspension and mastopexy techniques were described by Rubin et al., to ensure the longevity of reshaping procedure [12].

The breast volume insufficient, sufficient or excess volume, the surgeon experience, and the patient opinion and hope, and realistic expectation were the standards in breast reshaping. Insufficient breast volume was treated by augmentation, and sufficient breast volume treated by auto augmentation, and excess volume was managed by reduction mastopexy [9].

Many kinds of literature showed different techniques for post-bariatric breast reshaping. Rubin et al., described dermal suspension mastopexy in management of sufficient volume of ptotic breasts, breast reduction is included when indicated [12], and the result was highly satisfactory as only delayed healing at the triple point which represented 5% and scar revision of unilateral medial inframammary fold. In our study dermal suspension was done in 6 cases and we included minimal excision of excess breast parenchyma to achieve skin closure without tension and extended wise pattern and dermal suspension managed the lateral rolls producing a satisfactory aesthetic outcome and only one case had wound dehiscence from all 6 cases (16.6%). Reviewing our cases, we found that this technique is more safer and can assist in the enhancement of the breast and treatment of lateral rolls and we are agree with this technique.

Different techniques for reduction mastopexy are available, using wise pattern and vertical technique, Hurwitz described the vertical technique and showed its advantages in decreasing breast base and increasing projection, but cannot address the lateral rolls with satisfactory results [13]. Akyurek added liposuction from the lateral chest wall and IMF to define the breast contour and the outcome of his study was very satisfied and no major complications were detected. He showed that vertical breast reduction with superior medial pedicle is a good option with long stable results for post-bariatric patients [14]. In our study, 2 patients underwent breast reduction vertical technique and they had a good projection of the breast and good satisfactory result with no major complications were recorded and we agree with Hurwitz study. We do not recommend liposuction in post bariatric breast except in case of close observation and

monitoring for at least 24 hours post-operative, because this can lead to severe bleeding from hypertrophied blood vessels which became hypertrophied during weight gain and did not decrease in size after weight loss, we disagree with Akyurek study [3].

Insufficient breast tissue requires an implant to fill the deflated breast. Augmentation mastopexy combined with wise pattern technique presented by Bitar using a saline implant which inserted through axillary incision to minimize the rate of infection, the outcome of his study was; hematoma (2%), capsular contracture (4%), high riding implant (2%), implant deflation (<1%), 3% unsatisfied by asymmetry [15]. Spear showed one stage augmentation combined with mastopexy, the implant placed either sub pectoral or dual plane, the outcome of his study was (2.9%) continued ptosis after surgery, (2.9%) grade 2 capsular contracture, (2.9%) grade 3 capsular contracture, (14%) revision surgery. Most of the patients were satisfied with the size and shape of their breast, and few patients were looking for revision to gain more aesthetic outcome [16]. In our study augmentation mastopexy was done in 5 patients. All of them were done using wise pattern incision. Small silicone implant (150-200cc) was used and placed through the same incision of mastopexy in sub glandular pocket to increase the size and protection. Breast contour, projection and size were satisfactory in most of them, 2 patients developed seroma (40%), and we agree with Spear study.

The outcome analysis shows that the complication rate was 30% in the form of seroma which was treated by ultrasound follow-up. The recorded complications were more in patients that have huge pendulous breast that require reduction. Regarding patients' satisfaction, it was found that 70% of them were highly satisfied regarding their size and shape. Most of the more satisfied patients were from the auto augmentation technique followed by patients from pure augmentation and the unsatisfied patients were from those with reduction mammoplasty.

Small silicone implant (150-200cc) can improve breast projection and aesthetic outcomes. We prefer auto augmentation as it gives good lasting results and no complications like implant capsular contracture, implant rupture, double bubble, implant malposition, and Anaplastic Large Cell Lymphoma (ALCL), which increased with texture implant and became risky, and this made some countries as my country advised us not to use that type of implant for safety.

We do not recommend liposuction of any part of breast in post bariatric patients, since the blood vessels become hypertrophied during weight gain and do not decrease in the size like the breast tissue after weight loss which become risky for bleeding during and after operation. We advise to insert drain in post bariatric breast augmentation as the rate of bleeding and hematoma increase than non post bariatric augmentation.

#### *Conclusion:*

Post bariatric breast ptosis and atrophy is a common clinical presentation especially after popularization of bariatric surgery. Aesthetic restoration of shape, contour, and fullness represents a great challenge for plastic surgeons. From different modalities used to address this issue, breast auto augmentation is the summit of these procedures for its safety and long term results.

#### **REFERENCES**

- 1- Pavan C., Azzi M., Lancerotto L., Marini M., Busetto L., Bassetto F. and Vindigni V.: *Obes. Surg.*, 23 (4): 437-45, 2013.
- 2- Coriddi M., Nadeau M., Taghizadeh M. and Taylor A.: *Analysis of satisfaction and well-being following breast reduction using a validated survey instrument: The BREAST-Q. Plastic and Reconstructive Surgery*, 132 (2): 285-90, 2013.
- 3- Migliori F.C., Gabrielli A., Rizzo R. and Serra Cervetti G.G.: *Breast contouring in postbariatric patients: A technique selection algorithm. Obes. Surg.*, 20 (5): 651-6, 2010.
- 4- Coriddi M., Koltz F. and Gusenogg J.A.: *Reduction mammoplasty, obesity, and massive weight loss: Temporal relationships of satisfaction with breast contour. Plast. Reconstr. Surg.*, 128: 643-50, 2011.
- 5- Song A., O. Toole J., Jean R. and Rubin P.: *Classification of contour deformities after massive weight loss: Application of Pittsburgh Rating Scale. Seminars in plastic surgery. Thieme Medical Publishers*, 20: pp. 24-5, 2006.
- 6- Losken A.: *Breast reshaping following massive weight loss: Principles and techniques. Plast. Reconstr. Surg.*, 126 (3): 1075-85, 2010.
- 7- Hamdi M. and Tuncer S.: *Breast surgery in patients after massive weight loss. In Attiyeh BS: Body contouring following bariatric surgery and massive weight loss: Post-bariatric body contouring. Bentham Science Publishers*, p. 102-11, 2012.
- 8- Lázaro Cárdenas-Camarena and Roberto Ramírez-Macías: *Augmentation/Mastopexy: How to Select and Perform the Proper Technique, Aesth. Plast. Surg.*, 30: 21-33, 2006.
- 9- Colwell A.S., Driscoll D. and Breuing K.H.: *Mastopexy techniques after massive weight loss: An algorithmic approach and review of the literature. Ann. Plast. Surg.*, 63 (1): 28-33, 2009.
- 10- Cheng I.C., Wei S.C., Yeh S.L. and Wang W.: *Comparison of weight loss and body composition changes in morbidly*

- obese Taiwanese patients with different bariatric surgeries: A 1-year follow-up study. *Obes. Surg.*, 24: 572-7, 2014.
- 11- Rubin J.P.: Mastopexy in the massive weight loss patient: Dermal suspension and total parenchymal reshaping. *Aesthet. Surg. J.*, 26: 214-22, 2006.
- 12- Rubin P.: Mastopexy after massive weight loss: Dermal suspension and total parenchymal reshaping. *Aesthetic Surgery Journal SAGE*, 26: 214-22, 2006.
- 13- Hurwitz D. and Golla D.: Breast reshaping after massive weight loss. *Seminplasturg.*, 18 (3): 179-87, 2004.
- 14- Akyurek M.: Short scar reduction mammoplasty in the bariatric patients. *Ann. Plas. Surg.*, June, 66: pp. 602-6, 2011.
- 15- Bitar G.: Transaxillary breast augmentation/Wise pattern mastopexy in massive weight loss patients. In: M. Shiffman. *Body contouring art, science, and clinical practice*. Springer, 2 Ch. 70 pp. 709-13, 2010.
- 16- Scott L. Spear, M.D., Christopher V. Pelletiere, M.D. and Nathan Menon, M.D. and Washington D.C.: USA. *One-Stage Augmentation Combined with Mastopexy: Aesthetic Results and Patient Satisfaction*. *Aesth. Plast. Surg.*, 28: 259-67, 2004.