

Maximizing Aesthetic Results of Buttock Augmentation in Post-Bariatric Patients-Dual Approach

ABDEL RAHMAN MOHAMED, M.D.; NIVEEN F. AL-MAHMOUDY, M.D. and EMAN N. MOHAMED, M.D.

The Department of Plastic & Reconstructive Surgery, Faculty of Medicine, Ain Shams University, Cairo, Egypt

ABSTRACT

Background: Post-bariatric patients suffer from laxity of skin and redundancy in different parts of the body, with resultant unaesthetic appearance. Concerning the lower body, different surgeons have introduced lower body lift and buttock augmentation and have discussed different approaches and techniques. In this study, we compare between buttock auto-augmentation with fat injection and buttock auto-augmentation with gluteal implant application as regards the maximum aesthetic outcome in post-bariatric patients.

Patients and Methods: 26 post-bariatric patients with redundancy of the skin of the abdomen and buttocks. All patients had belt lipectomy/abdominoplasty and buttock augmentation (auto-augmentation) in addition to fat injection (Group A, 15 cases), or application of intramuscular gluteal implants (Group B, 11 cases).

Results: All patients had follow-up for one year with no major complications. The *p*-value was calculated for both groups and was found that there is a highly significant statistical difference in the post-operative measurements in Group A (fat injection).

Conclusion: Dual autoaugmentation for post bariatric ptotic buttocks give more appealing results for patients, either objectively by measurements or subjectively by high satisfaction scores with a higher preference for fat injection.

Keywords: *Buttock augmentation – Post-bariatric – Fat injection in buttocks.*

INTRODUCTION

In 1966, bariatric surgery evolved and offered a great degree of weight loss in a short time in the morbidly obese candidates, and since then, post-bariatric plastic surgery has officially arrived in the world [1].

Contouring procedures after bariatric surgery have grown in frequency as announced by the American Society of Plastic Surgeons. According to the statistics, there were 52,000 body-contouring procedures performed in post-bariatric weight loss patients in 2003 and raised by 36% in 2004 [2].

After 50% weight loss, patients will have loose, ptotic skin envelopes, and protruding bulges, and creases will be present instead of the previously large amount of adipose tissue, and smooth contours. These deformities commonly have bad aesthetic and psychological impacts on the patients [3].

Changes in gluteal anatomy after massive weight loss is observed as excess skin and fat in the area between the iliac crest and the perceived superior gluteal margin defined by the superior extent of the origin of the gluteal muscles and also in the region between the L5 dimple and central crease. Also, there is drooping of the central crease and inferior gluteal crease. In addition, the excess of skin and fat is more prominent in the lateral compared with medial quadrants of the buttocks [4].

The belt-lipectomy removes only sagged skin and tissues of the abdomen as well as lower back and gluteal region; however, this procedure alone fails to satisfy the patient as the deficient projection and buttock definition will be missed. Previous studies reported that belt-lipectomy when combined with autologous augmentation alone; give suboptimal results [5].

In the current study, we aim to assess the aesthetic results of buttock augmentation by dual method; auto-augmentation with fat injection in comparison to buttock auto-augmentation with gluteal implant application as regards the maximum aesthetic outcome in post-bariatric patients, both subjectively and objectively.

PATIENTS AND METHODS

Twenty-six patients requiring lower body-contouring procedures after massive weight loss had increased skin laxity, decreased adiposity were

divided in two groups; (Group A) 15 patients underwent buttock auto-augmentation combined with fat injection & belt-lipectomy/abdominoplasty, (Group B) 11 patients underwent buttock auto-augmentation combined with prosthetic silicone implant application, also with belt-lipectomy/abdominoplasty. The study was conducted in the Plastic Surgery Department, Ain Shams University Hospitals in the period between February 2016 and February 2019. The study was controlled by the following selection criteria: Age (18-40 years old), sex (female), body mass index following bariatric surgery ($25-35\text{kg/m}^2$); and all patients had a constant weight over the prior 6 months, any co-morbid conditions were recorded as diabetes, hypertension, and/or smoking.

Pre-operative distance between the iliac crest and apparent superior gluteal margin and distance between the L5 dimple and the central crease were measured, recorded and compared with 6 months post-operative distance.

Pre-operative markings:

The patients were marked pre-operative in both the standing and supine positions. The patients' backs were marked on the lateral side by drawing a vertical line through the middle of the armpit; next a vertical spinal line was drawn dorsally, the L5 dimple was identified (point A) and a point B 5cm inferior to the dimple was marked serving as the low point of the V in the upper transverse incision, the Posterior Superior Iliac Spine (PSIS) was marked (point C), the incision courses from point B just one finger breadth above point C and continues laterally approximately one finger breadth above the upper margin of the gluteus maximus till reach mid axillary line. The lower incision was determined by pinching the skin after 30 degrees of trunk flexion Fig. (1).

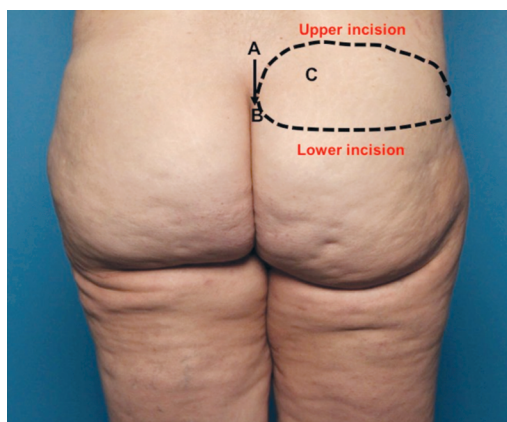


Fig. (1): Pre-operative marking where point A represents L5 dimple, point B represents 5cm inferior to the dimple, point C represents PSIS

Operative technique:

Surgery was performed under general anesthesia. Antibiotic prophylaxis of 2gm ceftriaxone a day before surgery was administered, with a further 2gm given later during surgery. All patients took a shower using betadine shampoo one hour before surgery. Two wide bore intravenous cannulas were inserted in the arms.

The procedure started after full anesthesia of the patient then sterilization and tueling took place with insertion of the urinary catheter, infiltration with an adrenaline solution in saline (1:500000) of planned lipodystrophy areas was done to reduce bleeding during surgery and to facilitate liposuction.

In all cases, the procedure started with the patient in the prone position. Liposuction of the back performed primarily; all fat was removed between the dermis and the muscular fascia using a 4-mm-diameter cannula. The fat harvested was used for buttock augmentation in (Group A). Skin excisions were checked peri-operatively by pinching. Next, the incision was done and de-epithelialization was performed.

In (Group A), dermofat flap was created after de-epithelialization of the marked flap, then; the lower edge of the flap was incised and dissected to raise the redundant lower flap. After closure of the fascia and subcutaneous tissue, assessment of the projection of the buttock and overall shape were done to determine the areas that need fat injection. Fat injection was done in multiple layers in subcutaneous tissue never perpendicular or intramuscular to avoid fat embolism. The wound closure was done in a tension-free manner over the created flap.

In (Group B), dermofat flap was created as before after de-epithelialization, but with exposure of gluteal maximus and its fascia, then incision in fascia and muscle fiber was done in the same direction of the muscle fibers and intramuscular plane was created for gluteal biconvex shape silicone implant (400-450cc) application. After that, wound closure was done in a tension-free manner over the flap and prosthesis.

Closure is done using absorbable vicryl (0) for the fascia and subcutaneous tissue, Monocryl 2/0 stitches was used for skin closure, then reassessment of the projection of the buttock and overall shape were done.

After that, the patient turned to the supine position in order to perform abdominoplasty and re-sterilization of the patient was done. Whereas in cases of belt lipectomy in combination with buttock augmentation in either group, we started in the supine position and ended with the prone position. Finally, sterile dressings were applied for all patients' wounds and they wore pressure garments over the dressings.

Post-operative care:

All patients wore compression stockings to prevent phlebitis, low-molecular weight heparin (Clexane 20 units) was given to all patients post-surgery. Broad spectrum antibiotics (Ceftriaxone 1gm for 12 hours), with systemic analgesia using Patient Controlled Analgesia as well as antiemetics and antigastric medications were taken. Dressings were changed every other day. Patients were given instructions of early ambulation on the day of the surgery and the urinary catheter was removed the next day.

RESULTS

Twenty-six post-bariatric surgery female patients, age from (23-44 years) underwent belt lipectomy/abdominoplasty after massive weight loss; There was a decrease in the distance between the iliac crest and perceived superior gluteal margin, a decrease in the distance between the L5 dimple and the central crease, with lifting of the central crease, and a relative increase in the buttock projection compared with pre-operative distance in both groups Figs. (2,3). All measurements were taken and statistically analyzed. The *p*-value was calculated for both groups and was found that there is a highly significant statistical difference in the post-operative measurements in Group A.

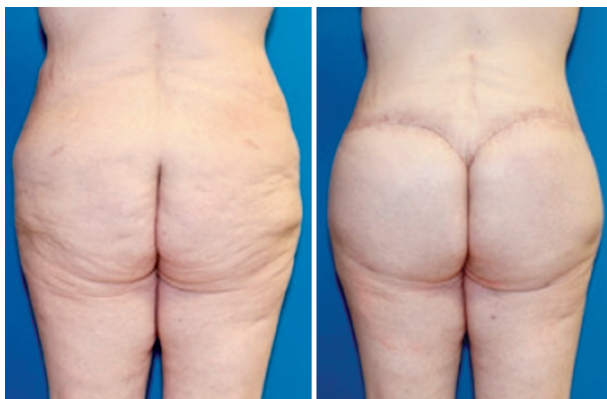

Fig. (2): Pre-and post-operative (after 6 months) for a patient in Group A.

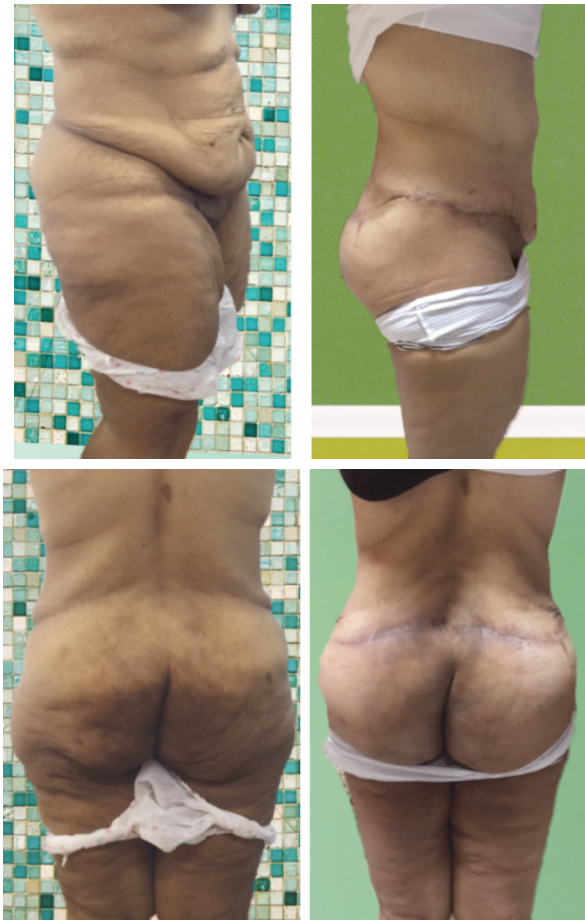

Fig. (3): (Upper) lateral view (Lower) front view pre-operative and post-operative (after 6 months) for a patient in Group B.

All patients had been followed-up for one year with no major complications (i.e., hematoma, thromboembolism, bleeding and skin necrosis). The aesthetic results were considered satisfactory in all cases with variable scores, of all 26 patients, 8 cases experienced at least one complication.

Minor complications included wound dehiscence (2 cases in Group A, 3 cases in Group B) treated by frequent dressing and healing with secondary intention. Only 2 patients recurred to perform scar revision operation for aesthetic purposes (one case in each group). One patient suffered from fat resorption in Group A after 3 months need for reinjection. Patients' data are illustrated in (Table 1) (Group A) and (Table 2) (Group B).

In (Group A) patients, the overall shape of the gluteal augmentation was more natural in appearance with a very good projection, compared to patients of (group B), Those patients with silicone augmentation have good augmentation and projection but they had aberrant overall shape and unnatural appearance as prosthesis boundaries are sometimes visible with an unnatural appearance.

Table (1): Patients data for (Group A): Patients underwent belt-lipectomy/abdominoplasty procedure with auto-augmentation combined with fat injection of the buttock.

No	Age year	BMI kg/m ²	Co-morbid conditions	Operative time minutes	Measurement (distance)				Amount of fat injected (cc)	Complications
					Pre-operative		6 months post-operative			
					Iliac creast - superior gluteal margin	L5 dimple - central crease	Iliac creast - superior gluteal margin	L5 dimple - central crease		
1	23	30	–	420	11	6.7	7	5.2	600	–
2	44	29	–	380	10.6	6.9	7.2	5	800	–
3	35	33	DM	400	10.5	7	6.9	5.1	400	
4	26	26	–	390	11.3	7.2	7.1	5.4	400	–
5	39	28	DM	350	11.5	6.9	6.8	5.2	500	
6	25	32	HTN	390	11	7.4	6.8	5.1	660	–
7	42	31	DM	350	11.6	7.3	7	5.5	440	Scar revision
8	44	30	–	320	11.3	7	7.2	5.3	400	–
9	36	32	Smoker	320	11.6	7.7	7.4	5	500	Wound dehiscence, fat resorption
10	40	33	–	350	11	6.9	7.1	5	600	–
11	27	30	Smoker	320	10.9	7	7.5	5.2	500	Wound dehiscence
12	24	29	–	330	10.8	7.8	6.9	5	400	–
13	35	28	HTN	320	11.5	7	7.1	5.1	700	–
14	38	28	–	350	11	7.3	7.2	5.2	400	–
15	41	30	–	320	11.5	7.4	7	5.5	500	–

Table (2): Patients data for (Group B): Patients underwent belt-lipectomy/abdominoplasty with auto-augmentation combined with prosthetic silicone implant.

No	Age year	BMI kg/m ²	Co-morbid conditions	Operative time minutes	Measurement (distance)				Size of the implant (cc)	Complications
					Pre-operative		6 months post-operative			
					Iliac creast - superior gluteal margin	L5 dimple - central crease	Iliac creast - superior gluteal margin	L5 dimple - central crease		
1	40	30	–	400	11	7	6.8	5.1	450	–
2	35	28	HTN	320	10.9	7.8	7	5.5	450	Wound dehiscence
3	38	28	–	350	10.8	7	7.2	5.3	450	–
4	41	30	–	320	11.5	7.3	7.4	5	400	Scar revision
5	34	29	–	380	11	7	7.1	5	400	–
6	33	33	DM	400	11.5	7.8	7.5	5.2	400	Wound dehiscence
7	23	26	–	390	11	7	6.9	5	450	–
8	44	28	DM	350	10.7	7.3	7.1	5.1	450	Wound dehiscence
9	35	32	HTN	390	11.7	7.4	7.2	5.2	400	–
10	26	31	DM	350	11.5	7.3	6.8	5.1	400	–
11	39	30	–	320	11.4	7	7	5.3	450	–

The overall patient satisfaction score 6 in Group A was 11 patients (excellent), 2 patients (good), 1 patient (satisfactory) and 1 patient (poor). Whereas, overall patient satisfaction score in Group B was 8 patients (excellent), 2 patients (good), and 1 patient (satisfactory).

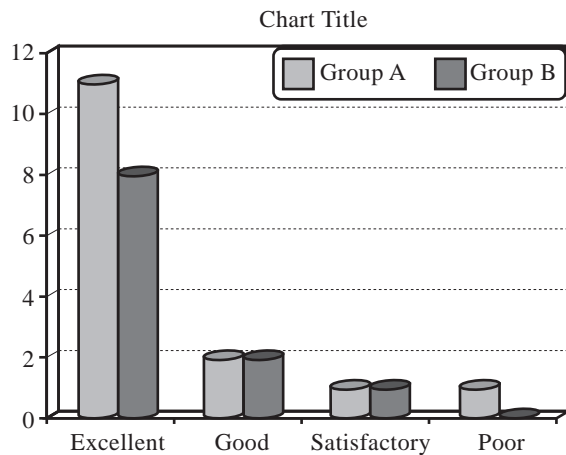


Fig. (4): Patient satisfaction score in Groups A and B.

DISCUSSION

The goal of plastic surgical management after massive weight loss is to optimize the functional outcomes that are possible by means of surgical removal of redundant skin folds, which may negatively impact both the quality of life and physical function [7,8].

Attractive buttocks should include adequate volume, projection, and a defined infra-gluteal fold. The gluteal region in patients with massive weight loss is characterized by excessive skin and exaggerated fat loss. Lower body lift procedures remove excess skin and lift sagging buttock tissue, but they typically result in further gluteal flattening [4].

Gluteal augmentation techniques fall into three main categories: Autologous flaps, large-volume fat injections and implants. Autoaugmentation procedures using autologous skin and fat from the region of the lower body lift have previously been described for gluteal augmentation. Pascal et al., described a technique where tissue flaps were designed within the lower body lift incisions but not mobilized; rather, the inferior gluteal tissue is mobilized and brought over the stationary flaps [9]. Young and Centeno used a similar technique but with release of the muscle fascia superior and lateral to the flap to allow more downward mobility [10]. Others use superior gluteal artery perforator flap as a mean of autoaugmentation [4].

In current study, we thought that the most practical means of augmenting the gluteal region is to use tissue that would otherwise be discarded.

Large-volume fat injections are used as a mean of autoaugmentation, collect autologous fat from areas of excess are collected and redistributed in the area with a relative deficiency [11]. However, Complications as seroma and abscess may occur, and moreover there are published reports about fatal and non-fatal pulmonary fat embolism resulting from this procedure. So, fat injection into deep muscle and pointing downwards during intramuscular fat injection should be avoided to avoid pulmonary fat embolism [12].

Murillo reported excellent take of large-volume fat injections for buttock augmentation, with only 20 percent loss in patients followed for one year [13], however further long-term studies are needed to confirm fat resorption rates.

In this study, fat injection was used for autoaugmentation with autologous de-epithelialized flap in Group A, (400-800cc) of fat was used harvested from back and area of excess, injected in multiple layers to increase buttock projection. None of patient had seroma or abscess formation with one case showed fat resorption after 3 months and fat was injected again after 2 months.

Gonzalez described intramuscular placement of gluteal implants [14]. Although implant insertion in any plane increases volume and projection, it also introduces a foreign body into the buttocks, and a technical learning curve exists for proper placement.

In our study, intramuscular silicone implant was used together with the de-epithelialized flap for more buttock shape definition. None of the patients had any complication related to implant, rather than wound dehiscence in 3 cases due to poor healing of the patients.

A study was made to determine the satisfaction between autoaugmented buttock and non-augmented one and it showed no statistical significance between the two groups [15]. So in the current study, the dual method of augmentation was proposed for more definition and projection of buttocks, and the patients were satisfied in both groups with higher preference (satisfaction score) in Group A.

Conclusion:

Dual autoaugmentation for post bariatric ptotic buttocks give more appealing results for patients,

either objectively by measurements or subjectively by high satisfaction scores with a higher preference for fat injection.

REFERENCES

- 1- Song A.Y., Jean R.D., Hurwitz D.J., Fernstrom M.H., Scott J.A. and Rubin J.P.: A Classification of Contour Deformities after Bariatric Weight Loss: The Pittsburgh Rating Scale, 116: 1535-44, 2005.
- 2- Song A.Y., Rubin J.P., Thomas V., Dudas J.R., Marra K.G. and Fernstrom M.H.: Body Image and Quality of Life in Post Massive Weight Loss Body Contouring Patients, 14: 1626-36, 2006.
- 3- Giordano S., Victorzon M., Koskivuo I. and Suominen E.: Physical discomfort due to redundant skin in post-bariatric surgery patients. *J. Journal of Plastic, Reconstructive Aesthetic Surgery*, 66: 950-5, 2013.
- 4- Amy S.C. and Loren J.B.: Autologous Gluteal Augmentation after Massive Weight Loss: Aesthetic Analysis and Role of the Superior Gluteal Artery Perforator Flap, *Plast. Reconstr. Surg.*, 119: 345-56, 2007.
- 5- Shiffman M.A. and Di Giuseppe A.: *Body contouring: art, science, and clinical practice*: Springer Science & Business Media, 2010.
- 6- Strasser E.: An objective grading system for the evaluation of cosmetic surgical result *plast. reconstr. surg.*, 104 (7): 2282-5, 1999.
- 7- Chandawarkar R.Y.: Body contouring following massive weight loss resulting from bariatric surgery. *Adv. Psychosom. Med.*, 27: 61-72, 2006.
- 8- Zuelzer H.B. and Baugh N.G.: Bariatric and body-contouring surgery: A continuum of care for excess and lax skin. *Plast. Surg. Nurs.*, 27: 3-13, 2007.
- 9- Pascal J.F. and Le Louarn C.: Remodeling body lift with high lateral tension. *Aesthetic Plast. Surg.*, 26: 223, 2002.
- 10- Young V.L. and Centeno R.F.: Marking and operative technique. *Plast. Reconstr. Surg.*, 117 (1 Suppl.): 50S, 2006.
- 11- Baran C.N., Celebioglu S., Sensoz O., Ulusoy G., Civelek B. and Ortak T.: The behavior of fat graft in recipient areas with enhanced vascularity. *Plast. Reconstr. Surg.*, 109: 1646, 2002.
- 12- M. Mark Mofid, Daniel Suissa, Denis C. and Constantino Mandieta: Report on mortality from gluteal fat grafting, recommendation from the ASERF Task Force. In: *Aesthetic surgery Journal*, 37 (7): 796-806, 2017.
- 13- Murillo W.L.: Buttock augmentation: Case studies of fat injection monitored by magnetic resonance imaging. *Plast. Reconstr. Surg.*, 114: 1606, 2004.
- 14- Gonzalez R.: Augmentation gluteoplasty: The XYZ method. *Aesthetic Plast. Surg.*, 28: 417, 2004.
- 15- Udayan Srivastava, Peter Rubin and Jeffrey A.G.: Lower Body Lift after Massive Weight Loss: Autoaugmentation versus No Augmentation *Plast. Reconstr. Surg.*, 135 (3): 762-72, 2015.