

**Original Article**

# Effect of adjunctive systemic vitamin E on clinical parameters and salivary total antioxidant capacity in symptomatic oral lichen planus patients: Randomized controlled clinical trial

Engy Abdel Dayem <sup>1</sup>, Wessam Abd Elmoneim Mohamad <sup>1</sup>, Olfat Gamil Shaker <sup>2</sup>, Shereen Ali <sup>1</sup>

<sup>1</sup> Oral Medicine and Periodontology Department, Faculty of Dentistry, Cairo University, Cairo, Egypt

<sup>2</sup> Department of Biochemistry, Faculty of Medicine, Cairo University, Cairo, Egypt

Email: engyabdeldayem@hotmail.com

## Abstract

**Background:** Most of the available therapeutics of oral lichen planus are associated with adverse effects and there is no sufficient evidence to support the effectiveness of these modalities over placebo or over each other. Micronutrients including antioxidants modify the immune system function and are considered promising alternatives in management of OLP with negligible side effects. The current trial assessed the effect of adjunctive use of systemic vitamin E in symptomatic oral lichen planus patients.

**Methods:** This randomized controlled clinical trial includes 30 symptomatic (erosive and atrophic ) oral lichen planus patients in two parallel groups (intervention – topical triamcinolone acetonide adhesive paste and vitamin E, control - topical triamcinolone acetonide adhesive paste and placebo), with allocation ratio 1:1. Outcome measures were pain intensity, clinical improvement and salivary level of total antioxidant capacity.

**Results:** Mean amount of pain reduction and clinical improvement were greater in the experimental group with statistically significant difference. Mean amount of total antioxidant capacity upregulation was greater in the control group with no statistical difference.

**Conclusion:** Adjunctive use of systemic vitamin E has shown promising results in management of OLP with no side effects.

**Key words:** Vitamin E, Oral lichen planus, salivary total antioxidant capacity, Randomized-controlled clinical trial

## Introduction

Oral lichen planus (OLP) is one of the most common lesions affecting patients referred to Oral Medicine

specialists. There is consensus on the fundamental role of the immune deregulation in the pathogenesis of OLP, specifically the cellular arm with Th1/Th2 imbalance assisted by a complex cytokine network.<sup>1</sup>

<sup>2</sup> Data obtained from salivary and tissue markers confirm the involvement of oxidative stress in OLP pathogenesis.<sup>3-7</sup>

Although there are many proposed treatment modalities including corticosteroids, retinoids, calcineurin inhibitors, laser, and phototherapy; a permanent cure is not yet available. Corticosteroids are the mainstay and other therapies are required in recalcitrant OLP or contraindication to corticosteroids. Most of the therapeutic modalities are associated with adverse effects; some of them are serious, which limits their use.<sup>1, 8, 9</sup>

Systematic reviews have documented that the evidence is insufficient to support the effectiveness of the available modalities over placebo or superiority of any modality over the other even on comparing two corticosteroids.<sup>10-13</sup>

Nutritional immunity is an interesting growing concept. Micronutrients are thought to modify the immune system function where deficiency of micronutrients impair the function of immune cells and micronutrients repletion reverse this impairment.<sup>14</sup>

Researchers are considering micronutrients as promising alternatives in management of OLP being natural products with negligible adverse effects compared to other medications.<sup>15, 16</sup>

Vitamin E is a fat-soluble vitamin with a well-known antioxidant properties. Vitamin E is a free radical scavenger that inhibits lipid peroxidation and protects cell membranes from the free radical attacks, thus maintain the cell membrane integrity. Vitamin E is one of the constituents of all cell membranes and it is present with high levels in immune cells.<sup>17, 18</sup>

Other properties of vitamin E are being more elucidated. It can regulate cellular responses such as cell signaling, gene expression, immune response

including cell functions and inflammatory mediators' production, cell cycle and apoptosis.<sup>19</sup>

Vitamin E reduces migration of dendritic cells and interleukin (IL)-12 secretion; inhibits cyclooxygenase (Cox)-2 activity and prostaglandin E2 (PGE2) production and modulates TH1/TH2 balance.<sup>20</sup>

Vitamin E modulates T-cell function directly by maintaining cell membrane integrity and regulating signal transduction; indirectly through its regulatory effect on pro-inflammatory cytokines, it reduces production of tumor necrosis factor (TNF)- $\alpha$ , IL-6 and IL-1 $\beta$ .<sup>19</sup>

The current trial was conducted to evaluate the effect of adjunctive use of systemic vitamin E on clinical parameters and salivary total antioxidant capacity in symptomatic (erosive and atrophic) oral lichen planus patients.

## Materials and Methods

### Study design and Participants:

The current study is a randomized controlled clinical trial that includes 30 symptomatic OLP patients in two parallel groups (intervention – topical triamcinolone acetonide adhesive paste and Vitamin E capsule, control - topical triamcinolone acetonide adhesive paste and placebo capsule), with allocation ratio 1:1. The current trial was conducted in Faculty of Dentistry - Cairo University, participants were recruited from the pool of the Diagnostic center and the Out-Patient Clinic of Oral Medicine and Periodontology Department. This clinical trial followed the principles of the Helsinki Declaration and was approved by the Research ethics committee of Faculty of Dentistry, Cairo University (Code: 15733). Each participant was informed about the details of the study and signed a written consent.

Erosive and atrophic OLP patients who agreed to take supplied medications were included. Reticular OLP patients; erosive and atrophic OLP patients

receiving any systemic treatment such as systemic steroids, other immunosuppressive drugs or non-steroidal anti-inflammatory drugs during the eight weeks prior to the study; erosive and atrophic OLP patients receiving any oral topical medications for during the four weeks prior to the study; patients suffering from systemic disease; or pregnant and lactating ladies were excluded.

### **Interventions:**

The intervention was 0.1% triamcinolone acetonide adhesive paste (Kenacort A Orabase – Dermapharm) and 400 mg Vitamin E capsule (Vitamin E 400 - Pharopharmaceuticles) for the experimental group and 0.1% triamcinolone acetonide adhesive paste (Kenacort A Orabase – Dermapharm) and identical placebo capsule for the control group.

Patients were instructed to apply triamcinolone acetonide regularly four times a day after meals and before sleeping for four weeks and to refrain from eating and drinking for 30 minutes after the application. In addition, patients were asked to take one capsule (Vitamin E or placebo) once daily at morning.

### **Outcomes:**

Pain intensity was evaluated using numerical rating scale (NRS) at baseline, daily during the first week, then weekly for four weeks. NRS ranges from 0 to 10, with 0 indicating “no pain” and 10 indicating “pain as bad as you can imagine”.<sup>21</sup>

(NRS) was used as Chronic pain patients prefer the NRS over other measures of pain intensity, including the pain VAS, due to comprehensibility and ease of completion.<sup>31</sup>

Clinical improvement of the oral lesions was scored using Thongprasom et al. scale at baseline and weekly for four weeks. In Thongprasom et al. scale, lesions are given score as follows: 0, no lesions, normal mucosa; 1, Mild white striae, no erythematous area; 2, White striae with atrophic area < 1 cm<sup>2</sup>; 3, White striae with atrophic area > 1 cm<sup>2</sup>;

4, White striae with erosive area < 1 cm<sup>2</sup> and 5, White striae with erosive area > 1 cm<sup>2</sup>.<sup>22</sup>

Salivary level of TAC (total antioxidant capacity) was evaluated using ELISA kit. Unstimulated whole saliva samples were used for determination of TAC using ImAnOx (TAS/TAC) Kit provided by Immun Diagnostik, Germany. Participants were asked to refrain from eating, drinking or using saliva stimulators for one hour before sample collection. Participants were asked to swallow, then tilt their head forward and expectorate saliva into a centrifuge tubes for 5 minutes without swallowing. The saliva samples were frozen at -70°C, until analysis. The saliva samples were centrifuged at 4500 g for 15 minutes.

### **Randomization and Blinding:**

The eligible OLP patients were randomly divided into two parallel groups with 1:1 allocation ratio using random.org. The sequence generation was created then concealed using numbered, opaque, sealed envelopes by (MZ), associate lecturer of Oral Medicine and Periodontology, Faculty of Dentistry, Cairo University who is not an investigator in the study. The sealed envelopes were opened after completing all baseline assessments, when it was time to allocate the intervention.

Investigator (SA) assigned the interventions, while investigator (IA) assessed the outcome measures. The investigators, the assessor and the patients were blinded to the allocation and were kept blinded throughout the trial by supplying Vitamin E and placebo capsules in identical containers labeled either A or B with the key handled by an independent pharmacist.

### **Statistical analysis:**

Data were explored for normality using Kolmogorov-Smirnov and Shapiro-Wilk tests. For parametric data, Independent sample t-test was used to compare between two groups in non-related samples. Paired sample t-test was used to compare between two groups in related samples. For non-

parametric data, Friedman was used to compare between more than two groups in related samples. Wilcoxon was used to compare between two groups in related samples. Mann Whitney was used to compare between two groups in non-related samples. The significance level was set at  $P \leq 0.05$ . Statistical analysis was performed with IBM® SPSS® Statistics Version 20 for Windows.

### Results

Fifty-two OLP patients were assessed for eligibility in this study. Fourteen patients were not eligible, and eight patients refused to participate in the study. The thirty eligible patients were allocated into two groups with 1:1 allocation ratio. None of the included patients discontinued the treatment or dropped off during the follow up periods. The collected data of all the participants were analyzed for statistical significance without exclusion (Figure 1).

Baseline demographic and clinical characteristics for the two studied groups are revealed in table 1. The mean pain score was relatively higher in the experimental group with no statistically significant difference. There were no significant differences among the two groups concerning the remaining demographic and clinical characteristics at baseline.

Both groups showed a statistically significant pain reduction during the first week and through the weekly visits, the differences between the two groups were not significant at any time-point (Table 2 and 3). Mean amount of pain reduction was greater in the experimental group in comparison with the control group with statistically significant difference (Table 4).

The two groups showed a statistically significant clinical improvement of the oral mucosal lesions

through the weekly visits, the differences between the two groups were not significant at any visit (Table 3). Mean amount of clinical improvement was greater in the experimental group compared to the control group with statistically significant difference (Table 4).

Both groups showed a statistically significant upregulation of the salivary TAC level, the differences between the two groups were not significant (Table 5). Mean amount of upregulation was greater in the control group in comparison with the experimental group with no statistical difference (Table 4).

No adverse effects were reported by patients in both groups.

### Discussion

Many hypotheses had been raised to explain the role of oxidative stress in OLP pathogenesis. Researchers believe that oxidative stress influence molecules and pathways implicated in recruitment of lymphocytic infiltrate in OLP lesions and induction of apoptosis including ICAM-1, p53, TNF- $\alpha$ , NF- $\kappa$ B, the Fas/FasL pathway and granzyme B-perforin system.<sup>3, 4, 23, 24</sup> Others believe that the inflammatory processes of OLP activate T-cells to release reactive oxygen species (ROS) by itself or by stimulating keratinocytes to increase ROS production, which cause damage to adjacent cells.<sup>5, 6</sup>

Accordingly, antioxidant defenses were introduced as a part of OLP treatment strategy. Retinoids, lycopene, curcumin, purslane and aloe vera have been previously assessed for management of OLP with different outcomes.<sup>15, 16</sup>

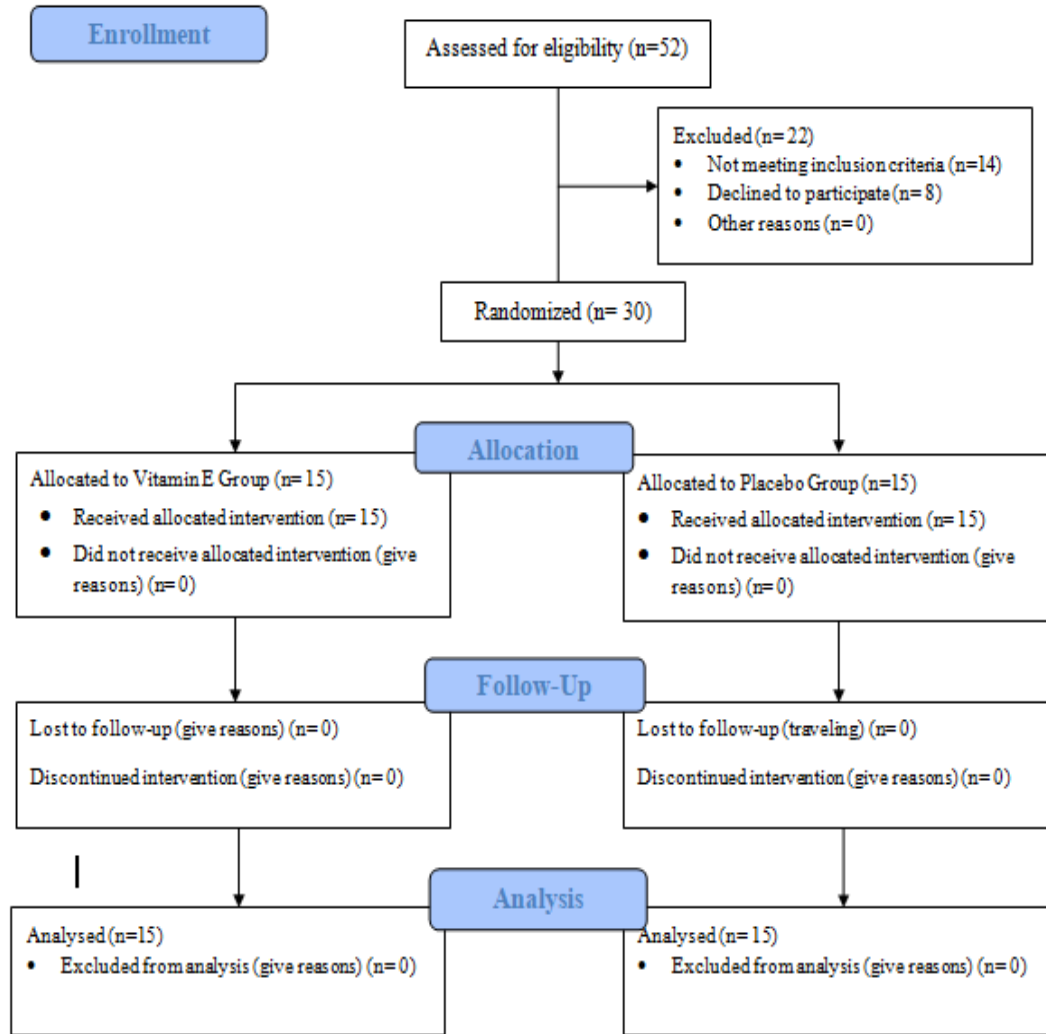


Figure 1: CONSORT Flow Diagram

Table 1: Baseline data of the studied groups

	Placebo group (n= 15)	Vitamin E group (n= 15)	P value
Age (mean ± SD)	50.82 ± 13.61	54.23 ± 12.79	0.527
Gender (F:M)	10:5	11:4	
Erosive OLP (n)	7	6	
Atrophic OLP (n)	8	9	
Salivary TAC	0.44 ± 0.1	0.48 ± 0.09	0.738
Pain (mean ± SD)	6.82 ± 1.78	8.08 ± 1.80	0.083
Clinical improvement (mean ± SD)	4.00 ± 0.45	4.15 ± 0.55	0.444

Table 2: Comparison of daily pain scores.

	<b>Placebo group (n= 15)</b>	<b>Vitamin E group (n= 15)</b>	<b>P value</b>
<b>Baseline</b>	6.82 ± 1.78	8.08 ± 1.8	0.094
<b>Day 1</b>	6 ± 1.18	6.54 ± 2.22	0.557
<b>Day 2</b>	5.82 ± 1.33	6.23 ± 2.13	0.86
<b>Day 3</b>	5.55 ± 1.63	6.08 ± 2.14	0.725
<b>Day 4</b>	5.36 ± 1.57	5.69 ± 2.14	0.883
<b>Day 5</b>	5.36 ± 1.57	5.62 ± 2.10	0.997
<b>Day 6</b>	5.2 ± 1.4	5.54 ± 2.03	0.999
<b>Day 7</b>	4.91 ± 1.64	5.69 ± 2.21	0.68
<b>P value</b>	< 0.001*	< 0.001*	

Table 3: Comparison of weekly pain and clinical improvement scores

	<b>Pain</b>			<b>Clinical improvement</b>		
	<b>Placebo group (n= 15)</b>	<b>Vitamin E group (n= 15)</b>	<b>P value</b>	<b>Placebo group (n= 15)</b>	<b>Vitamin E group (n= 15)</b>	<b>P value</b>
<b>Baseline</b>	6.82 ± 1.78	8.08 ± 1.8	0.094	4 ± 0.45	4.15 ± 0.55	0.444
<b>Week 1</b>	4.91 ± 1.64	5.69 ± 2.21	0.68	3.73 ± 0.65	3.69 ± 0.48	0.973
<b>Week 2</b>	4.45 ± 1.51	5.15 ± 2.03	0.497	3.18 ± 0.75	3.08 ± 0.64	0.676
<b>Week 3</b>	3.27 ± 1.68	4.15 ± 2.08	0.445	3 ± 0.63	2.62 ± 0.51	0.128
<b>Week 4</b>	4.36 ± 2.11	2.69 ± 2.02	0.069	2.64 ± 0.5	2.31 ± 0.48	0.115
<b>P value</b>	< 0.001*	< 0.001*		< 0.001*	< 0.001*	

Table 4: Comparison of change in pain intensity, clinical improvement scores and salivary

	<b>Placebo group (n= 15)</b>	<b>Vitamin E group (n= 15)</b>	<b>P value</b>
<b>Pain</b>	2.45 ± 2.9	5.38 ± 2.39	0.005*
<b>Clinical improvement</b>	1.36 ± 0.5	1.85 ± 0.68	0.032*
<b>Salivary TAC</b>	0.75 ± 0.36	0.69 ± 0.21	0.58

Table 5: Comparison of salivary TAC level

	<b>Salivary TAC</b>		<b>P value</b>
	<b>Placebo group (n= 15)</b>	<b>Vitamin E group (n= 15)</b>	
<b>Baseline</b>	0.44 ± 0.1	0.48 ± 0.09	0.49
<b>Week 4</b>	1.19 ± 0.47	1.16 ± 0.31	0.91
<b>P value</b>	0.01*	0.003*	

Another potent antioxidant is Vitamin E. Other functions of Vitamin E include its ability to modulate immune system function, prevent inflammation and inhibit cancer cell growth/differentiation.<sup>18, 19</sup> Observational studies assessed the serum and salivary level of Vitamin E in OLP. Salivary level of Vitamin E was lower in OLP patients compared to healthy controls.<sup>23, 26</sup> Moreover, serum level of Vitamin E was lower in erosive/atrophic OLP compared to reticular OLP.<sup>27</sup>

Previous studies assessing the role of topical Vitamin E in management of OLP are case reports and case series<sup>28, 29</sup> with one recent randomized cross-over clinical trial assessing the role of topical Vitamin E as main treatment modality compared to placebo in reticular OLP.<sup>25</sup>

As far as we know, the present study is the first parallel randomized clinical trial to assess the role of adjunctive systemic Vitamin E in management of symptomatic (erosive and atrophic) OLP.

In the current trial, both groups showed a statistically significant pain reduction and clinical improvement, the amount of pain reduction and clinical improvement was more prominent in the experimental group than the control group.

Petruzzi et al. (2005)<sup>28</sup> and Petruzzi et al. (2007)<sup>29</sup> assessed the effect of topical clobetasol propionate and topical vitamin E. The first study included two cases; complete healing was achieved in one case after four weeks and the second case was resistant.<sup>28</sup> The second study included ten cases; complete healing was obtained in eight cases and partial improvement was detected in the remaining two cases.<sup>29</sup>

Bacci et al. (2017)<sup>25</sup> assessed topical vitamin E in the management of reticular OLP compared to placebo as a main treatment modality in a cross-over

design with two-weeks washout period. They reported statistically significant differences between the two groups in the surface area of the lesions and Thongprasom scale scores and no statistically significant differences in pain scores.<sup>25</sup>

No side effects were reported in the current study. This is in accordance to Petruzzi et al. (2005)<sup>28</sup>, Petruzzi et al. (2007)<sup>29</sup> and Bacci et al. (2017)<sup>25</sup> who confirmed that none of their patients reported any adverse effects or complications during or after the administration of the medications.

Regarding the salivary TAC level, our results revealed a statistically significant increase in TAC level after four weeks topical corticosteroid with adjunctive placebo (control group). This was not in accordance with Hashemy et al. (2016)<sup>30</sup> who found that there is no significant change in the serum TAC level after two weeks of topical corticosteroid therapy. The difference in results may be related to the difference in follow up periods or the studied biological fluid.

In the current study, the increase in TAC level was slightly more in the experimental group compared to the control group with no statistical significance. Consequently, the effect of Vitamin E in the management of OLP may not be limited to its potent antioxidant properties and it may be linked, in addition, to its immunomodulatory and anti-inflammatory properties.<sup>14, 19, 20</sup>

Limitations of this study include small sample size as well as the effect of the confounders such as unequal distribution of OLP forms and gender among the two groups and higher values of pain scores in Vitamin E group.

## Conclusion

Adjunctive use of systemic vitamin E has shown promising results in management of OLP where both

pain reduction and clinical improvement were more prominent in patients who received topical corticosteroid with adjunctive systemic vitamin E 6. compared to the controls with no side effects.

Future studies should be extended to include higher doses of systemic vitamin E and larger number of patients suffering from different forms of OLP to confirm the present suggestions.

**Acknowledgment:** The authors would like to express their gratitude to Dr Manar Zanaty (MZ), associate lecturer of Oral Medicine and Periodontology, Faculty of Dentistry, Cairo University.

**Funding:** Self-funded

**Conflict of interest:** No conflict of interest

## References

- Lodi G, Scully C, Carrozzo M, Griffiths M, Sugeran PB, Thongprasom K. Current controversies in oral lichen planus: report of an international consensus meeting. Part 1. Viral infections and etiopathogenesis. *Oral Surg Oral Med Oral Pathol Oral Radiol Endod.* 2005; 100(1): 40-51. doi: 10.1016/j.tripleo.2004.06.077
- Carrozzo M. Understanding the Pathobiology of Oral Lichen Planus. *Curr Oral Health Rep.* 2014; 1 (3): 173-179. <https://doi.org/10.1007/s40496-014-0022-y>
- Aly DG, Shahin RS. Oxidative stress in lichen planus. *Acta Dermatovenerol Alp Pannonica Adriat.* 2010; 19(1): 3-11.
- Scrobotă I, Mocan T, Cătoi C, Bolfă P, Mureșan A, Băciuț G. Histopathological aspects and local implications of oxidative stress in patients with oral lichen planus. *Rom J Morphol Embryol.* 2011; 52(4): 1305-1309.
- Lopez-Jornet P, Martinez-Canovas A, Pons-Fuster A. Salivary biomarkers of oxidative stress and quality of life in patients with oral lichen planus. *Geriatr Gerontol Int.* 2014;14(3): 654-659. doi: 10.1111/ggi.12153.
- Darczuk D, Krzysciak W, Vyhouskaya P, Kesek B, Galecka-Wanatowicz D, Lipska W, Kaczmarzyk T, Gluch-Lutwin M, Mordyl B, Chomyszyn-Gajewska M. Salivary oxidative status in patients with oral lichen planus. *J Physiol Pharmacol.* 2016; 67(6): 885-894.
- Rekha VR, Sunil S, Rathy R. Evaluation of oxidative stress markers in oral lichen planus. *J Oral Maxillofac Pathol.* 2017; 21(3): 387-393. doi: 10.4103/jomfp.JOMFP\_19\_17.
- Carrozzo M, Thorpe R. Oral lichen planus: a review. *Minerva Stomatol.* 2009; 58 (10): 519-537.
- Farhi D, Dupin N. Pathophysiology, etiologic factors, and clinical management of oral lichen planus, part I: facts and controversies. *Clin Dermatol.* 2010; 28 (1): 100-108. doi: 10.1016/j.clindermatol.2009.03.004.
- Chan ES, Thornhill M, Zakrzewska J. Interventions for treating oral lichen planus. *Cochrane Database Syst Rev.* 2000; (2): CD001168.
- Zakrzewska JM, Chan ES, Thornhill MH. A systematic review of placebo-controlled randomized clinical trials of treatments used in oral lichen planus. *Br J Dermatol.* 2005;153(2): 336-341.
- Cheng S, Kirtschig G, Cooper S, Thornhill M, Leonardi-Bee J, Murphy R. Interventions for erosive lichen planus affecting mucosal sites. *Cochrane Database Syst Rev.* 2012; 15 (2): CD008092. doi: 10.1002/14651858.CD008092.pub2.
- Lodi G, Carrozzo M, Furness S, Thongprasom K. Interventions for treating oral lichen planus: a systematic review. *Br J Dermatol.* 2012; 166 (5): 938-947. doi: 10.1111/j.1365-2133.2012.10821.x.
- Wu D, Lewis ED, Pae M, Meydani SN. Nutritional Modulation of Immune Function: Analysis of Evidence, Mechanisms, and Clinical Relevance. *Front. Immunol.* 2019; 9: 3160. doi: 10.3389/fimmu.2018.03160
- Thongprasom K, Prapinjumrune C, Carrozzo M. Novel therapies for oral lichen planus. *J Oral Pathol Med.* 2013; 42 (10): 721-727. doi: 10.1111/jop.12083.



16. Gupta S, Ghosh S, Gupta S. Interventions for the management of oral lichen planus: a review of the conventional and novel therapies. *Oral Dis.* 2017; 23 (8): 1029-1042. doi: 10.1111/odi.12634.
17. Wang X, Quinn PJ. The location and function of vitamin E in membranes (review). *Mol Membr Biol.* 2000; 17 (3): 143-156.
18. Iqbal MA, Khan M, Kumar P, Kumar A, Ajai K. Role of vitamin e in prevention of oral cancer:-a review. *J Clin Diagn Res.* 2014; 8 (10): ZE05-7. doi: 10.7860/JCDR/2014/9166.4958.
19. Lewis ED, Meydani SN, Wu D. Regulatory role of vitamin E in the immune system and inflammation. *IUBMB Life.* 2019; 71 (4): 487-494. doi: 10.1002/iub.1976.
20. Lee GY, Han SN. The Role of Vitamin E in Immunity. *Nutrients.* 2018; 10 (11): E1614. doi: 10.3390/nu10111614.
21. Chainani-Wu N, Silverman S Jr, Reingold A, Bostrom A, Lozada-Nur F, Weintraub J. Validation of instruments to measure the symptoms and signs of oral lichen planus. *Oral Surg Oral Med Oral Pathol Oral Radiol Endod.* 2008; 105 (1): 51-58.
22. Thongprasom K, Luangjarmekorn L, Sererat T, Taweasap W. Relative efficacy of fluocinolone acetonide compared with triamcinolone acetonide in treatment of oral lichen planus. *J Oral Pathol Med.* 1992; 21 (10): 456-458.
23. Rai B, Kharb S, Jain R, Anand SC. Salivary vitamin E and C in lichen planus. *Gomal J Med Sci.* 2008; 6 (2): 91-92.
24. Ergun S, Troşala SC, Warnakulasuriya S, Özel S, Önal AE, Ofluoğlu D, Güven Y, Tanyeri H. Evaluation of oxidative stress and antioxidant profile in patients with oral lichen planus. *J Oral Pathol Med.* 2011; 40 (4): 286-293. doi: 10.1111/j.1600-0714.2010.00955.x.
25. Bacci C, Vanzo V, Frigo AC, Stellini E, Sbricoli L, Valente M. Topical tocopherol for treatment of reticular oral lichen planus: a randomized, double-blind, crossover study. *Oral Dis.* 2017; 23 (1): 62-68. doi: 10.1111/odi.12573.
26. Abdolsamadi H, Rafieian N, Goodarzi MT, Feradmal J, Davoodi P, Jazayeri M, Taghavi Z, Hoseyni SM, Ahmadi-Motamayel F. Levels of salivary antioxidant vitamins and lipid peroxidation in patients with oral lichen planus and healthy individuals. *Chonnam Med J.* 2014; 50 (2): 58-62. doi: 10.4068/cmj.2014.50.2.58.
27. Nagao T, Warnakulasuriya S, Ikeda N, Fukano H, Yamamoto S, Yano M, Miyazaki H, Ito Y. Serum antioxidant micronutrient levels in oral lichen planus. *J Oral Pathol Med.* 2001; 30 (5): 264-267.
28. Petruzzi M, De Benedittis M, Carriero C, Giardina C, Parisi G, Serpico R. Oro-vaginal-vulvar lichen planus: report of two new cases. *Maturitas.* 2005; 50 (2): 140-150.
29. Petruzzi M, De Benedittis M, Pastore L, Pannone G, Grassi FR, Serpico R. Isolated lichen planus of the lip. *Int J Immunopathol Pharmacol.* 2007; 20 (3): 631-635.
30. Hashemy SI, Gharraei S, Vasigh S, Kargozar S, Alirezaei B, Keyhani FJ, Amirchaghmaghi M. Oxidative stress factors and C-reactive protein in patients with oral lichen planus before and 2 weeks after treatment. *J Oral Pathol Med.* 2016; 45 (1): 35-40. doi: 10.1111/jop.12326.
31. De C Williams AC, Davies HT, Chadury Y. Simple pain rating scales hide complex idiosyncratic meanings. *Pain* 2000; 85: 457– 63.