



Study on Occurrence of Contagious Equine Metritis in the Genital Tract of Equine.



CrossMark

Mona M. Sobhy^{1*}, A. Fathi², Kh.A. Abougazia¹, M.R. Oshba³ and M.H.R. Kotb¹

¹*Department of Reproductive Diseases, Animal Reproduction Research Institute, Agriculture Research Centre (ARC), Cairo, Egypt.

²Immunity Units, Animal Reproduction Research Institute, Agriculture Research Centre (ARC), Cairo, Egypt.

³Ultrasonography and Laparoscopy Unit, Animal Reproduction Research Institute, Agriculture Research Centre (ARC), Cairo, Egypt.

CONTAGIOUS Equine Metritis (CEM) is a transmissible venereal disease of equine, causes infertility in mares and spontaneous abortion in pregnant ones. The etiologic agent of CEM is Gram negative bacteria; *Taylorella equigenitalis*. In this study, a number of 45 clitoral swabs were collected from suspected mares and twenty swabs were from urethral fossa of stallions. Swabs were kept cool during transportation on Amies with charcoal medium. At the lab, all swabs during 48 hours since they have been collected then cultured on tryptose chocolate blood agar (TBA) plates, and incubated at 37°C in microaerophilic atmosphere of 5%-10% CO₂ in hydrogen of 7 days. The suspected colonies have been examined for biochemical characters of catalase, oxidase and phosphatase. All mares were scanned by ultrasound scanner (Sono Scape sonar), vaginal and/or rectal, checked for the presence of any uterine fluid which may indicate the presence of infection. On the other hand, culture investigations revealed 2 (10%) positive cases among stallions and 5 (11.1%) mare's culture positive for *T. equigenitalis*. The bacterium is catalase, oxidase and phosphatase positive. The colonies were confirmed by immunofluorescent test and its sensitivity was 100%. Ultrasound examination of three mare's uteri showing pyometra where their lumen measured 40.6- 57.3 mm fully filled with echogenic particles. While, the uteri of the other two mares showing endometritis which appeared as an echogenic uterine lumen measured 18.6 mm and 37.6 mm with echogenic particles scattered on it. Biosecurity practices can help in preventing spread of CEM by bacterial culture tests on breeding stallions prior to breeding season. Also, urethral swab for CEM testing should be a stallion's annual breeding exam. According to this study an ultrasound scan at the breeding season to check for the soundness of the mare uteri is strongly recommended.

Keywords: Contagious Equine Metritis, Mares, Stallion, Ultrasound.

Introduction

Contagious equine metritis (CEM) was first described in the United Kingdom (UK) in 1977, and then become world-wide [1]. Contagious equine metritis is an inflammatory disease of the proximal and distal reproductive tract of the mare

caused by *Taylorella equigenitalis*, causing mares temporary infertile [2].

Taylorella equigenitalis is a Gram-negative, microaerophilic coccobacillus bacterium, transmitted during mating. Infected mares had a profuse, mucopurulent vaginal discharge up to 40% of affected mares due to inflammation

of uterus and cervix, resulting in infertility in few days after breeding and return to estrus [3]. Acute infection cause mucoid inflammation of endometrium with obvious discharge from vulva seen 1-6 days after infection post-breeding [4].

CEM is rare abortions, but infected mares can produce subclinical carrier foals. Most mares are clitoral carriers and the poor hygienic measures during breeding may spread the organism. The sites of *T. equigenitalis* colonization are in the clitoral fossa [5].

Stallion is asymptomatic and carries the organism on their external genitalia for a period of time [6]. Both mares and stallions become chronic carriers acting as a reservoir of *T. equigenitalis* and source of infection [7]. Infected stallions are passive carriers of the colonised bacteria on their external genitalia where it invades urethra and sex glands, causing pus and contaminated semen [8].

The transmission is high with breeding, where the contaminated instruments and equipment's act as an indirect means of infection. The bacteria spread in semen collected for artificial insemination [9]. Organism has the fastidious nature and slow growth difficult to culture and requires multiple culture samples for one week [10].

The organism can be eliminated by treatment with systemic antibiotics at least 7 days or 21 days combined with antiseptic washing of the affected sites [11]. The infected equine can be treated by chlorhexidine and applying ointments 0.2% nitrofurazone [12]. Diagnostic tests must be repeated 21 days after the end of treatment. Trimethoprim-sulfamethoxazole and application 1% silver sulfadiazine cream can be used. Fertility appears to return normal after treatment of horses [13]. The present study was aimed at assessing the occurrence of Contagious Equine Metritis in equine by identification of infected carrier animals and on their treatment or elimination from breeding programs to avoid the introduction of the disease.

Materials and Methods

Sampling

From mares 45 clitoral swabs were collected, where 20 swabs were taken from the urethral fossa of stallions. All sanitary and hygienic measures were followed by using sterile saline and cotton to clean the areas of sample taken, and use new pair of disposable gloves for each animal. Swabs were kept on ice or at 4°C, and

delivered to a qualified laboratory within 24 hrs. transportation and plated out at lab during 48 hours after collection of samples. All swabs were transferred in a transport medium Amies with charcoal then labeled and kept under refrigeration conditions for variety of laboratory tests has been developed as described by Swerczek [14].

Cultural and biochemical characteristics

All swabs were cultured on plates of tryptose chocolate blood agar (TBA); by adding 5% horse blood with a rich peptone agar, trimethoprim 1µg/ml, clindamycin 5µg/ml and amphotericin B 10µg/ml then cultured at 37°C and kept in microaerophilic atmosphere of 5% to 10% CO₂ in hydrogen during a minimum period of 7 days [15]. The suspected colonies were subjected to biochemical investigations with catalase, oxidase and phosphatase [16].

Indirect immunofluorescence antibody tests (IFAT)

The Pourquier IIF *Taylorella equigenitalis* Test is an indirect immunofluorescence (IIF) test, a simple and cost-effective method based on the direct detection of *Taylorella equigenitalis* for confirming colonies by IDEXX kits.

Ultrasonography examination

Vaginal and/or rectal examinations of 45 mares were carried out by ultrasound scanner (SonoScape Sonar) checking for presence of any uterine fluids which may indicate infection.

Results

By culture examination found 5 (11.1%) positive cases of *T. equigenitalis* in mare and 2 (10%) positive cases in stallion. The colonies are up to 2-3mm in diameter, soft, full edge yellow / greyish colour produces, tiny and round after 48 h. The colonies may be enlarged and turned whitish at 37°C with further incubation. The bacterium is nonmotile, catalase, oxidase and phosphatase positive for biochemical characteristics. The indirect immunofluorescence test was applied to discriminate *T. equigenitalis* from *T. asinigenitalis*. This test constitutes a rapid, sensitive and specific tool for confirming presumptive colonies of *T. equigenitalis* (Fig.1).

The scanned of 45 mares with ultrasound scanner detected 3 cases of uterine pyometra which appears as lumen measured 40.6 - 57.3mm fully filled with echogenic particles (Image 1) and 2 mares affected with endometritis appears as anechoic uterine lumen measured 18.6 mm - 37.6 mm with some echogenic particles (Image 2).

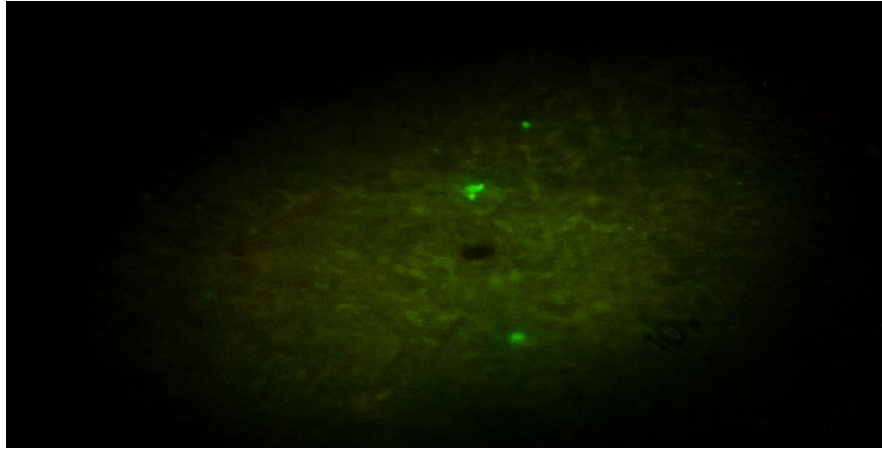


Fig. 1. Positive sample by indirect immunofluorescent test for *T. equigenitalis* under fluorescent microscope Zeiss at 10 X.

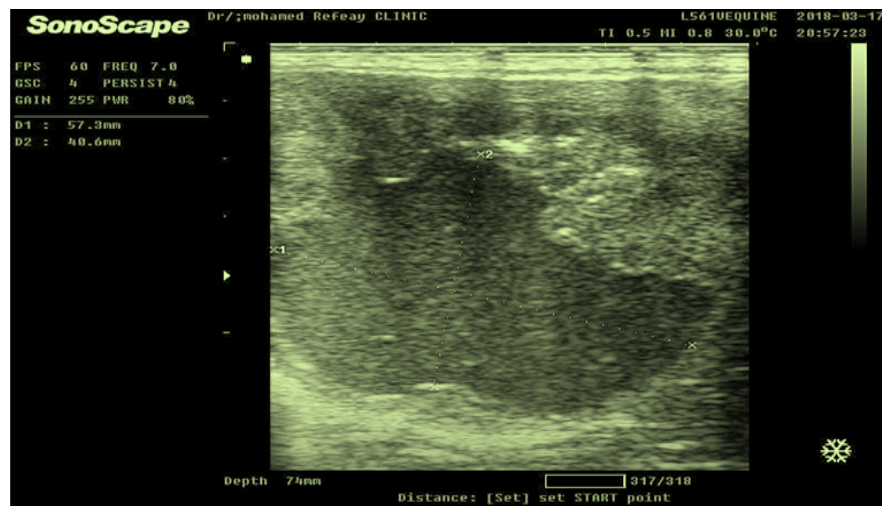


Image 1: Ultrasound image of mare uterus showing pyometra which appears as lumen measured 40.6 - 57.3 mm fully filled with echogenic particles.

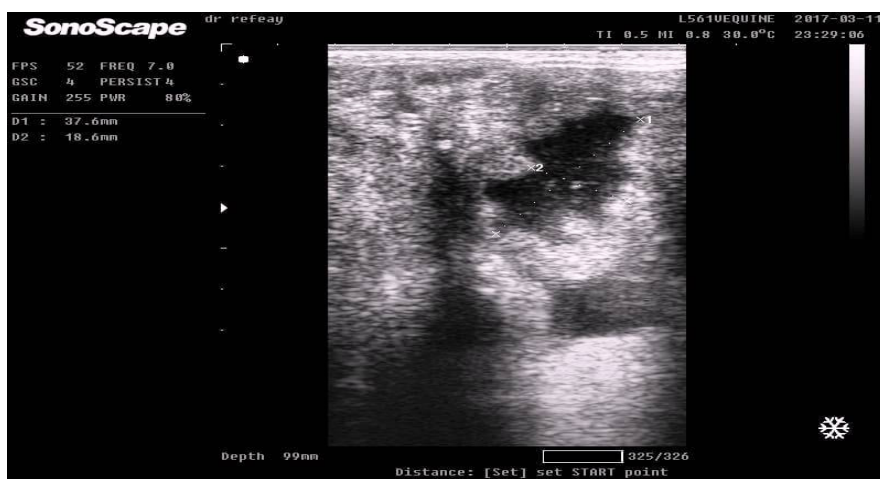

Image 2: Ultrasound image of mare uterus showing endometritis which appears as anechoic uterine lumen measured 18.6 mm- 37.6 mm with some echogenic particles.

Discussion

Contagious equine metritis (CEM) is a contagious venereal disease of horses caused by *Taylorella equigenitalis* [17]. Culture positive was investigated in 2 (10%) cases stallions and 5 (11.1%) mares belonging to different localities in Egypt. These results agreed with previously demonstrated in United States with Timoney [18].

The colonies were confirmed for *Taylorella equigenitalis* by IDEXX indirect immunofluorescent testkits (Fig.1) and discriminated bacterium from *T. asinigenitalis*. IFT sensitivity was 100% in samples and its specificity 97.2% screened by bacteriological tests constitutes a satisfactory way to determine CEM status [19]

The scanning of 45 mares with ultrasound scanner detected 3 (6.7%) uterine pyometra which appears as lumen measured 40.6 - 57.3 mm fully filled with echogenic particles (Image, 1) and 2 (4.4%) affected with endometritis appears as measured 18.6 mm- 37.6 mm (Image, 2) [20].

The equine breeding industry depends on the health of the uterus, and without a healthy uterus a mare cannot successfully conceive or carry a foal to term [21]. In this study detected low prevalence of CME can be treated or eliminated from breeding. Bacterial infections of uterus are leading cause of subfertility and infertility in mares and represent a major economic loss to the equine industry. Infected mares affected by cervicitis, metritis, with vaginal and cervical discharges. Mares had a short estrus cycle and failed to conceive or give full-term foal, which may carry the organism [22]. Mares may remain infected for several months and chronically infected mares show no signs [23].

T. equigenitalis spread to stallions via indirect mechanisms at shared breeding and to mares via artificial insemination [17]. CEM should be a diagnostic consideration even where this organism is to be absent. Infected horses must be quarantined and treated with disinfectants and antibiotics for several weeks [24].

Biosecurity practices can prevent the spread of CEM by conducting bacterial culture tests on breeding stallions prior to breeding season [25]. Urethral swab for CEM testing must be annual

breeding exam for stallion [26]. The use of the technique of ultrasonography and laboratory findings was very helpful and of great benefit, facilitated the selection of the suspected cases among the disease carriers and identify the endometritis in mare, that greatly saved time, effort and cost.

Conclusion

The control starts before reproductive season to know the status of the animal and improving hygienic measures to prevent the spread of infection among animals.

Control of CEM depends upon early identification of infected carrier horses, followed by treatment or elimination from breeding program. Horses over two years of age are quarantined and screened for *T. equigenitalis*.

The utmost preventing measures are:

- Stallions, teasers and mares should be examined for CEM before breeding by swabbing and testing at the laboratory.
- Strict hygienic measures should be applied during handling mares and stallions.
- Stop mating using the infected stallion.
- Isolate and treat the infected horse.
- Biosecurity measures during the daily handling.
- Clean and disinfect semen equipment between stallions.
- Keep records for horse movements and semen shipments.

Acknowledgment: I will be appreciating to staff of immunity unit in Animal Reproduction Research Institute for their helpful and support during this research.

Funding statement: Research workers paid the full costs of the research.

Conflict of interest: We didn't found any problem during the work.

Ethical consideration: All studies described in this research were carried out at the department of Reproductive Diseases Laboratory, located at Animal Reproduction Research Institute, Agriculture Research Center, Giza, Egypt. Code No. 13/732/3/4/7.

References

1. Sahu, S.P., Dardiri, A.H., Rommel, F.A. and Pierson, R.E. Survival of contagious equine metritis bacteria in transport media. *Am. J. Vet. Res.*, **40**, 1040–1042 (1979).
2. OIE (World Organization for Animal Health), Contagious Equine Metritis. <http://www.oie.int/en/scientific-expertise/reference-laboratories/list-of-laboratories/> 2018.
3. Fernie, D.S., Batty, I., Walker, P.D., Platt, H., Mackintosh, M.E. and Simpson, D.J. Observations on vaccine and post-infection immunity in contagious equine metritis. *Res. Vet. Sci.*, **28**, 362–367 (1980).
4. Anzai, T., Kamada, M., Niwa, H., Eguchi, M., and Nishi, H. Contagious equine metritis eradicated from Japan. *J. Vet. Med. Sci.*, **74** (4), 519–22 (2012).
5. Schulman, M.L., May, C.E., Keys, B. and Guthrie, A.J. Contagious equine metritis: artificial reproduction changes the epidemiologic paradigm. *Vet Microbiol.* **167** (1-2), 2-8 (2013).
6. Timoney, P.J. Contagious equine metritis. In: *Foreign Animal Diseases*. 7th ed. Boca Raton, FL: United States Animal Health Association. p. 225-230 (2008).
7. CDFA Animal Health and Food Safety Services. *Animal Health Branch*. (2019).
8. Mead, B.J., Timoney, P.J., Donahue, J.M., Branscum, A.J., Ford, R. and Rowe, R. Initial occurrence of *Taylorella asinigenitalis* and its detection in nurse mares, a stallion and donkeys in Kentucky. *Prev. Vet. Med.*, **95**, 292-296 (2010).
9. Klein, C., Donahue, J.M., Sells, S.F., Squires, E.L., Timoney, P.J., and Troedsson, M.H. Effect of antimicrobial-containing semen extender on risk of dissemination of contagious equine metritis. *J. Am. Vet. Med. Assoc.*, **241** (7), 916-921 (2012).
10. Baverud, V., Nyström, C., and Johansson, K.E. Isolation and identification of *Taylorella asinigenitalis* from the genital tract of a stallion, first case of a natural infection. *Vet. Microbiol.*, **116**, 294-300 (2006).
11. Jang, S.S., Donahue, J.M., Arata, A.B., Goris, J., Hansen, L.M., Earley, D.L., Vandamme, P.A., Timoney, P.J., and Hirsh, D.C. *Taylorella asinigenitalis* sp. A bacterium isolated from the genital tract of male donkeys (*Equus asinus*). *Int. J. Syst. Evol. Microbiol.* **51**, 971-976 (2001).
12. Kristula, M.A. and Smith, B.I. Diagnosis and treatment of four stallions, carriers of the contagious metritis organism--case report. *Theriogenology*, **61**, 595-601 (2004).
13. Katz, J.B., Evans, L.E., Hutto, D.L., Schroeder-Tucker, L.C., Carew, A.M., Donahue, J.M., and Hirsh, D.C. Clinical, bacteriologic, serologic, and pathologic features of infections with atypical *Taylorella equigenitalis* in mares. *J. Am. Vet. Med. Assoc.*, **216**, 1945-1948 (2000).
14. Swerczek, T.W. Inhibition of the CEM organism by the normal flora of the reproductive tract. *Vet. Rec.*, **103**, 125-129 (1978).
15. Platt, H. J.G. Atherton, D.J. Simpson, C.E.D., Taylor, R.O., Rosenthal, D.F. Brown, J. and Wright, T.G. Genital infection in mares. *Vet. Rec.*, **101**, 20-26 (1977).
16. HSC (Health Surveillance Centre). Complutense University, Spain. (2019).
17. Erdman, M.M., Creekmore, L.H., Fox, P.E., Pelzel, A.M., Porter-Spalding, B.A., Aalsburg, A.M., Cox, L.K., Morningstar-Shaw, B.R., and Crom, R.L. Diagnostic and epidemiologic analysis of the 2008-2010 investigation of a multi-year outbreak of contagious equine metritis in the United States. *Prev. Vet. Med.*, **101**(3-4), 219-228 (2011).
18. Timoney, P.J. Horse species symposium: contagious equine metritis: an insidious threat to the horse breeding industry in the United States. *J. Anim. Sci.*, **89** (5), 1552-1560 (2011).
19. Breuil, M.S.F., Duquesne, F., Sevin, C., Laugier, C. and Petry, S. Indirect immune-fluorescence test using polyclonal antibodies for the detection of *T. equigenitalis*. *Res. Vet. Sci.*, **88**, 369–371 (2010).
20. LeBlanc, M.M. and Causey, R.C. Clinical and subclinical endometritis in the mare: both threats to fertility. *Reprod. Domest. Anim.*, **44** (3), 10-22 (2009).
21. Swerczek, T.W. and Caudle, A. B. Bacterial Causes of Subfertility and Abortion in the Mare. The Merck Veterinary Manual, 10th Ed. Merck and Co. Chapter **21**, 168-172 (2014).
22. Gilbert, R.O. Contagious equine metritis. In: Kahn C.M., Line S., Aiello S.E. (Ed.), *The Merck Veterinary Manual*, 10th ed. Whitehouse Station, NJ: Merck and Co. (2014).

23. Robert, O.G. Contagious Equine Metritis. Reproductive Medicine, Department of Clinical Sciences, College of Veterinary Medicine, Cornell University. MSD and the MSD Veterinary Manual © Merck Sharp & Dohme Corp., a subsidiary of Merck & Co., Inc., Kenilworth, NJ, USA (2019).
24. Luddy, S. and Kutzler, M.A. Contagious equine metritis within the United States: A review of the 2008 outbreak. *J. Equine Vet. Sci.*, **30** (8), 393-400 (2010).
25. Timoney, P.J. Contagious equine metritis. *Comp. Immunol. Microbiol. Infect. Dis.*, **19**, 199-204 (1996).
26. APHIS, (Animal and Plant Health Inspection Service). Contagious Equine Metritis. *United States Department of Agriculture*, 1-2 (2014).

دراسة عن تواجد مرض الالتهاب الرحمي الضاري للخيل في الجهاز التناسلي للخيل المصرية

منى محمد صبحي^١، أحمد فتحى^٢، خالد عبد السميع ابو جازية^٣، محمد رفاعى عشبه^٤ و محمد حسام الدين رفاعى قطب^٥

^١ قسم الامراض التناسلية - معهد بحوث التناسليات - مركز البحوث الزراعية - جيزة - مصر.
^٢ وحدة المناعة - معهد بحوث التناسليات - مركز البحوث الزراعية - جيزة - مصر.
^٣ قسم الامراض التناسلية - معهد بحوث التناسليات - مركز البحوث الزراعية - جيزة - مصر.
^٤ وحدة الموجات الصوتية - معهد بحوث التناسليات - مركز البحوث الزراعية - جيزة - مصر.
^٥ قسم الامراض التناسلية - معهد بحوث التناسليات - مركز البحوث الزراعية - جيزة - مصر.

عدوى الخيل المعدية بالالتهاب الرحمي الضاري هو مرض تناسلي ينتقل للخيل. يؤدي إلى العقم في الأفراس بسببه ميكروب تيلوريلاكويجنالز ويمكن أن يتسبب في أجهاض في الأفراس. في هذه الدراسة، تم جمع عدد ٤٥ عينة مسحات مهبلية قطعة من الأفراس وعدد ٢٠ عينة من العضو الذكري للذكور. مع وضع المسحات في ثلاجة حفظ العينات باردة أثناء النقل إلى المختبر خلال ٤٨ ساعة من أخذ العينات ويتم زرع كل العينات على ميديا الامينيز والفحم كيميديا ناقلة ثم بعد ذلك تزرع على ميديا التريبوتومع الدم الساخن "شوكليت أجار" وتوضع الأطباق في درجة حرارة ٣٧ درجة مئوية في جو يحتوى على ٥% أكسجين و ١٠% ثنائي أكسيد الكربون و ٨٥% هيدروجين لمدة ٧ أيام ثم تفحص الأطباق لفحص المستعمرات البكتيرية النامية ويجرى عليها الاختبارات البيوكيميائية مثل الكتاليز والاكسيديز والفسفاتيز وتم تطبيق الاختبار الفلورسينى على المستعمرات البكتيرية للتأكد من الميكروب نتيجة حساسية الاختبار التي تصل ١٠٠%.

جميع الأفراس تم فحصها باستخدام الموجات فوق الصوتية، المهبلية / أو المستقيم بواسطة جهاز سونار سونوسكاب، يتم فحصها للتأكد من وجود أي سوائل بالرحم قد يشير إلى وجود إصابة. وكانت النتيجة إيجابية ٥ حالات من الأفراس إيجابية لميكروب الالتهاب الرحمي الضاري بنسبة ١١,١%. وعدد ٢ حالة إيجابية في الذكور بنسبة ١٠% وكانت نتيجة الاختبارات البيوكيميائية إيجابية للكتاليز والاكسيديز والفسفاتيز.

وكانت نتيجة الفحص باستخدام الموجات الصوتية وجود عدد ٣ حالات صديبية في الرحم يظهر كتجويف قياسه ٤٠,٦ - ٥٧,٣ ملم ملىء بالكامل بالصديد. وعدد حالتين يظهر بها الرحم به التهاب في بطانة الرحم والذي يظهر على شكل تجويف رحمى عديم اللون يبلغ قياسه ١٨,٦ ملم و ٣٧,٦ ملم.

وعن طريق الاجراءات الاحترافية للامن الحيوى يمكن أن نمنع أنتشار ميكروب الالتهاب الرحمي الضاري مع اجراء اختبارات استنبات البكتريا على الخيل قبل كل موسم تكاثر. ومن الناحية المثالية يتم أخذ عينات للاختبار من الذكور المربى سنويا كأجراء روتينى دورى. ونحن نوصى بالفحص باستخدام الموجات فوق الصوتية في موسم التكاثر للتحقق من عدم وجود أي عدوى بالرحم في الأفراس.