

## Age Related Changes in The Expression of Tenascin-c in The Liver of Albino Rats

Mohammed H Mohammed<sup>1\*</sup>MBBCh, Mohammed M El Assaly<sup>1</sup> MD, Hamdino M Attia<sup>1</sup>MD

**\*Corresponding Author:**

Mohammed H Mohammed  
[dr.m009009@gmail.com](mailto:dr.m009009@gmail.com)

**Received for publication**  
January 5, 2020; **Accepted**  
January 31, 2019; **Published**  
online February 1, 2020.

**Copyright** 2020 The Authors  
published by Al-Azhar  
University, Faculty of  
Medicine, Cairo, Egypt. All  
rights reserved. This an open-  
access article distributed under  
the legal terms, where it is  
permissible to download and  
share the work provided it is  
properly cited. The work  
cannot be changed in any way  
or used commercially.

**doi:** 10.21608/AIMJ.2020.69262

<sup>1</sup>Department of Anatomy and  
Embryology, Faculty of  
Medicine, AL-Azhar  
University, Damietta.

### Abstract

**Background:** Aging is a gradual deterioration in the function of tissues and organ systems with loss of the ability to maintain homeostasis, due to structural alteration or dysfunction. Aging impacts directly on all the different types of liver cells: hepatocytes, liver sinusoidal endothelial cells, Küpffer cells and hepatic stellate cells. Activation of former cells leads to deposition of collagen in the space of Disse, decrease of fenestrations of liver sinusoidal endothelial cells and formation of the basement membrane. These changes called pseudocapillarization. Tenascin-C is an extracellular matrix glycoprotein markedly up-regulated during liver fibrosis. Tenascin-C is highly expressed during embryonic development, wound healing, chronic inflammation, and cancer.

**Aim of the study:** we investigated the contribution of Tenascin-c to liver pseudocapillarization by comparing expression of tenascin c and levels of fibrosis deposition in space of Disse in different age groups.

**Material and methods:** Different ages of albino rats (6, 12, 18, 24, 30 and 36 months) were chosen and sacrificed. Morphometric and serological parameters were assessed, and the liver samples were processed for histological and immunohistochemical staining.

**Results:** Immunohistochemical staining revealed a gradual increase in Tenascin-c deposition from first to forth group then gradual decrease occurred. Masson's stain revealed a gradual increase of fibrosis in space of Disse deposition from the 2<sup>nd</sup> to 6<sup>th</sup> group.

**Conclusion:** Tenascin-c appears and increases before the appearance of fibrosis but when fibrosis is formed TNC is down-regulated again.

**Key words:** Tenascin-c; Masson's stain; hepatic stellate cells; space of Disse; albino rat.

**Disclosure:** The authors have no financial interest to declare in relation to the content of this article. The Article Processing Charge was paid for by the authors.

**Authorship:** All authors have a substantial contribution to the article

### INTRODUCTION

Aging leads to the progressive impairment of homeostasis at genomic, cellular, tissue and whole-organism levels, which reduce survival and fertility while increasing the risk of disease and death. At the cellular level, aging is secondary to multiple processes that have been described as the 'Hallmarks of Aging': epigenetic alterations, genomic instability, telomere attrition, loss of proteostasis, dysregulation of nutrient sensing, altered intracellular communication, mitochondrial dysfunction, stem cell exhaustion, cellular senescence, inflammation and impaired adaption to stress.<sup>1</sup>

The Hallmarks of Aging impact directly on all the different types of liver cells: hepatocytes, liver sinusoidal endothelial cells (LSECs), hepatic stellate cells (HSCs) and Küpffer cells (KCs).<sup>2</sup>

The HSC (or Ito cell) is a pericyte that resides in the extracellular space of Disse. In the early phases of many chronic liver diseases, HSC becomes activated and contributes fibrosis by producing extracellular matrix components such as collagen. It is unknown whether HSC contributes to the mild perisinusoidal fibrosis seen in old age. Furthermore, a recent study has shown that LSECs are involved in the regulation of activation of HSC which raises the possibility that the age-related changes in the LSEC might impact on HSCs.<sup>3</sup>

A pivotal event in the progression of liver fibrosis and cirrhosis is hepatic stellate cell (HSC) activation and secretion of extracellular matrix proteins, including tenascin-C (TnC).<sup>4</sup>

Tenascin-C (TNC) is an extracellular matrix protein with several molecular forms that are created through alternative splicing and protein modifications. It is highly conserved amongst vertebrates. Tenascin-C

has many extracellular binding partners, including matrix components, soluble factors, and pathogens; it also influences cell phenotype directly through interactions with cell surface receptors. Tenascin-C protein synthesis is tightly regulated, with widespread protein distribution in embryonic tissues, but restricted distribution of tenascin-C in adult tissues. Tenascin-C is also expressed de novo during

## MATERIAL AND METHODS

All experiments were approved by the ethical committee of Al Azhar University, Damietta, Egypt and were done in accordance with the NIH recommendation and guidelines of (Committee for the Update of the Guide for the Care and Use of Laboratory Animals, 2011).

### Animals

Sixty, albino rats (30 males and 30 females) were obtained from the animal house, Mansoura University, Egypt (MERC: Mansoura Experimental Research Center). Each group was housed in one plastic cage on wood chip bedding in an air-conditioned animal room at  $22\pm 2$  °C and  $55\pm 5\%$  humidity with a 12 hour light/dark cycle and free access to water and chow in the animal house of Mansoura university, Egypt.

### Experimental design

In the present study, the rats were divided into three age stages. Each one represents a stage of the life span of rats. These stages contain two different age groups each one contains 10 rats as follow:

- 1- Middle age: including 6 month and 12 months age groups
- 2- Old age: including 18 month and 24 months age groups
- 3- Senile age: including 30- and 36-months age groups.

Rats were weighed then sacrificed at age of 6, 12, 18, 24, 30 and 36 months. Blood samples obtained for laboratory analysis. Trans-cardiac fixation was done. After trans cardiac fixation, Samples from each rat liver (about 1cm) is preserved in 4% paraformaldehyde in phosphate-buffered saline. then they were put into paraffin blocks to be sectioned for histological and Immunohistochemical staining.

### Measurements and laboratory analysis

On the day of termination, the rats were weighed on an animal balance to obtain data on body weight. Subsequently, the rat was anesthetized. Then 3-ml venous blood samples were drawn using capillary tubes after the rat was unconscious. Each blood sample was placed in an EDTA-containing Eppendorf tube. After 3ml of venous blood had been obtained, the experimental animals were terminated by trans-cardiac perfusion, using physiologic saline (NaCl) followed by PBS 10% formal fixative. The liver was taken and dried on filter paper. After drying, the liver was weighed on an analytical balance and the organ weight recorded, expressed in grams.<sup>6</sup>

The blood samples obtained from each of the experimental animals were centrifuged to obtain the respective sera, which were taken with micropipettes and placed in separate Eppendorf tubes. The sera were subsequently sent to the laboratory for measurement of alanine aminotransferase (ALT),

aspartate aminotransferase (AST), albumin, total Cholesterol, Triglycerides and malondialdehyde

(MDA). ALT and AST concentrations were expressed in unit/liter (U/L). Serum albumin, total cholesterol, and triglycerides were expressed in mg/dl. The MDA concentration was expressed in nanomol/gram (nmol/g).<sup>6</sup>

### Histological and Immunohistochemical staining

Slides of the liver were stained with (H&E) hematoxylin and eosin, Masson's and Immunohistochemical stains

For immunohistochemical staining, 5µm paraffin sections were deparaffinized, rehydrated and brought into the water. The slides were rinsed with phosphate-buffered saline (PBS), blocked in 0.1% hydrogen peroxide and incubated at room temperature, Block in 10% normal rabbit serum with 1% BSA in PBS. Incubation of the section overnight with the primary antibody was done. The primary antibodies were mouse monoclonal Tenascin-c antibody. Following rinsing the sections, they were incubated with biotinylated secondary antibody for 20 minutes. Finally, sections were counterstained with hematoxylin.

### Immunohistological assessment

Five non-overlapping randomly fields (400x) per section of the liver were captured using a digital camera (Olympus) and analyzed for each marker. The Tenascin-c expression was counted as a stained area fraction using NIH image J version 1.33 software and was statistically analyzed. Area fraction was automatically measured with the "threshold" function of the program. The program marks all the pixels of a selected gray value and counts all the groups of marked pixels within the selected area.<sup>7</sup>

Quantification of the optical density (OD) of Tenascin-c was performed using NIH Image J software (Fiji version). Open the image then run color then deconvolution then chose "H DAB" which will form new three images. One (color 2) is the DAB image, the other (color 1) is the hematoxyline image, the third complementary image, contained shades of both DAB and hematoxylin. Quantification was made for the DAB image from the analysis menu, the "mean gray value" was measured. Optical density (OD) numbers were obtained with the following formula:  $OD = \log(\text{maximum intensity/mean intensity})$ , where max intensity=255 for the 8-bit image. The immunostaining intensity was expressed as OD. The data were presented as Mean  $\pm$  SD.<sup>7</sup>

### Statistical analysis

Data were collected, revised, verified then edited on P.C and then analyzed statistically using SPSS statistical package version (22). One-way ANOVA was performed to determine the significance of the difference between the mean body weight, mean weights of liver, mean ALT, AST, Albumin, Total cholesterol, triglycerides and MDA concentrations in each group.

One-way ANOVA was also used to determine the significance of the mean optical density of Tenascin-c and Masson trichrome stained sections in each group. The post-hoc Tukey HSD test was performed on data that were found to be statistically significant by the parametric one-way ANOVA test. Results

were presented as Mean± SD. P-value <0.05 was considered statistically significant.

**RESULTS**

**Morphological assessment:**

The data analysis revealed that there was a noticeable increase in the body and liver weights of rats 6, 12- and 18-months age groups. After that, there was a gradual decrease in weights of rats 24, 30 and 36 age groups. The liver/body weight ratio showed no significant change with age. Table 1

Age	Body weight Mean ± SD	Liver weight Mean ± SD	Ratio Mean ± SD
6 Months	420 ± 20.8	9.508 ± 0.3	2.268 ± 0.123
١٢ Months	547,8 ± 23.7	12.34 ± 0.5	2.255 ± 0.115
١٨ Months	589,9 ± 23.5	13.238 ± 0.42	2.247 ± 0.117
٢٤ Months	473,8 ± 19.4	10.585 ± 0.3	2.237 ± 0.104
٣٠ Months	450,3 ± 23.5	10.029 ± 0.13	2.232 ± 0.127
٣٦ Months	430,3 ± 41.5	9.452 ± 0.5	2.215 ± 0.245
	P-value < 0.00	P-value < 0.00	P-value = 0.978

P> 0.05 not significant,  
 \*Indicates p< 0.05 significant,  
 \*\*Indicates p< 0.001 highly significant.

**Table (1): ANOVA for age groups.**

The mean percentage values of liver weight, body weight and liver weight/ body weight ratio in different age groups of the adult albino rats.

**Serological assessment**

The data analysis revealed that there was minimal change in liver ALT and AST in the form of a gradual increase with aging. This increase was within normal values in all groups except group 6. The increase in liver enzymes was associated with a gradual decrease in serum albumin. Lipid profiles also affected by aging. Total cholesterol showed an increase with age in all groups while triglycerides showed an increase with age till the fourth group (age of 24 months) then decreased in the fifth and sixth group. The inflammatory mediator, malondialdehyde (MDA) showed a significant increase with aging. Table 2 & 3

**Histological and Immunohistochemical assessment**

Light microscopic examination of sections of the rat's liver stained with hematoxylin and eosin revealed that no changes observed from age of the 6<sup>th</sup> months till age of 36 months, the hepatocytes arranged in regular, branching, interconnecting plates that are interposed with a network of hepatic sinusoids. The hepatocytes were large oval to polygonal and a single nucleus (mononucleated). The nuclei were central large, round to oval with diffuse chromatin. The cytoplasm showed multiple small

clear vesicular bodies. Sinusoidal spaces were seen separating the hepatocytes from each other and opened into the central vein. Figure 1

Age	ALT	AST	Albumin
6 Months	16.8 ± 1.6	10.3 ± 2.1	26.8 ± 0.28
١٢ Months	22.9 ± 3.2	18.6 ± 2	25.9 ± 0.26
١٨ Months	30.4 ± 2.8	31.1 ± 3	24.7 ± 0.26
٢٤ Months	41.7 ± 3.3	45.5 ± 1	24.3 ± 0.13
٣٠ Months	50.5 ± 2.7	54.6 ± 1.9	23.7 ± 0.19
٣٦ Months	57 ± 1.9	59.8 ± 1.9	23.5 ± 0.11
	P-value < 0.00	P-value < 0.00	P-value < 0.00

\*Indicates p< 0.05 significant  
 \*\*Indicates p< 0.001 highly significant.

**Table (2): ANOVA for age groups.**

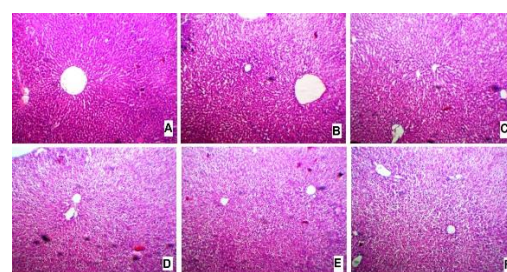
The mean percentage values of ALT, AST, albumin in different age groups of adult albino rats

Age	Cholesterol	Triglycerides	MDA
6 Months	80.6 ± 1.9	113 ± 2.7	٧,٦ ± 0.12
١٢ Months	92.23 ± 3	128 ± 2.6	٨,٥ ± 0.19
١٨ Months	113.36 ± 2.7	141 ± 2.2	٩,٣ ± 0.18
٢٤ Months	131.25 ± 3.2	150 ± 2.3	١٠,٢ ± 0.13
٣٠ Months	142.28 ± 2.7	131 ± 2.3	١٠,٧ ± 0.16
٣٦ Months	150.44 ± 2.1	105 ± 2.4	١١,٣ ± 0.19
	P-value < 0.00	P-value < 0.00	P-value < 0.00

\*Indicates p< 0.05 significant  
 \*\*Indicates p< 0.001 highly significant.

**Table (3): ANOVA for age groups.**

The mean percentage values of total cholesterol, triglycerides, and Malondialdehyde (MDA) in different age groups of the adult albino rats.

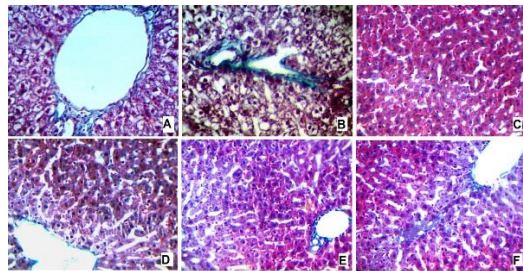


**Fig. 1:** A photomicrograph of Hematoxylin and eosin-stained sections of the liver of albino rat (A= 6months old, B= 12 months old, C= 18 months old, D= 24 months old, E= 30 months old and F= 36 months old) showing the normal histological appearance of the liver with the hepatic cords

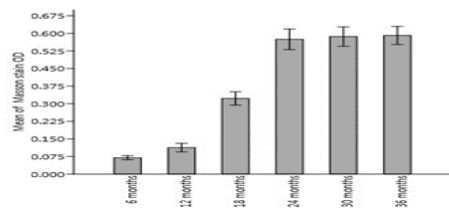


(H) radiating from portal triad (PT) and directed towards the central vein(C) (X 100)

Sections stained with Masson’s stain revealed that there was Masson’s positive stain around the portal tract and central vein in all groups. There was no or minimal fibrosis in the 6 months age group. Fibrosis appeared in liver sinusoids of the 12 months age group. Fibrosis was markedly increased in the 18- and 24-months age groups, then the increase was minimal or plateau. This means fibrosis was presented in liver sinusoids. This fibrosis increased with age till the age of 24 months with no further increase in other age groups. Figure 2 & Graph 1

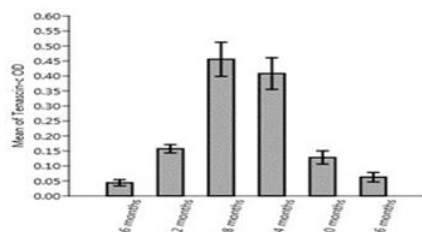


**Fig 2:** A photomicrograph of Masson stained sections of the liver of albino rat (A= 6months old, B= 12 months old, C= 18 months old, D= 24 months old, E= 30 months old and F= 36 months old) (X 400)



**Graph 1:** Showing the comparison of the optical density of sections stained with Masson stain in different age groups in the liver of albino rats

Immunohistochemically stained section with anti-Tenascin c antibody showed positive stain localized to hepatic sinusoids in the 6, 12, 30 and 36 age groups. In 18 and 24 months, there was diffuse stain not localized to sinusoids. Optic density and statistical analysis revealed a marked increase in tenascin c from 6 to 18 months rats then gradual decrease occurred. This means that Tenascin c was increased (up-regulated) with the appearance and increase of fibrosis but when fibrosis was established Tenascin c decreased (down-regulated) again. Graph 2, Table 4 and Figure 3.



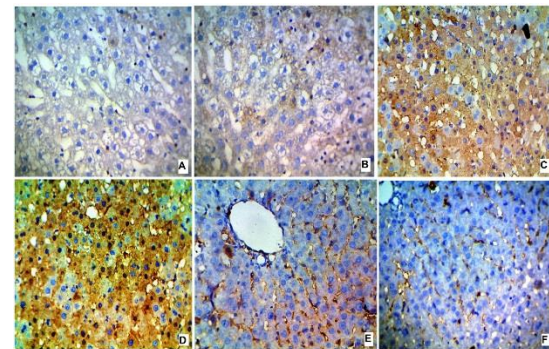
**Graph 2:** showing the comparison of the optical density of sections stained with anti-tenascin c in different age groups in the liver of the albino rats.

Age	Tenascin-c Mean ± SD	Masson’s Mean ± SD
6 Months	0.043 ± 0.032	0.069 ± 0.02
12 Months	0.15 ± 0.043	0.112 ± 0.05
18 Months	0.45 ± 0.18	0.32 ± 0.08
24 Months	0.40 ± 0.16	0.57 ± 0.13
30 Months	0.12 ± 0.069	0.58 ± 0.12
36 Months	0.062 ± 0.049	0.59 ± 0.12
	<b>P-value &lt; 0.00</b>	<b>P-value &lt; 0.00</b>

\*Indicates p< 0.05 significant

**Table (4): ANOVA for age groups.**

The mean percentage values of the optical density of Tenascin-c and Masson’s stain in different age groups in the liver of the albino adult rats.



**Fig 3:** A photomicrograph of immunostained sections of the liver of albino rats (A= 6months old, B= 12 months old, C= 18 months old, D= 24 months old, E= 30 months old and F= 36 months old) (X400)

**DISCUSSION**

In the present study, we observed a gradual increase in body weight and liver weight from the age of 6 months till the age of 24 months then gradual decrease occurred. There was minimal change in liver ALT and AST in the form of a gradual increase with aging. This increase was within normal values in all groups except group 6. The increase in liver enzymes was associated with a gradual decrease in serum albumin. Lipid profiles also affected by aging. Total cholesterol showed an increase with age in all groups, while triglycerides showed an increase with age till the fourth group (age of 24 months) then decreased in the fifth and sixth group. The inflammatory mediator, Malondialdehyde (MDA), showed a significant increase with aging.

Aging is associated with a variety of morphological changes in the liver, but their underlying mechanisms are still unclear. The liver progressively shrinks by 20-40%

during the course of human life, and there is a concomitant age-related decrease in liver volume.<sup>8</sup>

In agreement of the current study Ying et al.<sup>9</sup> used rats 6, 12, 18 and 24 months old and found that there was marked increase in body weight and liver weight in 6, 12 and 18 age group rats followed by a decrease in body weight and liver weight in 24 age group rats.<sup>9</sup>

Miler et al.<sup>10</sup> used rats 4 d 24 months old, and they mentioned that the functional status of the liver was achieved by measuring the concentration of alanine aminotransferase (ALT), aspartate aminotransferase (AST), and gamma-glutamyl trans-peptidase (GGT) in the serum of young and old rats. The results obtained displayed an old age-associated 4-folds increase in GGT concentration when compared to young rats. ALT and AST concentrations unchanged accompanied by the increase of cholesterol and decrease of triglycerides in old age. These findings support the result of the current study.<sup>10</sup>

Serum lipid levels are related to age total cholesterol (TC) gradually increase after adolescence. Triglycerides changeless during adulthood but tends to be higher in old age.<sup>11</sup>

Free radicals, because of their nature of the attack on cellular organelles behave like oxidants. The attack of free radicals on polyunsaturated membrane lipids gives hydroperoxide with subsequent production of malondialdehyde (MDA). This attack on membrane lipid is termed as lipid peroxidation, and malondialdehyde is now measured as the product of free radical injury on membrane lipid. The attack of free radicals on polyunsaturated membrane lipids results in hydroperoxide with subsequent production of malondialdehyde (MDA).<sup>12</sup>

These findings were supported by the study done by Maeso et al.<sup>13</sup> using 3 and 20 age group rats. They found that aged rats (20 months old) presented significantly increased body and liver weight compared to 3-month young rats, however, the liver-body weight ratio was moderately diminished in old rats. elderly animals exhibited a certain decline in liver function as suggested by reductions in albumin levels, although no significant differences in transaminases (as a marker of liver cell injury) were observed. Evaluation of plasma lipids revealed an increase in cholesterol, without significant changes in triglycerides. Hepatic malondialdehyde (MDA) in old rats was elevated, suggesting an increase in oxidative stress secondary to the lipid peroxidation process.<sup>13</sup>

The free radical theory of aging hypothesized a single common process, modifiable by genetic and environmental factors in which the accumulation of endogenous oxygen radicals generated in cells could be responsible for the aging and death of all living beings.<sup>14</sup>

In our study, sections stained with Masson's stain revealed that there was Masson's positive stain around the portal tract and central vein in all groups. There was a marked increase in optical density of Masson's stain in blood sinusoids from 6 to 24 months age groups, then the increase was minimal or plateau. This means fibrosis present in liver sinusoids. This fibrosis increased with age till the age of 24 months with no further increase in other age groups. Gerontology and Geriatrics Research. 2011; Article ID 439835, 7 Pages doi:10.1155/2011/439835.

Tenascin c was increased (up-regulated) with the appearance and increase of fibrosis but when fibrosis was established Tenascin c decreased (down-regulated) again.

Upon liver injury, HSCs trans-differentiate from an adipogenic like a cell to that of a highly contractile, proliferative, myofibroblasts like a cell with an increase in the secretion of ECM proteins, including collagens and Tenascins. Tenascin C (TnC), an ECM glycoprotein, is minimally detected in healthy tissue, but is transiently expressed during tissue injury, and plays a role in fibrogenesis and tumorigenesis. In liver disease and is up regulated in fibrotic areas and perisinusoidal spaces, with HSCs being the primary cellular source. Conversely, TnC deficiency attenuates the development of fibrosis.<sup>15</sup>

Swati et al.<sup>16</sup> found that levels of Tenascin-C and fibrosis are elevated in systemic sclerosis SSc skin biopsy samples, and serum and SSc fibroblasts, and in fibrotic skin tissues from mice. Exogenous tenascin-C stimulates collagen gene expression and myofibroblasts transformation. Mice lacking Tenascin-C show attenuation of skin and lung fibrosis, and accelerated fibrosis resolution. These results identify tenascin-C as an endogenous danger signal that is up-regulated in SSc and by its persistence impedes fibrosis resolution.<sup>16</sup>

In agreement with our study, El-Karef et al.<sup>17</sup> used immunohistochemistry and quantitative real-time PCR and they observed that large variants of Tenascin-C were not expressed in normal liver, but were up-regulated in chronic hepatitis, especially at sites of interface hepatitis and confluent necrosis, showing stronger correlations between staining intensity and these than with other parameters or fibrosis. TN-C deposition was closely correlated with an increase in the number of  $\alpha$ -smooth muscle actin positive cells, i.e. activated HSCs/myofibroblasts, and in situ hybridization showed TN-C mRNA signals in the cells. Activated HSCs and myofibroblasts in a culture highly expressed large variants of TN-C. It was concluded that TN-C and its variants are produced by HSCs/ myofibroblasts, suggesting important roles in liver fibrogenesis.<sup>17</sup>

## CONCLUSION

Tenascin-C is an extracellular matrix protein upregulated with the formation and deposition of fibrosis in space of Disse of hepatic sinusoids of the albino rats. When fibrosis is formed, Tenascin-c is down-regulated again.

## REFERENCES

1. López-Otín C, Blasco M, Partridge L, et al. *Cell*. 2013;153(6):1194–217.
2. Nicholas J, Sun K, Glen P, et al. Hallmarks of Aging in the Liver. *Computational and Structural Biotechnology Journal*. 2019;17: 1151–61.
3. Alessandra W, Victoria C, Robin F, et al. The Effects of Old Age on Hepatic Stellate Cells. Hindawi Publishing Corporation Current
4. Vivero-Escoto JL, Vadarevu H, Juneja R, Schrum, Laura W, et al. Mediated silencing of Tenascin C in hepatic stellate cells: effect on inflammatory gene

- expression and cell migration. *J Mater Chem B*. 2019 Dec 14; 7(46): 7396-7405.
5. Midwood K, Matthias C, Richard P, et al *Journal of Cell Science*. 2016; 129: 4321-4327 doi:10.1242/jcs.190546
6. Ahsani D and Fidianingsih I. Age-related changes of malondialdehyde, body weight and organ weight in male mice. *Univ Med*. 2018; 37:115-26. doi: 10.18051.
7. Rania N. sheriff. Effect of cerebrolysin on the cerebellum of rats: An immunohistochemical study. *Tissue and Cell*. 2017; 49:726-733. <http://dx.doi.org/10.1016/j.tic.2017.10.006>.
8. Fabio G, Giuseppe Di Caro L, Paul H, et al. Mast cells and the liver aging process. *Immunity & Ageing*. 2013; 9.
9. Ying P, Yunen L, and Xiaodong X. et al. Change Trends of Organ Weight Background Data in Sprague Dawley Rats at Different Ages. *J Toxicol Pathol* 2013; 26: 29–34. doi: 10.1293/tox.26.29.
10. Miler M, Vladimir A, Jasmina Ž, et al. Old age-associated impairment of the rat liver antioxidant defense system: the basis for affirmation of the experimental model. *Turk J Vet Anim Sci*. 2019; 43: 423-426. doi:10.3906/vet-1812-39.
11. Eveliina U, Sirkku L, Paula H, et al. Longitudinal changes in serum lipids in older people The Turku cells/myofibroblasts in chronic hepatitis C. *J Hepatol*. 2007. doi: 10.1016/j.jhep.2006.10.011.
- Elderly Study 1991–2006. *Age and Ageing*. 2011; 40: 280–283.
12. Niedernhofer L, Daniels J, Rouzer C, et al. Malondialdehyde, a product of lipid peroxidation, is mutagenic in human cells. *J Biol Chem*. 2003;278(33):31426–31433. 15.
13. Maeso-Díaz R, Ortega-Ribera M, Fernández-Iglesias A, et al. Effects of aging on liver microcirculatory function and sinusoidal phenotype. *Aging Cell*. 2018;17. doi.org/10.1111/accel.12829.
14. Finkel T. and Holbrook N. Oxidants, oxidative stress and the biology of aging. *Nature*. 2000; 408:239-247.
15. Juan E, Hemapriyadarshini V, Ridhima J, et al. Nanoparticle mediated silencing of tenascin C in hepatic stellate cells: effect on inflammatory gene expression and cell migration. *J. Mater. Chem. B*. 2019; 7: 73-96. doi: 10.1039/c9tb01845j.
16. Swati B, Wenxia W, Luisa M, et al. Tenascin-C drives persistence of organ fibrosis. *Nature Communication*. 2016 | doi: 10.1038/ncomms11703.
17. El-Karef A, Masahiko K, Hideaki T, et al. Expression of large tenascin-C splice variants by hepatic stellate. *J Hepatol*. 2007 Apr;46(4):664-73. Epub 2006 Nov 27.