

The Added Value of Dynamic Contrast Enhanced MRI Semiquantitative Parameter in Discrimination of Ovarian Lesions

AHMED S. ABDELRAHMAN, M.D. and AHMED M. BASSIOUNY, M.D.

The Department of Radiology, Faculty of Medicine, Ain Shams University

Abstract

Background: Ovarian tumors are one of the most common women cancers. The high vascularity of malignant ovarian tumors can be assessed by the dynamic contrast enhanced MRI allowing preoperative characterization of ovarian lesions which help for planning the proper surgical management.

Aim of Study: To evaluate the role of semiquantitative parameters of the dynamic contrast enhanced MRI in differentiation of ovarian lesions.

Material and Methods: 25 patients with complex or solid ovarian lesions underwent dynamic contrast enhanced MRI (DCE MRI). The semiquantitative parameters including maximum relative enhancement percentage (MRE%) and time to peak (T_{max}) as well as the type of time intensity curve (TIC) were analyzed and compared to the histopathological results.

Results: The MRE% was higher for malignant ovarian tumors than for benign ($p < 0.001$) and for borderline lesions ($p = 0.002$). The T_{max} was earlier in malignant ovarian tumors than in benign ($p < 0.001$) and in borderline ovarian masses ($p = 0.019$). TIC Type III was specific for invasive malignant tumors. The DCE MRI maximal accuracy was 88.2.

Conclusion: The semiquantitative parameters of DCE MRI had increased the accuracy and sensitivity of MRI for discrimination between malignant, borderline and benign ovarian lesions.

Key Words: DCE MRI – TIC – MRE% – T_{max} .

Introduction

OVARIAN masses are one of the leading indications for surgery in women [1], and it involves a heterogeneous group of malignant, benign and borderline neoplasms, resulting in diagnostic challenges [2,3]. The preoperative accurate characterization of the complex ovarian masses is crucial for defining the optimal surgical strategy and the subsequent conservative treatment feasibility [4].

The differentiation of borderline and invasive tumors is very important as borderline ovarian

tumors are associated with lower recurrence rate and high survival rate. This is particularly important for young women so conservative surgery and fertility preservation can be offered for them [5-7].

Ultrasonography is the first-line investigation for suspected ovarian tumors, yet it is less accurate for discrimination of complex or indeterminate masses [8,9].

The high tissue contrast of conventional MRI help in detecting morphological features of the ovarian lesion including papillary projections, solid region, and thickened irregular septa, which are suggestive of malignancy [10,11].

However, some overlapping features among ovarian tumors are still existed. The dynamic contrast enhanced MRI (DCE-MRI) assess the tumor vascularity and perfusion, thus allowing semiquantitative analysis and more discrimination of the ovarian tumors [12].

The aim of this study was to assess the validity of the MRI dynamic contrast enhanced semiquantitative parameters in the differentiation between malignant, borderline and benign ovarian lesions.

Material and Methods

Patients:

This prospective study was included 25 women presenting with ovarian lesions which was diagnosed by ultrasound examination, and referred from the Obstetrics & Gynecology Department to the Radiology Department, Ain Shams Hospital during the period from November 2017 till December 2018, the patients mean age was 45.36 ± 12.76 years (range from 23 to 64 years), an informed consent was obtained from all patients according to the rules of ethical committee.

Correspondence to: Dr. Ahmed S. Abdelrahman,
E-Mail: dr_ahmedsamy@yahoo.com

Inclusion criteria:

- 1- Solid or complex ovarian masses.
- 2- Very large cystic ovarian lesion

Exclusion criteria:

- 1- Purely cystic ovarian lesion.
- 2- Contraindications to MRI or contrast media.

*Study tools:**1- Preliminary ultrasound:*

A preliminary pelvic ultrasound examination was done to all patients before DCE MRI to exclude simple cystic ovarian lesion. A trans abdominal and/or transvaginal ultrasound examination was performed using (LOGIQTM P7, GE Healthcare) using 3-5 and 7-10MHz probes.

2- MRI examination:

All patients underwent MRI on 1.5 T MRI Philips Achieva scanner using pelvic phased-array coil and it included conventional and dynamic contrast enhanced MRI.

The conventional MRI study involved:

- Axial T1 WI (TR=550ms, TE=24ms) and axial T2 WI (TR=7645ms, TE=115ms) with 6mm slice thickness, 1mm gap, 320-380mm field of view (FOV) and 256 x 256 matrix.
- Sagittal T2 WI and coronal T2 WI with 8-10mm slice thickness, 1mm gap, 400-500mm FOV, and 256 x 256 matrix.
- Axial T1 WI spectral pre-saturation inversion recovery images (TR=550ms, TE=24ms, 5mm slice thickness, 0.5- to 1.0-mm gap, 256 x 192 matrix, flip angle=90° and FOV=320-380mm.

Dynamic contrast enhanced MRI:

Dynamic Post contrast T1 THRIVE (High Resolution Isotropic Volume Examination) images were obtained immediately after the gadolinium was injected at a dose of 0.1mmol/kg of body weight and rate of 1.5ml-sec followed by injection of 20ml of saline to flush the contrast. The dynamic study has consisted of 6 phases, the first one was the baseline pre contrast phase, then it was followed by contrast injection, with starting the others five phases after bolus injection, the duration of each post contrast phase was about 20-25 sec (according to selected FOV), and the duration of the whole dynamic sequence was about 2-3min. The parameters of each phase were TR=3.9ms, TE=1.78ms, 6/-1mm slice thickness, 320-380mm FOV, 10° flip angle, and 144 x 144 matrix.

After the dynamic images were obtained an axial, coronal and sagittal T1 weighted delayed post contrast images were also acquired.

Post processing techniques for DCE-MRI:

The dynamic contrast-enhanced MR images were analyzed by the aid of Philips IntelliSpace Portal Image and information management software V 9.0. (Philips Medical System Nederland B.V). A region of interest is manually drawn over the most avidly enhancing solid lesion, thick enhanced wall or enhancing septations, the time intensity curve was automatically performed, then the enhancement amplitude, as well as the initial peak of uptake, was also automatically calculated.

Data interpretation:

The morphological features of each lesion in Conventional MR were analyzed according to size, bilaterally, border, signal characteristics at T1 WI and T2 WI. Features suggestive of malignancy included: Solid mass, large solid component (>6mm) in cystic lesion, vegetations or nodularity in cystic lesion, walls and septa thickening more than 3mm, large lesion more than 6cm, necrosis, hemorrhage and regions of marked enhancement. Features of malignant tumor spread included: Pelvic and/or para aortic lymph nodes, pelvic wall infiltration, involvement of other pelvic organs, peritoneal and/or omental deposit and ascites [13].

The post processing DCE MRI was evaluated regarding the time intensity curve (TIC), enhancement amplitude and the time of initial peak of uptake (T_{max}).

The time intensity curve showed three patterns: Type I which had a gradual increase in its signal intensity without a well-defined shoulder, Type II curve which had a moderate earlier rising yet the enhancement of lesion still later than that of myometrial enhancement and it was followed with plateau, and Type III which had a rapid steep rising so the curve of lesion was shifted to occur earlier than the myometrial curve and it may be followed by washout or even plateau [14].

The enhancement amplitude of the lesion was expressed as maximum relative enhancement percentage (MRE%), and it is calculated by the equation (signal intensity after contrast injection - signal intensity before contrast injection) / baseline signal intensity pre contrast injection [15].

The time of initial peak of uptake (T_{max}) and it was usually defined as early initial peak (peak occurred in the early two phases of dynamic study

after contrast injection), and delayed peak (peak delayed to the last phases of dynamic study).

The pathology of ovarian tumors suggested by the conventional MR examination and DCE MRI analysis, whether benign or malignant (which included malignant invasive and borderline) was correlated with the histopathological result, and in case of bilateral lesion, the more malignant looking lesion was analyzed to reduce intra-individual bias.

Statistical analysis: The data analysis was done using computer programs SPSS (version 15 for Microsoft Windows). Data were expressed as Mean ± SD for quantitative parametric measures in addition to frequencies (number of cases) and percentages when appropriate. For comparing categorical data, X² test was performed. Diagnostic validity tests were used, including diagnostic sensitivity, specificity, and accuracy. *p*-values less than 0.05 was considered statistically significant.

Results

Twenty-five patients with a solid/complex adnexal lesion underwent DCE MRI. No adverse events occurred during the MRI examination. No statically significant difference regarding patient means age between different pathological groups, the mean age for benign lesions was 39 ± 14 years, for borderline tumor was 47 ± 12 years and for malignant tumors was 48 ± 11 years.

The histopathological result of ovarian lesions was classified into 8 benign and 17 malignant tumors (14 malignant invasive and 3 borderline tumor tumors). Benign lesions included 2 endometriomas, 2 mature cystic teratomas 2 tubo-ovarian abscesses, 1 fibrothecoma, and 1 serous cystadenoma. Borderline tumors included 1 serous cystadenofibroma, 1 mucinous cystadenoma and 1 serous cystadenoma. Malignant invasive tumors included 6 serous cystadenocarcinoma, 4 mucinous cystadenocarcinomas, 2 immature cystic teratomas, 1 dysgerminoma and 1 granulosa cell carcinoma. Table (1).

Analysis of ovarian tumors by conventional MRI study:

17 cases were diagnosed as malignant tumors (malignant invasive and borderline tumor) by their morphological features in the conventional MRI, yet the reference histopathological results revealed that 12 of 17 were malignant invasive (TP), 2 were borderline tumors (TP) and 3 were benign lesions (FP) (1 tubo-ovarian abscess, 1 serous cystadenoma and 1 mature cystic teratoma).

8 cases were diagnosed by the conventional MRI morphological features as benign lesions, 5 of them were true benign (TN), while 3 cases were malignant and diagnosed as benign lesions (FN). (1 immature teratoma, 1 serous cyst adenofibroma and 1 serous cystadenocarcinoma). Table (2).

Analysis of ovarian tumors by DCE-MRI:

Curve type:

The type III curve was noted in 10 cases, all of them were malignant invasive tumors yielding 100% specificity, while type I curve was noted in 8 cases; 6 were benign lesions, 1 was borderline lesion and 1 was malignant invasive tumor, lastly type II curve was seen in 7 cases with overlying distribution between benign (2 lesions), borderline (2 lesions) and malignant invasive lesions (3 lesions). Table (3).

The semi quantitative analysis:

The MRE% mean value of malignant invasive tumor was 135% ± 67 which was significantly higher than benign (75% ± 45) (*p*<0.001), and borderline lesions (95% ± 51) (*p*<0.002). The T_{max} was significantly of shorter duration in malignant invasive tumor with mean value of 60 ± 11 sec compared to mean value of benign (150 ± 16 sec) (*p*<0.001), and borderline lesions (110 ± 13 sec) (*p*<0.019). No significant difference was noted in the MRE% and T_{max} between the benign and borderline lesion (*p* 0.775 and 0.638 respectively). Tables (4,5). Figs. (1-3).

Table (1): The histological types of ovarian lesions in our study.

Pathological	Pathological type	No.	%
Benign	Endometriomas	2	8.0
	Fibrothecoma	1	4.0
	Mature cystic teratoma	2	8.0
	Serous cystadenoma	1	4.0
	Tubo-ovarian abscess	2	8.0
Borderline	Mucinous cystadenoma	1	4.0
	Serous cystadenofibroma	1	4.0
	Serous cystadenoma	1	4.0
Malignant invasive	Dysgerminoma	1	4.0
	Granulosa cell carcinoma	1	4.0
	Immature cystic teratoma	2	8.0
	Mucinous cyst adenocarcinoma	4	16.0
	Serous cyst adenocarcinoma	6	24
Total		25	100

Table (2): The results of conventional MRI as compared to histopathological results.

Results of conventional MRI	Malignant (Invasive & Borderline) (N=17)	Benign (N=8)	Sens.	Spec.	PPV	NPV	Accuracy
Malignant	TP=14	FP=3	82.4%	62.5%	82.4%	62.5%	76.0%
Benign	FN=3	TN=5					

Table (3): Comparison between histopathological results and TIC.

TIC	Histopathological Results			X ²	p-value
	Benign (N=8)	Borderline (N=3)	Malignant Invasive (N=14)		
I	6 (75.0%)	1 (33.3%)	1 (7.1%)	17.028	0.002*
II	2 (25.0%)	2 (66.7%)	3 (21.4%)		
III	0 (0.0%)	0 (0.0%)	10 (71.5%)		

Table (4): Comparison between MRE% & T_{max} values and the histopathological results.

	Histopathological Results			p-value
	Benign (N=8)	Borderline (N=3)	Malignant (N=14)	
MRE% (Mean±SD)	75%±45	95%±51	135%±67	<0.001
T _{max} (Mean±SD)	150±16	110±13	60±11	<0.001

Table (5): Diagnostic performance of MRE% and T_{max} in discrimination between different ovarian pathology.

	p-value	
	MRE%	T _{max}
Malignant invasive vs Benign	<0.001	<0.001
Malignant invasive vs Borderline	0.002	0.019
Benign vs borderline	0.775	0.638

The MRE% and T_{max} cutoff value for differentiating malignant (invasive & borderline) and benign lesions was 128% and 65 sec respectively. The MRE% had higher sensitivity than T_{max} for the differentiation between malignant ovarian tumors and benign lesions (88% sensitivity for MRE% and 85.7% sensitivity for T_{max}) as well as

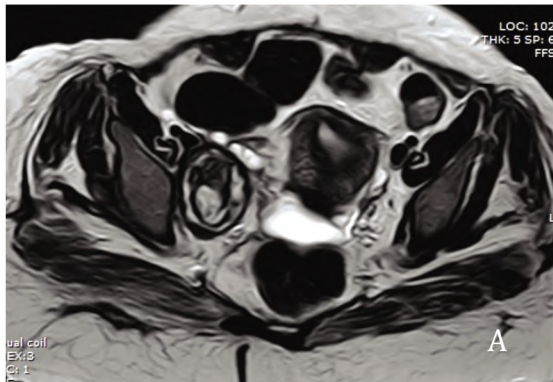
for discrimination between malignant invasive ovarian tumors and borderline tumors (92% sensitivity for MRE% and 85.7% sensitivity for T_{max}), yet the TIC type III showed the highest specificity (100%) for characterization of malignant invasive tumor. Tables (6,7).

Table (6): The diagnostic performance of the cutoff value of MRE% and T_{max} in differentiating between malignant (malignant invasive and borderline) & benign lesions.

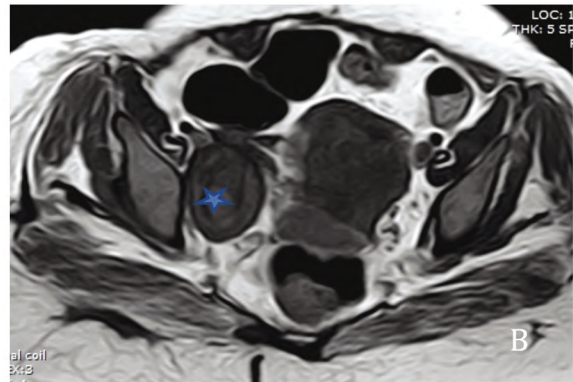
	Histopathological		Sens.	Spec.	PPV	NPV	Accuracy
	Malignant (Invasive & Borderline)	Benign					
MRE%:							
>128%	TP=15	FP=1	88%	87.5%	93.7%	77.7%	88%
<128%	FN=2	TN=7					
T _{max} :							
<65 sec	TP=14	FP=1	85.7%	87.5%	92.3%	77.8%	86.4%
>65 sec	FN=3	TN=7					

Table (7): The diagnostic performance of the cutoff value of MRE% & T_{max} in discrimination between malignant invasive & borderline lesions.

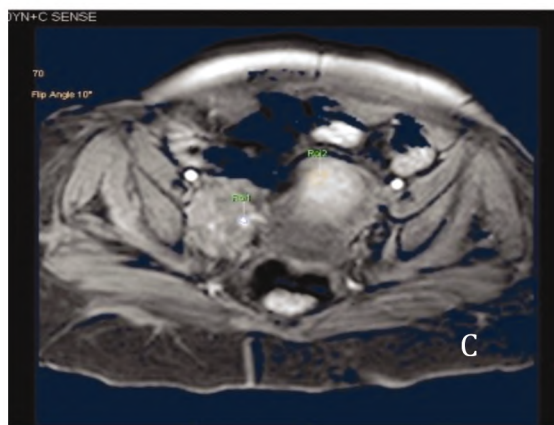
	Histopathological		Sens.	Spec.	PPV	NPV	Accuracy
	Malignant Invasive	Borderline					
MRE%:							
>128%	TP=13	FP=1	92%	66.7%	92.9%	66.7%	88.2%
<128%	FN=1	TN=2					
T _{max} :							
<65 sec	TP=12	FP=1	85.7%	66.7%	92.3%	50.0%	82.4%
>65 sec	FN=2	TN=2					



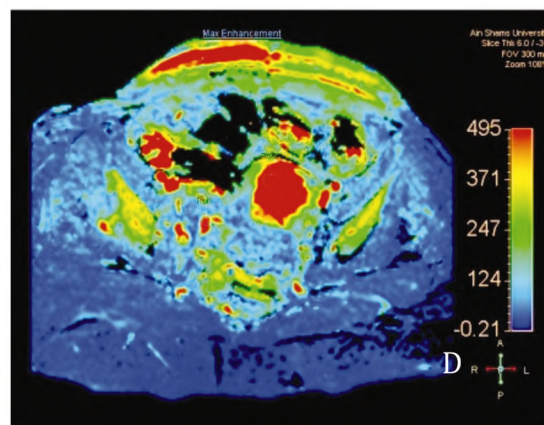
(A)



(B)



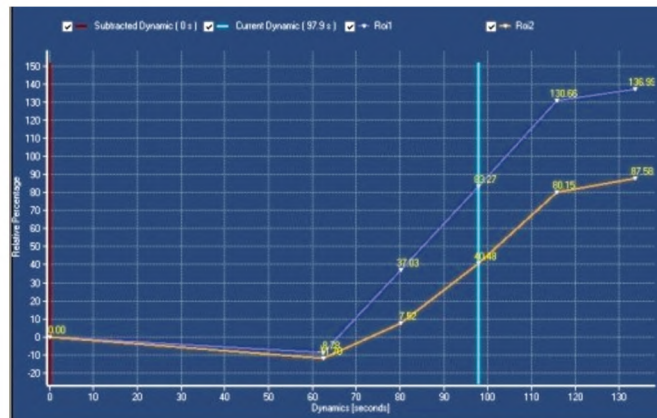
(C)



(D)

Pixel Location		
Patient frame (mm):	-31.3 , 112.6 , 50.5	
Image frame:	214 , 85	
	ROI2	ROI1
Rel Enhancement (%) :	40.48	83.27
Max Enhancement :	790.57	1113.74
Max Rel Enhancement (%) :	90.23	147.87
Time To Peak (s) :	133.55	133.55
T0 (s) :	80.18	62.41
Wash In Rate (s ⁻¹) :	19.82	20.99
Wash Out Rate (s ⁻¹) :	0.00	0.00
Brevity of Enhancement (s) :	0.00	0.00
Area under the curve :	27253.17	46621.58
Roi Area (mm ²) :	59.88	13.65

(E)



(F)

Fig. (1): Right ovarian granulosa cell carcinoma in a 41 years old female.

(A, B) Axial T2 WI and T1 WI showed right ovarian well-defined solid lesion (star) with mixed T2 high and intermediate signal. A combined figure that included THRIVE image (C), maximal enhancement color-coded image (D), semiquantitative parameters (E) and TIC (F) of both ovarian lesion (blue) and uterus (light brown), and it displayed patchy post contrast enhancement, high MRI% measuring 147%, early uptake of contrast with T_{max} duration was 62 sec, and Type III curve pattern (steeper ovarian lesion curve as compared to uterine curve).

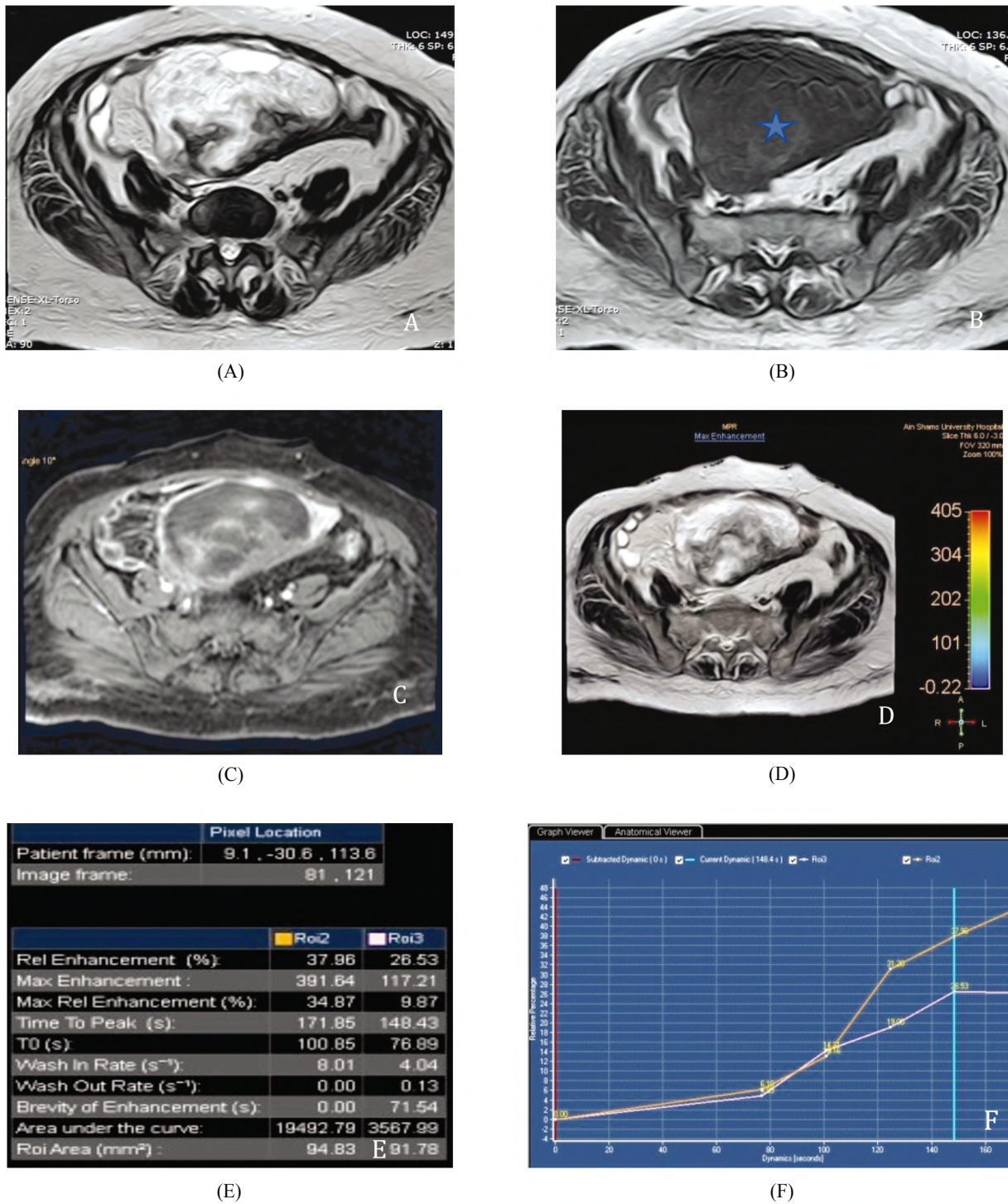
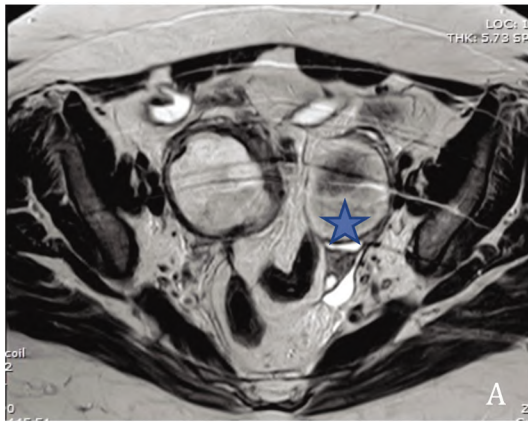
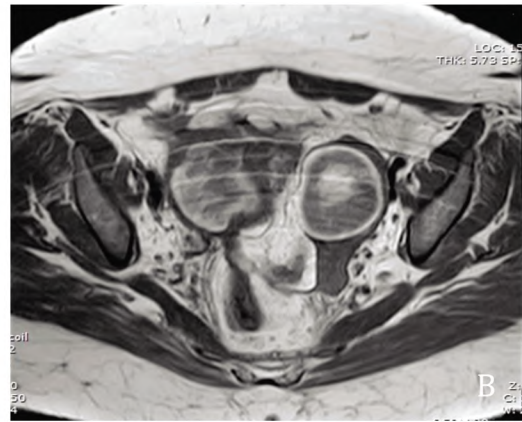


Fig. (2): Right ovarian fibrothecoma (benign lesion) in a 58 years old female.

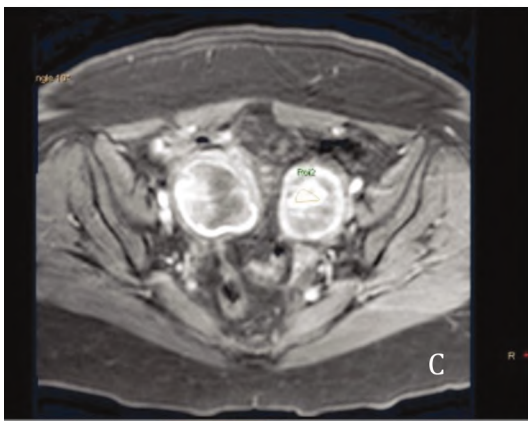
(A, B) Axial T2 WI and T1 WI showed right ovarian heterogeneous mass lesion displaying low signal intensity in T1WI and heterogenous high and low signal in T2WI (star). A combined figure that included THRIVE image (C), maximal enhancement color-coded image (D), semiquantitative parameters (E) and TIC (F) of ovarian mass (pink) and uterus (light brown) (lower left), it revealed patchy enhancement, low MRI% measuring 10%, late uptake of contrast and the T_{max} duration was 148 sec, and Type I curve pattern (uterine curve is steeper than ovarian lesion curve).



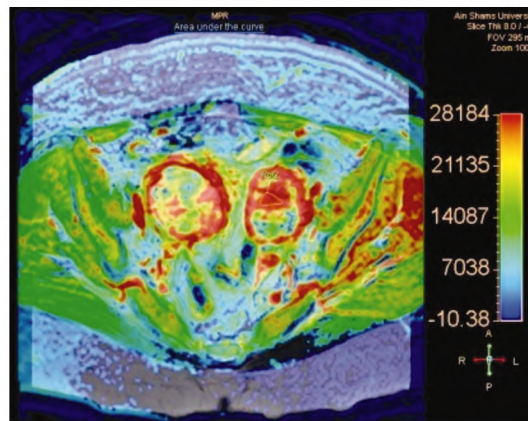
(A)



(B)



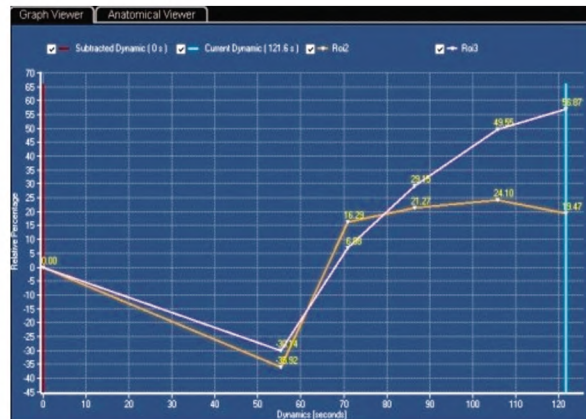
(C)



(D)

Subtracted - 11, 1: THR DYN+C SENSE		Table View	
		Pixel Location	
Patient frame (mm):		-53.1	94.7 , -29.9
Image frame:		220	75
		RoI2	RoI3
Rel Enhancement (%)		19.47	58.87
Max Enhancement		765.98	678.93
Max Rel Enhancement (%)		51.27	84.71
Time To Peak (s)		105.78	121.57
T0 (s)		55.39	55.39
Wash In Rate (s ⁻¹)		60.97	22.41
Wash Out Rate (s ⁻¹)		5.34	0.00
Brevity of Enhancement (s)		50.38	0.00
Area under the curve		38390.72	25430.10
RoI Area (mm ²)		82.18	142.67

(E)



(F)

Fig. (3): Bilateral ovarian borderline serous cystadenoma in a 47 years old female.

(A, B) Axial T2 WI and T1 WI showed bilateral ovarian cystic lesions with central solid region of high signal in T1 WI and intermediate to low signal in T2 WI (denoting hemorrhagic competent) which is prominent in the left ovarian lesion (star). A combined figure that composed of THRIVE (C), maximal enhancement image superimposed in T2 WI mask image(D), semiquantitative parameters (E), and TIC (F) of uterus (pink) and left ovarian mass (light brown) (lower left), it revealed peripheral ring and central area of enhancement, borderline MRI% measuring 51%, late uptake of contrast with T_{max} duration of 105 sec, and Type II plateau curve pattern.

Discussion

Although conventional MRI provide anatomical and morphological features of ovarian lesions through its high spatial and contrast resolution [12], yet the conventional MRI has insufficient value for discrimination between benign and borderline tumors [10,16], which is clinically important, as women with borderline ovarian tumors are young with relatively better prognosis, and a conservative surgery aiming to preserve their fertility could be considered for them [17].

Angiogenesis with the formation of new blood vessels is the cornerstone of tumor growth, progression, and invasion [18]. The malignant tumors are generally hypervascular with fragile immature vessels and increased permeability allowing the contrast agent to penetrate the interstitial space more quickly, whereas the benign tumors are most likely hypovascular having relatively mature vessels with no obvious change in tumor permeability [19]. Based on this different enhancement pattern, DCE-MRI could be used to assess the ovarian tumors microcirculatory perfusion and provide a useful tool for their discrimination through the time intensity curve (TIC) and the semiquantitative parameters [12,14].

Our result demonstrated that the type TIC curve was accurate for distinguishing malignant invasive ovarian tumor from benign ovarian lesion, and it demonstrated that type III TIC was not plotted in the benign ovarian lesion, yet it was detected only in the malignant invasive tumors with 100% specificity, similar result was concluded by the preliminary study done by Thomassin-Naggara et al., [14] Bernardin et al., [20] and Mansour et al., [21] as they demonstrated that type III TIC had a 100% specificity for invasive ovarian tumors.

Type II curve was seen in 7 cases in our study (28%) and it showed overlapped pathological distribution between the benign (2 cases), borderline (2 cases) and malignant invasive lesions (3 cases), Li et al., [22] also revealed that type II TIC was distributed between borderline, malignant invasive and benign lesions, and it was not specific for one of them.

Although the type I curve mostly was seen in the benign lesions, as it was seen in 6/8 (75%) of benign lesions and in 1/3 (33.3%) of borderline tumors yet the uneven distribution between borderline and benign ovarian lesions had compromised the usage of type I curve for discrimination between benign and borderline ovarian pathology, similar results was also concluded by Thomassin-

Naggara et al., [14] and Pegah et al., [23] who revealed that an overlapping in type I frequency between the benign and borderline ovarian lesions, had undermined type I curve for identification of benign ovarian lesions.

To improve the diagnostic performance of DCE MRI, a semiquantitative parameter was then analyzed which in conjunction with identification of TIC type had shown an improved diagnostic accuracy.

Our study revealed that the mean value of MRE% was significantly higher for malignant invasive tumor ($135\% \pm 67$) than benign ($75\% \pm 45$) and borderline lesions ($95\% \pm 51$), near similar results for borderline and benign ovarian lesions were also concluded by Thomassin-Naggara et al., [14] who showed that the enhancement amplitude (which was corresponding to MRE% in our study) was $187.7\% \pm 67.7$, $80.9\% \pm 43.2$ and $112.1\% \pm 58.8$ for malignant invasive, benign and borderline ovarian pathology respectively, yet the MRE% of malignant ovarian lesions was higher than that of our study, which was attributed to the fact that their study was involved only ovarian epithelial tumors, yet our study involved a diverse types of malignant ovarian tumors. Bernardin et al., [20] and Mansour et al., [21] also shown comparable results.

The estimated cutoff value of MRE% in our study between the benign and malignant tumors (malignant invasive and borderline) was 128% with sensitivity of 88% and specificity of 87.5%, close similar cutoff point was also concluded by Mansour et al., who revealed that MRE% cutoff value was 120%, with 88% sensitivity yet with lower specificity (71.4 % specificity), yet the cutoff value that was estimated by DeSouza et al., [24] and Thomassin-Naggara et al., [14] was lower, and they considered 114% as the MRE% cutoff between benign and malignant tumors, with sensitivity of 83% and specificity of 72%, the lower value of their study could be also attributed to that their study was limited to only the epithelial ovarian tumors.

In our study the T_{max} mean value was significantly shorter for malignant invasive ovarian tumor (60 ± 11 sec) than borderline (110 ± 13 sec) and benign ovarian lesions (150 ± 16 sec), and the estimated T_{max} cutoff value for malignant invasive tumors was 65 sec with maximal sensitivity of 85.7% and maximal specificity of 87.5%, similar results was concluded by Sohaib et al., [25] who revealed that early enhancement of 60 sec was

seen in malignant tumors. Thomassin-Naggara et al., [14] also considered $T_{1/2\max}$ of 29.7 seconds to be the cutoff value for malignant invasive tumor with maximum sensitivity of 92% and specificity of 79%. Nasr et al., [26] also concluded early uptake of 75sec as cutoff point for malignant tumor, yet Mansour et al., [21] revealed that T_{\max} was early (≤ 120 sec) in malignant ovarian tumors than in borderline and benign ovarian lesions, the differences in T_{\max} value in our study & other study and Mansour et al. [21] study was attributed to the more lengthy time of their dynamic study, as it was consistent of 7 post contrast phases and the whole duration of their dynamic study was about 5min and 30sec, yet our dynamic study was consisted of only 5 post contrast phases and the dynamic study duration was about 2-3min.

Thomassin-Naggara et al., [14] Bernardin et al., [20], Li et al., [22] and Mansour et al., [21] revealed that the MRE% value was higher in borderline tumors than in benign tumors, yet our study revealed that no significant difference in the MRE% and T_{\max} between the borderline and benign ovarian lesions which was also concluded by recent study performed by Thomassin-Naggara et al., [27] using DCE T1 permeability parameters, and it revealed that there was no significant difference in the quantitative parameters or perfusion heterogeneity value between the borderline and benign ovarian lesions.

In our study, the MRE% showed maximal sensitivity and accuracy (92 and 88.2 respectively) for characterization of ovarian lesions as compared to T_{\max} (85.7 and 86.4 respectively).

The semiquantitative parameters of DCE MRI increased the accuracy of MRI examination for characterization of ovarian lesion to reach 88.2% compared to 76% of the conventional MRI, similar result was also concluded by Nasr et al., who revealed that the accuracy of conventional MRI was 73.9% and it was increased to reach 77% for the DCE MRI.

Some limitations of our study included: (1) A sizable solid tissue is needed to generate the time intensity curve and subsequent semiquantitative parameters, and so the TIC was noisy or even can't be performed in small lesions. (2) The more or less variation on the semiquantitative parameter which was attributed to the interindividual variation in the perfusion kinetic owing to variable patient physiological and physical parameter, and it could be compensated by comparing the DCE MRI semiquantitative parameters of ovarian lesions to a standard reference as uterus, or other pelvic tissue.

Conclusion:

The DCE MRI semiquantitative parameters provide numerical value which increased the accuracy and sensitivity of MRI for discrimination between malignant invasive ovarian tumors and benign & borderline ovarian lesions, so adding a role for planning the optimal surgical management, especially in young women who in need to preserve their fertility.

References

- 1- CURTIN J.P: Management of the adnexal mass. *Gynecol. Oncol.*, 55 (3): 42-46, 1994.
- 2- KURMAN R.J., CARCANGIU M.L., HERRINGTON C.S., et al.: WHO classification of tumours of female reproductive organs. Lyon: IARC, 2014.
- 3- FOTI P.V., ATTINÀ G, SPADOLA S., CALTABIANO R., et al.: MR imaging of ovarian masses: Classification and differential diagnosis. *Insights Imaging*, 7 (1): 21-41, 2016.
- 4- MOHAGHEGH P. and ROCKALL A.G.: Imaging strategy for early ovarian cancer: Characterization of adnexal masses with conventional and advanced imaging techniques. *Radiographics*, 32 (6): 1751-73, 2012.
- 5- FAUVET R., BOCCARA J., DUFOURNET C., et al.: Laparoscopic management of borderline ovarian tumors: Results of a French multicenter study. *Ann. Oncol.*, 16: 403-410, 2005.
- 6- DARAI E., TULPIN L., PRUGNOLLE H., et al.: Laparoscopic restaging of borderline ovarian tumors. *Surg. Endosc.*, 21: 2039-2043, 2007.
- 7- MORICE P.: Borderline tumours of the ovary and fertility. *Eur. J. Cancer*, 42: 149-158, 2006.
- 8- KINKEL K., HRICAK H., LU Y., et al.: US characterization of ovarian masses: A meta-analysis. *Radiology*, 217: 803-811, 2000.
- 9- EKERHOVD E., WIENERROITH H., STAUDACH A., et al.: Preoperative assessment of unilocular adnexal cysts by transvaginal ultrasonography: A comparison between ultrasonographic morphologic imaging and histopathologic diagnosis. *Am J Obstet Gynecol.*, 184 (2): 48-54, 2001.
- 10- BAZOT M., NASSAR-SLABA J., THOMASSIN-NAGGARA I., et al.: R imaging compared with intraoperative frozen-section examination for the diagnosis of adnexal tumors; correlation with final histology. *Eur. Radiol.*, 16: 2687-2699, 2006.
- 11- THOMASSIN-NAGGARA I., BALVAY D., ROCKALL A., et al.: Added Value of Assessing Adnexal Masses with Advanced MRI Techniques. *Biomed Res. Int.*, 785206, 2015.
- 12- THOMASSIN-NAGGARA I., BAZOT M., DARAI E., et al.: Epithelial ovarian tumors: Value of dynamic contrast-enhanced MR imaging and correlation with tumor angiogenesis. *Radiology*, 248 (1): 148-159, 2008.
- 13- LI W., CHU C., CUI Y., et al.: Diffusion-weighted MRI: A useful technique to discriminate benign versus malignant ovarian surface epithelial tumors with solid and cystic

- components. *Abdominal Radiology*, 37 (5): 897-903, 2012.
- 14- THOMASSIN-NAGGARA I., CUENOD C.A., ROUZIER R., et al.: Dynamic Contrast-Enhanced Magnetic Resonance Imaging: A Useful Tool for Characterizing Ovarian Epithelial Tumors. *Journal of Magnetic Resonance Imaging*, 28: 111-120, 2008.
- 15- SOHAIB S.A., MILLS T.D., SAHDEV A., et al.: The role of magnetic resonance imaging and ultrasound in patients with adnexal masses. *Clin. Radiol.*, 60: 340-348, 2005.
- 16- HRICAK H., CHEN M., COAKLEY F.V., et al.: Complex adnexal masses: detection and characterization with MR imaging-multivariate analysis. *Radiology*, 214: 39-46, 2000.
- 17- HELPMAN L., BEINER M.E., AVIEL-RONEN S., et al.: Safety of ovarian conservation and fertility preservation in advanced borderline ovarian tumors. *Fertil Steril*, 104 (1): 138-144, 2015.
- 18- O'CONNOR J.P., JACKSON A., PARKER G.J., et al.: DCE-MRI biomarkers in the clinical evaluation of antiangiogenic and vascular disrupting agents. *Br. J. Cancer*, 96 (2): 189-95, 2007.
- 19- PATEL N., HARRIS A.L., GLEESON F.V., et al.: Clinical imaging of tumor angiogenesis. *Future Oncol.*, 8 (11): 1443-1455, 2012.
- 20- BERNARDIN L., DILKS P., LIYANAGE S., et al.: Effectiveness of semi-quantitative multiphase dynamic contrast-enhanced MRI as a predictor of malignancy in complex adnexal masses: Radiological and pathological correlation. *Eur. Radiol.*, 22: 880-890, 2012.
- 21- MANSOUR S.M., SARAYA S. and EL-FAISSAL Y.: Semi-quantitative contrast-enhanced MR analysis of indeterminate ovarian tumours: When to say malignancy? *Brit. J. Radiol.*, 88 (1053): 20150099, 2015.
- 22- LI H.M., QIANG J.W., MA F.H., et al.: The value of dynamic contrast-enhanced MRI in characterizing complex ovarian tumors. *J. Ovarian Res.*, 14; 10 (1): 4, 2017.
- 23- PEGAH M., ANDREA G. and ROCKALL G.: Characterization of adnexal masses with conventional and advanced imaging. *Techniques*, 32: 1751-73, 2012.
- 24- DeSOUZA N.M., O'NEILL R., MCINDOE G.A., et al.: Borderline tumors of the ovary: CT and MRI features and tumour markers in differentiation from stage I disease. *AJR Am. J. Roentgenol.*, 184: 999-1003, 2005.
- 25- SOHAIB A., SAHDEV A., VAN TRAPPEN P., et al.: Characterization of Adnexal Mass Lesions on MR Imaging. *American Journal of Roentgenology*, 180: 1297-1304, 2003.
- 26- NASR E., HAMED I., ABBAS I., et al.: Dynamic contrast enhanced MRI in correlation with diffusion weighted (DWI) MR for characterization of ovarian masses. *EJRN*, 45: 975-985, 2014.
- 27- THOMASSIN-NAGGARA I., SOUALHI N., BALVAY D., et al.: Quantifying tumor vascular heterogeneity with DCE-MRI in complex adnexal masses: A preliminary study. *J. Magn Reson Imaging*, 46 (6): 1776-1785, 2017.

دور التصوير بالرنين المغناطيسي مع استخدام التصوير الديناميكي بالصبغة في تمييز أمراض المبايض المختلفة وذلك بإستخدام العوامل الكمية

يعتبر ورم المبيض واحداً من أكثر أنواع السرطان شيوعاً بين النساء، ومن مميزات التصوير بالرنين المغناطيسي المعزز بالتباين الديناميكي إمكانية تقييم الأوعية الدموية لأورام المبيض مما يسمح بتحديد نوع الورم ويساعد على اختيار العملية الجراحية المناسبة لكل حالة مرضية.

الهدف: تهدف هذه الدراسة إلى تقييم دور التصوير الديناميكي بالصبغة بإستخدام الرنين المغناطيسي في تحديد الأنواع المختلفة لأورام المبيض.

المرضى وطريق البحث: لقد خضعت ٢٥ مريضة تعاني من وجود تورم بالمبيض إلى فحص التصوير الديناميكي بالصبغة بإستخدام الرنين المغناطيسي وقد تم مقارنة نتائج التشريح النسيجي مع النتائج الكمية للتصوير الديناميكي مثل نسبة الصبغة النسبية ومنحنى تباين الصبغة مع الوقت.

النتائج: لقد كانت نسبة الصبغة النسبية أعلى في أورام المبيض الخبيثة مقارنة بأمراض المبيض الحميدة وقد وصلت نسبة دقة التصوير بالرنين المغناطيسي مع استخدام التصوير الديناميكي بالصبغة إلى ٨٨.٢٪.

الاستنتاج: لقد أدى التصوير بالرنين المغناطيسي مع استخدام التصوير الديناميكي بالصبغة إلى زيادة دقة وحساسية التصوير بالرنين المغناطيسي التقليدي في التمييز بين أورام المبيض الخبيثة والحميدة.