

Ultrasound Guided Radiofrequency Ablation of the Suprascapular Nerve Versus Injection Block Technique: A Comparative Study in Patients with Chronic Shoulder Pain

AHMED M. BASSIOUNY, M.D. and AHMED S. ABDELRAHMAN, M.D.

The Department of Radiology, Faculty of Medicine, Ain Shams University, Cairo, Egypt

Abstract

Background: Chronic shoulder pain affects the quality of life and limits daily activities. Suprascapular nerve block is an effective technique in management of chronic shoulder pain. Suprascapular injection technique had several drawbacks particularly repeated injections that may affect the patients' outcomes. RFA is considered a safe technique especially with ultrasound guidance, having a long duration of action with absence of any complications or organ damage.

Aim of Study: This study aimed to examine the effectiveness of radiofrequency ablation (RFA) of the suprascapular nerve in comparison to the injection of lidocaine and hydrocortisone mixture under ultrasound guidance.

Patients and Methods: 20 patients with chronic shoulder pain were divided in to two equal groups one group was submitted to RFA of the suprascapular nerve using the Cool-Tip RF system and an internally cooled electrode (group A) and the other group had lidocaine and hydrocortisone mixture injection (group B) of the same nerve, both groups were followed-up over a period of 6 months with pre and post interventional assessment of the pain through visual analogue score for pain (VAS).

Results: All patients had chronic shoulder pain not responding to medical treatment and physiotherapy, after RFA, 6 patients were pain free, 4 cases had mild pain that responded to conservative treatment, regarding those of the injection group all cases had relief for 3 months, at 6 months, only 3 had no complain while 4 patients had recurrence and 3 had stationary course of pain relief.

Conclusion: RFA proved to be a superior technique compared to the injection method in management of chronic shoulder pain.

Key Words: Chronic shoulder pain – Radiofrequency – Ultrasound guided – Injection – Suprascapular nerve.

Introduction

CHRONIC shoulder pain affects the quality of life and limits daily activities [1]. Suprascapular

nerve block is an effective technique in management of chronic shoulder pain as well as acute pain in postoperative or posttraumatic conditions [2].

It is used by many specialties as rheumatology, orthopedics, neurologists and anesthesia [3-5].

Suprascapular injection technique had several drawbacks particularly repeated injections that may affect the patient's compliance, increase risk of infection, nerve trauma, intravascular injection and the prolonged use of steroids side effects [6].

About 30 years ago RFA was discovered which is an effective, time saving technique with satisfactory results in controlling cases of chronic shoulder pain, particularly in targeting the suprascapular nerve due to its extensive nerve supply of the shoulder [6,7].

RFA is considered a safe technique specially with ultrasound guidance, having a long duration of action with absence of any complications or organ damage [8].

Patients and Methods

Patients:

20 patients were reviewed in orthopedic outpatient clinic of Ain Shams University Hospitals having chronic shoulder pain due to various causes as frozen shoulder, rotator calf tendon tears, tendinosis and arthritis, and were referred to our musculoskeletal interventional radiology unit.

They were divided randomly into two equal groups (group A) in which the patients were treated by RFA of the suprascapular nerve and (group B) where its patients were injected by local anesthetic and steroids.

Correspondence to: Dr. Ahmed M. Bassiouny,
E-Mail: Ahmed_bassiouny@hotmail.com

15 patients were females and 5 males with age ranging from 47 to 55 years.

The study was performed between March 2018 and June 2019.

Patients enrolled in our study are those who did not respond to their regular medical treatment and physiotherapy for at least 3 months and were eligible for our study. On the other hand, patients above 55 years or those who responded to their regular medical treatment and physiotherapy in less than 3 months were excluded from the study.

Pain degree was assessed by visual analogue score (VAS), that represents a scale from 1 to 10 from least to severe pain (Table 1).

After approval of our research ethical board, written consent was taken from the patients with the details of both procedures regarding each group with their possible outcomes and complications.

Methods:

All patients underwent an ultrasound examination for evaluation of the suprascapular notch and exclusion of any pathological lesions, patients were examined in sitting position, probe was placed just below the spine of scapula with mild rotation till the suprascapular notch is visualized (Fig. 1A).

A sterile field was prepared, then a 1ml 10% xylocaine was administered prior needle insertion at site of puncture.

Regarding (group A) patients are in sitting position, only two cases were treated in prone position due to difficulty in maintaining proper sitting in upright state.

The radiofrequency needle was inserted in the suprascapular notch under ultrasound guidance of 13Mhz probe (Aplio 400, Toshiba, JAPAN), Doppler was used to avoid the suprascapular vessels (Fig. 1B), and insure the proper position of the needle (Fig. 2).

RFA was performed using our machine Neurotherm NT1100 (Neurotherm, USA), the ablation time was 240 seconds by 50V and 240 pulse.

Patients were observed for 30 minutes after the ablation, another ultrasound was done prior to discharge to ensure the absence of any complications.

NSAID was prescribed postinterventional if necessary.

As for (group B) all of our patients were treated in sitting position, a 22G needle (Fig. 3) was inserted under ultrasound guidance, aspiration was done before injection to avoid direct intravascular injection, then injection of 5ml mixture of 0.5% bupivacaine and 1ml of isolated xylocaine was done [9,10].

In both groups some patients had slight paresthesia in shoulder and upper arm when the needle approaches the nerve, this ensures more the proper position of the needle.

None of our patients had complications during or after the procedures, however reported complications are injury to the suprascapular nerve and vessels, as well as pneumothorax [11].

Patients of both groups returned to their physiotherapy regimen after the procedure.

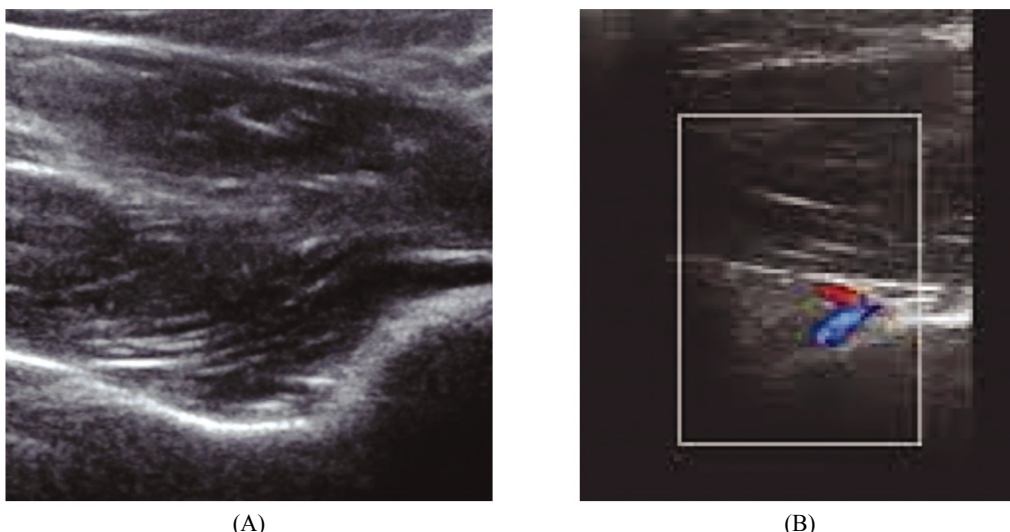


Fig. (1): Ultrasonographic image of the suprascapular fossa (A) and doppler study showing the vessels to avoid their injury during the procedure (B).

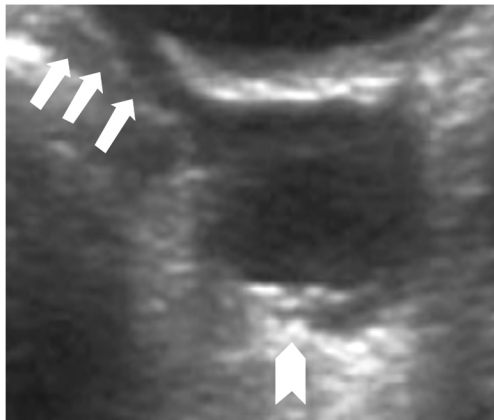


Fig. (2): 47 years female with chronic tendenosis, needle tip (arrows) is seen in suprascapular notch with injectant inside, the nerve and vessels (arrowhead) are seen away from the needle.

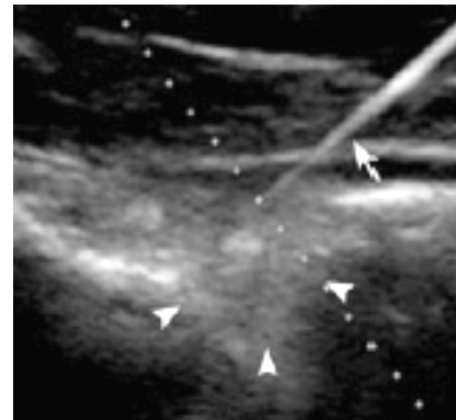


Fig. (3): RFA needle is seen in the suprascapular notch (arrow heads), in a 55 years female with history of adhesive capsulitis.

Results

This study included 20 patients, 15 (75%) women and 5 (25%) men, with age ranging between 47 and 55 years.

All patients suffered from chronic shoulder pain with average VAS of 8 (Table 1), pain duration was at least 3 months with no response to regular conservative treatment and physiotherapy.

Patients subjected to RFA (group A) and those performed nerve block injection (group B) were followed-up at 1,3 and 6 months.

Post-interventional outcomes in group A (Table 2) showed that 6 patients had complete resolution of pain (60%), the remaining 4 patients had mild pain (40%), regarding these 4 patients their pre-treatment VAS was severe in 3 of them (30%) while one (10%) complained of moderate pain, after treatment their VAS decreased to fall in mild pain zone, that was satisfactory for these patients

as they responded positively to their regular conventional treatment and physiotherapy.

In group B, (Table 3) all patients showed improvement in the first three months, but unfortunately at 6 months, 4 cases showed recurrence of pain, 3 of them (30%) showed recurrence of pain to same severe pre-treatment level, while 1 case (10%) showed a lesser extent being from mild to moderate, according to the VAS.

3 cases (30%) showed stationary course since the 3 months assessment, being 2 with mild pain and one with moderate pain 3 cases (30%) had no pain at 6 months (Table 4).

Table (1): Visual analogue scale (VAS) for pain grading.

0	1	2	3	4	5	6	7	8	9	10
No complain	Annoying		Uncomfortable/ distressing			Intense/ unbearable				
No pain	Mild pain		Moderate pain			Severe pain				

Table (2): Pain scoring of group A after RFA.

Patients numbers and age	Pre-treatment pain score	Pain score at 1 month post-treatment	Pain score at 3 months post-treatment	Pain score at 6 months post-treatment
1 (50 years)	5	4	3	0
2 (48)	6	2	0	0
3 (52)	7	4	2	2
4 (48)	5	2	0	0
5 (49)	4	2	0	0
6 (51)	6	3	3	2
7 (55)	9	8	4	3
8 (53)	7	3	0	0
9 (47)	8	5	3	2
10 (54)	6	3	2	0

Table (3): Pain scoring of group B after nerve block injection

Patients numbers and age	Pre-treatment pain score	Pain score at 1 month post-treatment	Pain score at 3 months post-treatment	Pain score at 6 months post-treatment
11 (52 years)	6	3	4	4
12 (49)	7	4	5	7
13 (47)	5	3	2	2
14 (48)	7	4	4	7
15 (49)	5	3	2	0
16 (47)	6	4	3	4
17 (52)	8	4	2	0
18 (48)	7	3	3	3
19 (49)	8	5	4	8
20 (54)	4	3	2	0

Table (4): Post RFA results in percentage at 6 months.

Pain degree	Group A	Group B
No pain	60%	30%
Mild	40%	20%
Moderate	0%	20%
Severe	0%	30%

Discussion

In patients of chronic shoulder pain, suprascapular nerve RFA and injections are the second line of treatment in case of failure of conservative management.

Interventional techniques may be used after failure of conservative therapy [12].

Both techniques under ultrasound guidance are considered safe. In our study we faced no complications, in literature pneumothorax accounts for less than 1% however, the usage of steroids in injection is still questionable regarding their side effects, especially in cases that need repeated sessions [6].

The main observation regarding the injection group is that only 30% of cases had no pain while 70% still had complain, 30% of these showed recurrence to the pretreatment VAS high scores after 6 months, and this proves that the injection method is effective for a short period of time and is not sustainable [13-15].

In literature the period between injections are variable ranging from once, to weekly or monthly visits, and the desired effect requires proper patient compliance [16].

As for RFA of the suprascapular nerve, it is a rapidly developing technique due to its longer effect in controlling shoulder pain [8].

Radiofrequency needles produce pulsed waves that neither causes damage to the target nor to the surrounding tissue [17-19].

In our study the ablation time was 240sec and we found that it was enough to completely resolve pain in 60% of cases, it also caused significant pain relief in 40%. A study performed by Luleci et al., had pain control over 78.9% of the cases over 480 sec of ablation per case [20].

As for Gurbet et al RFA was applied for 240 sec, and this was able to relief pain for about 3 months [21], our study stated it could be up to 6 months.

Ergonenc et al., in 2018 had a study on 74 patients that proved that RFA of the suprascapular nerve had rapid long standing positive results [22].

Suprascapular nerve ablation was performed by Jang et al., [23]. Under C-arm fluoroscopy guidance, as for Luleci et al., [20]. The study was performed blindly depending on the anatomical landmarks. We performed the ablation technique under ultrasound guidance, consequently reducing the complications, with higher success rate and a shorter time of the procedure.

As our patients were referred back to physiotherapy to complete their regimen, better compliance and tolerance of the patients was noted in both groups as far as the pain was controlled, this was more notable in the RFA group due to longer effect of pain control. Wu et al., [24] noticed the good response of the patients in his study to physiotherapy after the ablation, as it helped in pain reduction thus better performance with the physiotherapist.

A Limitation of our study is that we studied only the response to pain, but we did not assess the improvement of shoulder range of motion, also

the psychological factors that could contribute in pain assessment were not properly evaluated.

Conclusion:

Both suprascapular nerve RFA and guided therapeutic injection can control pain quickly, however RFA provides pain relief for a long period of time per session, unlike the therapeutic injection that may need several sessions due to its short-term effect. In chronic shoulder pain, both techniques can be applied safely with more satisfactory results noted in RFA. In order to verify our results additional large series and longer-term studies need to be conducted.

Financial support and sponsorship:

None.

Conflicts of interest:

There are no conflicts of interest.

References

- 1- MIASKOWSKI C., PAUL S.M., COOPER B., et al.: "Identification of patient subgroups and risk factors for persistent arm/shoulder pain following breast cancer surgery". *Eur. J. Oncol. Nurs.*, 18 (3): 242-53, 2014.
- 2- DAHAN T.H., FORTIN L., PELLETIER M., et al.: "Double blind randomized clinical trial examining the efficacy of bupivacaine suprascapular nerve blocks in frozen shoulder". *J. Rheumatol.*, 27 (6): 1464-9, 2000.
- 3- ALLEN Z.A., SHANAHAN E.M. and CROTTY M.: "Does suprascapular nerve block reduce shoulder pain following stroke: a double-blind randomised controlled trial with masked outcome assessment". *BMC Neurol.*, 10: 83, 2010.
- 4- FERNANDES M.R., BARBOSA M.A., SOUSA A.L., et al.: "Suprascapular nerve block: important procedure in clinical practice. Part II". *Rev. Bras. Reumatol.*, 52 (4): 616-22, 2013.
- 5- SHANAHAN E.M., SMITH M.D., WETHERALL M., et al.: "Suprascapular nerve block in chronic shoulder pain: Are the radiologists better?" *Ann. Rheum. Dis.*, 63 (9): 1035-40, 2004.
- 6- CHAN C.W. and PENG P. W.: "Suprascapular nerve block: A narrative review". *Reg. Anesth. Pain Med.*, 36 (4): 358-73, 2011.
- 7- ROHOF O.J.: "Radiofrequency treatment of peripheral nerves". *Pain Pract.*, 2 (3): 257-60, 2002.
- 8- KESKINBORA K. and AYDINLI I.: "[Long-term results of suprascapular pulsed radiofrequency in chronic shoulder pain]". *Agri.*, 21 (1): 16-21, 2009.
- 9- CHECCUCCI G., ALLEGRA A., BIGAZZI P., et al.: "A new technique for regional anesthesia for arthroscopic shoulder surgery based on a suprascapular nerve block and an axillary nerve block: An evaluation of the first results". *Arthroscopy*, 24 (6): 689-96, 2008.
- 10- KARATAS G.K. and MERAY J.: "Suprascapular nerve block for pain relief in adhesive capsulitis: Comparison of 2 different techniques". *Arch. Phys. Med. Rehabil.*, 83 (5): 593-7, 2002.
- 11- PITOMBO P.F., MEIRA BARROS R., MATOS M.A., et al.: "Selective suprascapular and axillary nerve block provides adequate analgesia and minimal motor block. Comparison with interscalene block". *Braz J. Anesthesiol.*, 63 (1): 45-51, 2013.
- 12- SCHULTZ J.S.: "Clinical evaluation of the shoulder". *Phys. Med. Rehabil Clin. N. Am.*, 15 (2): 351-71, 2004.
- 13- FREDRICKSON M.J., KRISHNAN S. and CHEN C.Y., et al.: "Postoperative analgesia for shoulder surgery: A critical appraisal and review of current techniques". *Anaesthesia*, 65 (6): 608-24, 2010.
- 14- BARBER, F.A.: "Suprascapular nerve block for shoulder arthroscopy". *Arthroscopy*, 21 (8): 1015, 2005.
- 15- PRICE D.J.: "The shoulder block: A new alternative to interscalene brachial plexus blockade for the control of postoperative shoulder pain". *Anaesth. Intensive Care*, 35: 575-581, 2007.
- 16- DAHAN T.H., FORTIN L., PELLETIER M., et al.: "Double blind randomized clinical trial examining the efficacy of bupivacaine suprascapular nerve blocks in frozen shoulder". *J. Rheumatol.*, 27 (6): 1464-9, 2000.
- 17- HAGIWARA S., IWASAKA H., TAKESHIMA N., et al.: "Mechanisms of analgesic action of pulsed radiofrequency on adjuvant-induced pain in the rat: Roles of descending adrenergic and serotonergic systems". *Eur. J. Pain*, 13 (3): 249-52, 2009.
- 18- CAHANA A., VAN ZUNDERT J., MACREA L., et al.: "Pulsed radiofrequency: Current clinical and biological literature available". *Pain Med.*, 7 (5): 411-23, 2006.
- 19- FUKUI S., NITTA K., et al.: "Intradiscal pulsed radiofrequency for chronic lumbar discogenic low back pain: A one-year prospective outcome study using discoblock for diagnosis". *Pain Physician*, 16 (4): E435-42, 2013.
- 20- LULECI N., OZDEMIR U., IWASHITA N., et al.: "Evaluation of patients' response to pulsed radiofrequency treatment applied to the suprascapular nerve in patients with chronic shoulder pain". *J. Back Musculoskeletal Rehabil.*, 24 (3): 189-94, 2011.
- 21- GURBET A., TURKER G., BOZKURT M., et al.: "[Efficacy of pulsed mode radiofrequency lesioning of the suprascapular nerve in chronic shoulder pain secondary to rotator cuff rupture]". *Agri.*, 17 (3): 48-52, 2005.
- 22- ERGONENC T. and BEYAZ S.G.: "Effects of ultrasound-guided suprascapular nerve pulsed radiofrequency on chronic shoulder pain". *Med. Ultrason*, 20 (4): 461-466, 2018.
- 23- JANG J.S., CHOI H.J., KANG S.H., et al.: "Effect of pulsed radiofrequency neuromodulation on clinical improvements in the patients of chronic intractable shoulder pain". *J. Korean Neurosurg. Soc.*, 54 (6): 507-10, (2013).
- 24- WU Y.T., HO C.W., CHEN Y.L., et al.: "Ultrasound-guided pulsed radiofrequency stimulation of the suprascapular nerve for adhesive capsulitis: A prospective, randomized, controlled trial". *Anesth. Analg.*, 119 (3): 686-92, 2014.

دراسة مقارنة لعلاج المرضى الذين يعانون من آلام الكتف المزمنة عن طريق التردد الحرارى أو الحقن الموجه بالموجات فوق الصوتية للعصب فوق الكتف

الهدف: يهدف هذا البحث إلى دراسة فعالية التردد الحرارى الموجه بالموجات فوق الصوتية بالمقارنة بحقن خليط الليدوكايين والهيدروكورتيزون للعصب فوق الكتف فى مرضى آلام الكتف المزمن.

الطريقة: تم تقسيم ٢٠ مريض إلى مجموعتين متساويتين كالتالى:

مجموعة (أ): تم علاج هذه المجموعة بالتردد الحرارى بقطب مبرد داخليا.

مجموعة (ب): تم علاج هذه المجموعة عن طريق حقن خليط الليدوكايين والهيدروكورتيزون الموجه بالموجات فوق الصوتية .

تمت متابعة المجموعتين على مدى ستة أشهر مع تقييم تحسن الألم.

النتائج: جميع المرضى كانوا يعانون من آلام مزمنة فى الكتف لا تستجيب للعلاج الطبى أو العلاج الطبيعى.

١- بعد العلاج بالتردد الحرارى:

- ستة مرضى تم شفاؤهم من الألم نهائياً.
- أربع حالات تحسن الألم عندهم من شديد إلى خفيف مع تحسن الإستجابة للعلاج التقليدى.

٢- فيما يتعلق بحالات الحقن:

- تحسن الألم عند جميع الحالات لمدة ثلاثة أشهر فقط.
- بعد ستة أشهر ثلاثة حالات لم يعاودهم الألم نهائياً.
- أربعة مرضى عاد إليهم الألم بنفس درجه ما قبل العلاج.
- ثلاث حالات ظل مستوى تحسن الألم ثابت عندهم.

الخلاصة: أثبتت تقنية التردد الحرارى للعصب فوق الكتف فعاليتها مقارنة بالحقن فى علاج الام الكتف المزمنة.