

Effect of Intravenous Lipid Emulsion on Haloperidol Toxicity: Biochemical and Histopathological Investigations in Albino Rats

Sherien S. Ghaleb¹, Dalia Abdelwahab Hassan^{2*}, Marwa M. Sayed³, Fadwa A. Alroby²

ABSTRACT

KEYWORDS

Intravenous Lipid Emulsion;
Haloperidol Toxicity;
Biochemical and
Histopathological
Investigations.

Haloperidol is one of the classic antipsychotic, was the cause of many cases of intoxication in several studies. Intravenous lipid emulsion is the first choice of treatment of haloperidol toxicity because of the haloperidol properties, such as high lipid solubility and water-soluble metabolites with low pharmacological activity. Animals were weighed and randomly allocated into four groups (30 rats each) as following: the first group served as control. The second group was treated with different doses of intravenous lipid emulsion (10 ml/kg & 15 ml/kg and 19ml/kg). The third group received a single dose of haloperidol intraperitoneal and the fourth group received a single dose of haloperidol intraperitoneal followed by different doses of intravenous lipid emulsion. Biochemical investigation and histopathological examination were done. There was elevation in liver function tests in the group treated with haloperidol and decrease of these levels in the groups that treated by combination of haloperidol and intravenous lipid emulsion especially in-group (intravenous lipid emulsion dose 10 ml / kg) but there was synergistic effect in-group (intravenous lipid emulsion dose 19 ml / kg). Hepatic and renal tissue in haloperidol group showed marked changes by histopathology also the haloperidol treated group showed significant diffuse changes in the brain histopathology compared to the control group. The treatment of haloperidol intoxication with dose of 10 mL/kg of intravenous lipid emulsion could significantly decrease in ALT and AST. The treatment of haloperidol intoxication with intravenous lipid emulsion could significantly cause improvement of pathology of liver, kidney and brain.

Introduction

In the past, mental illnesses were treated with antipsychotic drugs that act through blockage of dopamine receptor in the brain. These drugs have many sides effects with the prolong use like tardive dyskinesia and neuroleptic malignant syndrome (NMS) (John et al., 2007). Haloperidol used in treatment of acute and chronic psychosis and the aggressive

and agitated actions which appears in chronic brain syndrome and mental retardation. It can reverse the coma which a result of over dose of alcohol and depressant drugs (Andrezina et al., 2006).

Haloperidol is one of the Butyrophenones Group of the antipsychotic drugs' groups. Butyrophenones are D2 antagonists and have minimal anticholinergic and autonomic effects (Taylor et al., 2011). Haloperidol is a competitive agent with central or peripheral catecholamine neurotransmitters; in addition, it is a D1, D2, H1, H2 and alpha 1 and 2 receptor blocker, as well as of serotonin and muscarinic

⁽¹⁾Forensic Medicine and Clinical Toxicology
Department, Cairo University, Egypt.

⁽²⁾Forensic Medicine and Clinical Toxicology
Department, Beni-Suef University, Egypt.

⁽³⁾Pathology Department, Beni-Suef University, Egypt.

receptors, which causes a large number of symptoms ranging from dizziness to neuroleptic malignant syndrome (Gajre et al., 2012).

The first-pass hepatic metabolism decreases haloperidol oral bioavailability to 40 - 75%, with a high bioavailability when injected intramuscularly and the bioavailability is 100% in intravenous (IV) injection (Kudo and Ishizaki, 1999). Haloperidol is highly lipid-soluble and protein-bound; tend to have large volumes of distribution (Katzung, 2002). The most common clinical picture of acute toxicity of haloperidol are extrapyramidal syndrome, hypotension, respiratory distress, catalepsy and loss of alertness while akathisia, dystonic reactions (torticollis, retrocollis, jaw and tongue contracture, oculogyric crises and even opsithotonus), hyperreflexia and serotonin syndrome are less common but more serious (Akhiwu, et al., 2012).

Treatment of haloperidol acute toxicity includes biperiden (0.04 mg/kg oral, IM or IV, up to 4 doses at 30-minute intervals) and promethazine. Promethazine is contraindicated in children younger than 2 years because of the serious respiratory depression it causes as an adverse effect (Gajre et al., 2012).

The second choice of treatment is diphenhydramine. It is initially slowly administered by IV (1 mg/kg per dose) and, once the symptoms have resolved, it is continued by oral route for at least 72 hours. In case D2 antagonism-associated adverse effects predominate, therapy implies dose reduction and addition of an antiparkinsonian agent by parenteral route, such as benztropine (0.02 mg/kg, 1 mg maximum), trihexyphenidyl and procyclidine (James et al., 2014).

Intravenous lipid emulsion was only used for parenteral nutrition. Recently, intravenous lipid emulsion is used as an antidote for local anesthetic toxicity, new investigation reported that it can be used as antidote of lipophilic

drugs toxicity such as calcium channel blocker, tricyclic antidepressants, clomipramine and beta-adrenergic antagonists (Replinger et al., 2015). Intravenous lipid emulsion was recommended to be available in all emergency departments as a treatment of local anesthetic toxicity (Ciechanowicz and Patil, 2012).

Mechanism of ILE action is that the formation of a "lipid sink" which draw lipophilic toxins away from the tissues by expanding intravascular lipids, so reducing the concentration of the toxin at other sites (Cave et al., 2011). Intravenous lipid emulsion enhances cardiac function through a direct energy source to the myocardium and raising triglyceride level which increase myocardial calcium concentration by its action on cardiac calcium channels (Coat et al., 2010).

Intravenous lipid-emulsion also can improve myocardial free fatty acid availability, reversing the switch from lipid to glucose metabolism that occurs in stunned myocardium. Furthermore, lipid emulsion may counteract the inhibition to oxidative phosphorylation in toxic myocardium (Harvey and Cave, 2006).

Intravenous lipid emulsion could theoretically improve ATP synthesis in the cardiac myocytes by increasing intracellular fatty acid content. The reduction of ATP production results from local anesthetic's block of fatty acid transport and oxidation (Rothschild et al., 2010). Another theory is that ILE has metabolic effects by inhibiting mitochondrial metabolism of lipids, reducing tissue acidosis and decreasing carbon dioxide production during times of myocardial ischemia. Additionally, fatty acids, as found in ILE, have been shown to activate calcium and potassium channels, which have been associated with local anesthetics, induced cardio-toxicity (Felice and Schumann, 2008).

Early or immediate adverse effects of ILE include allergic reactions, headache, dizziness,

diaphoresis, dyspnea, nausea, vomiting, hyperthermia and hypercoagulability (Felice and Schumann, 2008). More delayed adverse effects of ILE include thrombocytopenia, jaundice, fat overloading syndrome, increased liver function tests, leucopenia, hepatomegaly and splenomegaly (Kasi et al., 2003).

The adverse effects of ILE are pulmonary or fat embolus and pulmonary vasoconstriction (Bania et al., 2007). Also cases of pancreatitis were reported as a side effect of intravenous lipids administration by multiple doses or a prolonged infusion (Bucklin et al., 2013).

Materials and Methods

Drugs:

- 1- Haloperidol ampoules: (5mg/ml) was obtained from Nile Company for pharmaceuticals-Egypt.
- 2- Intravenous lipid emulsion (ILE): SMOFlipid™ 20%, 500 ml of injectable emulsion that is white homogeneous emulsion, obtained from Fresenius Kabi Company, Austria. It is composed of (6% soybean oil, 6% medium chain triglycerides, 5% olive oil and 3% fish oil).
- 3- Saline (500 ml) solution: 0.9% NaCl (normal saline), was obtained from Nile Company.

Animals: The experiment was carried out on 120 male albino rats weighing 150-200g. They were obtained from the Animal House of Faculty of Pharmacy, El-Nahda University, BeniSuef, Egypt. An ethical approval (code:019-70) was taken from the animal committee in BeniSuef University.

The experiment was performed after a stabilization period in Faculty of Pharmacy animal house at the Department of Pharmacology and Toxicology, El-Nahda University for seven days. All animals were

housed in plastic cages with stainless steel wire-bar lids, using a wooden dust free litter as a bedding material in a room with a controlled temperature ($22 \pm 2^\circ\text{C}$) and humidity level ($50 \pm 5\%$). The animals were fed laboratory pellet chow and water ad libitum and were allowed free access to diet and water. Animals were weighed and randomly allocated into four groups (30 rats each) as following:

Group I (Control group): Each rat of this group received only regular diet and tap water for 48 hours.

Group II (Intravenous lipid emulsion group): Animals of this group were treated with different doses of intravenous lipid emulsion (Carreiro et al., 2013) which is further subdivided into subgroups IIA, IIB and IIC

- Sub group IIA: (n=10 rats) each animal of this group received 10 ml/kg of intravenous lipid emulsion by I.V. once.
- Sub group IIB: (n=10 rats) each animal of this group received 15 ml/kg of intravenous lipid emulsion by I.V. once.
- Sub group IIC: (n=10 rats) each animal of this group received 19 ml/kg of intravenous lipid emulsion by I.V. once.

Group III (Haloperidol): Each animal of this group received a single dose of haloperidol intraperitoneal (2.6 mg/Kg) (Mohammad et al., 2014).

Group IV (Haloperidol + ILE group): animals of this group received a single dose of haloperidol intraperitoneal (2.6 mg/Kg) then it was divided into 3 groups:

- Sub group IV A: (n=10 rats) each animal of this group received a single dose of haloperidol intraperitoneal (2.6 mg/Kg) following by 10 ml/kg of intravenous lipid emulsion by I.V. once.
- Sub group IV B: (n=10 rats) each animal of this group received a single dose of haloperidol intraperitoneal (2.6 mg/Kg)

following by 15 ml / kg of intravenous lipid emulsion by I.V. once.

- Sub group IV C: (n=10 rats) each animal of this group received a single dose of haloperidol intraperitoneal (2.6 mg/Kg) following by 19 ml / kg of intravenous lipid emulsion by I.V. once.

After 24 hours, blood samples were collected from retro orbital plexuses for biochemical study then all animals were scarified rats were sacrificed via decapitation under light ether anesthesia. Autopsy was intended to be done if animals died during the course of treatment.

Biochemical studies:

Blood samples were collected in dry centrifuge tubes for serum preparation, sera were separated and preserved at -20°C until used for analysis of liver function (alanine aminotransferase (ALT) aspartate aminotransferase (AST), albumin, glucose), kidney function (BUN, creatinine) and creatinine phosphokinase (CPK).

Histopathological study:

Autopsy samples were collected from experimental groups; samples were secured in normal saline for 24 hours. Tap water and ethyl alcohol were used in washing and drying out

the samples. Specimens were vacant in xylene and fixed in paraffin at 56°C in a hot discuss stove for 24 hours. It was segmented at four microns thickness by sledge microtome for paraffin beeswax tissue pieces. Collect gotten tissue segments upon glass slides, deparaffinized and recolored with hematoxylin and eosin recolor for histopathological examination under microscope (Banchroft et al., 1996).

Statistical analysis

Computer program package SPSS 22 was used to analyze organized and, arranged data statistically. Number and percentages were displayed for quantitative variables. Fisher's exact tests and Chi-square were utilized to appraise differences in qualitative variables and significance below (0.05).

Results

Effect of different doses of intravenous lipid emulsion on liver function tests: There was little elevation in serum ALT, AST and variable effect on glucose level but within normal ranges compared to the control group as shown in table (1).

Table (1): Effect of different doses of intravenous lipid emulsion (ILE) on liver function tests (n: 120):

Group	ALT	AST	Albumin	Glucose
NC	30.70±5.54 ^a	129.23±16.88	4.27±0.74 ^b	204.00±24.34 ^{bc}
ILE 10 ml	37.78±1.84 ^b	138.40±18.53	4.73±0.72 ^b	173.00±12.00 ^a
ILE 15 ml	43.78±2.45 ^c	145.40±37.06	3.37±0.58 ^a	222.00±29.22 ^c
ILE 19 ml	46.74±5.93 ^c	140.20±30.39	3.25±0.15 ^a	190.00±20.46 ^{ab}
F	37.60	1.43	13.39	8.48
p-value	<0.001**	0.242 (NS)	<0.001**	<0.001**

Means with different superscript letters (a, b, c) in the same column are significantly different at (p< 0.05), ALT: Alanine aminotransferase, AST: Aspartate aminotransferase, NC: control, ILE: intravenous lipid emulsion, F: F value = variance of the group means.

Effect of different doses of intravenous lipid emulsion on kidney function tests: There was little elevation in serum creatinine, urea

level in ILE groups but within normal ranges in comparison with the control group as shown in table (2).

Table (2): Effect of different doses of intravenous lipid emulsion (ILE) on kidney function tests:

Group	Creatinine	Urea
NC	0.57±0.08 ^a	43.87±1.81 ^a
ILE 10 ml	0.65±0.06 ^b	47.40±2.55 ^b
ILE 19 ml	0.63±0.03 ^b	49.40±1.43 ^c
F	7.95	37.00
p-value	<0.001**	<0.001**

Means with different superscript letters in the same column are significantly different at ($p < 0.05$), NC: control, ILE: Intravenous lipid emulsion, F: F value = variance of the group means

Effect of different dosages of intravenous lipid emulsion on creatinine phosphokinase ILE groups were showed that there was diminish in creatinine phosphokinase but inside ordinary ranges comparing to the control group as shown in table (3).

Table (3): Effect of different doses of intravenous lipid emulsion (ILE) on creatinine phosphokinase (CPK):

Group	CPK
NC	132.07±22.10 ^b
ILE 10 ml	63.40±35.86 ^a
ILE 19 ml	60.20±13.87 ^a
F	7.19
p-value	<0.001**

Means with different superscript letters in the same column are significantly different at ($p < 0.05$), CPK: Creatinine phosphokinase, NC: control, ILE: Intravenous lipid emulsion, F: F value = variance of the group means

Table (4): Effect of different doses of intravenous lipid emulsion (ILE) on liver function tests in haloperidol 2.6 mg group:

Group	ALT	AST	Albumin	Glucose
NC	30.70±5.54 ^a	129.23±16.88 ^{ab}	4.27±0.74 ^b	204.00±24.34
ILE 10 ml	37.78±1.84 ^b	138.40±18.53	4.73±0.72 ^b	173.00±12.00 ^a
ILE 15 ml	43.78±2.45 ^c	145.40±37.06	3.37±0.58 ^a	222.00±29.22 ^c
ILE 19 ml	46.74±5.93 ^c	140.20±30.39	3.25±0.15 ^a	190.00±20.46 ^{ab}
HA 2.6	51.97±18.72 ^{bc}	142.17±34.03 ^{bc}	3.90±0.48 ^{ab}	207.83±18.89
HA2.6+ILE10	34.56±5.90 ^a	117.20±15.65 ^a	3.58±0.50 ^a	191.30±19.80
HA2.6+ILE15	41.60±10.13 ^{ab}	163.00±5.44 ^c	3.43±0.68 ^a	195.50±49.84
HA2.6+ILE19	56.75±2.50 ^c	164.50±3.00 ^c	5.92±0.05 ^c	192.50±3.51
F	14.1	6.5	13.8	5.5
p-value	<0.001**	<0.001**	<0.001**	<0.001**

Means with different superscript letters in the same column are significantly different at ($p < 0.05$), ALT: Alanine aminotransferase, AST: Aspartate aminotransferase, NC: control, ILE: Intravenous lipid emulsion, HA: haloperidol, F: F value = variance of the group means

There was elevation in serum ALT and AST levels in haloperidol 2.6 mg group in comparison with the control group. However, in comparison with groups treated by combination of haloperidol and intravenous lipid emulsion there was decrease in serum ALT and AST level especially in-group (intravenous lipid emulsion dose 10 ml /kg) but in-group (intravenous lipid emulsion dose 19 ml / kg) there was more elevation (synergistic effect). There was little decrease (within normal ranges) in serum Albumin level in haloperidol 2.6 mg group in comparison with the control group. However, in comparison with groups treated by combination of haloperidol and intravenous lipid emulsion there was variable effect in serum albumin but within normal ranges. There was no effect in serum glucose level in haloperidol 2.6 mg group in comparison with the control group and groups treated by combination of haloperidol and intravenous lipid emulsion as shown in table (4).

There was no effect (within normal ranges) in serum creatinine, urea level in haloperidol 2.6 mg group in comparison with the control group and groups treated by combination of haloperidol and intravenous lipid emulsion as shown in table (5).

Table (5): Effect of different doses of intravenous lipid emulsion (ILE) on kidney function tests in haloperidol 2.6 mg group:

Group	Creatinine	Urea
NC	0.57±0.08 ^a	43.87±1.81 ^a
ILE 10 ml	0.65±0.06 ^b	47.40±2.55 ^b
ILE 15 ml	0.64±0.02 ^b	49.40±1.51 ^c
ILE 19 ml	0.63±0.03 ^b	49.40±1.43 ^c
HA 2.6	0.67±0.07 ^b	48.97±2.99 ^b
HA2.6+ILE10	0.61±0.06 ^{ab}	48.80±1.81 ^b
HA2.6+ILE15	0.61±0.06 ^{ab}	49.00±0.89 ^b
HA2.6+ILE19	0.62±0.04 ^{ab}	46.00±2.00 ^a
F	5.5	6.8
P-value	<0.001**	<0.001**

Means with different superscript letters in the same column are significantly different at (p < 0.05), NC: control, ILE: Intravenous lipid emulsion, HA: haloperidol, F: F value = variance of the group means

There was no effect (within normal ranges) in creatinine phosphokinase (CPK) level in haloperidol 2.6 mg group in comparison with the control group. However, in comparison with groups treated by combination of haloperidol and intravenous lipid emulsion there was decrease (within normal ranges) in serum creatinine phosphokinase (CPK) level especially in-group (intravenous lipid emulsion dose 19 ml / kg) but in-group (intravenous lipid emulsion dose 10 ml/kg) there was increase in serum creatinine phosphokinase (CPK) level (synergistic effect) as shown in table (6).

Table (6): Effect of different doses of intravenous lipid emulsion (ILE) on creatinine phosphokinase (CPK) in haloperidol 2.6 mg group:

Group	CPK
NC	132.07±22.10a
ILE 10 ml	63.40±35.86a
ILE 15 ml	94.00±19.52ab
ILE 19 ml	60.20±13.87a
HA 2.6	144.00±109.10a
HA2.6+ILE10	311.10±177.42b
HA2.6+ILE15	142.00±5.48a
HA2.6+ILE19	87.50±1.73a
F	8.22
p-value	<0.001**

Means with different superscript letters in the same column are significantly different at (p < 0.05), CPK: Creatinine phosphokinase, NC: control, ILE: Intravenous lipid emulsion, HA: haloperidol, F: F value = variance of the group means

Histopathological examination of the liver showed that there was no histopathological abnormality in control group as shown in figure (1). In-group haloperidol 2.6 mg there were marked hepatocellular hydropic degeneration with moderate portal vein and central vein congestion as shown in figure (2) but after treatment by ILE, there was recovery of the normal hepatic architecture with regeneration of hepatocytes and improvement in central vein, sinusoids and portal vein blood flow as shown in figure (3)

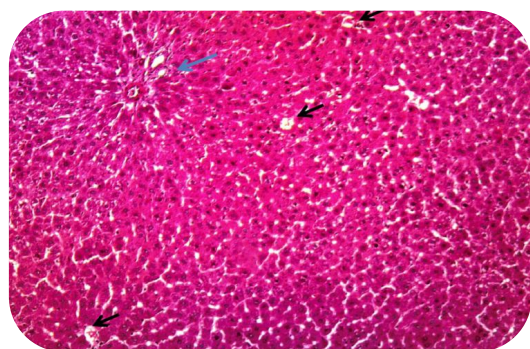


Fig. (1): Histological cross section of liver of the control group showed normal liver cell plates formed of polygonal hepatocytes with granular eosinophilic cytoplasm and vesicular nuclei & intervening regular sinusoids and normal central veins (black arrows). (Blue arrow) is the normal portal tract.

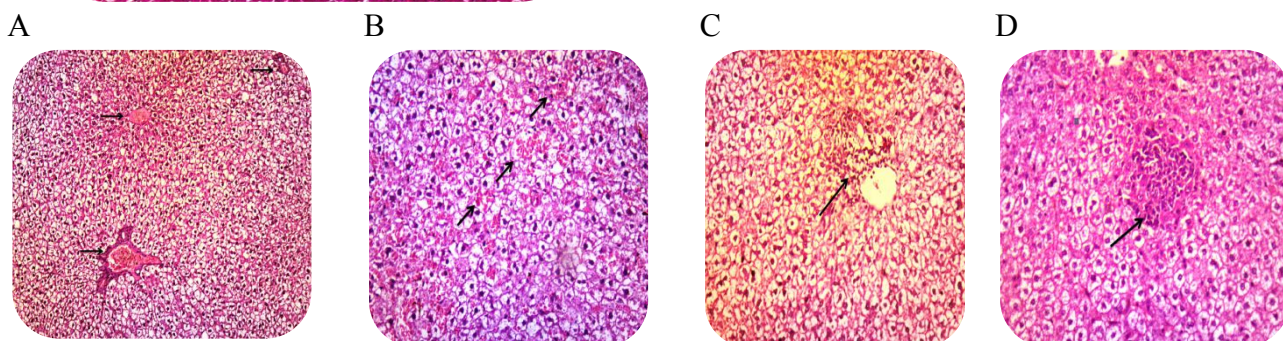


Fig. (2): Cross section of liver of the haloperidol group (2.6 mg). A: Marked hepatocellular hydropic degeneration with moderate portal vein and central vein congestion. B: Marked hepatocellular hydropic degeneration with multiple foci of hemorrhage (black arrows). C: Marked hepatocellular hydropic degeneration with Expansion of portal tract by portal vein congestion & moderate portal inflammation (black arrow). D: Marked hepatocellular hydropic degeneration & area of confluent necrosis with lymphocytic infiltration (black arrow).

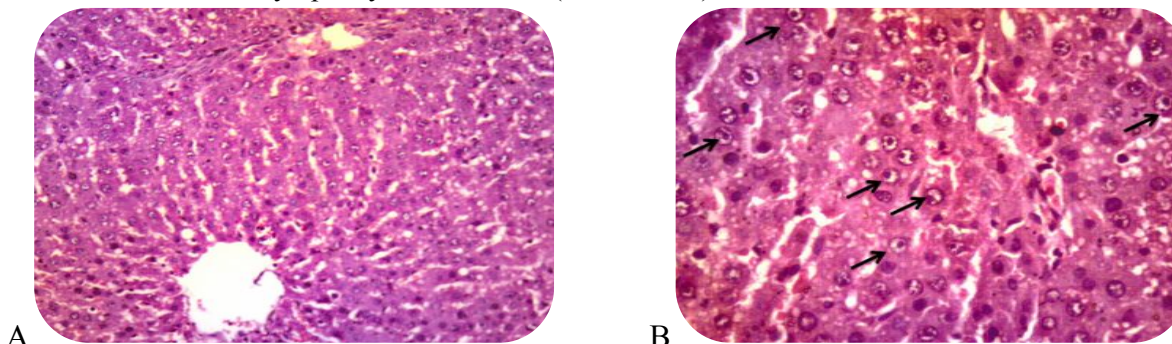
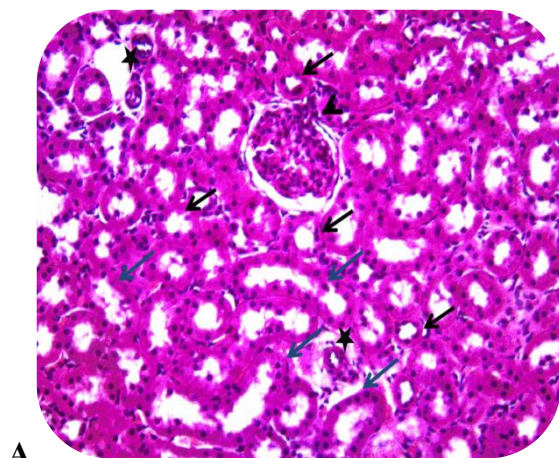


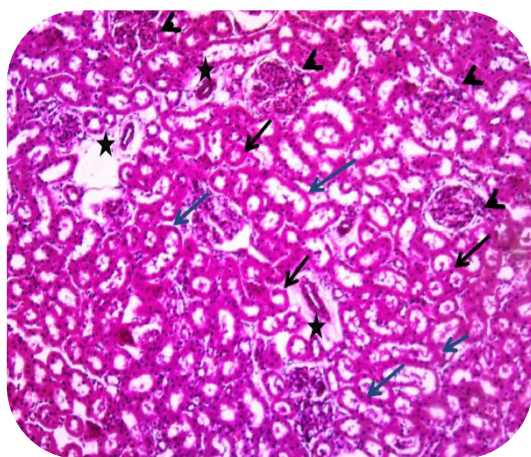
Fig. (3): Cross section of liver of the haloperidol group (2.6 mg) then treated with ILE. A: Recovery of the normal hepatic architecture with regeneration of hepatocytes and improvement in central vein, sinusoids and portal vein blood flow. B: Hepatocellular regeneration (black arrow).

Histopathological examination of the kidney showed no histopathological abnormality was found in control group as shown in figure (4). In-group haloperidol 2.6 mg showed marked congestion of interstitium and capillary tuft of the glomeruli with diffuse hydropic swelling in the epithelial

cells lining renal tubules with cystic dilatation as shown in figure (5). However, after treatment by intravenous lipid emulsion there was slightly decrease congestion of interstitial capillaries and glomerular tuft with some of renal tubules recovery to normal size as shown in figure (6).



A



B

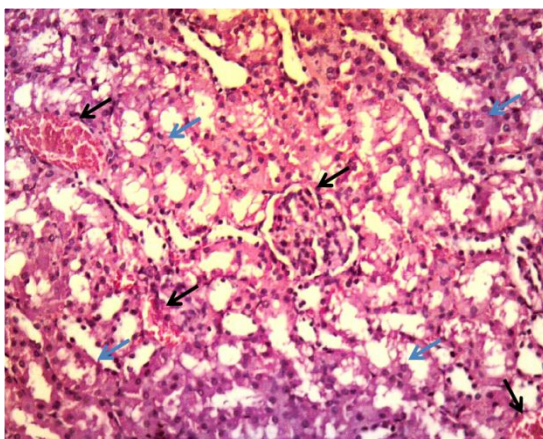


Fig. (4): Cross section of kidney of the control group. **A:** normal renal tissue showing normal glomeruli formed of capillary tuft surrounded by Bowman's capsule (arrow head), proximal convoluted tubules with narrow lumen lined by high cuboidal cells with homogeneous eosinophilic cytoplasm (black arrows) and distal convoluted tubules with wide lumen lined by low cuboidal cells (blue arrows) and normal sized capillaries (stars).

B: normal renal tissue showing normal glomerulus formed of capillary tuft surrounded by Bowman's capsule (arrow head), proximal convoluted tubules with narrow lumen lined by high cuboidal cells with homogeneous eosinophilic cytoplasm (black arrows) and distal convoluted tubules with wide lumen lined by low cuboidal cells (blue arrows) and normal sized capillaries (stars).

Fig. (5): Photomicrographs of cross section of kidney of the haloperidol group (2.6 mg). There are marked congestion of interstitium and capillary tuft of the glomeruli (black arrows) with diffuse hydropic swelling in the epithelial cells lining renal tubules (blue arrows) with cystic dilatation.

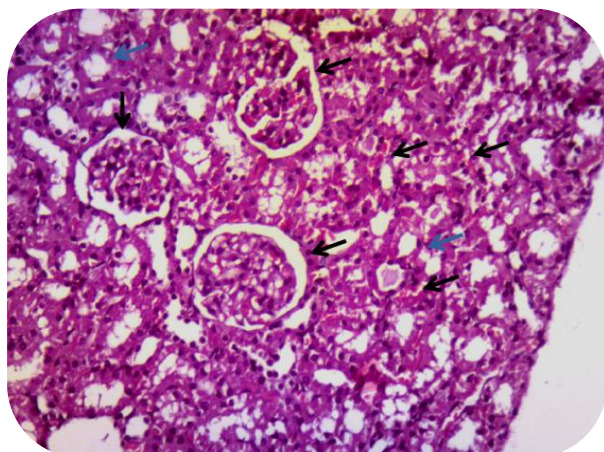


Fig. (6): Cross section of kidney of the haloperidol group (2.6 mg) then treated with ILE. Slightly decrease congestion of interstitial capillaries & glomerular tuft (black arrows) with some of renal tubules recovery to normal size (blue arrows).

Brain histopathological examination showed no histopathological abnormality was found in control group as shown in figure (7). In-group haloperidol 2.6 mg there were disarranged layers of cerebral cortex with hypercellularity and neuronal degeneration with marked dilated blood vessels with excess RBCs in rouleaux formation that indicated venous congestion & stasis. There were neurons with degenerative changes in the form

of shrunken hyperchromatic, irregular nuclei and marked vacuolation of neuropil with dilated congested blood vessels with perivascular spaces as shown in figure (8). However, after treatment by ILE there was near normal neurons with central large vesicular nuclei, containing nucleoli and small number of neurons with degenerative changes in the form of shrunken hyperchromatic, irregular nuclei as shown in figure (9).

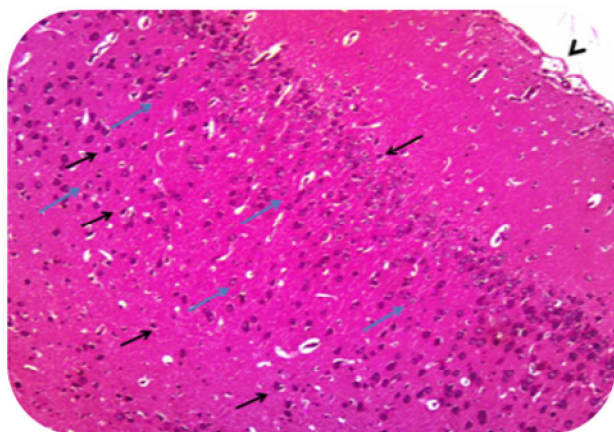


Fig. (7): cross section of brain of the control group. Control group showed a delicate layer of pia matter (arrow head) with six layers of cerebral cortex molecular layer (I), outer granular layer (II), outer pyramidal layer (III), inner granular layer (IV), inner pyramidal layer (V) and polymorphic layer (VI). These layers showing the normal neurons with rounded vesicular nuclei with prominent nucleoli and eosinophilic neuropil (blue arrow) and neuroglia cells with scanty cytoplasm (black arrow).

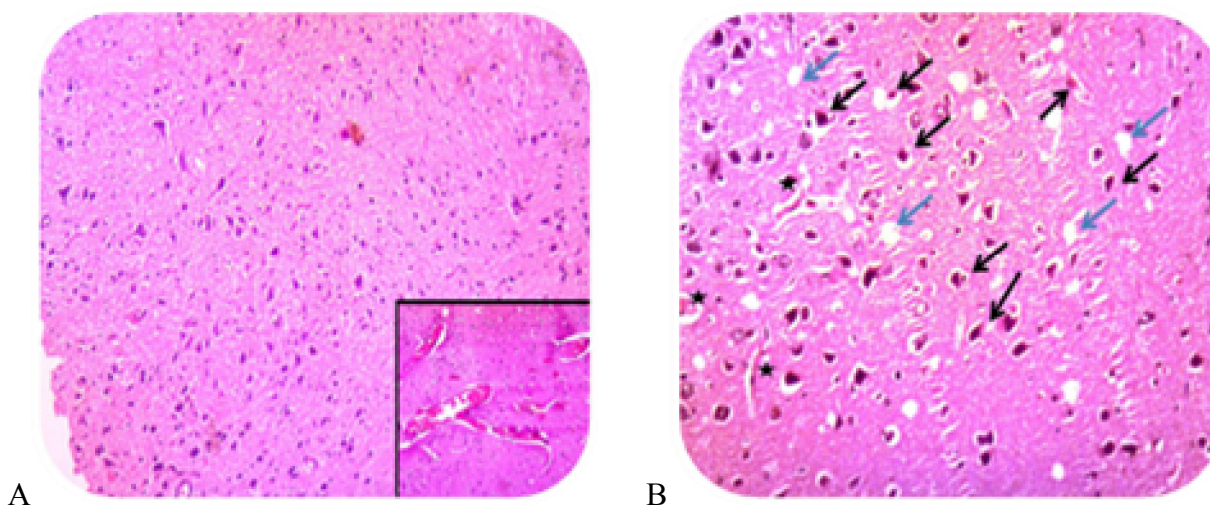


Fig. (8): Cross section of brain of the haloperidol group (2.6 mg). A: Section cerebral cortex showing disarrangement of its layers with hypercellularity and neuronal degeneration, insert box show marked dilated blood vessels with excess RBCs in rouleaux formation that indicated venous congestion & stasis. B: Neurons with degenerative changes in the form of shrunken hyperchromatic, irregular nuclei (black arrows) and marked vacuolation of neuropil (blue arrows) with dilated congested blood vessels with perivascular spaces

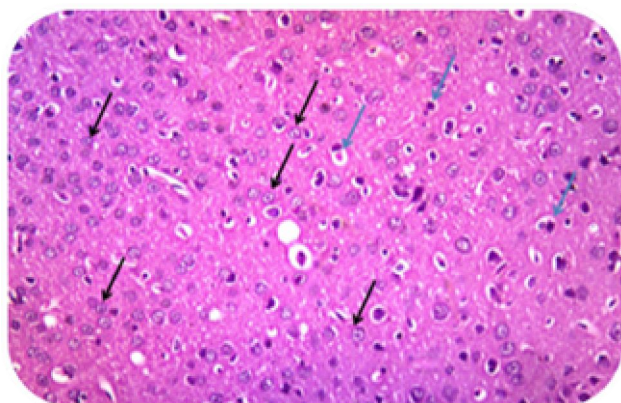


Fig. (9): Cross section of brain of the haloperidol group (2.6 mg) then treated with ILE. (Black arrows) shows near normal neurons with central large vesicular nuclei, containing nucleoli and (blue arrows) shows small number of neurons with degenerative changes in the form of shrunken hyperchromatic, irregular nuclei.

Discussion

Liver is responsible for the metabolism and excretion of haloperidol (Brockmoller et al., 2002) and that could explain the marked hepatocellular hydropic degeneration with moderate portal vein and central vein congestion in the haloperidol group. Halici et al. (2009) stated that there were changes in the general architecture of the liver and sinusoidal dilatation and congestion most areas. Hydropic degeneration in many hepatocytes, especially

in the perivenular areas was detected. Portal areas showed fibrosis and enlargement.

Also there were minor elevation in serum ALT and AST level associated with little decrease (within normal ranges) in serum Albumin level and no effect in serum Glucose level in the third group "haloperidol"; this may be attributed to mild affection on the nutritional status when compared with control groups. Moshiri et al. (2014) and Hanagama et al. (2008) also reported minor ALT, AST

elevation in case reports and animal studies after administration of haloperidol. Larry (2007) reported minor elevations of serum aminotransferases in people treated with haloperidol.

The histopathological examination of renal tissue of haloperidol group showed marked congestion of interstitium and capillary tuft of the glomeruli with diffuse hydropic swelling in the epithelial cells lining renal tubules with cystic dilatation. These changes are in agreement with previous histopathological studies that indicated a significant relationship between haloperidol treatment and structural changes in kidneys such as tubular deformations, prominent dilatation of the renal vessels and tubules, enlarged glomeruli, and glomerular basal membrane thickening (Uyanik et al., 2009).

Our study revealed that, there was no effect (within normal ranges) in serum creatinine, Urea level in haloperidol 2.6 mg group in comparison with the control group. This normal kidney function may indicate that haloperidol is a safer drug and this may indicate that the haloperidol induced renal toxicity takes longer time.

The long-term use of therapeutic doses of certain drugs and oxygen deficiency may induce diffuse changes in the brain histopathology (Druga et al., 2003). However, using of higher therapeutic doses of haloperidol in short period does not affect gliosis process in the dark matter and striatum of the rat brain (Gil-ad et al. 2001).

In our study, the haloperidol treated group showed significant diffuse changes in the brain histopathology compared to the control group, mainly in the form of disarrangement layers of cerebral cortex with hypercellularity and neuronal degeneration with marked dilated blood vessels with excess RBCS in rouleaux formation that indicated venous congestion and stasis. There were neurons with degenerative

changes in the form of shrunken hyperchromatic, irregular nuclei and marked vacuolation of neuropil (a dense network of interwoven nerve fibers and their branches and synapses, together with glial filaments) with dilated congested blood vessels with perivascular spaces.

Studies have claimed that using low doses of haloperidol does not cause damage to the cerebral cortex, while haloperidol induces apoptosis in cortical neurons due to higher production of oxidizing agents in a dose of 10 mg. Also antioxidants such as vitamin E and C can reduce cell damage induced by haloperidol (Post et al., 2002).

The serum level of skeletal muscle enzymes is affected by the pathological and physiological conditions so it can play an index of cellular necrosis and tissue damage which may be caused by acute and chronic muscle injuries (Brancaccio et al., 2007). Creatine phosphokinase is one of the skeletal muscles enzymes that is an indicator of muscle necrosis, increasing with its extent (Martinez et al., 2008). Intravenous lipid emulsion can provide cells with ATP can be produced from phosphocreatine and adenosine diphosphate (Vahabzadeh et al., 2013).

In this study, serum CPK levels were within normal ranges in h group. Whereas ILE could decrease (within normal ranges) in (CPK) level especially in-group (intravenous lipid emulsion dose 19 ml/kg) but in-group (intravenous lipid emulsion dose 10 ml/kg) there was increase in serum creatinine phosphokinase (CPK) level (synergistic effect). The previous result disagrees with (Tanii et al., 1996) and (Karre et al., 2009), who reported rise of CPK in cases with haloperidol overdose because of the neuroleptic malignant syndrome (NMS).

After treatment with ILE, the present study revealed that histopathological examination of liver tissue of group

(haloperidol + ILE) showed recovery of the normal hepatic architecture with regeneration of hepatocytes and improvement in central vein, sinusoids and portal vein blood flow. The histopathological examination of kidney tissue showed slightly decrease congestion of interstitial capillaries and glomerular tuft with some of renal tubules recovery to normal size. The histopathological examination of the brain showed near normal neurons with central large vesicular nuclei, containing nucleoli and small number of neurons with degenerative changes in the form of shrunken hyperchromatic, irregular nuclei.

The histopathological improvement of liver tissue of group IV is supported by the liver function indices results. There were decrease in serum ALT and AST level at lower dose of ILE in-subgroup IV A (intravenous lipid emulsion dose 10 ml/kg) and it worse with higher dose of ILE in-subgroup IVB-IV C (intravenous lipid emulsion dose 15 and 19 ml / kg).

Lipid-sink theory suggests that introducing an expanded lipid compartment into the intravascular space draws lipophilic agents out of the aqueous plasma phase; reducing bioavailability (Harvey and Cave, 2006). Also ILE has antidotal effect of against HA-induced catalepsy. The co-administration of voltage calcium channel blockers with HA could increase the catalepsy score of rats and decrease the onset of catalepsy by reducing the neurotransmitter dopamine in striatal region (Biała, 2000).

It is known that flunarizine and cinnarizine, two piperazine calcium channel blockers, can provoke Parkinsonism, tardive dyskinesia, and akathisia. It has also been reported that the duration of catalepsy would be prolonged, if the levels of calcium (Ca) and magnesium (Mg) in drinking water were low (Nakagawasai et al., 2012).

Fast infusion of ILE has been reported as a treatment for patients with cardiotoxicity induced by a lipophilic drug that does not react to conventional therapies (Jovic-Stosic et al., 2011).

Arslan et al. (2013), reported that when Intravenous lipid emulsion (ILE) was administered at a dose higher than that used in the standard management of toxicity. Rapid improvement was observed and no additional treatment was required. No adverse effect of lipid administration was observed. Intravenous lipid emulsion treatment seems to have great potential in the management of lipophilic drug toxicity but their reliability has not been proven yet so they cannot replace common antidotes or supportive special treatments (Jamaty et al., 2010).

The findings of Sahin et al. (2016) indicate that in a toxicity model of rats produced with verapamil, intralipid 20% and medialipid 20% solutions partially eliminate cardiac-depressant effects and increase the survival rate.

Some studies reported that ILE could reverse local anesthetic CNS toxicity and it raised the Glasgow coma scale of intoxicated patients (Taftachi et al., 2012). And other studies demonstrated the efficacy of lipid emulsion in reducing serum phenytoin levels in animal model and stated that lipid emulsion shows potential manner for treatment of phenytoin intoxication (Kayipmaz et al., 2017).

Conclusions

The treatment of haloperidol intoxication with dose of 10 mL/kg of intravenous lipid emulsion (ILE) could significantly decrease serum ALT and AST. The treatment of haloperidol intoxication with intravenous lipid emulsion (ILE) could significantly cause improvement of pathology of liver, kidney and brain.

References

- Akhiwu H.O., Ibrahim J.S., Abdullahi S.U., et al. (2012):** "The dilemma of managing childhood poisoning without adequate history in a resource-poor environment: report of 4 cases". *J. Niger Basic Clin Sci.*, 9:40-43.
- Andrezina, R.; Josiassen, R.C.; Marcus, R.N.; et al. (2006):** "Intramuscular aripiprazole for the treatment of acute agitation in patients with schizophrenia or schizoaffective disorder: a double-blind, placebo-controlled comparison with intramuscular haloperidol". *J. Psychopharmacology*, 188(3): 281-292.
- Arslan, E.D.; Demir, A.; Yilmaz, F.; et al. (2013):** "Treatment of Quetiapine overdose with intravenous lipid emulsion". *J. Keio. Med.*, 62 (2): 53–57.
- Banchroft, J.; Stevens, A. and Turner, D. (1996):** *A Text Book of Theory and Practice of Histological Techniques*. 4th Edition. Edinburgh, New York, Churchill Livingstone, P.P. 653-661.
- Bania, T.C.; Chu, J.; Perez, E.; et al. (2007):** "Hemodynamic effects of intravenous fat emulsion in an animal model of severe verapamil toxicity resuscitated with atropine, calcium, and saline". *J. Acad. Emergency Med.*, 14:105-111.
- Biala, G. (2000):** "Haloperidol-induced catalepsy is influenced by calcium channel antagonists". *J. Acta Poloniae Pharmaceutica.*, 57 (3): 233–237.
- Brancaccio, P.; Maffulli, N. and Limongelli, F. M. (2007): "Creatine kinase monitoring in sport medicine". *J. Br. Med. Bull.*, 81(1):209- 230.
- Brockmoller, J.; Kirchheiner, J. and Schmider, J. (2002):** "The impact of the CYP2D6 polymorphism on haloperidol pharmacokinetics and on the outcome of haloperidol treatment". *J. Clinical Pharmacology Therapy*, 4:438-452.
- Bucklin, M.H.; Gorodetsky, R.M. and Wiegand, T.J. (2013):** "Prolonged lipemia and pancreatitis due to extended infusion of lipid emulsion in bupropion overdose". *J. Clinical Toxicology*, 51(9):896- 898.
- Carreiro, S.; Blum, J.; Jay, G. and Hack, J.B. (2013):** "Intravenous lipid emulsion alters the hemodynamic response to epinephrine in a rat model". *J. Med. Toxicol.*, 9: 220-225.
- Cave, G.; Harvey, M. and Graudins, A. (2011):** "Review article: intravenous lipid emulsion as antidote: a summary of published human experience". *J. Emergency Med.*, 23(2): 123-141.
- Ciechanowicz, S. and Patil, V. (2012):** "Lipid emulsion for local anesthetic systemic toxicity". *J. Anesthesiol. Res. Pract.*, 2: 1-11.
- Coat, M.; Penneec, J. P.; Guillouet, M.; et al. (2010):** "Haemodynamic effects of intralipid after local anaesthetics intoxication may be due to a direct effect of fatty acids on myocardial voltage-dependent calcium channels". *J. Resuscitation*, 29(9):661.
- Druga, R.; Kubová, H.; Suchomelová, L. et al. (2003):** "Lithium/ Pilocarpine status epilepticus-induced neuropathology of piriform cortex and adjoining structures in rats is age- dependent". *J. Physiol. Res.*, 52(2):251-264.
- Felice, K.L. and Schumann, H.M. (2008):** "Intravenous lipid emulsion for local anesthetic toxicity: A review of the literature". *J. Med. Toxicol.*, 4(3):184-191.
- Gajre MP, Jain D and Jadhav A. (2012):** "Accidental haloperidol poisoning in

- children". *Indian J. Pharmacol.*, 44(6): 803–804.
- Gil-ad, I.; Shtaif, B.; Shiloh, R. and Weizman, A. (2001):** "Evaluation of the neurotoxic activity of typical and atypical neuroleptics: relevance to iatrogenic extrapyramidal symptoms". *J. Cell Mol. Neurobiol.*, 21(6):705-716.
- Halici, Z.; Dursun, H.; Keles. O.N.; et al. (2009):** "Effect of chronic treatment of haloperidol on the rat liver: a stereological and histopathological study". *J. Naunyn-Schmiedeberg's Archives of Pharmacology*, 379(3): 253–261.
- Hanagama, M.; Inoue, H.; Kamiya, M.; et al. (2008):** "Gene expression on liver toxicity induced by administration of haloperidol in rats with severe fatty liver". *J. Legal Medicine*, 10(4):177–184.
- Harvey, M. and Cave, G. (2006):** "Intralipid outperforms sodium bicarbonate in a rabbit model of clomipramine toxicity". *J. Ann. Emerg. Med.*, 49:178-185.
- Jamaty, C.; Bailey, B.; Larocque, A.; et al. (2010):** "Lipid emulsions in the treatment of acute poisoning: a systematic review of human and animal studies". *J. Clin. Toxicol.*, 48:1-27.
- James, A.; Kanthikiran, Y.; Chaitanya, K.; et al.(2014):** "Case report on haloperidol induced Parkinsonism and its management". *J. Asian Pac. Health Sci.*, 1:78-90.
- John, H.; Block; John, M. et al.(2007):** A text Book of Organic Medicinal & Pharmaceutical Chemistry. David B. Troy (Ed.), 12th Edition. Inc./Maryland Composition, A Wolters Kluwer Company, P.P. 504-515.
- Jovic-Stosic, J.; Gligic, B.; Putic, et al. (2011):** "Severe propranolol and ethanol overdose with wide complex tachycardia treated with intravenous lipid emulsion: a case report". *J. Clin. Toxicol.*, 49(5):426-430.
- Karre, P. R.; Gujral, J.; and Rodriguez, E. (2009):** "Rhabdomyolysis with erratic serum creatinine phosphokinase levels: intramuscular injection of haloperidol decanoate". *J. BMJ case reports online*. Available at: [http:// https://europepmc.org/article/med/21847426#free-full-text](https://europepmc.org/article/med/21847426#free-full-text).
- Kasi, V.S.; Estrada, C.A. and Wiese, W. (2003):** "Association of pancreatitis with administration of contrast medium and intravenous lipid emulsion in a patient with the acquired immunodeficiency syndrome". *J. South Med.*, 96:66-69.
- Katzung, P. G. (2002):** Structural formulas of commonly used antipsychotic drugs, Pharmacokinetics and Toxicokinetics: Absorption and Distribution, Non-psychiatric indications. In: *Basic & Clinical Pharmacology*, 8th edition, Chapter 29, P.P. 479-485.
- Kayipmaz, A.E.; Kavalci, C.; Bayraktar, et al. (2017):** "Treatment with lipid emulsion decreases high levels of phenytoin in rats". *J. Biomedical Research*, 25-29.
- Kudo, S. and Ishizaki, T. (1999):** "Pharmacokinetics of haloperidol: an update". *J. Clinical Pharmacokinetics*. 37 (6): 435–456.
- Larry, D. (2007):** Hepatotoxicity of psychotropic drugs and drugs of abuse In: *Drug-Induced Liver Disease*, N. Kaplowitz and L. D. De Leve, Eds., Informa Health Care, New York, NY, USA, P.P. 507–526.
- Martinez-Amat, A.; Hita, F.; Rodriguez-Serrano, F.; et al. (2008):** "Overview of the use of skeletal muscle markers for damage detection in sports people". *J. Sport and Exercise Psychology Research Advances*, 251.

- Mohammad, M.; Amir, H.; Maryam, V.; et al. (2014): "Evaluating the effects and safety of Intravenous Lipid Emulsion on haloperidol-induced neurotoxicity in rabbit". *BioMed Research International*, 1-10
- Nakagawasai, O.; Taniguchi, R.; Tan-No K. et al. (2012): "Pharmacological evaluation of catalepsy in low calcium and/or magnesium deficient feeding mice". *J. Health.*, 4:138–144.
- Post, A.; Rücker, M.; Ohl, F.; et al. (2002): "Mechanism underlying the protective potential of vitamin E against haloperidol-associated neurotoxicity". *J. Neuro-psycho-pharmacology*, 26(3):397-405.
- Repplinger, D.; Olsen, D.; Smith, S.; et al. (2015): "Lipid emulsion for cocaine toxicity: More questions for investigation". *J. Ann. Emerg. Med.*, 65(1): 127.
- Rothschild, L.; Bern, S.; Oswald, S. et al. (2010): "Intravenous lipid emulsion in clinical toxicology". *J. Scand. Trauma Resusc. Emerg. Med.*, 18(1): 18-51.
- Taftachi, F.; Sanaei-Zadeh, H.; Sepehrian, B. et al. (2012): "Lipid emulsion improves Glasgow coma scale and decreases blood glucose level in the setting of acute non-local anesthetic drug poisoning-a randomized controlled trial," *J. European Review for Medical and Pharmacological Sciences*, 16(1): 38–42.
- Tanii, H.; Taniguchi, N.; Niigawa, H.; et al. (1996): "Development of an animal model for neuroleptic malignant syndrome: heat-exposed rabbits with haloperidol and atropine administration exhibit increased muscle activity, hyperthermia, and high serum creatine phosphokinase level". *J. Brain Res.*, 16; 743(1-2):263-270.
- Taylor, D.; Paton, C. and Kapur, S. (2011): *Lecture Notes: Psychiatry*, 11th Edition, Wiley-Blackwell, USA.
- Uyanik, A.; Unal, D.; Halici, Z.; et al. (2009): "Does haloperidol have side effects on histological and stereological structure of the rat kidneys?" *Renal Failure*, 31; 7: 573-581.
- Vahabzadeh, M.; Moshiri, M.; Mohammadpour, A.H. et al. (2013): "Promising effects of intravenous lipid emulsion as an antidote in acute tramadol poisoning". *J. Reg. Anesth. Pain Med.*, 38(5): 425-430.

تأثير مستحلب الدهون المعطى بالوريد على سمية هالوبيريديول : فحوص كيميائية حيوية وهستوباثولوجية

أ. د. شيرن صلاح غالب^١، داليا عبد الوهاب حسن^٢، فدوي علي الروبي^٢، مروة محمد سيد^٢

^١ قسم الطب الشرعي والسموم كلية الطب جامعة القاهرة

^٢ قسم الطب الشرعي والسموم كلية الطب جامعة بني سويف

^٣ قسم الباثولوجي كلية الطب جامعة بني سويف

هالوبيريديول هو أحد مضادات الذهان الكلاسيكية ، وكان سبب العديد من حالات التسمم في العديد من الدراسات. و حاليا يستخدم مستحلب الدهون الذي يعطي عن طريق الوريد كخيار أول لعلاج سمية هالوبيريديول بسبب خصائص الهالوبيريديول ، مثل قابلية ذوبان الدهون المرتفعة والأيضات القابلة للذوبان في الماء مع نشاط دوائي منخفض. ولقد قامت التجربة علي علي^٣ مجموعات من الفئران كل مجموعة عبارة عن ٣٠ فأر: المجموعة الأولى كانت بمثابة المجموعة الطبيعية التي يتم المقارنة بها. والمجموعة الثانية بجرعات مختلفة من مستحلب الدهون الذي يعطي عن طريق الوريد و تلقت المجموعة الثالثة جرعة واحدة من هالوبيريديول والمجموعة الرابعة تلقت جرعة واحدة اخري من هالوبيريديول تليها جرعات مختلفة من مستحلب الدهون الذي يعطي عن طريق الوريد. تم إجراء فحوصات كيميائية حيوية لوظائف الكبد والكلية. واستخدمت أجزاء الأنسجة التي تم جمعها من الكلى والكبد والدماغ لفحص الأنسجة. كان هناك ارتفاع في اختبارات وظائف الكبد في المجموعة التي عولجت بالهالوبيريديول وانخفاض هذه المستويات في المجموعات التي عولجت بمزيج من هالوبيريديول ومستحلب الدهون الذي يعطي عن طريق الوريد خاصة في المجموعة (جرعة مستحلب الدهون في الوريد ١٠ مل / كجم) و كان هناك تأثير تآزري في المجموعة (جرعة مستحلب الدهون في الوريد ١٩ مل / كجم). وأظهرت الأنسجة الكبدية والكلية في مجموعة هالوبيريديول تغييرات ملحوظة وأظهرت المجموعة المعالجة بالهالوبيريديول تغييرات كبيرة في المخ مقارنة بالمجموعة الأولى.

علاج تسمم بالهالوبيريديول بجرعة ١٠ مل / كجم من مستحلب الدهون الذي يعطي عن طريق الوريد يمكن أن يكون سبب في خفض الزيادة في وظائف الكبد الناتجة عن التسمم كما أن علاج تسمم هالوبيريديول بمستحلب الدهون الذي يعطي عن طريق الوريد يمكن أن يسبب إلى حد كبير عكس الأضرار التي تحدث لكل من الكبد والكلية والدماغ نتيجة هذا التسمم.