



## Detection of Nervous Necrosis Virus of Grouper Fish in Lombok Island, Indonesia Based on Serological and Molecular Studies

Arief Sulistiyono<sup>1</sup>, Kurniasih Kurniasih<sup>2\*</sup> and Tri Untari<sup>2</sup>

1-Magister Sains Veteriner Student, Faculty of Veterinary Medicine, Gadjah Mada University, Yogyakarta, Indonesia

2-Pathology Department, Faculty of Veterinary Medicine, Gadjah Mada University, Yogyakarta, Indonesia

3-Microbiology Department, Faculty of Veterinary Medicine, Gadjah Mada University, Yogyakarta, Indonesia

\*Corresponding Author: kurniasih\_1951@yahoo.co.id

### ARTICLE INFO

#### Article History:

Received: Oct. 11, 2019

Accepted: Jan. 30, 2020

Online: Feb. 2020

#### Keywords:

Cantang grouper

*E. fuscoguttatus*

*E. lanceolatus*

Lombok Island

NNV

IHC

PCR

### ABSTRACT

Cantang grouper fish (*Epinephelus fuscoguttatus* x *Epinephelus lanceolatus*) is one of the marine fisheries commodities that have opportunities both in the domestic and international markets. The cultivation of marine fish in Indonesian water has been largely harmed by the outbreak of viral diseases, for example, those caused by *Nervous Necrosis Virus* (NNV). The aim of study is to: produce primary antibody of NNV; and to detect disease based on immunohistochemical (IHC) and molecular methods. Two New Zealand rabbits (*Oryctolagus cuniculus*) of 8 months old males, ± 2 kgs of weight were vaccinated against NNV disease each week in a dose of 0.50 cc, 1.00 cc, 2.00 cc, and 3.00 cc by intra-peritoneal injection. The rabbit serum was harvested in the fifth week activated, and filtered by membrane dialysis three times to obtain immunoglobulin as the primary antibody. The brain, eyes, and spleen of infected grouper, were processed for histological tissue and stained with Hematoxylin and Eosin and immunohistochemical methods. Positive results were supported by the molecular test of Polymerase Chain Reaction (PCR) with Nishizawa's primers: R3: 5'-CGA GTC AAC ACG GGT GAA GA-3' and F2: 5'-CGT GTC AGT CAT GTG TCG CT-3'. The NNV primary antibody was sensitive for the detection. The positive results of IHC stains were supported by the PCR test in grouper fish from Lombok.

### INTRODUCTION

Grouper (*Epinephelus* sp.) is one of the marine fisheries commodities that potential both in the domestic and international markets (Lasabuda, 2013). The problem of grouper cultivation is viral infections such as *Nervous Necrosis Virus* (NNV), also known as *Viral Encephalopathy and Retinopathy* (VER). *Nervous Necrosis Virus* disease is caused by *Betanodavirus* infection. *Nervous Necrosis Virus* caused mass mortality in

more than 39 species, including grouper species. *Nervous Necrosis Virus* was first identified in 1990 in parrotfish (larval and juvenile stages) in Japan and barramundi fish in Australia, then spread widely to Southeast Asia, Mediterranean countries, the United Kingdom, North America and Australia (Shetty *et al.*, 2012).

Immunohistochemical (IHC) can be carried out using polyclonal and monoclonal antibodies in laboratory specimens, mainly in tissue forms, however, can also mucus, water, soil, etc. (Wasito and Wuryastuti, 2014). The immunohistochemical result of NNV will supported by the PCR test.

The PCR method had often been used to detect NNV disease of groupers in Bali (Sudaryatma and Lestari, 2014) and in Jakarta (Fitriatun and Manan, 2015). Diagnosis of disease by PCR was often be used to identify diseases in fish which is a confirmation test for NNV disease (OIE, 2016).

## MATERIALS AND METHODS

Two male rabbits with  $\pm 2$  kg of weight, 8 months of age were immunized intraperitoneally injected weekly with a dose of 0.5 ml, 1 ml, 2 ml, 3 ml, and 3 ml respectively. The serum was collected in the fifth week, activated at 56 °C for 30 minutes and precipitated using ammonium sulfate [(NH<sub>4</sub>)<sub>2</sub> (SO<sub>4</sub>)]. The serum obtained was added with ammonium sulfate slowly and stirred using a magnetic stirrer for 30-60 minutes, then centrifuged 6,000 rpm for 30 minutes. The supernatant was removed and the pellet was resuspended with physiological NaCl 0.85% until the original volume. It was then precipitated again with ammonium sulfate, it was repeated 3 times. The filtration process using the dialysis membrane in PBS with a pH of 7.2 for 12 hours, after which it was replaced with a new PBS with the same pH, it was repeated three times, to remove ammonium sulfate from the membrane (Amanu *et al.*, 2016).

The grouper samples used in this study were eight from East Lombok with 20-300 Gram of weight and two from Central Lombok with 280 and 300 Gram of weight. Several sizes of grouper fishes were collected from East and Central Lombok, Indonesia with clinical symptoms of weak swimming (irregular), loss of appetite, de-pigmented or the fish's body becomes darker. The fishes were autopsied, brain, eye, and spleen were collected.

Histopathological preparations used automatic tissue processor consisted of dehydrating, clearing, embedding, blocking, processing, and was stained by Haematoxylin & Eosin method (Slaoui and Fisetete, 2011). The IHC staining followed to The Procedure Novolink Min Polymer Detection System and using primary antibody product. Positive results on immunohistochemical stain showed a brownish reaction to the tissue. This color indicated the presence of antigen and antibody reaction from NNV to the tissues or organs.

The organs were fixed in ethanol absolute. They were RNA extracted and amplified using primers: R3: 5 '-CGA GTC AAC ACG GGT GAA GA-3' and F2: 5 '-CGT GTC AGT CAT GTG TCG CT-3' (Nishizawa *et al.*, 1995). The cycles of amplification was preheating at 48 °C for 45 minutes and 94 °C for 2 minutes, then 35 times with a denaturation temperature of 95 °C for 40 seconds, annealing temperature of 55 °C for 40 seconds and polymerization temperature of 72 °C for 40 seconds, the final elongation was 72 °C for 5 minutes and stored at 4 °C. The electrophoresis process used 1% of agarose gel, with 100 Volt for 30 minutes. Documentation with UV

Transilluminator (UV Doc) connected to a computer to see the results of PCR on agarose gel.

## RESULTS

Eight groupers from East Lombok and two groupers from Central Lombok were tested by Hematoxylin & Eosin and IHC stains. Necrosis and inflammation were found in the eye, liver, and kidney (Figure 1).

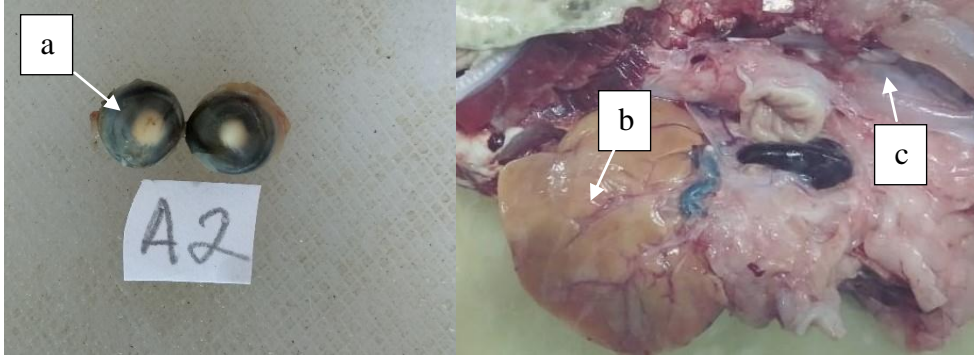


Figure 1. Image of necrosis and inflammation in organ (a) eye; (b) liver and (c) kidney.

A lot of small vacuoles were also found in the eye and brain by the H&E stain. The result of immunohistochemical stains spleen, brain and eyes showed a positive NNV with dark brown color in the tissue (Figure 2).

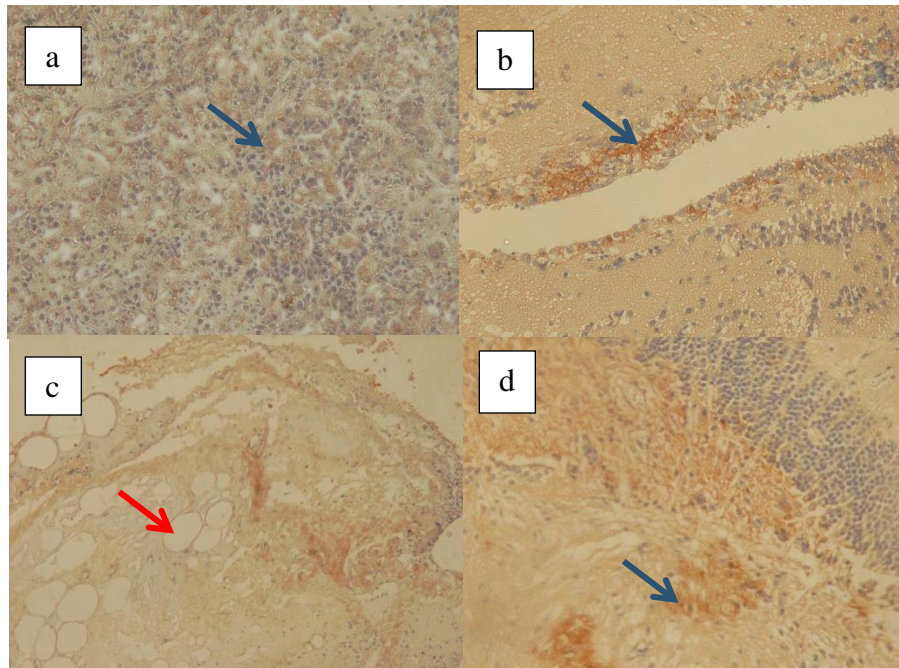


Figure 2. Image of immunohistochemical staining in organs (a) spleen; (b and c) eyes; (d) brain. Blue arrow: dark brown due to NNV antigen-antibody binding; red arrow: vacuole.

Four groupers from East Lombok and two groupers from Central Lombok were tested by PCR. The PCR results from East and Central Lombok positive band of NNV in 430 bp (Figure 3).




Figure 3. Image of the results of RT-PCR Test on grouper fish samples from East and Central Lombok; (M) marker; (-) negative control of NNV; (+) positive control of NNV; (3-8) NNV positive grouper fish samples from East Lombok; (9-10) NNV positive grouper fish samples from Central Lombok.

The result of RT-PCR and immunohistochemistry test of grouper fish samples from East and Central Lombok were shown in table 1.

Table 1. The Result of RT-PCR and immunohistochemistry tests of grouper fish samples from East and Central Lombok

Sample Number	Sample Origin	RT-PCR test result	IHC test result		
			Brain	Eye	Spleen
1	East Lombok	Untested	+	-	+
2	East Lombok	Untested	-	-	+
3	East Lombok	+	+	-	+
4	East Lombok	Untested	-	-	+
5	East Lombok	Untested	+	-	+
6	East Lombok	+	-	+	++
7	East Lombok	+	-	-	++
8	East Lombok	+	+	-	+
9	Central Lombok	+	-	+	++
10	Central Lombok	+	-	+	+

+ : positive result

- : negative result

++ : very positive result

The BLAST of RNA sequences result showed that the NNV samples were Red-spotted Grouper Nervous Necrosis Virus (RGNNV) strain.

## DISCUSSION

Immunohistochemical techniques were used to identify antigens in cells or tissues ranging from amino acids, proteins, carbohydrates, infectious agents and specific cellular populations through antigen-antibody interactions. Immunohistochemistry was the process of determining the location and type of antigen contained in tissue cells (Hastuti and Lubis, 2011).

Nervous necrosis virus infects fish through epithelial cells of the digestive tract, axons found on the surface of the skin and through blood circulation. The larvae of young fish that were naturally attacked by the virus could be detected in epithelial skin cells and epithelium associated with the intestine and nerve cells of the Central Nervous System (CNS) as the initial stage of infection by NNV. The initial infection of NNV was usually in the spine, then damaged to the swim bladder, brain, and retina (Korsnes, 2008).

Nervous necrosis virus replicated in the muscle and enters through the circulatory system and directly attached to the host receptor (ganglion) by entering genetic material in the host cell or intracellular infection. Cells became necrosis left empty spaces in brain tissue because of intracellular NNV infection from the blood to the brain. Nervous necrosis virus was also caused necrosis of eye tissues, such as vacuoles fish became blind, abnormally swimming, and could not take the food, and die.

Pathological changes that could be used as indicators that groupers were infected with NNV were the occurrence of vacuoles in the lining of the eye ganglion in the cerebral region of the brain. Fish infected with NNV-causing viruses through muscle attack by replicating themselves in the cytoplasm or the nucleus of muscle cells then spread and replicate in the peripheral nervous system where the virus would enter directly into the central nervous system (Sudaryatma and Lestari, 2014). Roberts's study (2008) showed that several lymphatic organs were found in the melanomacrophage center (MMC). Melanomacrophage Center proliferation was an indication of the body's defense reaction to foreign matter in fish. Melanin was a granular pigment that is dark brown. The existence of the virus in the spleen organ was related to the process of blood circulation and the regeneration of red blood cells which had genetic replication of viral material (virulence factors) and/or there were still active viruses (Kibenge and Godoy, 2016).

The PCR method has often been used to detect NNV disease of groupers in France (Thirey *et al.*, 1999). The results of his study showed PCR results at 430 bp. In Indonesia PCR NNV testing has been carried out, including research on NNV in Bali by Sudaryatma and Lestari, in 2014 which detected NNV at 630 bp, Fitriatun and Manan (2015) on groupers in Jakarta at 294 bp, and in Tanjung Pinang and Batam by Putra (2017) who tested NNV at 294 bp. The sequences test result showed that the NNV that has infected the groupers in East and Central Lombok was the strain Red-spotted Grouper Nervous Necrosis Virus (RGNNV). RGNNV is a genotype of the NNV virus which more often attacks fish in warm waters including Indonesia (Koesharyani and Yuasa, 1999).

## CONCLUSION

The NNV primary antibody was sensitive for the detection. It was proven by the discovery of a dark brown color in the IHC test was found in the spleen, brain, and eyes. The result was also supported by RT-PCR and sequencing methods. It was caused by the Red-spotted Grouper Nervous Necrosis Virus (RGNNV) strain of NNV.

## ACKNOWLEDGMENTS

Research was supported by *Penelitian Unggulan Perguruan Tinggi* Project, Gadjah Mada University, Education Department of Indonesia. Thank full to Center for Marine and Fisheries Education, The Ministry of Marine Affairs and Fisheries; Fish Quarantine and Inspection Agency of Yogyakarta; Microbiology and Pathology Department, Faculty of Veterinary Medicine, Gadjah Mada University have been providing laboratory facilities.

## REFERENCES

- Amanu, S.; Sulistiyono, D. and Suardana, I. (2016). Detection of Fish Disease Caused by *Iridovirus* on Grouper (*Epinephelus sp.*) and Pomfret Star (*Trachinotus blochii*) with Co-agglutination Method in Tanjungpinang, Indonesia. *Journal of Agriculture Science and Technology*. 6: 121-128.
- Fitriatun, E. and Manan, A. (2015). Pemeriksaan Viral Nervous Necrosis (VNN) pada Ikan dengan Metode Polymerase Chain Reaction (PCR). *Jurnal Ilmiah Perikanan dan Kelautan*. 7(2): 149-152.
- Hastuti, W.H. and Lubis, M.L.H. (2011). Manfaat Praktis Pemeriksaan Imunohisto(sito)kimia. *Cermin Dunia Kedokteran*. 186(38): 65-71.
- Kibenge, F. and Godoy, M. (2016). *Aquaculture Virology*. Elsevier, Sidney, pp. 130-146.
- Koesharyani, I. and Yuasa, Z.K. (1999). Deteksi Viral Nervous Necrosis (VNN) Menggunakan Polymerase Chain Reaction (PCR) pada Ikan Kerapu Bebek, *Cromileptes altivelis*. *Prosiding seminar Nasional Penelitian dan Desiminasi Budidaya Laut dan Pantai*. Jakarta. Indonesia. p.12.
- Korsnes, K. (2008). Nervous Necrosis Virus (NNV) in Farmed Norwegian Fish Species. Department of Molecular Biology, University of Bergen.
- Lasabuda, R. (2013). Tinjauan Teoritis Dalam Perspektif Negara Kepulauan Republik Indonesia. *Jurnal Ilmiah Platax*. 1(2): 92–101.
- Nishizawa, T.; Mori, K.; Furuhashi, M.; Nakai, T.; Furusawa, I. and Muroga, K. (1995). Comparison of The Coat Protein Genes of Five Fish Nodaviruses, The Causative Agents of Viral Nervous Necrosis in Marine Fish. *Journal of General Virology*. 76: 1563-1569.
- OIE. (2016). Viral Encephalopathy and Retinopathy. In *Manual of Diagnostic Tests for Aquatic Animals*, Paris: Office International des Epizooties, pp: 1-20.
- Putra, H.H. (2017). Pengembangan Perangkat Uji Serologis Dibandingkan Uji Molekuler untuk Deteksi Penyakit Viral Nervous Necrosis (VNN) pada Kerapu Macan. Fakultas Kedokteran Hewan, Universitas Gadjah Mada, Yogyakarta, Indonesia.
- Roberts, R. (2008). *Fish Pathology* 4<sup>th</sup> edition. W.B Saunders, London. Pp:165-173.

- Shetty, M.; Maiti, B.; Santhosh, S.K.; Venugopal, N.M. and Karunasagar, I. (2012). Betanodavirus of Marine and Freshwater Fish: Distribution, Genomic Organization, Diagnosis, and Control Measures. *Indian Journal of Virology*. 23(2): 114–123.
- Slaoui, M. and Fiset, L. (2011). Histopathology Procedures: From Tissue Sampling to Histopathological Evaluation. *Method in Molecular Biology*. 69: 69-82.
- Sudaryatma, E.P. and Lestari, T.A. (2014). Imunohistokimia Patogenitas Viral Nervous Necrosis Isolat Lapang Bali yang Diinfeksi pada Kerapu Macan Budidaya. *Acta Veterinaria Indonesiana*. 2(2): 54-61.
- Thirey, R.; Arnauld, C. and Delsert, C. (1999). Two Isolates of Sea Bass, *Dicentrarchus labrax* L, Nervous Necrosis Virus with Distinct Genomes. *Journal of Fish Diseases*. 22: 201-207.
- Wasito, R. and Wuryastuti, H. (2014). Antibodi dan Imunohistokimia. Andi Offset. Yogyakarta. Indonesia. Pp: 69-97.