



PATIENT-SPECIFIC COMPUTER MODIFIED TITANIUM PLATE IN UNILATERAL ANGLE FRACTURES

Khaled Amr*, Hussein Hatem** and Mohamed Farid Shehab**

ABSTRACT

Purpose: Various treatment modalities have been stated to avoid faulty healing of the mandibular angle fracture and the subsequent functional and esthetic disasters. In this study, we aimed to design a new patient-specific titanium plate to overcome Champy's acknowledged drawbacks and avoid splaying of the inferior border of the mandible.

Patients and methods: This study included eight patients suffering from a displaced unilateral mandibular angle fracture with a mean age of 37 years. They all needed open reduction and internal fixation. Preoperative evaluation included the clinical examination through inspection of malocclusion and measurement of maximum inter-incisal mouth opening, along with the radiographic assessment through the screening panoramic view and the 3-D CT examination to determine the amount of displacement between the fractured segments. Computer mirroring of the intact side was done to virtually reduce the fractured side to design a patient-specific plate. This plate aimed to fit on the superior ventral surface of the external oblique ridge, namely; Champ's osteosynthesis line. Downward extended lingual shelf and two buccal arms were added in the plate, to only immobilize the mandible lingually along with fixing both fractured segments buccally with screws, while fixing the segments superiorly at Champy's line with the standard plate shaft. The titanium PS-plate was processed and fixed in place using 2.0 screws through the standard intra-oral approach after Maxillo-mandibular fixation using ivy-loops. Immediate postoperative mandibular function was allowed. Postoperative clinical assessment of the occlusion and the Maximum inter-incisal opening (MIO) was performed at one week, 1 month and 3 months. Postoperative radiographic CT assessment was performed through measuring the linear inter-fragmentary gap between the fractured segments at the inferior mandibular border.

Results: The surgeries in all cases were uneventful. Surgical site was normal with no signs of infection or dehiscence except in only one case, which showed primary intra-oral plate exposure. The preoperative parasthesia recorded in three patients was improved postoperatively, however without its complete disappearance. MIO was significantly improved over the follow-up period to reach a mean of 40.3 mm after 3 months. Radiographic examination, over the follow-up period,

* Lecturer of Oral and Maxillofacial Surgery, Oral and Maxillofacial Surgery Department, Faculty of Dentistry, Cairo University.

** Associate Professor of Oral and Maxillofacial Surgery, Oral and Maxillofacial Surgery Department, Faculty of Dentistry, Cairo University.

revealed the exact alignment of the fractured segments in normal position throughout the whole thickness of the mandible at the fracture line with no inferior border distraction.

Conclusion: This study provided a newly designed plate capable of eliminating the splaying of the inferior border of the mandible in other literature-documented intra-oral plating techniques, which was also profitable in sparing the disadvantages of extra-oral approaches.

Keywords: Mandibular Angle Fracture, Champy's Plate, Computer-modified.

INTRODUCTION

Mandibular fractures (MFs) comprise around 36 to 70% of all maxillofacial fractures⁽¹⁻²⁾. Studies reported that fracture of the mandibular angle accounts for 12-30 % of all MFs which in turn falls in incidence after the body and the subcondylar fractures⁽²⁾. It is mostly caused by sports, interpersonal violence, then, motor vehicle accidents⁽³⁾.

Faulty treatment of the mandibular angle fracture (MAF) is a major foundation of significant functional and esthetic crisis ranging from occlusal discrepancies and pain during function to prominent facial asymmetries⁽¹⁾.

As a rule, the success of any treatment modality in MAF depends primarily on the inter-fragmentary approximation and stability and the incidence of postoperative complications⁽⁴⁾.

Despite of the widespread agreement for the need of surgical interference through open reduction and internal fixation (ORIF) of MAF, the optimal plating sites of MAF remains a subject of great debate, thereby, various treatment modalities have been described in the literature⁽⁵⁻⁷⁾.

The literature established the tensile and compressive zones all over the mandible where different plating sites were identified. These were found to counteract the muscular forces that naturally act on the fragments⁽⁸⁻⁹⁾.

Traditionally, compression plates on the inferior and outer surface of the mandible rigidly fixed the fractured segments preventing inter-fragmentary movement, however with the disadvantageous need of an extra-oral incisional approach. Scars due to

extra-oral approaches, difficulty in plate adaptation due to its bulkiness, and increased chances of nerve injury triggered surgeons to seek a less invasive plating technique⁽⁷⁾.

Champy et al⁽¹⁰⁾ proposed the concept of an ideal line for plating; the superior ventral surface to the external oblique ridge of the mandible. Champy's technique involved the placement of a single mini-plate for MAF, that's why *Kroon et al*⁽¹¹⁾ questioned its adequacy on basis of the possibility of the inferior border distraction or splaying attributed to the opposing muscular forces of the elevator muscles versus the depressor muscles. This inferior border distraction led to many complications as malocclusion, facial widening and non-union.

Choi et al⁽¹²⁾ suggested the addition of a second mini plate along the inferior border to stabilize fixation during functional loading, while the recent use of three-dimensional (3D) plates has been introduced as a growing alternative for the fixation of MAFs where simultaneous stabilization of the tension and compression zones were addressed.

Considering the above and utilizing the Champy's concept, this study aimed to design a newly modified patient-specific (PS) titanium plate to overcome the declared drawbacks and avoid mandibular inferior border splaying.

PATIENTS AND METHODS

The present study was performed in the department of oral and maxillofacial surgery, faculty of Dentistry, Cairo University. Eight patients were included with a mean age of 37 years. All the patients

suffered from displaced unilateral mandibular angle fracture which needed open reduction and internal fixation. Written consents and ethical clearance were obtained.

Exclusion criteria:

- Medically compromised patients with impaired healing ability.
- Old fractures.

Preoperative evaluation and preparation:

Clinically, the patients complained of pain and facial asymmetry due to malocclusion and restriction in mouth opening (Maximum inter-incisal opening). Preoperative parasthesia of the lip was recorded in three patients. (Fig. 1)

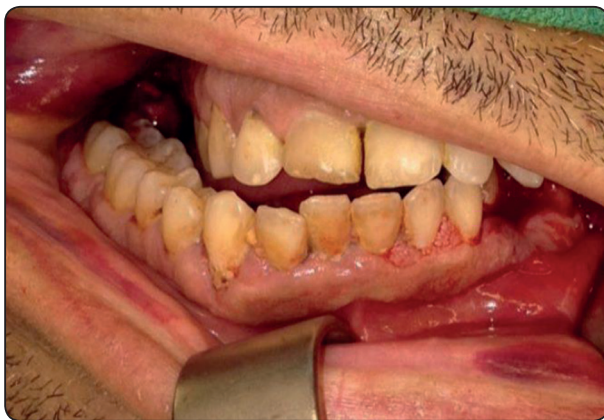

Fig. (1) A Photograph showing the preoperative malocclusion due to angle fracture.

Routine preoperative panoramic radiographs were performed to reach a diagnosis. CT was ordered to determine the amount of displacement between the fractured segments. (Fig. 2)

Utilizing the 3D CT images, mirroring of the intact side was done and used to virtually reduce create an image of the fractured side in a reduced state. This was used to design a PS-plate to fit on the ventral surface of the superior border of the external oblique ridge, namely; Champ’s osteosynthesis line.

The designed plate varied from the regular Champy’s plate by adding downward extended arms to the newly designed plate; lingual shelf and two buccal arms. These aimed to only immobilize the mandible lingually, along with fixing both fractured segments buccally with screws, while fixing the segments superiorly at Champy’s line with the standard screw-holes’ positions. (Fig. 3)

Processing of the PS-angle plate was done from titanium blocks through direct metal laser sintering.

Surgical procedure:

Under general anesthesia via naso-tracheal intubation, Maxillo-mandibular fixation (MMF) was done using the famous ivy-loops to bring the segments back together in normal position and put the patient in centric proper occlusion. Standard intra-oral approach was performed to reach the MAF line.

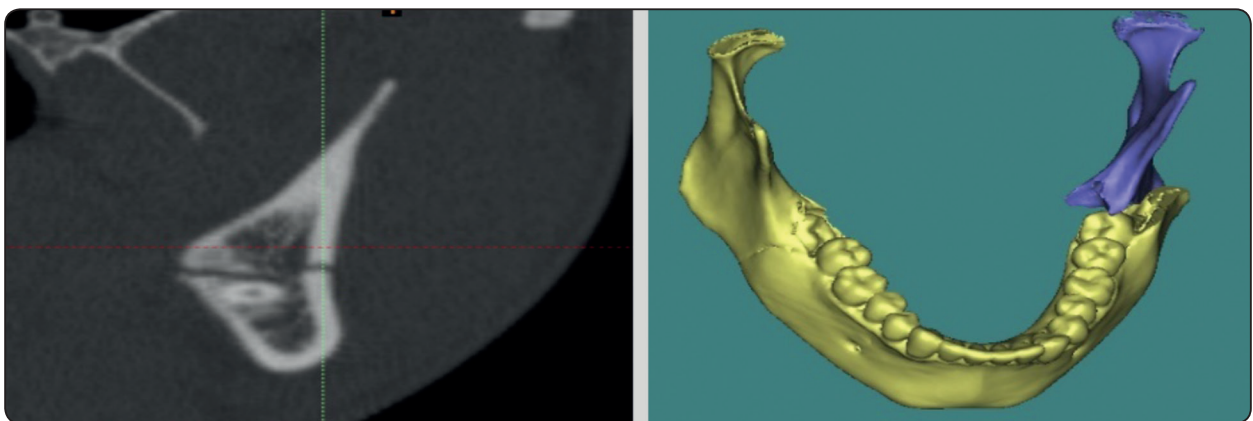


Fig. (2) Images showing the preoperative angle fracture.

The plate was then applied in the predetermined place and fixed using 2.0 screws through the holes in the main plate shaft and the two extended buccal arms. The lingual shelf just rested on the mandibular lingual surface and was not fixed with screws due to inaccessibility. This allowed the mandibular thickness at the angle region to be sandwiched between the lingual and buccal arms of the plate. (Fig. 4)

The MMF was released and the mandibular function and occlusion were checked. The wound was then sutured. All the patients were closely monitored and immediate postoperative mandibular function was allowed.

Postoperative assessment

Follow up period was determined to be 3 months. During which, the soft tissue over the plate were inspected for any signs of infection or dehiscence. Postoperative complications were recorded if present as fragment mobility, changed occlusion and/or parasthesia.

The clinical evaluation of the occlusion together with the maximum inter-incisal opening (MIO) measured in mm was done at one week, one month and 3 months.

Postoperative CT was performed to measure the linear inter-fragmentary gap between the fractured segments at the inferior mandibular border after

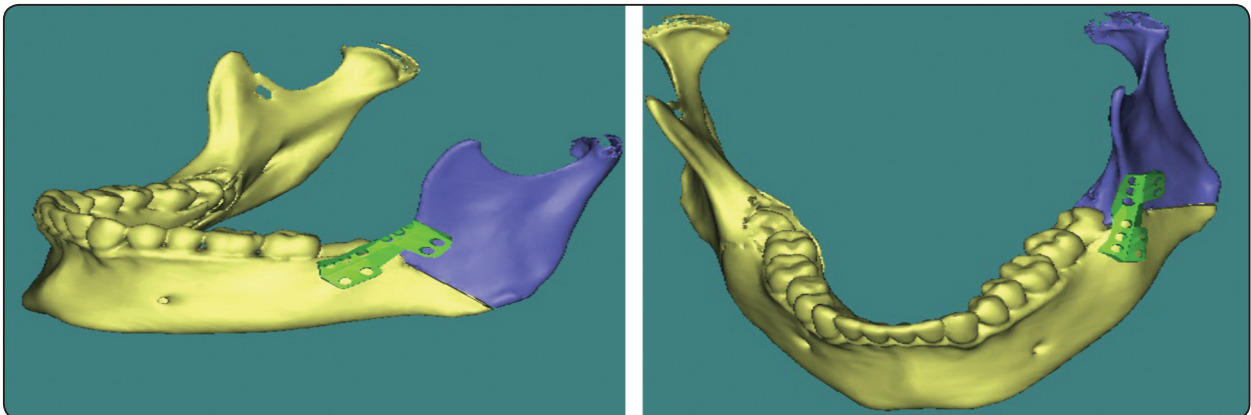


Fig. (3) Images showing the computer designed PS-angle plate after virtual fracture reduction.

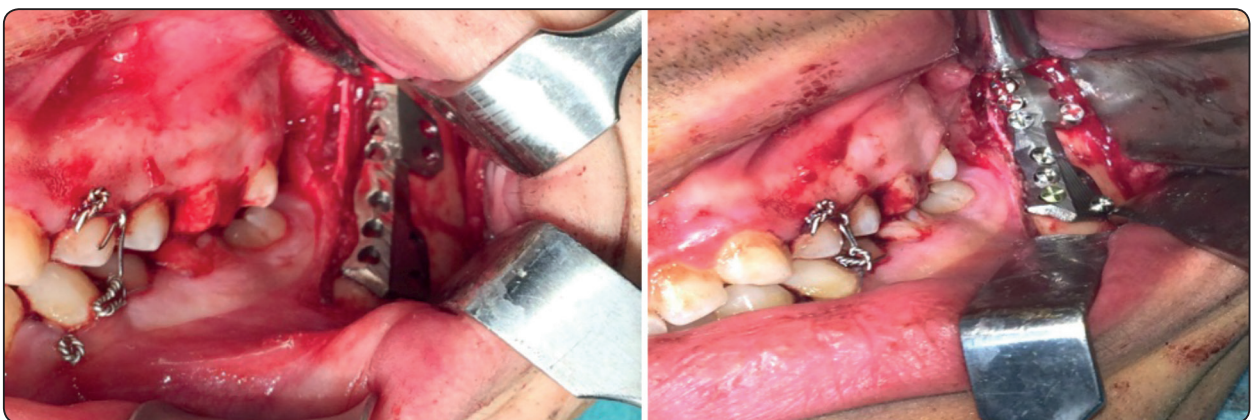

Fig. (4) Photographs showing the surgical exposure and plate adaptation and fixation.

fixation to validate the ability of the modified plate to approximate and immobilize the fractured segments through the whole thickness of the mandible.

RESULTS

A total of eight MAFs were treated by means of the computer-modified new titanium plate in this study. All the patients were males with a mean age of 37 years.

All the surgeries were uneventful with a tolerable resultant postoperative pain and swelling which were considered normal. All patients were followed up clinically and radiographically for 3 months postoperatively, after which the patients were clinically pleased.

The preoperative parasthesia recorded in three patients was improved postoperatively, however without its complete disappearance.

Soft tissue healing recorded no signs of infection, inflammation or dehiscence except in only one case, which showed primary signs of plate showing through the intra-oral soft tissue.

Over the study period, the severe preoperative restriction of the mandibular function and MIO was significantly improved to reach a pleasing

result after 3 months reaching a mean of 40.3 mm opening. (Table 1)

TABLE (1) Showing the mean values and SD of MIO indicating significant difference.

Period	Mean	SD
1 week	31.2	1.8
1 month	38.1	1.6
3 months	40.3	1.7

Radiographic examination after 1 week postoperatively revealed the exact alignment of the fractured segments in normal position throughout the whole thickness of the mandible at the fracture line. This continued without changes in position over the study period. No signs of adverse effects were detected around the screws. (Fig. 4)

DISCUSSION

Though a variety of treatment modalities for MAFs have been described, ORIF remains the gold standard treatment described in the literature for MAF⁽¹³⁾.

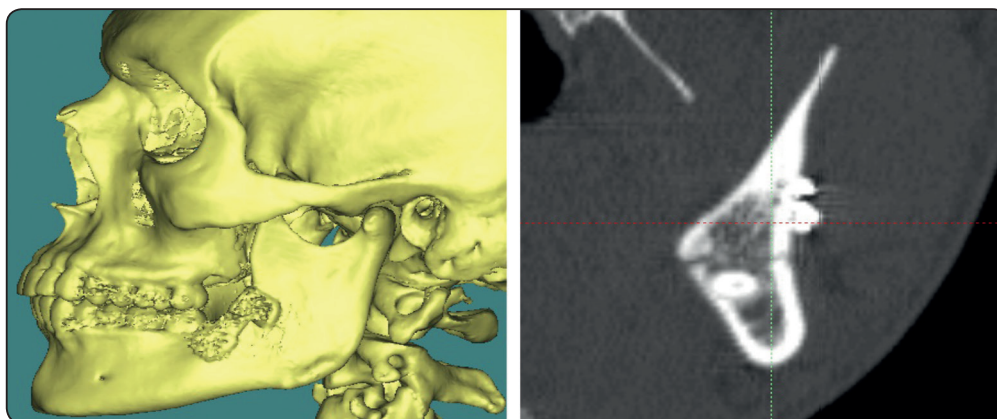


Fig. (5) CT images showing the exact alignment of the fractured segments after fixation through the whole mandibular thickness at the fracture line.

Studies suggested different plating sites in management of MAFs via ORIF. The wide agreement on the use of compression plate on the inferior border of the mandible has faced many disadvantages; extra-oral scar, risk of facial nerve injury and difficult adaptation ⁽⁷⁾.

Surgeons presented the more conservative Champy's intra-oral plate to avoid these disadvantages. Inferior border splaying due to the opposing muscular forces with the inferior border distraction led to many adverse effects as malocclusion, facial widening and non-union ⁽¹⁴⁾.

As philosophies on the treatment of maxillofacial trauma change over time, thereby, a periodic review is necessary to refine the present techniques and modify plate design for a more efficient outcome ⁽⁹⁾.

Accordingly, a new plate design was provided in this study in an attempt to modify Champy's concept to prevent inferior border distraction and subsequent complications. It utilized more than one plane of fixation, to counteract the opposing muscular forces and mastication load.

A tolerable resultant postoperative pain and swelling was documented immediately postoperative and faded in one week. This was considered normal due to the open reduction and tissue manipulation at the fracture site.

Regarding the postoperative complications, *Lizuka and Lindquist* ⁽¹⁵⁻¹⁶⁾ reported that MAF is associated with the highest incidence of postsurgical infection and dehiscence of all mandible fractures. On the contrary, in this study, despite of its statistical insignificance, the dehiscence and minor plate exposure reported in one case. This was attributed to the thin covering mucosa in this area along with the relatively high thickness of the plate, which was difficult to be further reduced due to the plate design and the main shaft junction with the extending arms.

Most studies in the literature didn't declare whether the lip parasthesia was recorded before surgery or due to the surgery itself ⁽⁹⁾. Three patients complained of the persisting preoperative parasthesia after the surgery however with less

intensity. This was insignificant due the established fact that nerve affection in MAFs depended mainly on the preoperative degree of displacement of the segments ⁽⁹⁾. This was confirmed in other studies which did not identify any difference after surgery regarding the presented paresthesia ⁽¹⁷⁾.

The readings of this study revealed the primary minor improvement in MIO due to the re-aligned segment and regained proper mandibular mechanics. This was significantly increased along the follow-up visits, which was explained by *El-Anwar et al* ⁽¹⁸⁾ where the initial muscle spasm and pain from the healing soft tissue produced an inability of the patients to fully open their mouths.

At the angle region, strong distractive forces are created due to the acting elevator muscles attached to the ramus. According to *Champy* ⁽¹⁹⁾, the muscular and functional action on a linear plate on the superior border at the external oblique ridge in MAF causes bucco-lingual splaying of the inferior border of the mandible and subsequent gap formation between the fractured segments due to torsion forces and movement over the axis of the plate.

Gutwald et al ⁽²⁰⁾ proved this while using 3-D box-shaped plates which superseded the 2-D miniplates in MAF through providing superior and inferior fixation that prevented bucco-lingual distraction of the fractured segments and inter-fragmentary gap formation.

Similarly, in our modified design, the use of the buccal and lingual extending arms sandwiched the mandible and provided an extra form of fixation of the fractured segments through a plane other than the plane of the main plate shaft. This provided rigid fixation and counteraction to the inferior border splaying tendency.

Validating the plate design of this study was revealed in the documented exact alignment of the fractured segments in normal position throughout the whole thickness of the mandible at the fracture line which continued without changes over the study period.

CONCLUSION AND SIGNIFICANCE

As philosophies in treatment of maxillofacial trauma change over time, this study provided a newly designed plate proved to spare the disadvantages of extra-oral approaches with the elimination of the mandibular inferior border splaying in the literature-documented intra-oral plating techniques.

A limitation of the design is reported in the obvious thickness of the plate affecting the ease of adaptation and soft tissue cover.

The need to include equivalent groups involving other plates is evident in order to statistically compare between different modalities.

REFERENCES

- Al-Moraissi EA and Ellis E. Surgical management of anterior mandibular fractures: A systematic review and meta-analysis. *J Oral Maxillofac Surg*; 72: 2507, 2014.
- Meram AT, Olate S, and Palmieri C. Is the Three-Dimensional Strut Plate an Adequate Fixation Technique for Mandibular Symphysis Fractures? *Journal of Oral and Maxillofacial Surgery*; 76: 140, 2018.
- Chrcanovic BR, Abreu MH, Freire-Maia B, and Souza LN. 1,454 mandibular fractures: a 3- year study in a hospital in Belo Horizonte, Brazil. *J Cranio Maxillofac Surg*; 40: 116–23, 2012.
- Moore E, Bayrak S, Moody M, Key JM and Vural E. Hardware removal rates for mandibular angle fractures: comparing the 8-hole strut and Champy plates. *J Craniofac Surg*; 24: 163–5, 2013.
- Chrcanovic BR. Fixation of mandibular angle fractures: clinical studies. *Oral Maxillofac Surg*; 12: 45, 2012.
- Chrcanovic BR. Fixation of mandibular angle fractures: in vitro biomechanical assessments and computer-based studies. *Oral Maxillofac Surg*; 17:251–68, 2013.
- Sadhwani B and Anchlia S. Conventional 2.0 mm miniplates versus 3-D plates in mandibular fractures. *Annals of Maxillofacial Surgery*; 3: 2, 2013.
- Singh RK, Pal US, Agrawal A, and Singh G. Single miniplate osteosynthesis in angle fracture. *Natl J Maxillofac Surg*; 2:47-50, 2011.
- Al-Moraissi EA, El-Sharkawy TM., El-Ghareeb TI, and Chrcanovic B.R.: Three-dimensional versus standard miniplate fixation in the management of mandibular angle fractures: a systematic review and meta-analysis. *Int. J. Oral Maxillofac. Surg*; 43: 708–716, 2014.
- Champy M and Pape HD. The strasbourg miniplate osteosynthesis. In: Kruger E, Schilli W, editors. *Oral and Maxillofacial Traumatology*. vol. 2. Berlin: Quintessence; 19: 43, 1986.
- Kroon F, Mathisson M, Cordey J, and Rahn B. The use of miniplates in mandibular fractures. *J Cranio Maxillofac Surg*; 19:199-204, 1991.
- Choi BH, Yoo JH, Kim KN and Kang HS. Stability testing of a two miniplate fixation technique for mandibular angle fractures: an in vitro study. *J cranio Maxillofac Surg*; 23:123-5, 1995.
- Zix J, Lieger O, and Iizuka T. Use of straight and curved 3-dimensional titanium miniplates for fracture fixation at the mandibular angle. *J Oral Maxillofac Surg*; 65(9):1758–63, 2007.
- Mannan R, Farooq A, and Mukhtar H. Comparison of Single vs Double Miniplates in the Management of Mandibular Angle Fractures. *P J M H S*; 12: 662, 2018.
- Iizuka T, and Lindquist C. Rigid internal fixation of fracture in angular region of mandible: An analysis of factors contributing to different complications. *Plast Reconstr Surg*; 91: 265-71, 1993.
- Balaji SM. Condylar fractures – open vs closed reduction: Review of 39 cases. *J Maxillofac Oral Surg* 2003; 2:16-84.
- Yong Liu and Bo Wei et al. The 3-dimensional miniplate is more effective than the standard miniplate for the management of mandibular fractures: a meta-analysis. *European Journal of Medical Research*; 22:5, 2017.
- El-Anwar MW, El-Ahl S and Amer HS. Open reduction and internal fixation of mandibular fracture without rigid maxilla-mandibular fixation. *Int Arch Otorhinolaryngol*; 19: 314, 2015.
- Champy M, Lodde JP, Schmitt R, Jaeger JH, and Muster D. Mandibular osteosynthesis by miniature screwed plates via a buccal approach. *J Maxillofac Surg*; 6: 14–21, 1978.
- Gutwald R, Alpert B, and Schmelzesisen R. Principle and stability of locking plates. Presented at 67th meeting of Keio Medical Society. Tokyo; July 15, 2002.