

EFFECT OF PREOPERATIVE INHIBITION OF ORBICULARIS ORIS MUSCLE ACTION ON PHILTRUM LENGTH IN PRIMARY CLEFT LIP REPAIR

Rehab Elsharkawy* and Mamdouh Aboulhassan**

ABSTRACT

Hypothesis: Botulinum toxin injection before cleft lip repair will inhibit the Orbicularis Oris muscle action and decrease the tension applied on the wound edges during healing leading to improved esthetic outcome.

Methods: Thirty two patients, under 6 months of age, with complete unilateral cleft lip, were enrolled in this double-blind, randomized, placebo-controlled prospective study. Patients were randomly divided into two equal groups; in the BTX group, botulinum toxin type A (BTX-A) was injected while in the Placebo group normal saline was injected in 4 points in the subjacent orbicularis oris muscle on both edges of the cleft, one week before the primary lip repair. At six-month follow up patients were assessed, in blinded fashion, for length of philtrum ridge both in cleft and non-cleft sides as well as for scar width. Collected data were tabulated and statistically analyzed.

Results: Thirty patients completed the study. After 6 months, difference in philtrum length between cleft and non-cleft sides in the BTX group was significantly less than the placebo group ($P=0.001$). The scar width in the BTX group was also statistically significantly less than the Placebo group ($P=0.001$).

Conclusions: Inhibition of orbicularis oris muscle during wound healing by BTX injection, before primary repair of unilateral cleft lip, safely and effectively reduced the difference in philtrum length between cleft and non-cleft sides and it also reduced the width of the scar.

INTRODUCTION

Oral clefts are considered one of the most common examples of congenital craniofacial malformations.^{1,2,3} Surgical repair of the cleft

lip is based on reestablishing the continuity of the orbicularis oris muscle to reach a satisfactory functional and esthetic lip contour. But tension applied on the wound edges by the orbicularis oris muscle pull during healing process affects the

* Assistant Professor of Oral and Maxillofacial Surgery. Faculty of Dentistry. Cairo University.

** Professor of Pediatric Plastic Surgery. Faculty of Medicine, Cairo University

cosmetic outcome.⁴ Generally the muscles of facial expression lie superficially and create expressions by changing the tension of adjacent skin. Consequently, if the skin tension is perpendicular to a laceration or a surgical incision, it might increase the risk of unfavorable healing due to the distracting forces applied on the healing wound.⁵

The cosmetic outcome, associated with reconstructive and aesthetic surgery of cleft lip, is always a great concern for patients and may have a harmful emotional effect on these children. Most of the researches have focused on the treatment and revision of the scars rather than the Prophylaxis. So, early management even before the surgical repair might yield a better cosmetic appearance and require fewer treatments.⁶

Botulinum toxin (BTX) is a potent neurotoxin produced by the *Clostridium Botulinum* bacteria. The BTX type-A therapeutic uses came from the fact that it can cause prolonged inhibition of release of acetylcholine at the neuromuscular junction. This effect leads to local muscle paralysis. BTX-A is commonly used to decrease facial dynamic wrinkles. Recently it is also believed to improve scar quality by reducing wound tension during healing. In 2006, Gassner et al. reported that BTX injection tended to improve facial scars.⁷ In 2018, in a study done by Hu et al. they also concluded that early postsurgical botulinum toxin injections can produce better, narrower, and flatter facial surgical scars.⁸

Despite the different surgical methods and treatment modalities employed to improve quality of repair of cleft lip, hypertrophic scarring is still observed. So, in trying to improve results of the cleft lip repair, botulinum toxin injection around the cleft was suggested. Chang et al. in 2014, Assessed the Quality of surgical upper lip scars after injection of botulinum toxin, on adults undergoing cleft lip scar revision. They reported that the scar quality was significantly improved by the muscle temporary paralysis during wound healing.⁹

Based on the previous, the hypothesis of this study was that, injecting Botulinum toxin type-A into the orbicularis oris muscle on the edges of cleft lip, one week before cheiloplasty may minimize the scar width and improve the nasal and labial appearance.

PATIENTS AND METHODS

Thirty two male and female children, under 6 months of age, born with complete unilateral cleft lip were included in this study. Only primary non-syndromic cases were selected from the outpatient clinic of Department of Plastic Pediatric Surgery, the Specialized Pediatric Hospital- Cairo University. Family history was taken and patients were medically evaluated. Children with cardiac conditions or any associated medical condition that may affect the surgical operation were excluded from the study. Preoperative photographs were taken. Guardians were informed about the procedure; the possible postoperative complications and the study follow up schedule. Those who were willing to participation in the study had to sign an informed consent.

Patients were randomly divided into two equal groups; in group I (BTX group); 1.5 units/kg of Botulinum toxin-A (Botox; Allergan, Inc., Irvine, Calif.) was injected into the superior orbicularis oris muscle in 4 superficial sites 0.5cm away from the cleft edges. In group II (Placebo group), patients were injected with 1.5 unit/kg of normal saline around the cleft edges.

One week later the clefts were repaired by modified Millard cheiloplasty technique under general anesthesia. Oral antibiotic and Analgesic were prescribed to the patients for 7 postoperative days. The parents were instructed to clean the wound and apply antibiotic cream 3 times daily.

Patients were seen after one week to remove sutures and assess healing. Standard photographs were also taken for patients during this visit. Children were recalled again 6 months after the

surgery, where healing was assessed and patients were photographed again in a standardized manner. Using the image processing program (ImageJ program) the scar width and the philtrum length at the cleft side and non-cleft side were measured and recorded (fig.1).

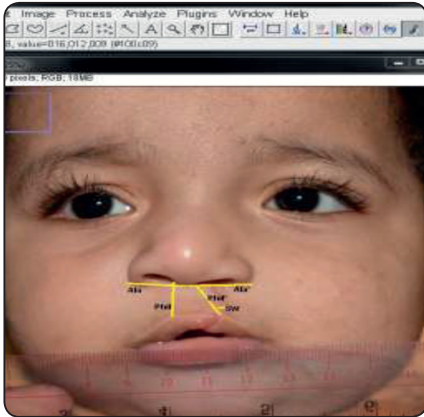

Fig. (1) Photograph showing patient at 6-moth follow up visit and measures using the ImageJ computer program.

Data were coded and entered using the statistical package SPSS version 25. Data was summarized using mean and standard deviation. Comparisons between groups were done using unpaired t test in normally distributed quantitative variables while non-parametric Mann-Whitney test was used for non-normally distributed quantitative variables. P-values less than 0.05 were considered as statistically significant.

RESULTS

Thirty patients completed the study, 15 in each group. They were 10 males and 5 females in the BTX group and 9 males and 6 females in the Placebo group. Patients' age at presentation ranged

from 3 to 6 months. In all operations blood loss was minimal and did not necessitate replacement during or after surgery. Post-surgical edema was within normal limit and subsided completely within a week. Healing after the surgery was generally uneventful in both groups and no complications such as infection, wound dehiscence, oral incontinence or feeding dysfunction were encountered.

Preoperative, immediate postoperative, one week and six-month postoperative standardized radiographs were takes for each patient (fig. 2). On these photographs, the scar width was measured at 6 months and the Mean \pm SD in the BTX group was 1.85 ± 0.58 while in the Placebo group it was 3.31 ± 0.51 . The BTX group had statistically significant less scar width than the Placebo group where the P value was <0.001 (fig.3).

Length of philtrum: Comparison between the 2 groups showed that here was no significant difference in the length of philtrum in cleft sides or non-cleft sides between the two groups (fig.4). However, when we measured the difference of the philtrum length in each group between the cleft and non-cleft sides, the difference in BTX group was 0.84 ± 1.31 , while in the Placebo group the difference was 2.34 ± 1.19 . Comparing the differences of the 2 groups revealed that the difference between non-cleft and cleft sides in the placebo group is statically significantly higher than that of the BTX group ($P=0.001$). In other words, BTX group has less difference in philtrum length between cleft and non-cleft sides. The mean \pm SD values of the philtrum length in cleft and non-cleft sides in BTX group and Placebo group are presented in Table 1.

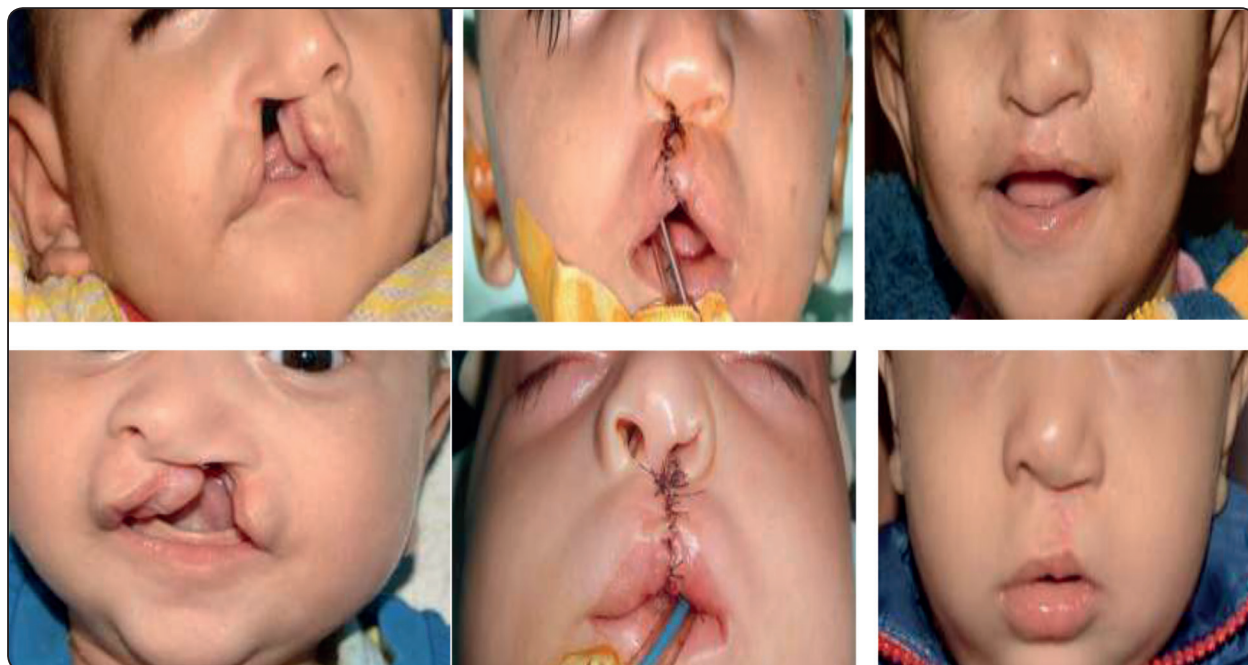

Fig. (2): Photographs showing patients in preoperative, immediate postoperative and six months postoperative views.

TABLE (1): Mean ± SD values of the philtrum length in cleft and non-cleft sides in BTX group and Placebo group.

	BTX group		Placebo group		P value
	Mean	SD	Mean	SD	
Cleft side Length of philtrum(mm)	8.32	2.12	6.83	1.71	0.026
Non-cleft side Length of philtraum (mm)	9.16	2.50	9.17	2.38	0.990
philtral ridge difference (non-cleft-cleft) (mm)	0.84	1.31	2.34	1.19	0.001

*Insignificant difference ($P > 0.05$)

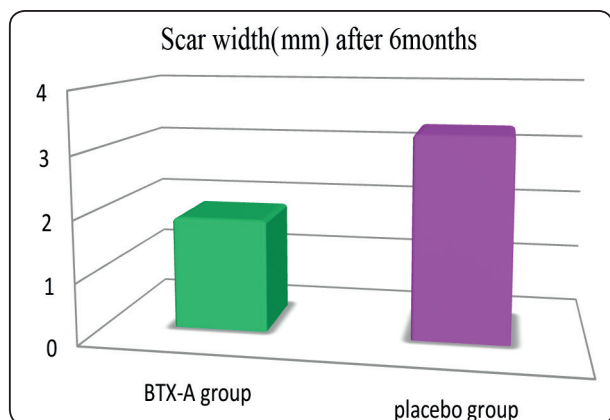


Fig. (3) Histogram showing the Scar width Mean ± SD comparison between groups after 6 months where the scar in the BTX group was significantly less in width than that of the control group.

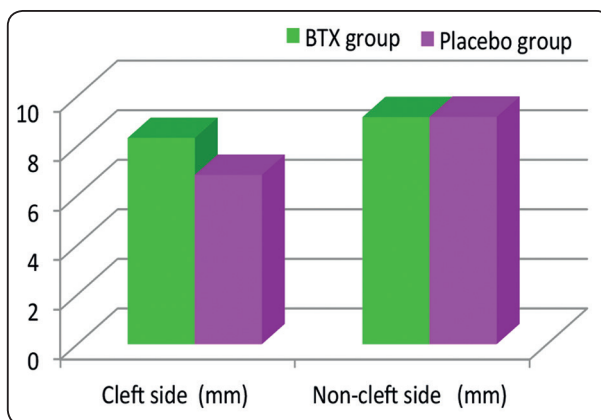


Fig. (4) Histogram showing the difference between the cleft sides in both groups and difference between non-cleft sides in both groups.

DISCUSSION

Upper lip injuries that occur at right angle to the relaxed skin tension lines are exposed to repetitive dynamic tension caused by the orbicularis oris muscle and they usually heal by unacceptable scarring. When surgical incisions are planned in the face, we try to hide them in the skin lines and avoid the muscle pull effect for better healing results. But in patients born with cleft lip deformity, we can't avoid dealing with wounds that are oriented at right angle to direction of the muscle pull. So, children born with this deformity would benefit from even a slight improvement in scar quality after repair.

In 1992, Carvajal et al. reported that children with repaired cleft lip with abnormal lip seal showed higher electromyographic (EMG) activity during the swallowing of saliva.¹⁰ In 2000, Ravera et al. added that a significantly higher level of superior orbicularis oris muscle electromyographic activity at rest as well as during swallowing in children with repaired unilateral cleft lip than other normal children. They also suggested a correlation between this hyperactivity and presence of shorter upper lip and abnormal lip seal.¹¹ Nine years after the work of Ravera et al., Galarraga confirmed the inhibition of the orbicularis oris muscle by using BTX during cleft lip repair by the EMG.¹² The results of our study, presence of less difference between the cleft and the non-cleft sides in the BTX group came in agreement with the previous conclusion that the orbicularis oris muscle increased activity correlates to shorter lip and inhibiting this activity may prevent the complication of shorter incompetent lip.

The increase in the muscle activity and consequently the increased tension applied on the healing wound edges, in the repaired cleft lip, increases the risk of an undesirable hypertrophic or widened scar. Especially if wound is orientated perpendicular to the direction of the underlying muscle fibers.¹³ Consequently, reducing tension around a wound is important for improving scar quality and reducing the incidence of hypertrophic

scars.¹⁴ These conclusions are in agreement with our results as we reduced the tension on the scar edges by the chmoimmobilization of the orbicularis oris muscle so we significantly succeeded in reducing the width of the scar in the BTX group than the placebo group. Similar result was reported by Chang et al., as they concluded that BTX injections produced narrower cheiloplasty scars. Although they also added that the BTX didn't affect scar pigmentation, vascularity, pliability, or height.⁹

In 2006, Tollefson et al. first reported satisfactory preliminary results when they tried BTX injection in 3 infants with bilateral cleft lip before the cheiloplasty.¹⁵ Similar satisfactory results were again reported by Salgado et al. after BTX-A injection in cleft lip patients before surgery.¹⁶ These studies contained a small sample size and they lacked clear evaluation parameters of the scar and esthetic outcomes. However, their reported satisfactory results were refined by our study as the BTX group showed smaller scar width and better philtral length at the cleft side which are good esthetic outcomes.

Similar to the two previous studies^{15,16} we chose to inject the BTX one week before the cheiloplasty. The reason for this is the fact that, following application of BTX-A, the clinical effect occurs within approximately 3 to 7 days, followed by 1 to 2 weeks of maximum effect, which then levels off to a moderate plateau until full nerve recovery within 3 to 6 months.¹⁷ Thus in the present study we planned to have the maximum effect of the drug to be reached at time of the surgery. Although Chang et al. used the BTX at the end of the cheiloplast surgery. Galárraga¹² also had a different opinion as he considered the intraoperative administration of BTX-A is appropriate because the children frequently suffer from upper respiratory tract infections that often delay the surgeries.

The selection of adequate number of units of BTX-A sufficient to decrease the muscle activity, yet harmless to the children was a tough task. Chang et al,⁹ used 1 unit/kg in 3 months old babies and

Tollefson et al. reported the efficiency and safety of using 1 to 2 units/kg of BTX in infants from 3 to 6 months.¹⁵ Accordingly in this study we safely and effectively used 1.5 units/kg in the infants between 3 to 6 months.

Generally the safety of using BTX in infants, younger than 2 years, was studied and confirmed by the work of Pascual-Pascual and Pascual-Castroviejo in 2009. They suggested that BTX-A is a dose dependent not related to age and its one of the safest drugs in the field of neurology.¹⁸ Same reports of the safety of the drug in infants were reported in other studies.¹⁶ Using this, infant's weight calculated, dose in this study was safe. At the end, we did not find any complications of using the drug and did not encounter any complaint from the parents, regarding the function of the mouth during feeding, throughout the follow up period.

CONCLUSIONS

Inhibition of Orbicularis Oris Muscle by Botulinum toxin injection before primary repair of unilateral cleft lip effectively reduced the difference in philtrum length between cleft and non-cleft-sides. The width of upper lip scar was also significantly improved by temporary paralysis of the surrounding muscles during wound healing.

REFERENCES

1. Calzolari E, Bianchi F, Rubini M, Neville AJ. Epidemiology of cleft palate in Europe: implications for genetic research. *Cleft Palate Craniofac J.* 2004; 41(3): 244–249.
2. Derijcke A, Eerens A, Carels C. The incidence of oral clefts: a review. *Br J Oral Maxillofac Surg.* 1996; 34: 488–494.
3. Mossey P, Castilla E. Global Registry and Database on Craniofacial Anomalies: Report of a WHO Registry Meeting on Craniofacial Anomalies, Baurú, Brazil. 2001. 2001 Geneva, Switzerland: World Health Organization.
4. Gassner, HG and Sherris DA. Chemoimmobilization: improving predictability in the treatment of facial scars. *Plast. Reconstr. Surg.* 2003; 112: 1464–6.
5. Gassner HG, Sherris DA, Otley CC. Treatment of facial wounds with botulinum toxin A improves cosmetic outcome in primates. *Plast Reconstr Surg.* 2000; 105:1948–1953.
6. Liu A, Moy RL, Ozog DM. Current methods employed in the prevention and minimization of surgical scars. *Dermatol Surg.* 2011; 37: 1740–1746.
7. Gassner HG, Brissett AE, Otley CC, Boahene DK, Boggust AJ. Botulinum toxin to improve facial wound healing: A prospective, blinded, placebo-controlled study. *Mayo Clin Proc* 2006; 81:1023–1028.
8. Hu L, Zou Y, Chang SJ, Qiu Y, Chen H, Gang M, Jin Y, Lin X. Effects of Botulinum Toxin on Improving Facial Surgical Scars: A Prospective, Split-Scar, Double-Blind, Randomized Controlled Trial. *Plast Reconstr Surg.* 2018; 141(3): 646-650.
9. Chang, CS, Wallace CG, Hsiao YC, Chang CJ and Chen PK. Botulinum Toxin to Improve Results in Cleft Lip Repair. *Plast. Reconstr. Surg.* 2014; 134: 511–516.
10. Carvajal R, Miralles R, Cauvi D, Berger B, Carvajal A, Bull R. Superior orbicularis oris muscle activity in children with and without cleft lip and palate. *Cleft Palate Craniofac J.* 1992; 29: 32–36.
11. Ravera MJ, Miralles R, Santander H, Valenzuela S, Villanueva P, Zúñiga C. Comparative study between children with and without cleft lip and cleft palate, part 2: electromyographic analysis. *Cleft Palate Craniofac J.* 2000; 37 (3): 286-91.
12. Galárraga, I. Use of botulinum toxin in cheiloplasty: A new method to decrease tension. *Can. J. Plast. Surg.* 2009; 75: 52–55.
13. Martel H, Walker DC, Reed RK & Bert JL. Dermal fibroblast morphology is affected by stretching and not by C48/80. *Connect. Tissue Res.* 2001; 42: 235–44.
14. Gurtner GC. et al. Improving cutaneous scar formation by controlling the mechanical environment: large animal and phase I studies. *Ann. Surg.* 2011; 254: 217–25.
15. Tollefson TT, Senders CM, Sykes JM & Byorth PJ. Botulinum toxin to improve results in cleft lip repair. *Arch. Facial Plast. Surg.* 2006; 8: 221–2.
16. Salgado M, Meier J and Tollefson, T. Botulinum Toxin in Cleft Lip Repair 3-D Videographic Analysis. *Otolaryngol.* 2009; 141: 35–35
17. Sadick, N. S. & Matarasso, S. L. Comparison of botulinum toxins A and B in the treatment of facial rhytides. *Dermatol. Clin.* 2004; 22: 221–6.
18. Pascual-Pascual SI and Pascual-Castroviejo I. Safety of botulinum toxin type A in children younger than 2 years. *Eur. J. Paediatr. Neurol.* 2009; 13: 511–515.