



## THE EFFECT OF TRIPLE ANTIBIOTIC PASTE ON PULP CAPPING OF PRIMARY TEETH. (CLINICAL AND RADIOGRAPHIC STUDY)

Salem A. Salem,\* Samy Y Baiomy \*\* and Abdallah A.\*\*\*

### ABSTRACT

The use of 3Mix can play a significant role in the dental management of pulp therapy for primary teeth. Where caries has penetrated into the deeper dentinal tissue, triple antibiotic paste may have a role depending on its antimicrobial effect. This study compared between the clinical, radiographic and microbiological effects of two medicaments; (3Mix and formocresol) on the remaining pulp tissue of the pulpotomized teeth, comprised 4 main groups. In the first and second groups, vital pulpotomy procedure was performed while the third and fourth groups, non-vital pulpotomy were done. The teeth were evaluated clinically and radiographically at different intervals (immediately post-operative, 6 weeks, and 3 months), the result show that antibiotic paste having promising clinical effect on primary teeth.

### INTRODUCTION

Pulpotomy is one of the most used frequently treatment for retaining cariously pulp involved primary teeth that would otherwise be extracted. Different materials have been used for performing pulpotomies of primary teeth. Formocresol (FC) has been a popular material of choice for pulpotomy procedure in the primary teeth, because of its ease in use and excellent clinical success. Concerns have been expressed about Formocresol pulpotomy because of inflammation and necrosis, cytotoxicity, systemic disturbance, mutagenic, carcinogenic potential and immunologic response<sup>(1)</sup>. Alternative dressing materials such as NaOCl, MTA, calcium hydroxide (CH), collagen, ferric sulfate (FS), Bio active glass, and bone morphogenic protein (BMP) ...etc., have been suggested as possible replacements for formocresol in vital and non-vital pulp therapy with varying success rate<sup>(2)</sup>.

Application of antibiotics can help in eradication of bacteria in exposed vital and non-vital teeth. With the advent of non-instrumentation

endodontic treatment, lesion sterilization and tissue repair, local application of antibiotics has been investigated<sup>(3)</sup>. Triple antibiotic paste (TAP) containing metronidazole, ciprofloxacin, and minocycline have been reported to be a successful regimen in controlling the root canal pathogen and in managing non-vital young permanent tooth<sup>(4)</sup>.

The aim of present study was comparing the effect of triple antibiotic paste as a capping material on cariously pulp involved vital and non-vital primary teeth

### Methodology

The present study was a longitudinal study comprising of eighty deeply carious primary molars with pulp involvement, from 80 child patients their ages ranged from (3- 8) years.

After a complete history was obtained and a thorough clinical examination was conducted, peri-apical radiographs of the intended tooth were obtained prior treatment from every child included in the study at definite intervals (preoperative, 24hours postoperative, after 6 weeks and after 3 months).

\* Demonstrator, Pedodontic and Oral Health Department Faculty of Dentistry, Al Azhar University.

\*\* Professor, Pedodontic and Oral Health Department Faculty of Dentistry, Al Azhar University.

\*\*\* Assistant Professor, Pedodontic and Oral Health Department Faculty of Dentistry, Al Azhar University.

The children were classified according to capping materials and tooth vitality into four equal groups; each group comprised of (20) primary molars teeth.

**Group (A);** Comprising 20 primary molars that received vital FC pulpotomy technique.

**Group (B);** The teeth of this group were received TAP vital pulpotomy technique.

**Group (C);** The teeth in this group were non-vital and received (mortal) FC pulpotomy technique.

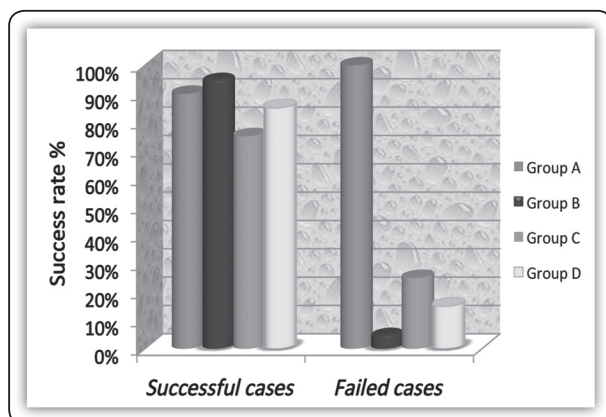
**Group (D);** The non-vital teeth of this group received TAP non-vital (mortal) pulpotomy technique.

#### *Clinical and radiographic criteria of success*<sup>(5-7)</sup>

- 1.No history of pain or discomfort.
- 2.No sensitivity to percussion.
- 3.No mobility.
- 4.No internal or external resorption.
5. No periodontal ligament space widening.
6. No apical or bifurcation radiolucent areas.

## RESULTS

In the first and second group, vital pulpotomy with formocresol gave raise a 90% success rate, while that with triple antibiotic paste was 95%. In the third and fourth groups, the success rate of non-vital pulpotomy with formocresol gave raise 75% success rate, while that with triple antibiotic paste was 85%



Character	Group (A)	Group (B)	Group (C)	Group (D)
Sub. No.	20	20	20	20
Success cases	18	19	15	17
Percentage Success cases	90%	95%	75%	85%
Failed cases	2	1	5	3
Percentage Failed cases	10 %	5%	25%	15%
Std. deviation( ±)	.30779	.22361	.444	.366
Std. error (+ )	0.06	0.05	0.099	0.081
Mean	0.90	0.95	0.75	0.85
Sig(four groups)	P= 0.243			
Sig.	A: B p=0.64		C: D p= 0.36	
	A:C p= 0.17		B: D p= 0.36	

## DISCUSSION

The current study investigates the availability of using triple antibiotic paste as a potent antibacterial and biocompatible pulp capping medicament in primary molars after three months of clinical and radiographic follow up in compare to formocresol pulpotomy in vital and non-vital pulp in primary molars.

On regard to the positive response observed in group A, the success rate was approximately (90%) This result was in agreement with Rolling and Thylstrup, 1975<sup>(8)</sup>, who recorded (92%) success rate, also with Hicks, 1986<sup>(9)</sup>, who reported the same success rate of this study. Moreover, Moretti et al., 2008<sup>(10)</sup> and Junior et al. 2013<sup>(11)</sup>, recorded 87% success rate of FC pulpotomy.

The high clinical and radiographic success rate of Group A in this study may attributable to formocresol germicidal action. The chemical bonding with the proteins of microorganisms is the basis of bactericidal action of formocresol and also to its fixative qualities. Although the study is imperative to suggest the clinical and radiographic success, it is difficult to forego the formaldehyde chemical action with reference to protein fixation<sup>(12, 13)</sup>.

The promising clinical outcome of vital pulpotomy performed with triple antibiotic paste (95% success rate) may be explained on the base that TAP was possess a potent antibacterial effect. Since Tetracycline inhibits collagenases and matrix metalloproteinases. Also, it is not cytotoxic, and increases the level of interleukin-10, an anti-inflammatory cytokine. In addition, metronidazole and ciprofloxacin can generate fibroblasts<sup>(14)</sup>. Moreover, TAP proved to be biocompatible and can help promote functional development of the pulp–dentin complex<sup>(15, 16)</sup>. The systemic administration of antibiotics relies on children patients' compliance, GIT absorption and circulatory system distribution to bring the drug to the infected site. Hence, local application of antibiotics within the root canal system may be a more effective mode for delivering the drug<sup>(17)</sup>.

The teeth included in the third and fourth groups were non-vital primary molars with invasion of microorganisms to the radicular pulp resulting in irreversible pulpitis and necrosis. At this stage, the radicular pulp is unable to recover and the preferred treatment is pulpectomy<sup>(18)</sup>. However, pulpectomy of primary molars is often impractical. Therefore, non-vital (mortal) pulpotomy technique is commonly used and preferred by clinicians<sup>(19)</sup>.

Considering the TAP success rate (85%), its results are in agreement with Nakornchi et al., 2010 (84%)<sup>(20)</sup>, Pinky et al., 2011 (90%)<sup>(21)</sup>, Trairatvorakul et al., (2012) (75%)<sup>(22)</sup> and Duanduan A et al., 2013 (86.6%)<sup>(8)</sup> who evaluated success rate of TAP on necrotic primary molars. However, they enlarged the orifice of the roots to create a medication cavity (1mm diameter and 2 mm depth). In comparing with the vital teeth results, these relatively higher failure rates of both materials in non-vital molars may be referred to pulp vitality and healthy tissues reactivity.

The teeth positive response to TAP in case of non-vital pulpotomy is depending on the combination of three drugs to address the diverse flora encountered and decrease the likelihood of the de-

velopment of resistant bacterial strains. The infection of the root canal system is considered to be a polymicrobial infection, consisting of both aerobic and anaerobic bacteria<sup>(23, 24)</sup>. This promising combination of metronidazole, ciprofloxacin, and minocycline was investigated by Sato et al., in vitro. They found that it is very effective in the sterilization of carious lesions, necrotic pulps, and infected root dentin of deciduous teeth<sup>(25)</sup>. However, none of these drugs alone could result in complete elimination of bacteria<sup>(26, 27)</sup>.

In the present study, radiographic investigation revealed an improvement, at the end of the follow up period (3 months) with both TAP and formocresol treated teeth. This was seen through a gradual decrease of radiolucency. This finding agrees with other studies<sup>(28, 21, 8, 22)</sup>, since clinical and radiographic results revealed success at the aforementioned intervals. However, TAP proved promising better healing ability and positive responses than formocresol in both vital and non-vital pulpotomies.

## CONCLUSION

Based on the study finding it could be concluded that triple antibiotic paste can be used in primary teeth vital pulpotomy as a biocompatible material offers a good healing potential, leaving the remaining pulp tissue healthy and functioning.

## REFERENCE

1. Majid B, Pouya P, Sepanta H, Golnoush J, and Mostafa Z. Plasma Level Formaldehyde in Children Receiving Pulpotomy Treatment under General Anesthesia. *J of Clin Pediatr Dentistry* 2017; 41(2): 95-101.
2. Fuks AB. Vital pulp therapy with new materials for primary teeth: new directions and treatment perspectives. *Pediatr Dent* 2008 May-Jun; 30(3):211-19.
3. Duanduan A. Retrospective study of pulpectomy with Vitapex and LSTR with three antibiotics combination (3mix) for non-vital pulp treatment in primary teeth. *CMU J Nat Sci* 2013;12(2):131-39.
4. Ahmed HM. Pulpectomy procedures in primary molar teeth. *European J Gen Dent* 2014; 3:3-10.

5. Vostatek SF, Kanellis MJ, Weber-Gasparoni K, Gregorsok RL. Sodium hypochlorite pulpotomies in primary teeth: a retrospective assessment. *Pediatr Dent*. 2011;33(4):327–32.
6. Al-Mutairi MA, Bawazir OA. Sodium hypochlorite versus Formocresol in primary molars pulpotomies: a randomized clinical trial. *Eur J Paediatr Dent*. 2013; 14(1):33–6.
7. Alacam A, Odabas ME, Tuzuner T, Sillelioglu H, Baygin O. Clinical and radiographic outcomes of calcium hydroxide and formocresol pulpotomies performed by dental students. *Oral Surg Oral Med Oral Pathol Oral Radiol Endod*. 2009; 108(5):127–33.
8. Rölling, I. N. G. E., and Anders Thylstrup. "A 3-year clinical follow-up study of pulpotomized primary molars treated with the formocresol technique." *European J of Oral Sciences*.1975;83(2): 47-53.
9. Hicks, M. J., E. S. Barr, and C. M. Flaitz. "Formocresol pulpotomies in primary molars: a radiographic study in a pediatric dentistry practice. *J of pedo*.1985; 10(4): 331-39.
10. Moretti AB, Sakai VT, Oliveira TM, Fornetti AP, Santos CF, Machado MA et al. The effectiveness of mineral trioxide aggregate, calcium hydroxide and formocresol for pulpotomies in primary teeth, *IntEndod J*. 2008 Jul;41(7):547-55.
11. McRae, R., Bagchi, P., Sumalekshmy, S., and Fahrni, C. J. In situ imaging of metals in cells and tissues. *Chemical Reviews*.2009; 109(10).
12. Thavarajah and Rooban. "Chemical and physical basics of routine formaldehyde fixation." *Journal of oral and maxillofacial pathology: JOMFP*2012; 16(3): 400.
13. Chandrashekhar, Shashidhar, and Jyothi Shashidhar. "Formocresol, still a controversial material for pulpotomy: A critical literature review." *J of Restorative Dent*. 2014; 2(3): 114.
14. Vijayaraghavan R, Mathian VM, Sundaram AM, Karunakaran R, Vinodh S. Triple antibiotic paste in root canal therapy. *J of Pharmacy & Bioallied Sciences*. 2012; 4(2): 230-33.
15. Bose R, Nummikoski P, Hargreaves K. A retrospective evaluation of radiographic outcomes in immature teeth with necrotic root canal systems treated with regenerative endodontic procedures. *J Endod*. 2009;35:1343–9
16. Gomes-Filho JE, Duarte PCT, de Oliveira CB, Watanabe S, Lodi CS & Cintra LTA. Tissue reaction to a triantibiotic paste used for endodontic tissue self-regeneration of non-vital immature permanent teeth. *J Endo*. 2012; 38:91–4.
17. Huang GT. A paradigm shift in endodontic management of immature teeth: Conservation of stem cells for regeneration. *J Dent*. 2008; 36:379–86.
18. Mohammad, Shukry Gamal, and Kusai Baroudi. "Assessment of the potential of Allium sativum oil as a new medicament for non-vital pulpotomy of primary teeth." *J of Inter Society of Preventive & Community Dentistry* 2015; 5(4): 314.
19. Mohammad, Shukry Gamal, and Kusai Baroudi. "Bacteriological evaluation of Allium sativum oil as a new medicament for pulpotomy of primary teeth." *J of Inter Society of Preventive & Community Dent*. 2015; 5(2): 125.
20. Nakornchai S, Banditsing P, Visetratana N. Clinical evaluation of 3Mix and Vitapex as treatment options for pulpally involved primary molars. *Inter J of pediatr Dent / the British pedodontic Society {and} the International Association of Dentistry for children*, 2010 May; 20(3):214-21.
21. Pinky C, Shashi Bhushan KK, Subbareddy .V.V. Endodontic treatment of necrosed primary teeth using two different combinations of antibacterial drugs: An in vivo study. *J of the Indian society of pedo and Prev Dent*, 2011; 29(2): 121-27.
22. Trairatvorakul, Chutima, and Palinee Detsomboonrat. "Success rates of a mixture of ciprofloxacin, metronidazole, and minocycline antibiotics used in the non-instrumentation endodontic treatment of mandibular primary molars with carious pulpal involvement." *Inter j of paediatr dentistry*.2012;22(3): 217-227
23. Bergenholtz G. Micro-organisms from necrotic pulp of traumatized teeth. *Odontol Revy* 1974; 25:347–58.
24. Fabricius L, Dahlen G, Ohman AE, Moller AJ. Predominant indigenous oral bacteria isolated from infected root canals after varied times of closure. *Scand J Dent Res* 1982; 90:134–44.
25. Sato T, Hoshino E, Uematsu H, Noda T. In vitro antimicrobial susceptibility to combinations of drugs on bacteria from carious and endodontic lesions of human deciduous teeth. *Oral Microbiol Immunol* 1993; 8:172–76.
26. Hoshino E, Kurihara-Ando N, Sato I, Uematsu H, Sato M & Kota K . In-vitro antibacterial susceptibility of bacteria taken from infected root dentine to a mixture of ciprofloxacin, metronidazole and minocycline. *Int Endod J* 1996; 29:125–30.
27. Sato I, Ando-Kurihara N, Kota K, Iwaku M, Hoshino E. Sterilization of infected root-canal dentine by topical application of a mixture of ciprofloxacin, metronidazole and minocycline in situ. *Int Endod J* 1996; 29:118 –24.
28. Meyer F. W. and Sayegh F. S. Wound healing following curettement of bifurcation abscesses of human primary molars. *Oral Surg*.1979; 47(3): 267-74.