



## EVALUATION OF PILOCARPINE POTENTIALITY TO COUNTERACT THE RAT PAROTID GLAND STRUCTURAL ALTERATIONS INDUCED BY GAMMA IRRADIATION

Said M. Hani<sup>\*</sup>, Abd Elnasser A. Elmawla<sup>\*\*</sup>, Ashraf M. Emran<sup>\*\*\*</sup> and Salwa F. Ahmed<sup>\*\*\*\*</sup>

### ABSTRACT

The effect of pilocarpine on irradiation induced rat parotid gland structural alterations was evaluated in 45 adult male Sprague-Dawley rats used in this study and they were divided into three groups, 15 rats each. The control group rats did not expose to pilocarpine nor radiation. The experimental group II rats were irradiated while those of group III were primarily treated by pilocarpine before irradiation. At 1, 4 and 16 weeks after irradiation exposure, 5 rats from each group were euthanasially decapitated. Then the parotid glands were carefully dissected out and prepared for stain by hematoxylin and eosin stain. The histological examination showed that radiation induced harmful effects on the parotid gland were significantly reduced with pilocarpine. Conclusion: Pilocarpine, the parasympathomimetic agonist known to stimulate the various exocrine glands, has considerable improvement for the injurious radiation effects on salivary glands.

### INTRODUCTION

Salivary gland function plays an important role in oral health including food digestion, protection of oral mucosa, remineralization of dental hard tissues, and moistening the palate for articulation<sup>(1)</sup>. Head and neck cancer is the fifth most common malignancy worldwide<sup>(2)</sup>. Each year about 500,000 patients world-wide were treated for head and neck cancer. The majority of these patients were treated with radiotherapy either alone or in combination with other treatment modalities such as surgery and/or chemotherapy<sup>(3,4)</sup>.

Radiation-induced damage to salivary glands results in xerostomia (dry mouth), and the affected patients have both compromised quantity and quality of saliva that can affect the emotional and systemic well-being of these individuals<sup>(5)</sup>. Such patients suffer from increased oral infections,

difficulty in speaking, difficulty in swallowing food, and problems with digestion. Various studies have noted that over a 50% reduction in parotid gland function within a few days after exposure of the head and neck region to low doses of irradiation<sup>(6)</sup>. In the human, the parotid gland is more radiosensitive when compared to the submandibular gland and the high sensitivity of the parotid gland has been suggested to be due to the predominance of serous cells in this gland as these epithelial cells appear to be the most radiosensitive<sup>(7,8)</sup>.

Pilocarpine is a naturally occurring compound derived from the South American shrub, the *Pilocarpus jaborandi*. This alkaloid plant simulates a cholinergic parasympathomimetic agonist that can bind to the muscarinic-M3 receptors and can also cause pharmacological smooth muscle contraction and stimulation of the various exocrine glands<sup>(9)</sup>.

\* Professor of Oral Histology and Pathology, Oral biology department, faculty of dental medicine, Azhar University.

\*\* Assistant Professor of Oral histology, Oral biology department, faculty of dental medicine, Al-Azhar University.

\*\*\* Demonstrator of oral histology, Oral Biology Department, faculty of dental medicine, Al-Azhar University.

\*\*\*\* Lecture in Health Radiation Research Department, National Center for Radiation Research and Technology.

Pilocarpine is currently used to treat xerostomia caused by Sjogren's syndrome or dryness emerged as a consequence of radiotherapy<sup>(10)</sup>. However, in a recent study, the pilocarpine was shown to also counteract the oral dryness and the xerostomia induced by the drug treatment<sup>(11)</sup>.

The purpose of this study is to investigate the efficiency of the prior treatment of pilocarpine as a protector agent against the radiation induced parotid glands damage.

## MATERIALS AND METHODS

45 adult male Sprague- Dawley rats weighing 150-250 g were used in this study. The experiment was performed after accommodation period in the laboratory environment for 7 days. The rats were housed at the animal house of National Center for Radiation Research and Technology (NCRRT), Cairo, Egypt in a room with controlled temperature  $25^{\circ}\text{C} \pm 2^{\circ}\text{C}$ , humidity  $50\% \pm 5\%$ , and about 12-hour light/dark cycle and were fed on chew and water ad libitum. The whole-body irradiation of animals was performed at National Center for Radiation Research and Technology (NCRRT), Cairo, Egypt, using Gamma cell 40. All animals were exposed to a dose of 6 Gy (Cs <sup>137</sup>) a dose rate of 0.43 Gy / mi. The animals were divided randomly into 3 main groups, 15 rats each as follows: Control group (GI): the animals received neither irradiation nor drug, Radiation group (GII): the rats were exposed to a single whole body  $\gamma$ -irradiation at dose of 6 Gy, Pilocarpine-Radiation group (GIII): the rats were injected intraperitoneally by a single dose of pilocarpine (0.2 mg/kg) (Sigma Chemical Co., St. Louis, MO) dissolved in 1ml of normal saline then exposed to a single whole body  $\gamma$ -irradiation at dose of 6 Gy. At 1, 4 and 16 weeks after irradiation exposure, 5 rats from each group were euthanasiually decapitated and the parotid glands were carefully dissected out and immediately fixed in neutral calciformol solution for 72 hours. The salivary glands were processed micro technically,

that is, embedded in paraffin wax and paraffinized tissue sections were cut at 5-7  $\mu\text{m}$  thick and stained hematoxylin and eosin stain (Bancroft and Gamble, 2002)<sup>(12)</sup> for general histological investigations to detect the histological changes.

## RESULT

### Control group

The histological features of parotid gland collected after 1, 4, and 16 weeks of control group showed no structural differences. The glands were composed of parenchyma and connective tissue stroma. The parenchyma was consisted of several lobes divided into lobules interspersed through the connective tissue stroma without connective tissue capsule. The lobes and lobules were composed of tightly packed serous acini (Fig. 1). Some intercalated, striated and secretory ducts were also observed. The acinar cells appeared pyramidal in shape with a basally located oval or round basophilic nuclei and deeply basophilic cytoplasm. The intercalated duct cells were cuboidal in shape with large rounded centrally located nuclei, while the striated duct cells were columnar with pale centrally located nuclei and basal striation. The stroma consisted of connective tissue containing the classical connective tissue cells and fibers.

### Radiation group:

One-week post-irradiation, the parotid gland was severely affected by gamma irradiation. The irradiation provoked many destructive changes including the massive loss of acinar architecture, severe acinar atrophy and acinar degeneration. The degenerative effects of irradiation on the gland also included widely distributed acinar cell and variable sized lipid vacuolations. The acinar cells showed also nuclear pleomorphism, hyperchromatism and perinuclear hallow in some areas of the gland. The destructive manifestations of the ducts included extensive loss of ductal architecture, ductal cell vacuolations or even destruction and perinuclear hallow of ductal cells. (Fig. 2).

Four weeks post-irradiation, the gland in general showed slightly less intense degenerative changes than those noted after one week. In some areas of the gland, moderate acinar atrophy was seen throughout the gland, while the degeneration of acini was restricted to less and discrete areas rather than the diffuse and multiple atrophy seen after one-week post-irradiation. The acinar cell vacuolation, pleomorphism and hyperchromatism were demonstrated but at slightly less distributed pattern were markedly reduced when compared to the existing vacuolation after one-week post-irradiation group. The ducts showed some cellular vacuolations, while the others demonstrated loss of architecture and degeneration (Fig. 3).

Sixteen weeks post-irradiation, the gland showed a marked reduction in the intensity and distribution of the degenerative affections. The acinar atrophy was mild and only restricted to small and widely distributed areas through the gland and the acinar degeneration was absent in most areas of the gland. The nuclear pleomorphism was markedly diminished but only exhibited in some areas of the gland while the ducts appeared with normal cellular architecture absent ductal cell vacuolation and degeneration (Fig. 4).

#### Pilocarpine-irradiation group:

One-week post-irradiation, variable degrees of degenerative changes have occurred in response to pilocarpine administration before the radiation exposure. The gland showed moderate acinar atrophy, while the acinar degeneration was only confined to some areas in the gland and while some acinar cells showed nuclear pleomorphism. The ducts demonstrated almost intact architecture, while some duct cells appeared with few and small cellular vacuolations. The periductal vasculature was congested with numerous stagnated blood cells. While mild inflammatory cell infiltration occurred throughout the parenchymatous tissue (Fig. 5).

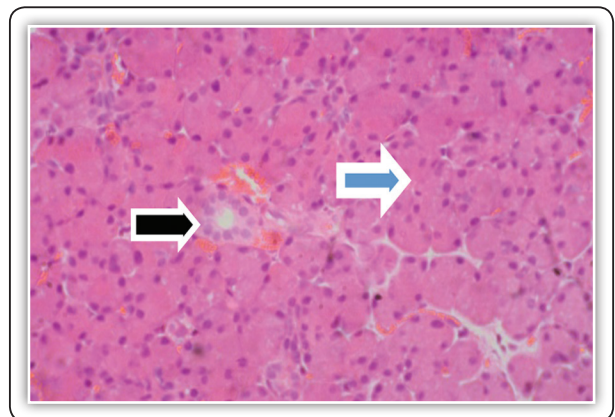


Fig (1): parotid gland (G I) showing normal acinar architecture (blue arrow), and striated duct (black arrow).

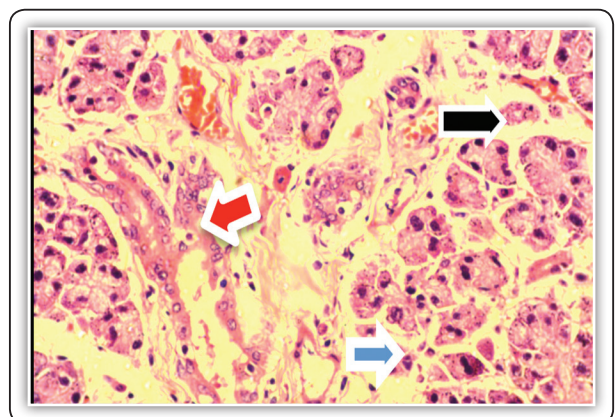


Fig (2) parotid gland of (G II one-week post-irradiation) showing sever acinar atrophy and degeneration (black arrow), nuclear hyperchromatism and pleomorphism (blue arrow), and perinuclear hallow of destructed duct cells (red arrow). (H&E x400)

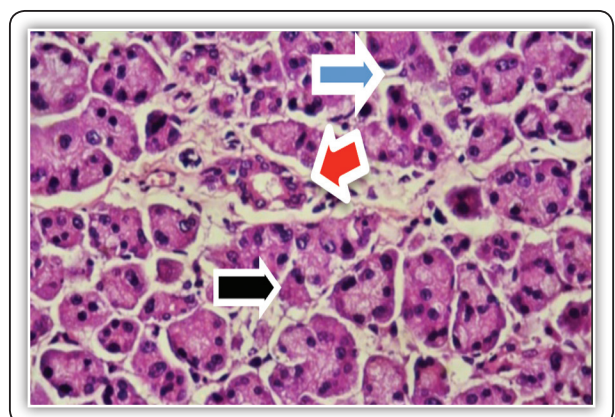


Fig (3): parotid gland (G II B 4-week post-irradiation) showing mild acinar atrophy (black arrow), nuclear hyperchromatism and pleomorphism (blue arrow). Some duct cells show perinuclear hallow vacuolation (red arrow).

Four weeks post-irradiation, the pilocarpine administration demonstrated better integrity in the structural architecture of the gland than the glandular changes noted after one week after pilocarpine and radiation. The acinar atrophy was only restricted to few widely dispersed acini, while the acinar degeneration was almost absent. Some acinar cells were still exhibited nuclear pleomorphism. The ducts showed intact architecture in most majority of the gland, while scanty ducts showed structural breakdown and slight periductal inflammatory cell infiltration and intense fibrosis were seen replacing the degeneration periductal acini (Fig. 6).

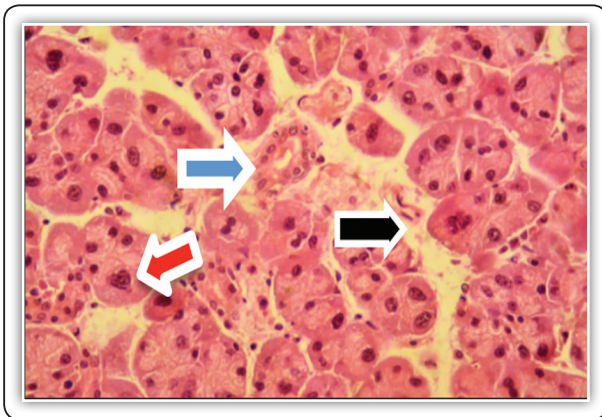


Fig (4) parotid gland (GII C,16-week post-irradiation) showing slight acinar atrophy (black arrow) and intact ductal architecture (blue arrow), while some acinar cells show slight nuclear pleomorphism (red arrow). (H&E x400)

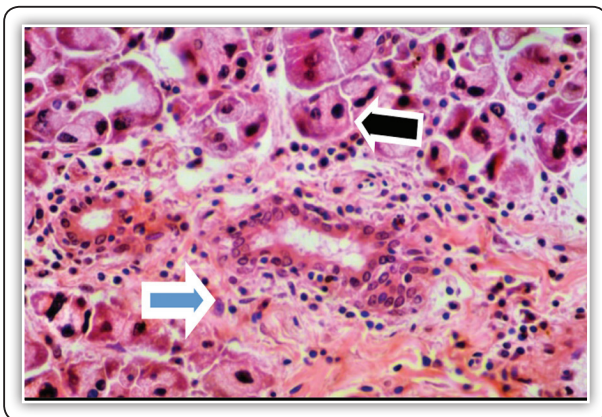


Fig (6): parotid gland group III (4-week post- pilocarpine and radiation) showing variable acinar atrophy and pleomorphism (black arrows) and slight periductal inflammatory cell infiltration and intense fibrosis (blue arrow) (H&E x400)

Sixteen weeks post-irradiation, the glands exhibited tilt toward the normal architecture where scanty acinar atrophy occurred in some areas of the gland, while most of the gland did not. The acinar vacuolation and degeneration were almost absent in the gland. Some acinar cells showed nuclear pleomorphism but with very limited distribution. Most of the ducts appeared with intact architecture and well-arranged duct cells. However, some ducts have undergone destruction except the striated ducts which appeared resistant to the degenerative changes (Fig.7).

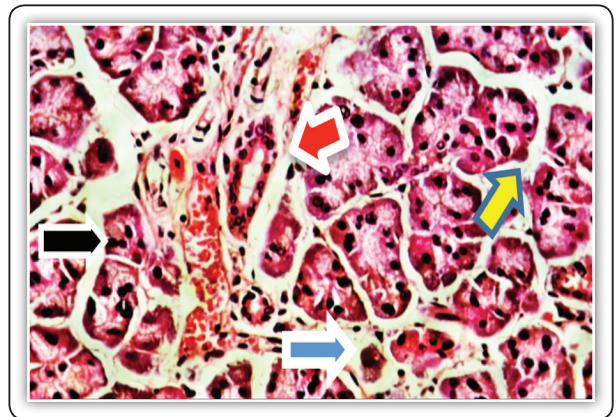


Fig (5): parotid gland group III (one-week post-pilocarpine and radiation) showing moderate acinar atrophy (yellow arrow) to intense acinar atrophy (black arrow) with nuclear pleomorphism (blue arrows) while duct cells show vacuolation (red arrow). The periductal vasculature is congested with numerous stagnated blood cells (white arrow).

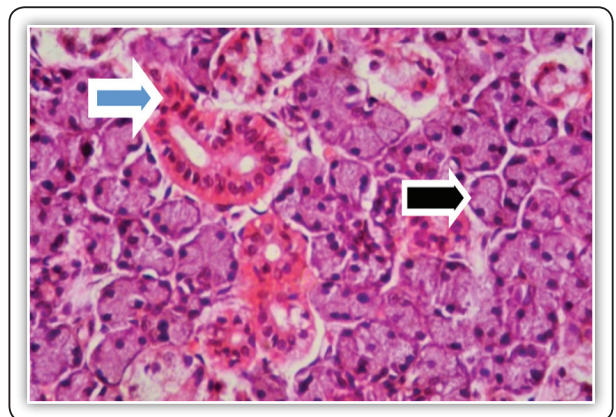


Fig (7): parotid gland group III (16 weeks post- pilocarpine and radiation) showing slight acinar atrophy (black arrow) while the ductal architecture is intact(bluearrow) (H&E x 400).

## DISCUSSION

Several causes of impaired salivary secretion have been reported, including irradiation therapy to the head and neck area<sup>(13)</sup>. The salivary glands are the most affected organ by irradiation in this area and the irradiation induced alterations are variable among the different glands. The present study demonstrated many degenerative changes in the salivary glands when they are exposed to irradiation. The radiation has induced destructive changes in the investigated parotid glands, which were demonstrated in the present findings and included the massive injuries of both the acinar and ductal architecture as the acinar atrophy, intracytoplasmic vacuolation and degeneration with the nuclear changes including the pleomorphism and hyperchromatism. These degenerative changes were demonstrated with variable degrees among the parotid and submandibular glands and findings were comparable with those reported in the previous studies<sup>(14-17)</sup>.

The atrophic changes of serous acini and the ductal elements, observed in the parotid and were also documented in other studied.<sup>(15,18)</sup> The acinar atrophic changes which were more obvious and progressive in the serous acini of parotid glands, noted in the present study were also observed in relation with the hyper fractionated, accelerated and conventionally fractionated radiotherapy of the rhesus monkey.<sup>(16)</sup>

Moreover, the results of the present study showed the absence of predominant and acute inflammation in the irradiated salivary glands and this event was also reported by O'Connell et al<sup>(19)</sup>. There is evidence that the early loss of acini by radiation is due to apoptotic cell death in monkeys<sup>(20)</sup>. However, periductal chronic inflammatory cells infiltration was associated with fibrosis replacing degenerated periductal acini may indicate a previous inflammation has been repaired by fibrous tissue.

The early response resulting in the atrophic changes of the secretory cells, without inflammation were presumed to be due to radiation-induced apoptosis, while the late response with inflammation could be the result of radiation-induced necrosis<sup>(20)</sup>. Other investigators, however, have proposed that the progressive loss of acini in the parotid and submandibular glands can be correlated to the activation of mast cells and the release of their secretory products<sup>(17)</sup>.

The present study has demonstrated the radiation-induced nuclear pleomorphism and hyperchromatism. These nuclear changes were also demonstrated in previous investigation which recorded hyperchromatism in the gland cell nuclei of mice early after a local irradiation with a single dose of 7.5 Gy<sup>(21)</sup>. The present study has also demonstrated the relative variable effect of pilocarpine as prophylactic measure against the harmful effects of irradiation on the parotid gland structure.

The improved salivary gland function has been observed in rats when degranulation was stimulated by pilocarpine administration prior to the radiation exposure.<sup>(22)</sup> The involvement of the serous secretory granules associates with the increased damage caused by ionizing radiation was further confirmed by Nagler et al.<sup>(22)</sup> and Coppes et al.<sup>(23)</sup>.

The salivary glands have been suggested to have dual innervation, since it has been observed that the Para sympathectomy can prevent the attainment of the adult gland size, the normal proliferation and the DNA and RNA content, while the sympathectomy has only moderate influence on the cells and gland size<sup>(24)</sup>. This may explain the curative potentiality of the administration pilocarpine in the present study against the harmful radiation effect. this may also be indicated through the observation that the pilocarpine hydrochloride is known as a cholinergic parasympathomimetic agent exerting a broad spectrum of pharmacologic effect with predominant muscarinic action and in appropriate dosage it can increase the secretion of exocrine glands<sup>(9)</sup>.

## CONCLUSIONS

- 1- Gamma radiation has deleterious on the histological structure of parotid and submaxillary salivary glands.
- 2- The parotid gland is the mostly affected by radiation than the submandibular gland .
- 3- Pilocarpine, the Para sympathomimetic agonist known to stimulate the various exocrine glands, has considerable improvement for the injurious radiation effects on salivary glands .

## RECOMMENDATION

Pilocarpine application prior to radiation exposure is recommended as a protective measure for securing the integrity of salivary glands against radiation injury.

## REFERENCES

1. Grisius MM, Fox PC: Salivary gland dysfunction and xerostomia. *Front Oral Biol.* 1998; 9:156-167.
2. Eduardo M., Erich M., George E., Anita L., and Gary C: *Neoplasms of the Head and Neck* 2003, BC Decker Inc.
3. Vissink A, Burlage FR, Spijkervet FK, Jansma J, Coppes RP: Prevention and treatment of the consequences of head and neck radiotherapy. *Crit Rev Oral Biol Med.* 2003; 14:213–225.
4. Vissink A, Jansma J, Spijkervet FK, Burlage FR, Coppes RP: Oral sequelae of head and neck radiotherapy. *Crit Rev Oral Biol Med.* 2003;14:199–212.
5. Wright WE.: Management of oral sequelae. *J Dent Res.* 1987;66:699–702.
6. Nagler RM.: The enigmatic mechanism of irradiation-induced damage to the major salivary glands. *Oral Diseases.* 2002;8:141–146.
7. Baum BJ, Bodner L, Fox PC, Izutsu KT, Pizzo PA, et al.: Therapy induced dysfunction of salivary glands: Implications for oral health. *Spec Care Dent.* 1985; 5:274–275.
8. Kashiima HK, Kirkham WR, Andrews JR.: Post-irradiation sialadenitis: a study of the clinical features, histopathological changes, and serum enzyme variations following irradiation of human salivary glands. *Am J Roentgenol Radium Ther Nucl Medical.* 1965;94: 271–291.
9. Taylor P., Goodman. and Gilman's. *The Pharmacologic Basis of Therapeutics.* 8th ed. New York, NY Pergamon Press Inc 1990, pp.122-130.
10. Porter SR., Scully C. and Hegarty AM.: An up date of the etiology and management of xerostomia. *Oral Surg Oral Med Oral Pathol Oral Radiol Endod,* 2004, 97:28–46.
11. Berk L.: Systemic pilocarpine for treatment of xerostomia. *Expert Opin Drug Metab Toxicol,* 2008, 4:1333–1340.
12. Bancroft., J D. and Gamble M. : *Theory and Practice of Histological Technique.* Churchill Livingstone. Edinburgh London New York Oxford Philadelphia St Louis Sydney Toronro. 2002, 5<sup>th</sup> Ed. pp. 125-242.
13. Moutsopoulos HM.: Sjogren's syndrome: autoimmune epithelitis. *Clin Immunol Immunopathol* 1994, 72: 162–165.
14. Ahlner BH., Hagelqvist E., Lind MG. and Ruden BI: Irradiation of rabbit submandibular glands. *Histology and morphometry after 15 Gy. Acta Otolaryngol.;* 1993, 113(2):210-219.
15. Henriksson R., Fröjd O., Gustafsson H., Johansson S., Yi-Qing C., Franzén L. and Bjermer L: Increase in mast cells and hyaluronic acid correlates to radiation-induced damage and loss of serous acinar cells in salivary glands: the parotid and submandibular glands differ in radiation sensitivity. *Br. J. Cancer;* 1994, 69(2):320-326.
16. Price RE., Ang KK., Stephens LC. and Peters LJ: Effects of continuous hyperfractionated accelerated and conventionally fractionated radiotherapy on the parotid and submandibular salivary glands of rhesus monkey. *Radiother. Oncol.;* 1995, 34:39–46..
17. Sagowski C., Wenzel S., Riehle I., Tesche S., Jenicke L., and Zywiets F.: Histomorphologic and salivary gland scintigraphic findings in radiation-induced sialadenitis due to fractionated irradiation of the head and neck region of rats. A model for evaluating potentially radioprotective substances. *HNO.;* 2004, 52(1):25-32.
18. Barbara A., Leslie .and James W.: Ionic Mechanisms in Secretagogue induced Morphological Changes in Rat Parotid Gland. *J cell biol,* 1983, 1119-1130.

19. O'Connell AC., Redman RS., Evans RL. and Ambudkar IS: Radiation-induced progressive decrease in fluid secretion in rat submandibular glands is related to decreased acinar volume and not impaired calcium signaling. *Radiat. Res.*; 1999, 151(2):150-158,
20. Guchelaar HJ., Vermes A. and Meerwaldt JH.: Radiation-induced xerostomia: pathophysiology, clinical course and supportive treatment. *Support Care Cancer*; 1997, 5(4):281-288.
21. Urek MM., Bralic M., Tomac J., Borcic J., Uhac I., Glazar I., Antonic R. and Ferreri S: Early and late effects of X-irradiation on submandibular gland: a morphological study in mice. *Arch. Med. Res* 2005, 6(4):339-343.
22. Nagler RM: Effects of head and neck radiotherapy on major salivary glands--animal studies and human implications. *In Vivo*; 2003, 17(4):369-375.
23. Coppes RP., Vissink A. and Konings AW.: Comparison of radiosensitivity of rat parotid and submandibular glands after different radiation schedules. *Radiother. Oncol.* 2002, 63:321-328.
24. Hani SM. *Oral and Dental Histology*, Bill print, Cairo, Egypt. part 2-second edition- 2003 pp322-323.