



## CHEMOPREVENTIVE EFFICACY OF CARVACROL ON EXPERIMENTALLY INDUCED HAMSTER BUCCAL POUCH CARCINOGENESIS

Hassan Ali Mohamed\*, Amr Saad Abd-Al-Wahab\*\* and Mohamed Gomaa Attia Zouair\*\*\*

### ABSTRACT

The aim of the present study was directed to investigate the chemopreventive efficacy of carvacrol on experimentally induced hamster buccal pouch(s) (HBP(s)) carcinogenesis utilizing Bcl-2 and Bax as apoptotic markers. **Material and methods:** Fifty five Syrian male hamsters, five weeks old, weighing 80-120 gm. The animals were divided into three groups (G(s)) (GI, GII and GIII): GI (negative control): 5 animals were left untreated. GII: (DMBA painted group): the right BPs of 20 animals were painted with 0.5% DMBA in paraffin oil 3 times a week on alternative days; they were subclassified into two subgroups (GIIA and GIIIB). GIIA: the right BPs of 10 hamsters were painted with DMBA for 6 weeks. GIIIB: the right buccal pouches of 10 hamsters were painted with DMBA for 14 weeks. GIII (carvacrol chemoprevention group): 30 hamsters were received carvacrol by the oral route using a specific vehicle in a dose of 15mg/kg; they were subclassified into two subgroups (GIIIA and GIIIB). GIIIA: 15 hamsters were given carvacrol one week before, as well as, during DMBA application for 6 weeks. GIIIB: 15 hamsters were given carvacrol one week before, as well as, during DMBA application for 14 weeks. **Results:** Gross observation revealed that, there is reduction in the size and distribution of tumors in the GIII compared to that observed in GII. Histopathological findings using H&E stain demonstrated variable changes in the GIII ranging from decrease severity to complete absence of dysplastic features compared to those observed in GII. Immunohistochemical (IHC) results of GIII revealed an increased Bax expression and decreased Bcl-2 expression compared to that observed in GII. **Conclusion:** The incidence of HBP carcinogenesis was prevented and decreased by oral administration of carvacrol with variable degrees, so it might be considered as a promising chemoprevention agent. The positive effect of carvacrol on apoptosis has been realized, as shown by, increased levels of Bax and decreased levels of Bcl-2 expression during carvacrol chemoprevention, in addition to, highly significantly difference of apoptosis between carvacrol chemoprevention group and DMBA painted group.

**KEYWORDS:** HBP carcinogenesis, carvacrol, apoptosis, DMBA.

### INTRODUCTION

Oral squamous cell carcinoma (OSCC) is one of the major global health problems with an annual estimated incidence of 300,000 newly diagnosed cases<sup>(1)</sup>. The incidence of OSCC varies in different parts of the world and this difference is largely attributed to the exposure to risk factors specific to the area<sup>(2)</sup>. OSCC is commonly preceded by a range of tissue and cellular alterations, yet restricted to surface epithelial layers, termed oral epithelial dysplasia (OED). These changes often manifest in a clinical mucosal lesion<sup>(3,4)</sup>. Oral carcinogenesis induced by 7,

12-dimethylbenz [a] anthracene (DMBA) in golden Syrian hamsters is an accepted and well recognized experimental model for studying biochemical, histopathological and molecular alterations of human OSCC<sup>(5)</sup>. Among various factors, apoptosis (programmed cell death) was found to play a pivotal role in the regulation of OSCC<sup>(6)</sup>. Extensive studies on B cell lymphoma/leukemia-2 (Bcl-2) and Bcl-2 associated X-protein (Bax) expressions suggested that these markers could be used as a diagnostic and prognostic markers in carcinogenesis<sup>(7-9)</sup>. Despite advances in diagnostic techniques and

\* Demonstrator, Oral and Dental Pathology Department, Faculty of Dental Medicine, Boys, Cairo, Al-Azhar University, Egypt.

\*\* Lecturer; Department of Oral and Dental pathology, Faculty of Dental Medicine, Boys, Cairo, Al-Azhar University, Egypt.

\*\*\* Professor and head of Oral and Dental Pathology Department, Faculty of Dental Medicine, Boys, Cairo, Al-Azhar University, Egypt.

improvement in treatment modalities, the prognosis of OSCC remains poor, mainly owing to the high-rate of local and regional recurrence and to the development of new malignant changes within the original field of precancerization. Therefore, it is particularly important to identify new agents that could inhibit OSCC growth and metastasis<sup>(10, 11)</sup>. It has been believed that medicinal plants are promising alternative therapeutics against cancer<sup>(12, 13)</sup>. Carvacrol is a phenolic compound present in the essential oil fraction of oreganum and thyme. It has been found that, carvacrol could inhibit viability and proliferation of human non-small cell lung cancer cell line, and induced early apoptotic features in a dose-dependent manner on these cells<sup>(14)</sup>. The same effect also had been seen on human metastatic breast cancer cells<sup>(15)</sup>. Also it has anti-proliferative properties on human hepatocellular carcinoma cell line<sup>(16)</sup>, and increases apoptosis proportion in the human cervical cancer cell lines<sup>(17)</sup>. Experimental studies of carvacrol revealed that, there were no apparent side effects during uses, this provided preliminary positive evidence for the safety of carvacrol<sup>(18, 19)</sup>.

## MATERIAL AND METHODS

The Experimental animals used in the current study were golden Syrian male hamsters. The animals were used as model for OSCC induction utilizing DMBA as chemical carcinogen, DMBA (0.5%) was obtained from Sigma-Aldrich Company, and dissolved in paraffin oil. Oral administration of carvacrol using a specific vehicle in a dose of 15mg/kg was used for chemoprevention of carcinogenesis, carvacrol was obtained from Sigma-Aldrich corporation (Stenlheim, Germany) and prepared by dissolving in corn oil and given in a dose of 15mg/kg<sup>(20)</sup>, after that, various investigations: hematoxylin and eosin (H&E) stain and (IHC) staining utilizing Bcl-2 and Bax antibodies were done. **Animals:** Fifty five Syrian male hamsters five weeks old, weighing

80-120gm were obtained from the animal house, Cairo University (Cairo, Egypt). The experimental animals were housed in standard cages with sawdust bedding under controlled environmental conditions of humidity (30-40%), temperature ( $20 \pm 2^\circ\text{C}$ ), and light (12-h light/12-h dark). All experimental animals were supplied with standard diet and water ad libitum.

## Experimental design

The experimental animals were divided into three groups (G(s)) (GI, GII and GIII). G1 (negative control): 5 hamsters were not treated. GII: (DMBA painted group): 20 hamsters were subdivided into GIIA in which the right buccal pouches of 10 hamsters were painted with DMBA for 6 weeks and GIIB, in which the right buccal pouches of 10 hamsters were painted with DMBA for 14 weeks. Group III (carvacrol chemoprevention group): 30 hamsters were subdivided into GIIIA in which 15 hamsters were given carvacrol orally one week before as well as during DMBA application for 6 weeks and Group IIIB in which 15 hamsters were given carvacrol orally one week before as well as during DMBA application for 14 weeks.

**Investigations:** After termination of the experiment, the animals were euthanized before sacrificed, after that, the heads of hamsters were separated and fixed in 10% buffered formalin solution for 24h after putting a piece of wood with suitable size between the teeth, to prevent wrinkling of the epithelium during manipulation, after that, the right HBPs were excised and placed in 10% buffered formalin solution for another 24h then, routinely processed and embedded in paraffin blocks for preparation in order to be examined histologically and immunohistochemically.

**Histological examination:** The specimens were dehydrated in an ascending ethanol series, embedded in paraffin wax to form paraffin blocks. Tissue sections of 4 $\mu\text{m}$  thickness were

cut using rotary microtome, mounted on glass slides, processed, and stained with H&E for light microscopic examination.

#### **Immunohistochemical examination:**

Tissue sections were cut for the application of standard labeled streptavidin- biotin method to demonstrate the expression of (Bcl-2 and Bax antibodies). The Paraffin embedded tissue sections were dewaxed and rehydrated through graded ethanol to distilled water. Endogenous peroxidase was blocked by incubation with 3% H<sub>2</sub>O<sub>2</sub> in methanol for 10 min. The antigen retrieval was achieved by adding citrate buffer solution (pH 6.0) and put in microwave for 3 intervals, 5 minutes for each at 95°C, followed by washing with phosphate buffered saline (PBS). The tissue sections were then received one or two drops of the primary antibodies (Bax & Bcl-2) in a dilution of 1:100 in Tris buffer solution and incubated in a humid chamber at room temperature overnight at 4°C. After washing with PBS, Biotinylated secondary antibody was added and incubated for 30 min at room temperature. After rinsing with PBS, tissue sections were received Diaminobenzidine (DAB) (Sigma, USA) was applied for 2-4 minutes to develop color. When acceptable colour intensity was reached, the slides were washed, counter stained with hematoxylin and covered with a mounting medium. The immunostained sections were examined using light microscope to assess the prevalence of positive cases and the localization of immunostaining within the tissues. In addition, image analysis computer system was used to assess area percentage of positive cells of the immunostaining. This was done in the Oral and Dental Pathology Department - Faculty of Dental Medicine, Boys, Cairo, Al-Azhar University, Egypt. The degree of positive staining for antibody was evaluated by a well-established semi-quantitative scoring on a scale range from negative to strong positive staining as follow: Strong staining (more than 50% of cells stained), moderate

staining (between 25 and 50% of cells stained), weak staining (between 5 and 25% of cell stained), and negative (less than 5% of cells stained)<sup>(14)</sup>.

## **RESULTS**

### **The Gross observation results**

HBP mucosa of GI was pink in color with smooth surface with no observable abnormalities (Fig.1.A). At 6 weeks: in GIIA, HBP mucosa showed variable changes included whitish (Fig.1.B), erythematous mucosal surface with diffuse swelling (Fig.1.C) and/or multiple small exophytic nodules surrounded with ulcerative and bleeding areas, while in GIIIA, HBP mucosa showed variable changes included normal color of mucosa, grayish white patch (Fig.1.D) and solitary small exophytic nodule with absence of ulceration (Fig.1.E), while at 14 weeks: regarding GIIIB, HBP mucosa showed multiple large exophytic nodules (Fig.1.F), which surrounded with ulcerative and bleeding areas in some animals (Fig.1.G) some animals appeared debilitated, and in GIIIB, HBP mucosa showed variable changes included erythematous mucosal surface with diffuse swelling (Fig.1.H) and/or multiple small exophytic nodules surrounded with ulcerative and bleeding areas (Fig.1.I).

### **Histopathological and immunohistochemical results**

The tissue sections of HBP mucosa of experimental groups showed variable results in regard to the histopathological results and immunohistochemical results. In GI, histological sections, using H&E stain, revealed normal HBP mucosa, composed of thin stratified squamous epithelium, consists of two to four layers of squamous cells exhibiting slight keratinization (i.e.; one layer of basal cells and one, two or three layers of spinous and thin keratinized cells with lacking rete ridges. Sub epithelial connective tissue (C.T), muscular layer and areolar layer were seen (Fig.2.A). The IHC staining using Bax exhibited moderate positive cytoplasmic

expression throughout the epithelial layers with mean area 45.32% (Fig.2.B). The IHC staining using Bcl-2 exhibited mild positive cytoplasmic expression limited to basal and suprabasal layers of the epithelium with mean area 6.72% (Fig.2.C).

**At 6 weeks:** regarding GIIA, H&E stain revealed severe epithelial dysplasia. Dysplastic epithelium showing basilar hyperplasia, hyperchromatism, cellular pleomorphism, abnormal mitosis and nuclear pleomorphism with drop shaped rete pigs (Fig.2.D). The IHC staining using Bax exhibited moderate positive cytoplasmic expression throughout the epithelial layers with mean area 28.58% (Fig.2.E). The IHC staining using Bcl-2 exhibited moderate positive cytoplasmic expression throughout the epithelial layers with mean area 31.79% (Fig.2.F), regarding GIIIA, H&E stain, revealed complete absence of epithelial dysplasia incidence in 8 out of 15 animals, (6 hamsters showed normal epithelium and 2 hamsters showed hyperkeratosis), while 7 out of 15 animals revealed mild epithelial dysplasia (Fig.2.G). The IHC staining using Bax exhibited moderate positive cytoplasmic expression throughout the epithelial layers with mean area 38.72% (Fig.2.H). The IHC staining using Bcl-2 exhibited mild positive cytoplasmic expression throughout the epithelial layers with mean area 15.63% (Fig.2.I). **At 14 weeks: GIIB:** H&E stain revealed that, the overlying epithelium shows well differentiated SCC. Dysplastic features in multiple areas and provide evidence of prominent true invasion with formation of epithelial nests and keratin pearls (Fig.2.J). The IHC staining using Bax exhibited mild positive cytoplasmic expression throughout the epithelial layers with mean area 10.38% (Fig.2.K) The IHC staining using Bcl-2 exhibited strong positive cytoplasmic expression throughout the epithelial layers with mean area 68.37% (Fig.2.L), and regarding **GIIB**, H&E stain indicated that 7 out of 15 animals exhibit well differentiated SCC, 4 out of 15 animals exhibited

severe epithelial dysplasia, while 2 animals exhibited moderate epithelial dysplasia (Fig.2.M) and 2 animals exhibited hyperplastic epithelium. The IHC staining using Bax exhibited mild positive cytoplasmic expression throughout the epithelial layers with mean area 19.32% (Fig.2.N). The IHC staining using Bcl-2 exhibited moderate positive cytoplasmic expression throughout the epithelial layers with mean area 48.8% (Fig.2.O).

**Statistical analysis results** of Bcl-2 and Bax expression were obtained by comparing the percentage of area distribution of Bcl-2 and Bax expression in the groups used. In regard to Bcl-2 expression, GI has recorded the lowest mean area percentage (6.72%), while group IIB had the highest mean area percentage (68.37 %), while in regard to Bax expression GI has recorded the highest mean area percentage (45.32%), while GIIB had the lowest mean area percentage (10.38 %). **At 6 weeks**, the comparison between GI, GIIA and GIIIA regarding Bcl-2 and Bax expression showed that, there were highly significant differences between them ( $P = 0.000$  in Bcl-2 and  $P = 0.002$  in Bax) (Chart. 1). **At 14 weeks**, the comparison between GI, GIIB and GIIBB regarding Bcl-2 and Bax showed that, there was highly significant difference between them ( $P = 0.000$  in Bcl-2 and Bax) (Chart. 2).

## DISCUSSION

In the present study, investigation of the chemopreventive efficacy of carvacrol on experimentally induced HBP carcinogenesis was successfully obtained. DMBA was chosen as the chemical carcinogen, because it plays the same etiological role in HBP carcinoma as do alcohol and tobacco in human OSCC<sup>(21, 22)</sup>. In the current study, the chemopreventive efficacy of carvacrol on experimentally induced HBP carcinogenesis resulted in variable observations of gross findings, H&E stain, Bax, and Bcl-2 expression. The gross observation in GI showed that HBP mucosa has normal appearance

(pink in color with smooth surface). This finding was in consistence with that of other studies<sup>(23,24)</sup>. H&E stain of this group showed that HBP mucosa is composed of a thin stratified squamous epithelium exhibiting slight keratinization with lacking rete ridges, sub-epithelial C.T, muscular layer and areolar C.T. This observation is in agreement with that of other studies<sup>(25, 26)</sup>. The IHC results, in GI, revealed positive cytoplasmic localization of both Bcl-2 and Bax. The Bcl-2 expression was limited to basal and suprabasal layers, with mean area 6.72 %, while Bax expression was distributed throughout the epithelial layers, with mean area 45.32 %. These

results were explained by other investigators who observed the similar observations. In order to control the terminal differentiation of keratinocytes, Bcl-2 was distributed in basal and suprabasal layers to protect their stem cells from apoptosis, while Bax was distributed throughout the epithelial layers, to increase susceptibility for apoptosis of unwanted cells <sup>(27-29)</sup>. In the present study, GIIA (DMBA painted group) at 6 weeks, gross observation showed variable changes. These changes included whitish and erythematous areas with diffuse swelling and/or multiple small exophytic nodules surrounded with ulcerative and bleeding areas in the HBP mucosa.

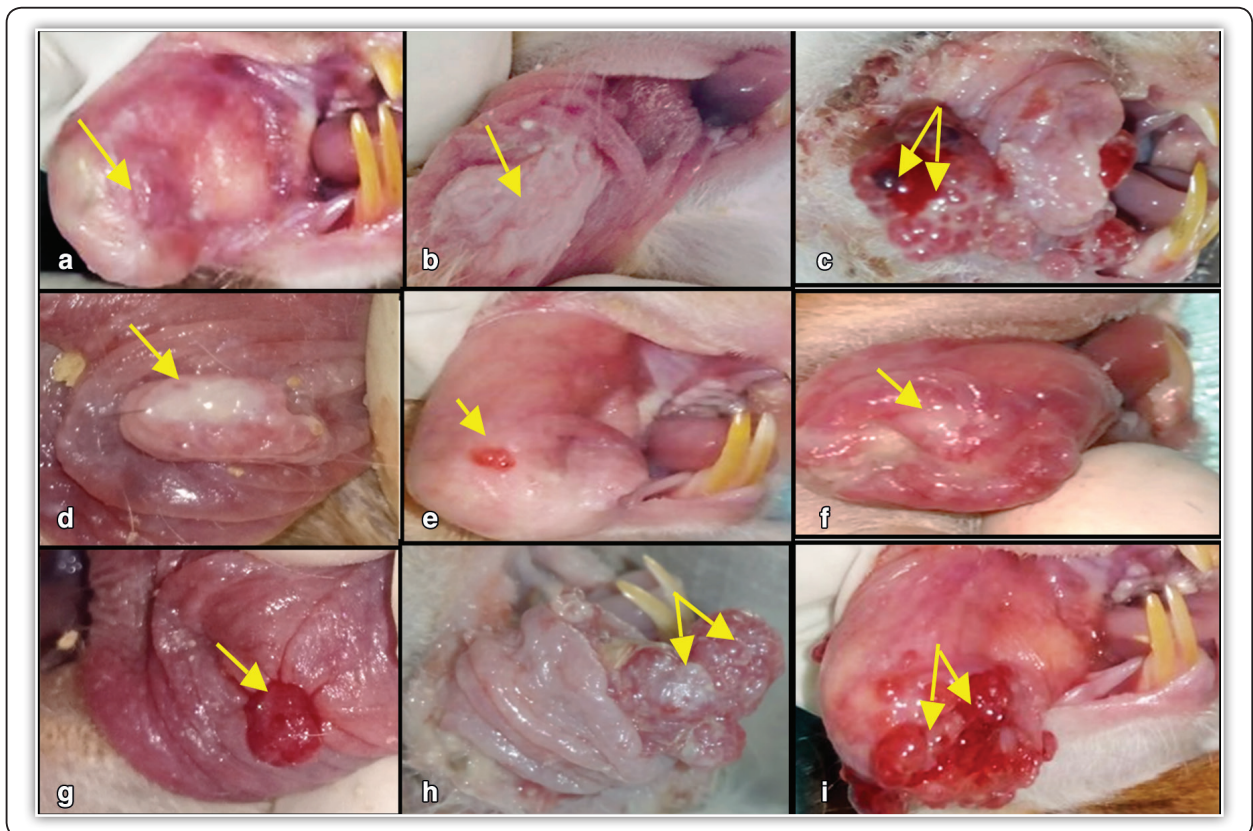


Fig. (1) (A): HBP of group I showing normal mucosa (pink in color with smooth surface) (arrow). Fig.1 (B): HBP of GIIA showing whitish mucosal surface (arrow). Fig.1 (C): HBP of GIIA showing large exophytic nodule with erythematous mucosal surface (arrow). Fig.1 (D) HBP of GIIIA showing grayish white patch on mucosal surface (arrow). Fig.1 (E): HBP of GIIIA showing solitary small exophytic nodule (arrow). Fig.1 (F): HBP of GIIB showing multiple large exophytic nodules (arrows). Fig.1 (G): HBP of GIIB showing multiple large exophytic nodules covered by bleeding and ulcerative areas (arrows). Fig.1 (H): HBP of GIIIB showing diffuse swelling covered by grayish white membrane (arrow). Fig.1 (I): HBP of GIIIB showing multiple small elevated nodules covered by ulcerative and bleeding areas (arrows).

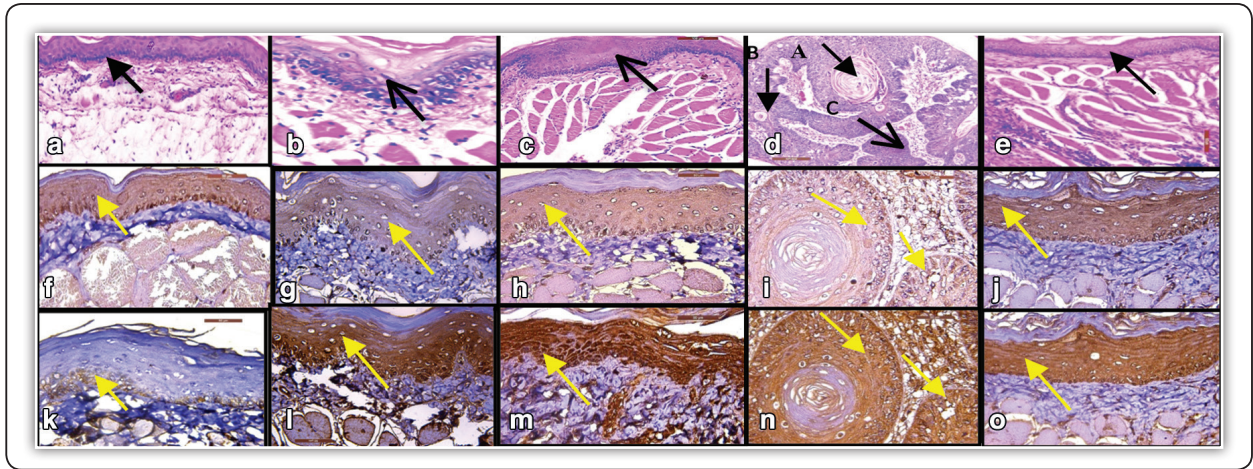


Fig.2 (A): H&E stain of GI showing: keratinized stratified squamous epithelium (arrow). Fig.2 (B): IHC expression of Bax in GI showing positive cytoplasmic expression throughout the epithelial layers (arrow). Fig.2 (C): IHC expression of Bcl-2 in GI showing positive cytoplasmic expression limited to basal and suprabasal layers of the epithelium (arrow). Fig.2 (D): H&E stain of GIIA showing severe epithelial dysplasia (arrow). Fig.2 (E): IHC expression of Bax in GIIA showing positive cytoplasmic expression throughout the dysplastic epithelial layers (arrow). Fig.2 (F): IHC expression of Bcl-2 in GIIA showing positive cytoplasmic expression throughout the dysplastic epithelial layers (arrow). Fig.2 (G): H&E stain of GIIIA showing mild epithelial dysplasia (arrow). Fig.2 (H): IHC expression of Bax in GIIIA showing positive cytoplasmic expression throughout the dysplastic epithelial layers (arrow). Fig.2 (I): IHC expression of Bcl-2 in GIIIA showing positive cytoplasmic expression throughout the dysplastic epithelial layers (arrow). Fig.2 (J): H&E stain of GIIB showing well differentiated SCC with keratin pearl (arrow A), individual cell keratinization (arrow B) and epithelial nests (arrows C) in superficial part of C.T. Fig.2 (K): IHC expression of Bax in GIIB showing positive cytoplasmic expression throughout the dysplastic epithelial nests (arrows). Fig.2 (L): IHC expression of Bcl-2 in GIIB showing positive cytoplasmic expression throughout the dysplastic epithelial nests (arrows). Fig.2 (M): H&E stain of HBP of GIIB showing moderate epithelial dysplasia (arrow). Fig.2 (N): IHC expression of Bax of in GIIB showing positive cytoplasmic expression throughout the epithelial layers (arrow). Fig.2 (O): IHC expression of Bcl-2 in GIIB showing positive cytoplasmic expression throughout the epithelial layers (arrow).

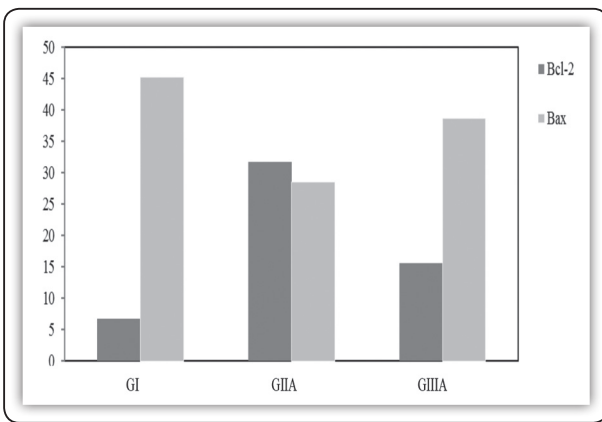


Chart (1): Bar chart representing mean area % values of Bax and Bcl-2 expression between GI, GIIA and GIIIA.

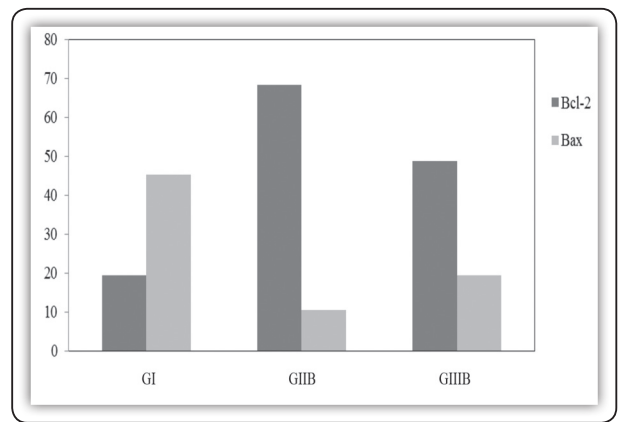


Chart (2): Bar chart representing mean area % values of Bax and Bcl-2 expression between GI, GIIB and GIIIB.

H&E stain revealed, severe epithelial dysplasia. These findings are in consistence with those of other studies<sup>(30-33)</sup>. These results may be due to chronic inflammation and production of ROS, generated by DMBA application, which covalently bound to the DNA, lead to adduct mutated region, activation of protoncogene, inactivation of tumor suppressor genes, and finally initiation of carcinogenesis'. In GIIA, the IHC result of Bcl-2 revealed positive cytoplasmic expression with mean area 31.79 %, while Bax showed positive cytoplasmic expression with mean area 28.58 %. This result may be attributed to the dysplastic changes which affect the Bcl-2/ Bax ratio, thus increase the proliferation and prevent apoptosis of dysplastic cells. These results are in agreement with those of other studies<sup>(34,35)</sup>. In the current study, GIIB (DMBA painted group) at 14 weeks, gross observation showed multiple large exophytic nodules surrounded with ulcerative and bleeding areas, some animals appeared debilitated and by H&E stain, a development of various patterns of invasive SCC (well differentiated and moderately differentiated) were seen. This is in consistence with that shown by other studies<sup>(26,36)</sup>. This observations might be attributed to DMBA effect on metabolic activation, DMBA is converted into its active carcinogenic metabolite, dihydrodiol epoxide, which mediates carcinogenesis through chronic inflammation, overproduction of ROS, activation of protoncogene, inactivation of tumor suppressor genes, extensive DNA damage, and reduction in DNA damage repair which reduced the ability to induce apoptosis<sup>(21,37)</sup>. The current results supported the concept that DMBA induced HBP carcinoma appears to go through the same changes as in human not only at the gross observations but also at the light microscopic observations. These results are in agreement with those of other studies<sup>(9,38,39)</sup>. In GIIB, the IHC result of Bcl-2 revealed positive cytoplasmic expression with mean area 68.37 %, while Bax showed positive cytoplasmic expression with mean area 10.38%. These results are in agreement with those of other investigators<sup>(8,23,24,40)</sup>.

The increase of Bcl-2 expression indicated that inhibition of apoptosis by prevention the release of cytochrome C from mitochondria and promotion of carcinogenesis, while the decreased expression of Bax could be due to reduced apoptotic cell death as well as accelerated their growth<sup>(41,36,38)</sup>. In the current study, oral administration of carvacrol in GIIIA, one week before as well as during DMBA application for 6 weeks on alternative days, showed variable results. These included normal color of mucosa, grayish white patch and solitary small exophytic nodules with absence of erosion, erythematous areas or spontaneous bleeding. Moreover, the animals appeared healthy and by H&E stain, revealed complete absence of epithelial dysplasia incidence in 8 out of 15 animals, (6 hamsters showed normal epithelium and 2 hamsters showed hyperkeratosis), while 7 out of 15 animals revealed mild epithelial dysplasia which suggested decrease severity of epithelial dysplasia compared to GIIA (DMBA painted group at 6 weeks). These observations might be attributed to a decrease in the carcinogenic effect of DMBA by oral administration of carvacrol. In the present study, oral administration of carvacrol in GIIB, one week before as well as during DMBA application for 14 weeks on alternative days showed variable results. These included normal color of mucosa, erythematous mucosal surface with diffuse swelling and / or multiple small exophytic nodules surrounded with ulcerative and bleeding areas in the HBP mucosa. These findings reflected on H&E stain, by complete absence of epithelial dysplasia incidence in 2 out of 15 animals which appeared with hyperplastic epithelium, while 4 out of 15 animals exhibited severe epithelial dysplasia, 2 animals exhibited moderate epithelial dysplasia and 7 animals exhibited well differentiated SCC. The gross observations and H&E stain results of GIIIA and GIIB are almost the same as reported by other studies<sup>(40,42,43)</sup>. Dai et al.<sup>(42)</sup> indicated that down regulation of cyclin D1 and cyclin dependent kinase 4 expressions and up regulation of P21 expression lead to decrease proliferation in SCC

cells treated with carvacrol *in vitro*. Subramaniyan et al.<sup>(40)</sup> indicated that carvacrol exhibited the potential anticancer activity by inhibiting cell proliferation and preventing metastasis in diethyl nitrosamine-induced hepatocellular carcinogenesis through down regulation the expressions of proliferative cytoplasmic nuclear antigen (PCNA), matrix metalloproteinase (MMP)-2, and MMP-9. Fan et al.<sup>(43)</sup> suggested that carvacrol inhibited the proliferation and migration in human colon cancer cell lines. In the current study, the results of GIIIA revealed down regulation of Bcl-2 with mean area 15.63 % and up regulation of Bax expression with mean area 38.72 % compared to GIIA. Also GIIIB revealed down regulation of Bcl-2 with mean area 48.8 % and up regulation of Bax expression with mean area 19.32 % compared to group IIB. These results suggested that oral administration of carvacrol induced apoptosis which almost the same as other studies<sup>(15, 16, 42)</sup>. These observations were attributed to increase of Bax/ Bcl-2 ratio which promotes apoptosis by decreasing the Bcl-2 gene expression. This lead to decrease mitochondrial membrane potential, increase in cytochrome c release from mitochondria, increase in caspase activity and cleavage of PARP that lead to fragmentation of DNA<sup>(14,20,42,44)</sup>.

## CONCLUSION

The incidence of HBP carcinogenesis was prevented and decreased by oral administration of carvacrol with variable degrees, so it might be considered as a promising chemoprevention agent. The positive effect of carvacrol on apoptosis has been realized, as shown by, increased levels of Bax and decreased levels of Bcl-2 expression during carvacrol chemoprevention, in addition to, highly significantly difference of apoptosis between carvacrol chemoprevention group and DMBA painted group.

## REFERENCES

- 1- Ferlay J, Isabelle S, Rajesh D, Sultan E, Colin M, Marise R, et al. Cancer incidence and mortality worldwide: sources, methods and major patterns in globocan. *Int J Cancer*, 2015; 136 (3): 359 - 86.
- 2- Aruna D, Prasad K, Shavi G, Ariga J, Rajesh G, Krishna M. Retrospective study on risk habits among oral cancer patients in Karnataka cancer therapy and research institute, Hubli, India. *Asian Pac J Cancer Prev*, 2011; 12 (6): 1561 - 66.
- 3- Barnes L, Eveson J, Reichart P, Sidransky D. World health organization classification of tumors pathology and genetics of head and neck tumors. Lyon, France IARC press, 2005; 177 - 80.
- 4- Van Der Wall I. Potentially malignant disorders of the oral and oropharyngeal mucosa, terminology, classification and present concepts of management. *J Oral Oncol*, 2009; 45: 317 - 23.
- 5- Manoharan S, Silvan S, Vasudevana K, Baskaran N, Kumar S, Vinoth K. Carnosic acid, a potent chemopreventive agent in oral carcinogenesis. *J Chem Biol Interact*, 2010; 188: 616 - 22.
- 6- Muzio L, Sartini D, Santarelli A, Rocchetti R, Morganti S, Pozzi V, et al. Expression and prognostic significance of apoptotic genes in oral squamous cell carcinoma. *J Mol Carcinog*, 2012; 21: 45 - 52.
- 7- Zargarani M, Eshghyar N, Baghaei F, Moghimbeigi A. Assessment of cellular proliferation in oral verrucous carcinoma and well-differentiated oral squamous cell carcinoma using Ki67: a non-reliable factor for differential diagnosis. *Asian Pac J Cancer Prev*, 2012; 13: 5811 - 15.
- 8- Rajasekaran D, Manoharan S, Silvan S, Vasudevan K, Baskaran N, Palanimuthu D. Proapoptotic, anti-cell proliferative, anti-inflammatory and anti-angiogenic potential of carnosic acid during 7, 12 dimethylbenz [a] anthracene-induced hamster buccal pouch carcinogenesis. *Afr J Tradit Complement Altern Med*, 2012; 10 (1): 102 - 20.
- 9- Silvan S and Manoharan S. Apigenin prevents deregulation in the expression pattern of cell-proliferative, apoptotic, inflammatory and angiogenic markers during 7, 12-dimethylbenz [a]anthracene induced hamster buccal pouch carcinogenesis. *J Arch Oral Biol*, 2013; 58: 94 - 01.



- 10- Rapidis A, Gullane P, Langdon J, Lefebvre J, Scully C, Shah J. Major advances in the knowledge and understanding of the epidemiology, aetiopathogenesis, diagnosis, management and prognosis of oral cancer. *J Oral Oncol*, 2009; 45: 299 - 300.
- 11- Kurita H, Nakanishi Y, Nishizawa R, Xiao T, Kamata T, Koike T, et al. Impact of different surgical margin conditions on local recurrence of oral squamous cell carcinoma. *J Oral Oncol*, 2010; 46: 814 - 17.
- 12- Pratheeshkumar P, Sreekala C, Zhang Z, Budhraj A, Ding S, Son Y, et al. Cancer prevention with promising natural products: mechanisms of action and molecular targets. *J Anti-cancer agents Med Chem*, 2012; 12 (10): 1159-84.
- 13- Rabe S, Emami S, Iranshahi M, Rastin M, Tabasi N, Mahmoudi M. Anti-cancer properties of a sesquiterpene lactone-bearing fraction from *artemisia khorassanica*. *Asian Pac J Cancer Prev*, 2015; 16: 863 - 68.
- 14- Koparal A, Zeytinoglu M. Effects of carvacrol on a human non-small cell lung cancer (NSCLC) cell line, A549. *J Cytotechnology*, 2003; 43 (3): 149 - 54.
- 15- Arunasree K. Anti-proliferative effects of carvacrol on a human metastatic breast cancer cell line, MDA-MB 231. *J Phytomedicine*, 2010; 17: 58 - 88.
- 16- Yin Q, Yan F, Zu X, Wu Y, Wu X, Liao M, et al. Anti-proliferative and pro-apoptotic effect of carvacrol on human hepatocellular carcinoma cell line HepG-2. *J Cytotechnology*, 2012; 64 (1): 43 - 51.
- 17- Mehdi S, Ahmad A, Irshad M, Manzoor N, Rizvi M. Cytotoxic effect of Carvacrol on human cervical cancer cells. *J BLM*, 2011; 3: 307 - 12.
- 18- Azizi Z, Ebrahimi S, Saadatfar E, Kamalinejad M, Majlessi N. Cognitive-enhancing activity of thymol and carvacrol in two rat models of dementia. *J Behav Pharmacol*, 2012; 23 (3): 241 - 49.
- 19- Fachini F, Kummer R, Estevao C, Carvalho M, Cunha J, Grespan R, et al. Effects of thymol and carvacrol, constituents of *thymus vulgaris* L. essential oil, on the inflammatory response. *Evid Based Complement. J Alternat Med*, 2012; 2012: 1 - 10.
- 20- Jayakumar S, Madankumar A, Asokkumar S, Raghunkumar S, Gokula D, Kamaraj S, et al. Potential preventive effect of carvacrol against diethylnitrosamine-induced hepatocellular carcinoma in rats. *J Mol Cell Biochem*, 2012; 360 (2): 51 - 60.
- 21- Manoharan S, Wani S, Vasudevan K. Saffron reduction of 7, 12-dimethylbenz [a] anthracene-induced hamster buccal pouch carcinogenesis. *Asian Pac J Cancer Prev*, 2013; 14: 951 -57.
- 22- Chen Y, Lin L. DMBA-induced hamster buccal pouch carcinoma and VX2 - induced rabbit cancer as a model for human oral carcinogenesis. *J Expert Rev Anticancer Ther*, 2010; 10 (9): 1485 - 96.
- 23- Kathiresan S, Mariadoss A, Muthusamy R, Kathiresan S. [6]-Shogaol, a novel chemopreventor in 7, 12 dimethylbenz [a] anthracene induced hamster buccal pouch carcinogenesis. *J Phytother Res*, 2016; 30 (4): 646-53.
- 24- Balakrishnan S, Manoharan S, Alias L, Nirmal M. Effect of curcumin and ferulic acid on modulation of expression pattern of p53 and Bcl-2 proteins in 7, 12-dimethylbenz [a] anthracene induced hamster buccal pouch carcinogenesis. *Indian J Biochem Biophys*, 2010; 47 (1): 7 - 12.
- 25- Adams J, Heintz P, Gross N, Andersen P, Everts E, Wax M, et al. Acid/pepsin promotion of carcinogenesis in the hamster cheek pouch. *Arch Otolaryngol - Head & Neck Surg*, 2000; 126 (3): 405 - 09.
- 26- Sophia J, Kiran K, Kowshik J, Mishra R, Nagini S. Nimbolide a neem limonoid inhibits phosphatidylinositol-3 kinase to activate glycogen synthase kinase-3 $\beta$  in a hamster model of oral oncogenesis. *J Sci Rep*, 2016; 6: 221 - 92.
- 27- Chen Y, Kayano T, Takagi M. Dysregulated expression of Bcl-2 and Bax in oral carcinomas: evidence of post-transcriptional control. *J Oral Pathol Med*, 2000; 29 (2): 63 - 69.
- 28- Xie X, Clausen O, De Angelis P, Boysen M. The prognostic value of spontaneous apoptosis, Bax, Bcl-2, and p53 in oral squamous cell carcinoma of the tongue. *J Cancer*, 1999; 86: 913 - 20.
- 29- Lavieille J, Gazzeri S, Riva C, Reyt E, Brambilla C, Brambilla E. p53 mutations and p53, Waf-1, Bax and Bcl-2 expression in field cancerization of the head and neck. *J Anticancer Res*, 1998; 18: 4741 - 49.
- 30- Xue T, Hua Y, Kai Y, Dan C, Qing W, Hong T, et al. Circadian variations of clock gene *Per2* and cell cycle genes in different stages of carcinogenesis in golden hamster buccal mucosa. *J Sci Rep*, 2015; 5: 97 - 108.
- 31- Kasem R, Hegazy R, Arafa M, Abdel Mohsen M. Chemopreventive effect of *Mentha piperita* on

- dimethylbenz [a] anthracene and formaldehyde induced tongue carcinogenesis in mice (histological and immunohistochemical study). *J Oral Pathol Medi*, 2014; 43 (7): 484 - 91.
- 32- Ebihara A, Krasieva T, Liaw L, Fago S, Messadi D, Osann K, et al. Detection and diagnosis of oral cancer by light-induced fluorescence. *J Lasers Surg Med*, 2003; 32 (1): 17 - 24.
- 33- Li N, Chen X, Liao J, Yang g, Wang S, Joseph y ,et al. Inhibition of 7, 12 dimethylbenz [a] anthracene induced oral carcinogenesis in hamster by tea and curcumin. *J Carcinogenesis*, 2002; 23: 1307 - 13.
- 34- Reed J. Bcl-2: prevention of apoptosis as a mechanism of drug resistance. *J Hematol Oncol Clin North Am*, 1995; 9: 451 - 73.
- 35- Gao Q, Hu J, Yu Y. The role of nitric oxide in ethanol post conditioning induced cardio protection. *J Zhongguo*, 2012; 28 (1): 9 - 13.
- 36- Manoharan S, Rajasekaran D, Murugaraj M, Karthikeyan S, Manimaran A. Modulating effect of *enicostemma littorale* on the expression pattern of apoptotic, cell proliferative, inflammatory and angiogenic markers during 7, 12-dimethylbenz [a] anthracene induced hamster buccal pouch carcinogenesis. *J Toxicol Int*, 2015; 22: 130 - 40.
- 37- Murata M, Ohnishi S, Seike K, Fukuhara K, Miyata N, Kawanishi S. Oxidative DNA damage induced by carcinogenic dinitropyrenes in the presence of P450 reductase. *J Chem Res Toxicol*, 2004; 17 (12): 1750 - 56.
- 38- Nagini S, Letchoumy P, Thangavelu A, Ramachandran C. A comparative evaluation of carcinogen activation, DNA damage, cell proliferation, apoptosis, invasion and angiogenesis in oral cancer patients and hamster buccal pouch carcinomas. *J Oral Oncol*, 2009; 45: 31 - 37.
- 39- Manoharan S, Palanimuthu D, Baskaran N, Silvan S. Modulating effect of lupeol on the expression pattern of apoptotic markers in 7, 12-dimethylbenz [a] anthracene induced oral carcinogenesis. *Asian Pac J Cancer Prev*, 2012; 13 (11): 5753 - 57.
- 40- Subramaniyan J, Krishnan G, Balan R, Mgi D, Ramasamy E, Ramalingam S, et al. Carvacrol modulates instability of xenobiotic metabolizing enzymes and down regulates the expressions of PCNA, MMP-2, and MMP-9 during diethyl nitrosamine induced hepatocarcinogenesis in rats. *J Mol Cell Biochem*, 2014; 395 (2): 65 - 76.
- 41- Manoharan S, Sindhu G, Nirmal M, Vetrichelvi V, Balakrishnan S. Protective effect of berberine on expression pattern of apoptotic, cell proliferative, inflammatory and angiogenic markers during 7, 12-dimethylbenz [a] anthracene induced hamster buccal pouch carcinogenesis. *PJBS*, 2011; 14 (20): 918 - 32.
- 42- Dai W, Sun C, Huang S, Zhou Q. Carvacrol suppresses proliferation and invasion in human oral squamous cell carcinoma. *Onco Targets Ther*, 2016; 9: 2297 - 304.
- 43- Fan K, Li X, Cao Y, Qi H, Li L, Zhang Q, et al. Carvacrol inhibits proliferation and induces apoptosis in human colon cancer cells. *J Anticancer Drugs*, 2015; 26 (8): 813 - 23.
- 44- Karkabounas S, Kostoula O, Daskalou T, Veltsistas P, Karamouzis M, Zelovitis I. Anticarcinogenic and antiplatelet effects of carvacrol. *J Exp Oncol*, 2006; 28: 121-25.