



## **CLINICAL AND RADIOGRAPHIC EVALUATION OF TWO VERSUS FOUR IMPLANT SUPPORTED MANDIBULAR OVER-DENTURE. A ONE-YEAR PROSPECTIVE STUDY USING COMPUTER GUIDED PLANNING**

Waleed Hamed Maryod<sup>\*</sup>, Shereen W. Arafat<sup>\*\*</sup>,  
Ahmed M. Hossam Eldin<sup>\*\*\*</sup> and Mohamed A. Elbaz<sup>\*\*\*\*</sup>

### **ABSTRACT**

**Objectives:** The current study was conducted to assess and compare 2 versus 4 implant supported mandibular over-denture using computer guided planning

**Material& methods:** The study was conducted on 16 patients who had completely edentulous jaws. Patients were divided into 2 groups. Group A: 8 patients received 2-implant supported mandibular over-denture, and Group B: 8 patients received 4-implant supported mandibular over-denture using computer guided planning. After 4 months of healing, complete denture was connected to the implants with Locator attachment abutments. Clinical evaluation was performed through Visual Analogue Scale (VAS) to assess patients' satisfaction after 12 months of loading. Radiographic evaluation was performed through CBCT to assess the marginal bone loss at 6, 12 months post-loading and posterior ridge resorption at 12 months post-loading. Statistical analysis of data was performed.

**Results:** all patients were satisfied with range of 7-10 VAS with no difference between the study groups. Group A showed significant higher marginal bone loss than group B at 6, 12 months post-loading. Group A showed significant higher values of posterior ridge resorption at 12 months post-loading.

**Conclusion:** increasing the number of implants from 2 to 4 in mandibular implant supported over-dentures leads to significant decrease in marginal bone loss, and residual posterior ridge resorption. But didn't have significant influence on patient satisfaction after 12 months of function.

**KEYWORDS:** mandibular over-denture, computer guided implants, marginal bone loss, ridge resorption, patient satisfaction.

\* Associate Professor of Removable Prosthodontics, MSA University.

\*\* Associate Professor of Oral & Maxillofacial Surgery, MSA University.

\*\*\* Associate Professor of Oral Radiology, MSA University.

\*\*\*\* Lecturer of Oral & Maxillofacial Surgery, MSA University.

## INTRODUCTION

The use of an implant-supported over-denture has been reported as an effective, widely used treatment modality for edentulous mandibles. <sup>(1, 2)</sup> This treatment option for edentulism has been regarded to overcome lots of the limitations of conventional complete dentures. It was reported that implant-supported over-denture decreases residual ridge resorption, improves stability and retention, and enhances the patient's satisfaction, and quality of life. <sup>(3-6)</sup>

Several studies mentioned that by increasing the number of implants, the retention and stability improve, and correspondingly the loading placed on individual implants decrease. <sup>(7)</sup> On the other hand, mandibular over-denture retained by 2 implants has become the first choice of treatment for edentulous individuals due to the decreased treatment cost, and invasiveness of the operation. <sup>(8,9)</sup>

Based on the fact that mandibular canines and premolars are usually the last to be lost, and the most resilient teeth, recommendations have been reported for these teeth on abutment selection, load distribution, and support for over-dentures. <sup>(10-12)</sup> Moreover, it was reported that the vertical retention and horizontal stability of over-denture increased with distal implant location up to the second premolar. <sup>(13)</sup> Furthermore, It was reported that progressive residual ridge resorption may affect peri-implant stress distribution. Several studies measured the vertical posterior ridge resorption to range from 0.5mm to 1mm over 5 years, and 1.4mm-1.5mm over 10 years. <sup>(14-16)</sup>

The attachment system is considered an important factor for a successful mandibular implant supported over-dentures. <sup>(17,18)</sup> In the last two decades, the prosthetic retention systems has been widely used in dental implants and proved increasing patients satisfaction and prosthetic rehabilitation outcome. <sup>(19)</sup> The locator abutment has been reported for its ease of use, low initial cost, and its compatibility

with implants from different manufacturers. <sup>(20)</sup> Moreover, over-dentures with the locator system hold good retention, but necessitates frequent maintenance visits to overcome the complications observed with the use of these prosthodontic rehabilitations. <sup>(21)</sup>

Locator attachment system uses a dual retention approach consisting of a patrix (male part) and a matrix (female part). It is classified as a resilient universal hinge device, it enables up to 40° inter-implant angles which is essential for limited inter-arch spaces. <sup>(22)</sup> The retention value of the Locator attachment depends on the patrix which composed of a metallic cap with a replaceable nylon element. It has dual retention feature (inner and outer) through which cross-sectional strength is obtained. This attachment performs mechanical and frictional forms of retention, since the nylon male component has insert section slightly oversized than the inner ring of the female abutment. <sup>(23)</sup>

The development of dental CBCT scanners for the use in dental offices provides dentists powerful imaging capabilities and software applications. Nowadays, Dental CBCT allows the implementation of a software-based treatment plan into clinical use in the form of patient-specific, computer-generated, CT-guided drill templates. <sup>(24)</sup> Computer-guided implant placement has become a popular treatment modality. This technique provides improved clinical experiences and superior outcomes as it allows flapless implant placement, shorter surgical time, less post-operative patient pain and swelling, and better esthetics. <sup>(25-27)</sup>

To date, there are lots of controversies regarding the number of implants supporting mandibular over-denture. Therefore, the aim of the current study was to assess and compare 2 versus 4 implant supported mandibular over-denture using computer guided planning In terms of marginal bone loss, patient satisfaction, survival rate, and ridge resorption.

## MATERIALS AND METHODS

The current clinical study was approved by the Research Ethics Committee-Faculty of Dentistry, Modern Sciences and Arts University (No.ETH2). The study was conducted on 16 patients (10 male and 6 female) with age range from 55 to 65 years, who had completely edentulous jaws with adequate bone in the anterior and premolar regions of the mandible to allow implant installation without bone augmentation (at least a 3.5 mm diameter and 10.0 mm length). The selected patients were free of diabetes, hypertension, hemorrhagic disorders, severe systemic diseases, compromised immune systems, or history of radiotherapy in the head or neck region. All selected patients signed an informed consent form and were randomly and equally divided into 2 groups. Group A: 8 patients received 2-implant supported mandibular over-denture, and Group B: 8 patients received 4-implant supported mandibular over-denture.

### Pre-surgical prosthetic & radiographic procedures

All patients received new maxillary and mandibular complete dentures constructed with the bilateral balanced occlusion, patients were instructed to wear them for 2 months before the implant surgery to enhance neuromuscular accommodation and this denture was used as a radiographic guide as well.

CBCT scanning was performed with at least eight gutta percha markers placed in different axial planes in the denture to act as radio-opaque reference points. Double scanning technique was used to fabricate CAD/CAM template for guided flapless implant installation (Nobel- Guide, Nobel Biocare, Gothenburg, Sweden). The first CBCT scan was performed while the patient clenching the radiographic guide with maximal bite force, to visualize the anatomy and the bony architecture of the mandible. The external form of the non-radio-opaque radiographic guide with radio-opaque markers as a reference point was visualized using

the radiographic guide alone and the same CBCT settings. The two sets of “Digital Imaging and Communication in Medicine” (DICOM) files were superimposed by coinciding the radio-opaque markers. A virtual 3-dimensional image of the radiographic guide and the anatomical architecture was created by the planning software (Nobel Clinician, Nobel Biocare).<sup>(28)</sup>

On the planning software, the optimal position of implants was virtually simulated in the anterior-premolar region. Moreover, the position of at least 3 anchor pins for fixation of the surgical guide was also simulated virtually. A customized surgical guide was then fabricated with guided sleeves for implants and anchor pins by rapid photo-typing. Fig (1)

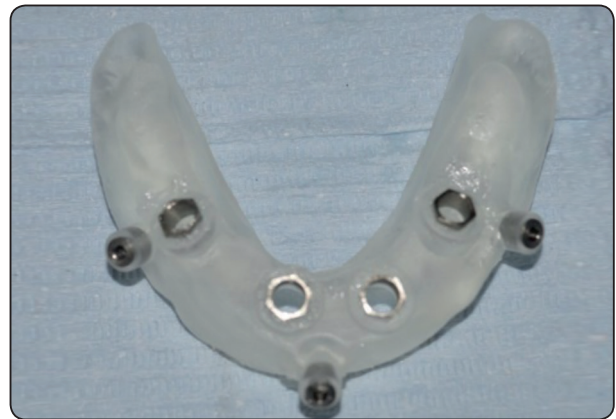

Fig. (1) Customized surgical guide with guided sleeves for implants and anchor pins

### Surgical procedures

The surgery was performed under Local Anesthesia (Lidocaine 2% containing 1: 100,000 epinephrine). The surgical guide was kept in place by firm finger compression until local anesthesia was administered through the sleeves of the anchor pins, and the guide then was stabilized by placement of the anchor pins. Fig (2) A tissue punch was then used to remove the gingival tissue under the implant sleeves. Drilling protocol was then followed for each

osteotomy site according to the drill sequence. The drilling depth was controlled by a drill stop on the shank that corresponded to the sum of the implant length, the gap between the guiding sleeve and the implant, and the guiding sleeve height. 2 implants and 4 implants (B&B Dental Implant Company, bebidental, Duravit 3p, Italy) were then placed for patients of group A, and group B correspondingly with insertion torque of at least 35 Nm. the guide was then removed, and the cover screws were placed.

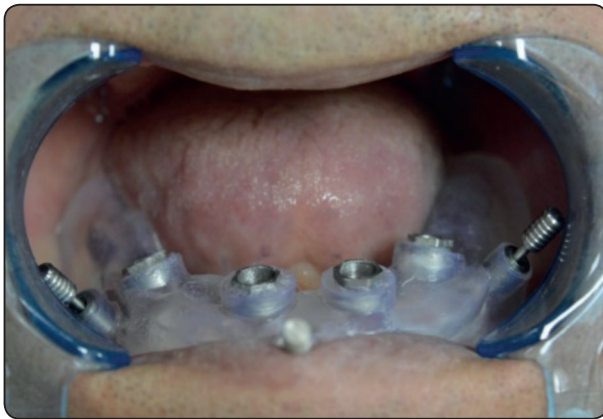

Fig. (2) The surgical guide stabilized intra-oral with the anchor pins

### Post-surgical instructions

Patients were instructed to wear their dentures immediately to minimize postoperative swelling and removed only for cleaning. Post-operatively, antibiotics (amoxicillin and clavulanic acid 625 mg three times a day) for 7 days and non-steroidal analgesics (Ibuprofen 400 mg three times daily) were prescribed. Patients are instructed to rinse with Chlorhexidine Gluconate Oral Rinse 0.12% 3 times per day for 2 weeks. Patients were recalled for follow-up observation and adjustment period of 4 months.

### Prosthetic procedure

Three weeks postoperatively, the patient's existing mandibular dentures were relieved over

implant sites and refitted to the mucosa using a tissue conditioner. After 4 months of healing, implants healing abutments were placed. Fig (3)

Complete denture was then connected to the implants with Locator attachment abutments using the direct pick-up technique.

The locator attachment consisted of: Locator abutment (The female component, medium (M), gingival height 3mm), Locator matrix (metal base with inner retention male insert, attached to the fitting surface of the over-denture), Locator black processing insert, and Retention male inserts (nylon inserts, fitted to the locator matrix, available in different colors according to the degree of retention). The used insert in this study was pink (medium retention; 1.365 g). For both groups, abutments were screwed into the implant hex using a 35 Ncm torque. The fitting surface of the new mandibular dentures directly above the implants was hollowed out to provide space for the attachments. The outer matrices for both groups were picked up intraorally to the fitting surface of mandibular dentures with cold-cure acrylic resin while the patient hold maxillary and mandibular dentures in centric occlusion. Fig (4,5) The locator black processing inserts were removed and pink nylon inserts were fitted to the locator matrix. The occlusion was refined before using the denture.

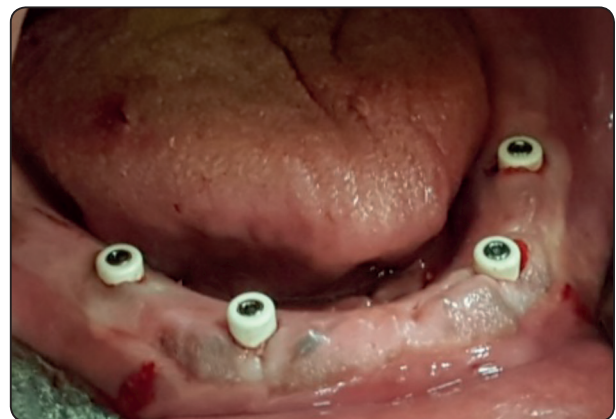


Fig. (3) intra-oral image showing implants with healing abutments

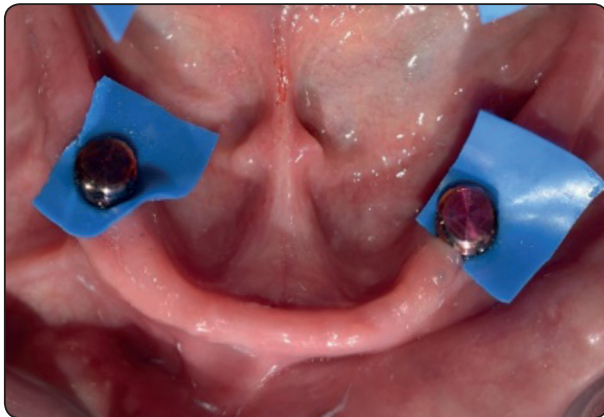


Fig. (4) Intra-oral image showing blocking the undercuts for pickup impression

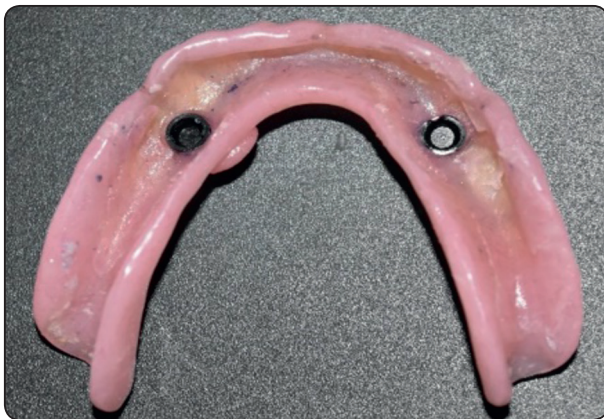

Fig. (5) image showing nylon cap and metal housing related to the fitting surface of the over-denture

### Clinical evaluation

Visual Analogue Scale (VAS) was used to assess patients' satisfaction after 12 months of using implant supported mandibular over-denture. Patients were requested to place a vertical line on the 10 mm scale to indicate their degree of overall satisfaction, with the left end (0) as completely unsatisfied and the right end (10) as completely satisfied. <sup>(29)</sup>

### Radiographic evaluation

All the patients underwent cone beam computed tomography (CBCT) scan prior to the surgical procedure for virtual planning. Follow up CBCT

were made 4 months after implant placement and immediately after over-denture fabrication with the locator attachment (0-interval), and 6, 12 months after loading. CBCT were evaluated for marginal bone loss, and ridge resorption. Evaluation was obtained by Scanora 3DX, with On-Demand 3DApp 1.0.10.4304 viewer. Measurements were calculated by an oral radiologist who was blinded to the surgical procedure and the evaluation was made twice with 10 days period interval.

The marginal bone loss assessment was evaluated from the average of bone loss in the buccal, lingual, mesial and distal surfaces in relation to the implant and the alveolar crest in millimeters. The measurement in coronal view was used for evaluation of the amount of bone resorption in buccal and lingual surfaces and in sagittal view for evaluation of bone loss in mesial and distal surfaces. Fig (6)

The assessment of the mandibular ridge resorption was based on the panoramic radiographs that were obtained from CBCT at intervals during treatment. The particular radiographs used in this investigation were those taken immediately and at 12 months after loading. To avoid the problems of magnification and distortion, the residual ridge was measured in bilateral posterior areas, using a method of proportional measurement that was similar to that used by several authors. <sup>(30-33)</sup>

The posterior area was bounded by a line joining the gonion to the lower border of the mental foramen and by the crest of the residual ridge. Fig (7a) The area was expressed as a proportion of a further area of bone, which was independent of the crest of the residual ridge; that is, a posterior triangle formed by the gonion, the lower border of the mental foramen and a point that was the centre of the triangle gonion, mental foramen and sigmoid notch. Fig (7b) Obviously, the measured area was compared with the triangular area on the same side, but the figure shows them on different sides for the sake of clarity.

The landmarks were traced from the radiographs and then digitized, and the necessary calculations were performed by a dedicated computer program.

The means of the posterior area indices for the two groups of patients were compared using two-sample t-tests, which assumed unequal variance. A multiple regression analysis using a backward stepwise procedure was also performed, and took the following factors into consideration: type of prosthesis, gender, age, years edentulous in the mandible and the initial height of the mandible.

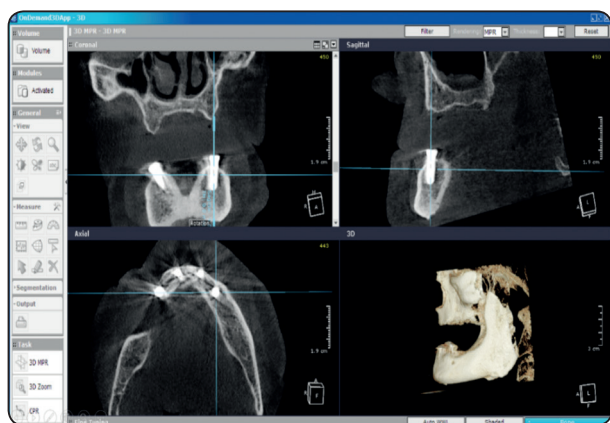


Fig. (6) Figure 6: CBCT in different cuts for measuring the marginal bone loss around the implants

**Statistical analysis:**

Data presented as mean and standard deviation (SD). Data explored for normality using Kolmogorov-Smirnov and Shapiro-Wilk tests. Marginal Bone Loss and Posterior Ridge Resorption showed Normal distribution, Repeated Measures ANOVA test used to compare between different tested Groups and Follow-up periods on mean Bone Density Followed by pairwise comparison with Bonferroni correction. Kruskal Wallis test used to compare between tested groups for VAS score. The significance level was set at  $P \leq 0.05$ . Statistical analysis was performed with IBM® SPSS® (SPSS Inc., IBM Corporation, NY, USA) Statistics Version 23 for Windows.

**RESULTS**

The study sample comprised 16 participants (10 male, 6 female) with age ranged from 55-65 years. A total of 48 implants (16 in group A and 32 in group B) were placed in a parallel inter-implant position in the inter-foraminal region of the mandible with good initial stability and successful Osseo-integration at 4 months postoperatively as observed during abutment tightening. All patients completed the 12-month post-loading follow-up, and no implant was lost, giving an overall one year survival rate of 100% for both groups.

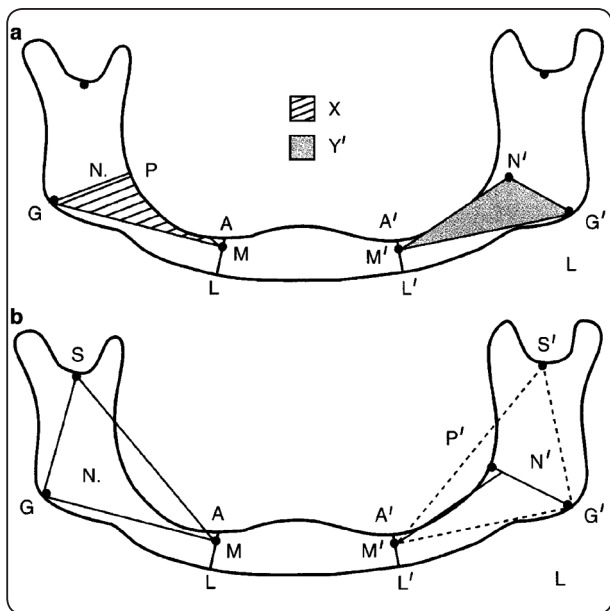


Fig.7 a. Boundary lines were constructed as follows: M-G and M'-G'; A-L and A'-L' (crest of residual ridge to lower border of mandible, perpendicular to M-G and M'-G'); M-N and M'-N'; G-P and G'-P' (G-N and G'-N' extended to the crest of the residual ridge at P and P'). The areas were defined as follows: X and X' by the crest of the residual ridge (P-A and P'-A') and the boundary lines A-M and A'-M', M-G and M'-G', and G-P and G'-P', respectively; Y and Y' by the triangles M-G-N and M'-G'-N', respectively. The posterior area index was calculated from  $(X/Y + X'/Y')/2$ . fig 7 b. The anatomical landmarks, M, M' (lower border of mental canal), S, S' (sigmoid notch) and G, G' (gonion) were used to construct the triangles M-S-G and M'-S'-G' with centres N and N', respectively). This diagram is sited from reference no 30

Regarding patient satisfaction measured by VAS score after 12 months of function (post-loading), there were no significant difference ( $p \geq 0.001$ ) between tested groups with satisfaction score range from 7-10 in both groups. Fig (8)

A significant increase on mean Marginal Bone Loss was reported at 6 and 12 months post-loading follow-up periods for group A and B. Comparing the marginal bone loss of the study groups, group A showed higher significant ( $p \leq 0.001$ ) values compared to group B at 6 Months and 12 Months. Table (1)

The study groups A & B showed Significant Posterior Ridge Resorption after 12 months of loading. Among the groups, Group A showed significant ( $p \leq 0.001$ ) higher ridge resorption values compared to Group B at 12 months post-loading. Table (2)

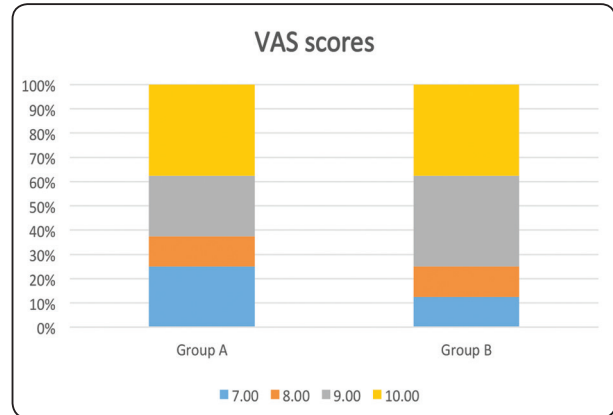


Fig. (8) Showing the VAS scores (7-10) for patient satisfaction after 12 months of loading for the study groups A&B with scores from 0-10; (0) as completely unsatisfied and (10) as completely satisfied.

TABLE (1) Mean and SD for Marginal Bone Loss for different tested groups for Follow-up periods

	6 Months		12 Months		Difference		p-value
	Mean	SD	Mean	SD	Mean	SD	
<b>Group A</b>	0.72	0.13	1.37	0.14	0.64750	0.08988	$\leq 0.001^*$
<b>Group B</b>	0.51	0.08	0.99	0.16	0.48125	0.14217	$\leq 0.001^*$
<b>p-value</b>	0.002*		$\leq 0.001^*$				

\*= significant

TABLE (2) Mean and SD for Posterior Ridge Resorption for different tested groups for Follow-up periods

	Imm		12 Months		Difference		p-value
	Mean	SD	Mean	SD	Mean	SD	
<b>Group A</b>	1.89	0.12	1.40	0.17	-0.48625	0.11262	$\leq 0.001^*$
<b>Group B</b>	1.86	0.14	1.58	0.15	-0.27250	0.06274	$\leq 0.001^*$
<b>p-value</b>	0.624 NS		0.043*				

## DISCUSSION

Results of the current study revealed 100 % survival rate of implant supported mandibular over-denture after 12 months of loading for both groups A, and B. This result is in accordance with other studies finding. <sup>(34-36)</sup>. Al-Magaleh et al <sup>(37)</sup> reported in comparison of 2 versus 4 implant supported mandibular over-dentures that the number of implants not be influential on implant stability and consequently implant success. This high survival rate could be also explained by the higher bone density of the anterior and premolar areas of the mandible which results in higher implant torque values, and better primary stability.

The current study reported high values of patient satisfaction as measured by VAS. These results are similar to findings by Aragon et al <sup>(38)</sup> who found high levels of patient satisfaction with implant-retained over-dentures. Moreover, other studies reported that implant-supported mandibular over-dentures are better treatment option for mandibular edentulous patients from patients' perspective. <sup>(39-41)</sup> Furthermore, there was no statistically significant difference between the study groups regarding patient satisfaction after 12 months of loading. This could be attributed to the better retention of implant supported over-denture which was the main concern of edentulous patients, and this can lead to less friction, less pain, better masticatory efficiency, and better speech function.

The significant increase of marginal bone loss, as reported in the current study at 6 and 12 months post-loading for the study groups, is in accordance with other studies. <sup>(42-45)</sup> Comparing the marginal bone loss of the study groups, group A showed more marginal bone loss compared to group B at 6 Months and 12 Months post-loading. This finding is in accordance to the finding of other studies, and could be attributed to the fact that the increase in implant number will decrease the loading forces applied on

each implant during function. <sup>(46-48)</sup> On the other hand, Talawy et al.<sup>(49)</sup> and Elawady et al.<sup>(50)</sup> have shown lesser marginal bone resorption with single implant compared with 2-implant supported over-denture. Moreover, It was reported by Helmy et al <sup>(51)</sup> that the assessment of peri-implant radiographic marginal bone loss cannot be recommended as a parameter to evaluate the effectiveness of oral implants. It should be only a measure of the disease process, and for the early detection of potential problems. Furthermore, the controversies regarding marginal bone loss could be attributed to lack of the standardization in methods used for the evaluation. Periapical radiographs and CBCTs are reported to be acceptable in measuring peri-implant bone levels <sup>(52,53)</sup> Also, it is difficult to correctly measure marginal bone loss in values less than 1 mm on panoramic X-rays. Thus the records of the current study was taken on CBCT for its accuracy as supported and used by several studies. <sup>(54-56)</sup>

The current study reported Significant Posterior Ridge Resorption after 12 months of loading in the study groups A, and B. While, Group A showed significant higher ridge resorption compared to Group B at 12 months post-loading. This finding could be explained that with the increase in implant number, the supporting increases, and more loading forces will be applied on implant/abutment complex and less loading forces will be applied on the mucosal area. This finding corresponds to the finding of other studies. <sup>(57-59)</sup>

## CONCLUSION

Within the limitations of the current study, we can conclude that increasing the number of implants from 2 to 4 in mandibular implant supported over-dentures leads to significant decrease in marginal bone loss, and residual posterior ridge resorption. But didn't have significant influence on patient satisfaction after 12 months of function.



**REFERENCES**

- 1- Feine JS, Carlsson GE, Awad MA, Chehade A, Duncan WJ, Gizani S, et al. The McGill consensus statement on overdentures. Mandibular two-implant overdentures as first choice standard of care for edentulous patients. *Gerodontology* 2002; 19: 3-4.
- 2- Thomason JM, Feine J, Exley C, Moynihan P, Müller F, Naert I, et al. Mandibular two implant-supported overdentures as the first choice standard of care for edentulous patients. *Br Dent J* 2009; 207:185-6.
- 3- Locker D. Patient-based assessment of the outcomes of implant therapy: a review of the literature. *Int J Prosthodont* 1998; 11: 453-61.
- 4- Kapur KK. Management of the edentulous elderly patient. *Gerodontics* 1987; 3: 51-4.
- 5- Assuncao WG, Zardo GG, Delben JA, Barao VA. Comparing the efficacy of mandibular implant-retained overdentures and conventional dentures among elderly edentulous patients: satisfaction and quality of life. *Gerodontology* 2007; 24:235-8.
- 6- Rashid F, Awad MA, Thomason JM, Piovano A, Spielberg GP, Scilingo E, et al. The effectiveness of 2-implant overdentures—a pragmatic international multi-centre study. *J Oral Rehabil* 2011; 38:176-84.
- 7- Kronström M, Widbom C, Soderfeldt B. Patient evaluation after treatment with maxillary implant-supported overdentures. *Clin Implant Dent Relat Res* 2006; 8:39-43.
- 8- Fitzpatrick B. Standard of care for the edentulous mandible: a systematic review. *J Prosthet Dent* 2006; 95:71-8.
- 9- Oda K, Kanazawa M, Takeshita S, Minakuchi S. Influence of implant number on the movement of mandibular implant overdentures. *J Prosthet Dent* 2017; 117:380-385.
- 10- Dolder EJ. The bar joint mandibular denture. *J Prosthet Dent* 1961; 11:689-707.
- 11- Morrow RM, Feldmann EE, Rudd KD, Trovillion HM. Tooth-supported complete dentures: an approach to preventive prosthodontics. *J Prosthet Dent* 1969; 21:513-22.
- 12- Schwartz IS, Morrow RM. Over-dentures. Principles and procedures. *Dent Clin North Am* 1996; 40:169-94.
- 13- Scherer MD, McGlumphy EA, Seghi RR, Campagni WV. Comparison of retention and stability of two implant-retained overdentures based on implant location. *J Prosthet Dent* 2014; 112:515-521.
- 14- Wright PS, Glantz PO, Randow K, Watson RM. The effects of fixed and removable implant-stabilized prostheses on posterior mandibular residual ridge resorption. *Clin Oral Implants Res* 2002; 13:169-74.
- 15- Kordatzis K, Wright PS, Meijer HJ. Posterior mandibular residual ridge resorption in patients with conventional dentures and implant overdentures. *Int J Oral Maxillofac Implants* 2003; 18: 447-52.
- 16- de Jong MH, Wright PS, Meijer HJ, Tymstra N. Posterior mandibular residual ridge resorption in patients with overdentures supported by two or four endosseous implants in a 10-year prospective comparative study. *Int J Oral Maxillofac Implants* 2010; 25: 1168-74.
- 17- Sadowsky SJ. Mandibular implant-retained overdentures: a literature review. *J Prosthet Dent* 2001; 86:468-73.
- 18- Trakas T, Michalakis K, Kang K, Hirayama H. Attachment systems for implant retained overdentures: a literature review. *Implant Dent* 2006; 15:24-34.
- 19- MacEntee MI, Walton JN, Glick N. A clinical trial of patient satisfaction and prosthodontic needs with ball and bar attachments for implant-retained complete overdentures: three-year results. *J Prosthet Dent* 2005; 93:28-37.
- 20- Matthys C, Vervaeke S, Jacquet W, Bruyn H. Impact of crestal bone resorption on quality of life and professional maintenance with conventional dentures or locator-retained mandibular implant overdentures. *J Prosthet Dent* 2018; 45: 34-45.
- 21- Artur M, André R, José M, José C, Maria H. Locator attachment system for implant overdentures: a systematic review. *Stomatologija, Baltic Dental and Maxillofacial Journal* 2017; 19: 124-9.
- 22- Nguyen CT, Masri R, Driscoll CF, Romberg E. The effect of denture cleansing solutions on the retention of pink Locator attachments: an in vitro study. *J Prosthodont* 2010; 19:226-30.
- 23- Evtimovska E, Masri R, Driscoll CF, Romberg E. The change in retentive values of locator attachments and hader clips over time. *J Prosthodont* 2009; 18:479-83.
- 24- Greenberg AM. Digital Technologies for Dental Implant Treatment Planning and Guided Surgery. *Oral Maxillofacial Surg Clin N Am* 2015; 27: 319-340.
- 25- Greenberg A. Basics of Cone-Beam CT and CT Guided Dental Implant Surgery. *Selected Readings in Oral and Maxillofacial Surgery* 2011; 19(5):1-48.

- 26- Laverty DP, Buglass J, Patel A. Flapless dental implant surgery and use of cone beam computer tomography guided surgery. *Br Dent J* 2018; 224:601–11.
- 27- Yong LT, Moy PK. Complications of computer-aided-design/computer-aided machining guided (Nobel Guide) surgical implant placement: an evaluation of early clinical results. *Clin Implant Dent Relat Res* 2008; 10:123–7.
- 28- Sanna AM, Molly L, van Steenberghe D. Immediately loaded CAD-CAM manufactured fixed complete dentures using flapless implant placement procedures: a cohort study of consecutive patients. *J Prosthet Dent* 2007;97: 331–9.
- 29- Ari Voutilainen, Taina Pitk€aaho, Tarja Kvist & Katri Vehvil€ainen-Julkunen. How to ask about patient satisfaction? The visual analogue scale is less vulnerable to confounding factors and ceiling effect than a symmetric Likert scale. *Journal of Advanced Nursing* 72(4), 946–957.
- 30- Kordatzis K, Wright PS, Meijer HJ. Posterior mandibular mandibular residual ridge resorption in patients with conventional dentures and implant over-dentures. *Int J Oral Maxillofac Implants*. 2003; 18(3):447-452.
- 31- Tymstra N, Raghoebar GM, Vissink A, Meijer HJ. Maxillary anterior and mandibular posterior residual ridge resorption in patients wearing a mandibular implant-retained over-denture. *J Oral Rehabil* 2011; 38(7):509-516.
- 32- Elsyad MA, Habib AA. Implant-Supported Versus Implant Retained Distal Extension Mandibular Partial Over-dentures and Residual Ridge Resorption: A 5-Year Retrospective Radiographic Study in Men. *Int J Prosthodont* 2011;(24):306–313
- 33- Maryod W & Shaheen N. Posterior mandibular residual ridge resorption with mini-implant retained mandibular overdentures. A 5-year retrospective radiographic study. *E D J* 2016; 62 (2): 1691-8. Kim HY, Lee JY, Shin SW, Bryant SR. Attachment systems for mandibular implant over-dentures: a systematic review. *J Advanced Prosthodont* 2012; 4(4):197-203.
- 34- Meijer HJA, Raghoebar GM, Van T Hof MA. Comparison of implant-retained mandibular over-dentures and conventional complete dentures: a 10-year prospective study of clinical aspects and patient satisfaction. *Int J Oral Maxillofac Implant* 2003; 18: 879-85.
- 35- Matthys C, Vervaeke S, Jacquet W, De Bruyn H. Impact of crestal bone resorption on quality of life and professional maintenance with conventional dentures or Locator-retained mandibular implant over-dentures. *J Prosthet Dent* 2018; 120:886-94.
- 36- Al-Magaleh W, Swelem A, Radi I. The effect of 2 versus 4 implants on implant stability in mandibular over-dentures: A randomized controlled trial. *J Prosthet Dent* 2017; 118: 725-731.
- 37- Aragon CE, Cornacchio AL, Ibarra LM, Saad MN, Zibrowski E. Implant over-dentures: dental students' performance in fabrication, denture quality, and patient satisfaction. *J Dent Educ* 2010; 74:993-1001.
- 38- Misch LS, Misch CE. Denture satisfaction-a patient perspective. *Int J Oral Implantol* 1991; 7: 43-8.
- 39- Sivaramakrishnan G, Sridharan K. Comparison of implant supported mandibular over-dentures and conventional dentures on quality of life: a systematic review and meta-analysis of randomized controlled studies. *Aust Dent J* 2016; 61(4):482-8.
- 40- Nogawa T, Takayama Y, Ishida K, Yokoyama A. Comparison of treatment outcomes in partially edentulous patients with implant-supported fixed prostheses and removable partial dentures. *Int J Oral Maxillofac Implants* 2016; 31: 1376-83.
- 41- Sandaa M, Fuekib K, Baric PR, Babaa K. Comparison of immediate and conventional loading protocols with respect to marginal bone loss around implants supporting mandibular over-dentures: A systematic review and meta-analysis. *Japanese Dental Science Review* 2019;55: 20–25.
- 42- Esposito M, Grusovin MG, Maghaireh H, Helen VW, Mg G, Maghaireh H, et al. Interventions for replacing missing teeth: different times for loading dental implants (Review). *Cochrane database Syst Rev* 2013 ;(3).
- 43- Suarez F, Chan H-L, Monje A, Galindo-Moreno P, Wang H-L. Effect of the timing of restoration on implant marginal bone loss: a systematic review. *J Periodontol* 2013;84: 159–69.
- 44- Engelhardt S, Papacosta P, Jansen JA. Annual failure rates and marginal bone-level changes of immediate compared to conventional loading of dental implants. A systematic review of the literature and meta-analysis. *Clin Oral Implants Res* 2015; 26: 671–87.
- 45- Br€anemark P-I, Svensson B, van Steenberghe D. Ten-year survival rates of fixed prostheses on four or six implants of modum Br€anemark in full edentulism. *Clin Oral Implants Res* 1995; 6: 227–231.

- 46- Hutton JE, Heath R, Chai JY, Harnett J, Jemt T, Johns RB, et al. Factors related to success and failure rates at 3-year follow up in a multicenter study of over-dentures supported by Brånemark implants. *Int J Oral Maxillofac Implants* 1995; 10: 33–42.
- 47- Naert I, Quirynen M, Hooghe M, van Steenberghe D. A comparative prospective study of splinted and unsplinted Brånemark implants in mandibular over-denture therapy: A preliminary report. *J Prosthet Dent* 1994; 71:4 86–492.
- 48- Talawy DBE, Ali SM. A two-year randomized clinical trial of one versus two implants retaining a mandibular over-denture with locator attachment. *EDJ* 2015; 61: 3829-38.
- 49- Elawady DM, Kaddah A, Omar H, Naby NA. Impact of single versus two implants on the bone height loss and bone density for patients restored by implant-retained mandibular overdentures. *EDJ* 2016; 62:2849-56.
- 50- M. H. E. -D. Helmy, A. Y. Alqutaibi, A. A. El-Ella, A. F. Shawky: Effect of implant loading protocols on failure and marginal bone loss with unsplinted two-implant supported mandibular over-dentures: systematic review and meta-analysis. *Int. J. Oral Maxillofac. Surg.* 2018; 47: 642–650.
- 51- Brägger R. Parameters for the evaluation of peri-implant tissues U. Radio-graphic parameters for the evaluation of peri-implant tissues. *Periodontol* 2000 1994;4: 87–97.
- 52- Liljeholm R, Kadesjö N, Benchimol D, Hellén-Halme K, Shi XQ. Cone-beam computed tomography with ultralow dose protocols for pre-implant radio-graphic assessment: an in vitro study. *Eur J Oral Implantol* 2017; 10:351–9.
- 53- Shereen W Arafat, Ingy M Chehata, Ahmed M Hossam. Sinus floor augmentation with simultaneous implant placement using Bio-Oss with and without PRF: Clinical study *E.D.J.* 2017; 63:151-160.
- 54- Maggie A. Khairy, Shereen W. Arafat. Buccal bone remodeling after immediate implant placement with and without grafting. *E.D.J.* 2014; 60: 4913-21.
- 55- Maggie A. Khairy\*, Shereen W. Arafat. Restoration of the peri-implant defect of immediate Implant by bovine-derived xenograft with and without PRF. *E.D.J.* 2014; 60: 2017-34.
- 56- Liu J, Pan S, Dong J, Mo Z, Fan Y, Feng H. Influence of implant number on the biomechanical behaviour of mandibular implant-retained/supported overdentures: a three-dimensional finite element analysis. *J Dent* 2013; 41:241-9.
- 57- Deuk-Won Jo, DDS, PhDa and Jin-Keun Dong, DDS, PhDb. Effects of posterior ridge resorption and attachment wear on periimplant strain in mandibular two-implant-supported overdentures. *J Prosthet Dent* 2015;114:839-847.
- 58- Warina P, Rungsiyakullb P, Rungsiyakullc C, Khongk-hunthiand P. Effects of different numbers of mini-dental implants on alveolar ridge strain distribution under mandibular implant-retained overdentures. *J Prosthodont Res* 2018; 62: 35–43.