

## CLINICAL OUTCOMES OF BONE REMOVAL USING PIEZOTOME VERSUS ROTARY INSTRUMENTS IN IMPACTED MANDIBULAR THIRD MOLAR SURGERIES

Salah El-Abbasy \*

### **ABSTRACT**

**Aim:** evaluation of the clinical outcomes of bone removal using Piezotome versus rotary instruments in impacted mandibular third molar surgeries.

**Materials and methods:** Ten patients with bilaterally impacted mandibular third molars having the same Pederson difficulty index for the right and left sides were included in our study. The patients were scheduled for surgical removal of both impactions with 45 days interval in-between where side A impactions were performed using a piezotome and side B impactions were performed using conventional rotary instruments.

**Results:** Comparing the overall outcomes of the present study and despite the increase in the operating time with the piezo surgery group, the postoperative pain, edema and trismus were significantly less in piezotome group compared to the conventional rotary group due to less heat generation, smoother osteotomy and decreased damage to the surrounding soft tissues provided by the piezotome.

**Conclusion:** Comparing the overall outcomes of the present study, and despite the increase in the operating time with the piezo surgery group, the postoperative pain, edema and trismus were significantly less in piezotome group compared to the conventional rotary group due to less heat generation, smoother osteotomy and decreased damage to the surrounding soft tissues provided by the piezotome.

**KEYWORDS:** Impacted mandibular third molar, Piezotome, Rotary instruments

### **INTRODUCTION**

Removal of impacted teeth is the most common surgical procedures performed by oral surgeons.<sup>1</sup> A great percent of the population suffers from

impacted teeth most commonly the mandibular third molars.<sup>2</sup> The third molar surgery range from a relatively simple procedure to an extremely difficult one which affects directly the postoperative pain, swelling and trismus.<sup>3-6</sup>

\* Lecturer of Oral and Maxillofacial Surgery, Oral and Maxillofacial Surgery Department, Faculty of Dentistry, Cairo University

The most important step during surgical extraction of impacted teeth is the bone removal which can be carried out either by a low speed rotary instruments or with a piezotome.<sup>7</sup>

Surgical burs can result in heat generation, damaging of the soft tissues and/or osteonecrosis.<sup>8</sup> However, Piezosurgery was introduced as a new technique for bone removal to overcome the surgical complications associated with the conventional rotary instruments.<sup>9</sup>

Piezosurgery allows for precise bone cutting and better visualization of the surgical field together with protection of the soft tissues and decreased heat generation. Piezosurgery nowadays has been widely used by maxillofacial surgeons in sinus lifting procedures, inferior alveolar nerve lateralization and orthognatic surgeries.<sup>10, 11</sup> It has also been introduced in endodontics and periodontics together with ENT and orthopedic surgeries.<sup>12</sup>

The aim of our study is to evaluate the clinical outcomes after bone removal using Piezotome versus rotary instruments in impacted mandibular third molar surgeries.

## MATERIALS AND METHODS

Ten patients with bilaterally impacted mandibular third molars having the same Pederson difficulty index<sup>13</sup> for the right and left sides (Fig. 1)

were selected from the outpatient clinic of the Oral and Maxillofacial Surgery Department, Faculty of Dentistry, Cairo University. Ten impactions were surgically extracted using piezotome and were included in side A and ten impactions were extracted using rotary instruments were included in side B. Cases were randomly divided between the two groups regardless of whether the impaction was on the right or left sides.

Immunocompromised patients, patients with hemorrhagic diseases or on an anticoagulant therapy together with pregnant females were excluded from the study.

The patients were scheduled for surgical removal of both impactions with 45 days interval in-between where side A impactions were performed using a piezotome and side B impactions were performed using conventional rotary instruments.

Local anesthesia 4% Articaine hydrochloride with epinephrine 1:100,000 was used to anesthize the inferior alveolar, lingual and long buccal nerves. Modified Ward's flap was performed to expose the tooth and the surrounding bone. Guttering and bone removal buccaly and distally was performed by a piezotome (Fig. 2) for side A cases with a vibration frequency between 28 and 36 kHz and by a conventional rotary fissure bur at 34000 rpm (Fig. 3) for side B cases and tooth sectioning was carried out whenever required.

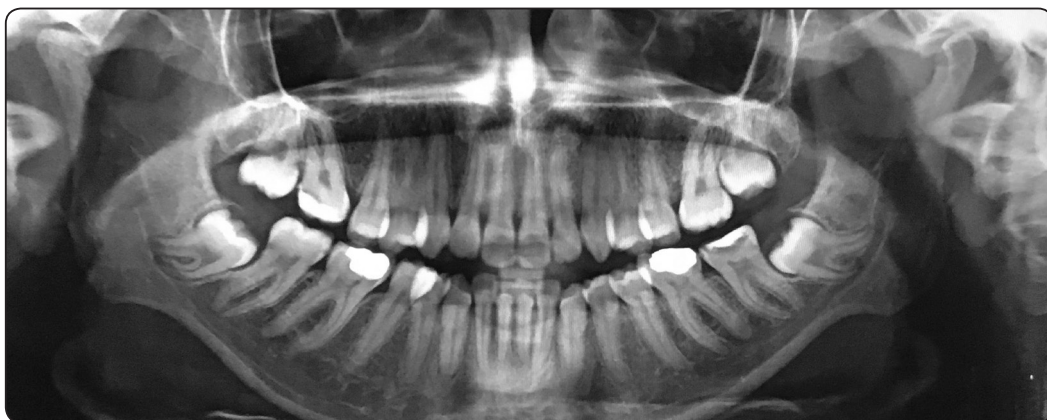

Fig. (1) Panoramic x-ray showing bilaterally impacted mandibular 3<sup>rd</sup> molar teeth having the same Pederson difficulty index.

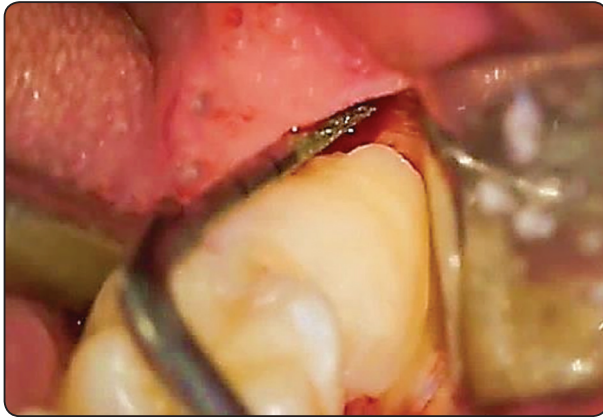


Fig. (2) Distal bone removal using a piezotome.

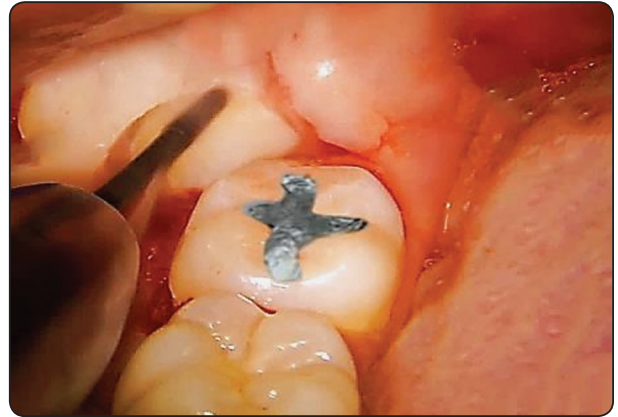


Fig. (3) Distal bone removal using fissure bur

After tooth removal, smoothening of any sharp bony margins was performed using bone files followed by debridement of the socket and adequate irrigation with saline for the whole surgical field.

The flap was sutured in place using 3-0 black silk suture and a pressure pack was placed over the surgical site intraorally.

Postoperative instructions and medications included (1) placing ice packs extraorally for twenty minutes (2) Chlorhexidine mouthwash 4 times daily for one week starting from the next day after surgery (3) Amoxicillin 500 mg 3 times a day for 3 days (4) Ibuprofen 600 mg whenever required.

The operative time was recorded starting from the first incision until the last suture. Postoperative pain, edema, trismus and parathesia were evaluated on the 2<sup>nd</sup>, 4<sup>th</sup> and 7<sup>th</sup> day after the surgery.

Pain was evaluated using visual analogue scale of pain with score 0-no pain and 10-worst pain together with counting the total number of analgesics used.

According to Amin and Laskin <sup>14</sup>, edema was evaluated by measuring the horizontal distance from the lower attachment of ear lobe to the mouth corner and the vertical distance was measured from the outer canthus of the eye to the angle of the mandible using a thread.

The distance between incisal edges of the maxillary and mandibular central incisors was measured to evaluate the trismus after the surgical procedures.

Cotton wool test was used to evaluate the presence or absence of parathesia in the lower lip.

## RESULTS

Six male patients and four female patients with an age range of 20-40 years and a mean age of  $26.3 \pm 4.2$  years were included in our study.

The mean operating time for the piezotome group (Side A) was  $43.1 \pm 3.1$  minutes, while for the conventional rotary group (Side B) was  $26.8 \pm 2.8$  minutes.

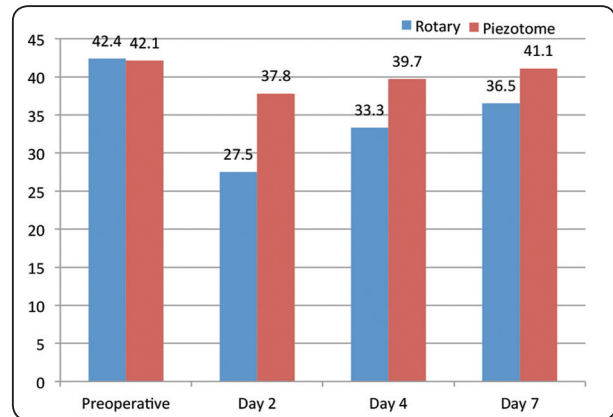
The mean pain scores for side A and side B on the 2<sup>nd</sup>, 4<sup>th</sup> and 7<sup>th</sup> day post surgical are shown on [graph 1]. There was significantly ( $P < 0.001$ ) less pain in piezotome group when compared to the rotary group during different follow up periods.

Edema on the 2<sup>nd</sup>, 4<sup>th</sup> and 7<sup>th</sup> day for side A and side B are shown on [graph 2]. There was no significant difference in vertical measurements between the two sides during different follow up periods, however in horizontal distance, there was significant difference ( $P = 0.014$ ) between the two groups on day 2 and no significant difference on day 4 and day 7 between the piezotome group and the rotary group.

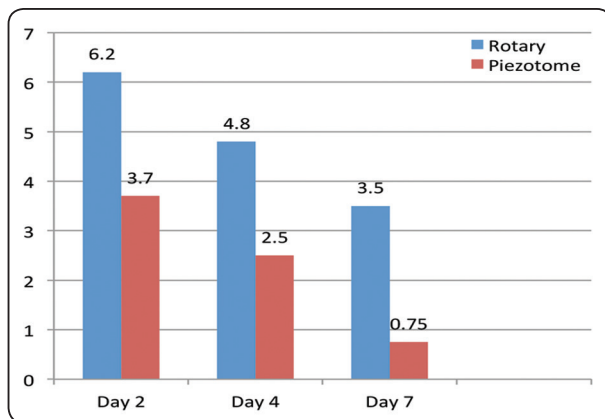
The mean interincisal distance for side A and side B on day 2, day 4 and day 7 are shown on [graph 3]. Piezotome group showed significant decrease in trismus ( $P < 0.01$ ) compared to the rotary during different follow up periods.

The mean total number of analgesics taken by the rotary group till day 7 was  $11.33 \pm 1.8$  tabs which is significantly higher ( $P < 0.001$ ) than the mean total number of analgesics taken by the piezotome group which was  $6.45 \pm 2.1$  tabs.

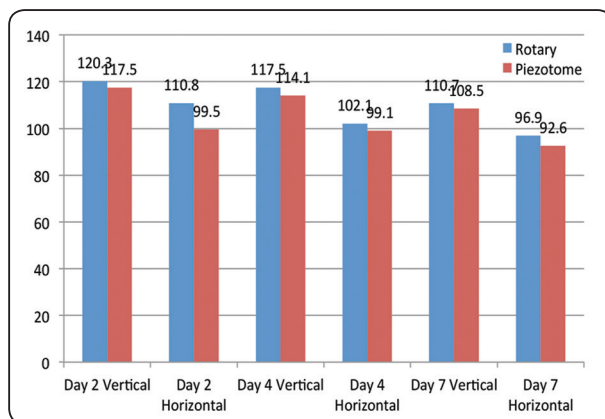
No cases were presented with lower lip parathesia in both groups during different follow up periods.



Graph (3) Mean maximum interincisal opening for rotary group and piezotome group.



Graph (1) Mean pain scores for rotary and piezotome groups



Graph (2) Mean vertical and horizontal edema measurements for rotary and piezotome groups

**DISCUSSION:**

In the present study, pain was evaluated utilizing the visual analogue scale of pain to compare between surgeries performed by rotary instruments and surgeries performed with piezotome. Pain decreased gradually in both groups, however it was significantly less with piezotome surgeries when compared to rotary instruments. This coincides with the findings of Horton et al<sup>15</sup> who reported that the severity of postoperative pain, swelling and trismus is directly related to the aggressiveness of the bone removal during surgical extractions of impacted mandibular third molars and that more postoperative pain resulted from rotary instruments followed by chisels followed by ultrasonics.

Our results also agrees with Barone et al<sup>16</sup> and Rullo et al<sup>17</sup> and Mantovani et al<sup>18</sup> who reported that there was less pain with piezotomes compared to rotary tools in simple extraction cases and concluded that even if piezotome surgeries require more time compared to conventional rotary instruments, less postoperative pain was monitored in the piezotome group.

In the current study, the total number of analgesics taken by the patients was significantly less with the piezotome surgeries compared to rotary surgeries. Decreased postoperative pain and the total number of analgesics taken agrees with the study of

Tsai et al <sup>19</sup> who concluded that reduced pain results from the minimal damage to the soft tissues surrounding the bone and due to the decreased heat generation with piezotomes.

In the present study, there was significantly less swelling after piezotome surgeries when compared to the conventional rotary surgeries on day 2 postoperatively which meets with the findings of Sortino et al <sup>20</sup>, Sivoletta et al <sup>21</sup> and Mantovani et al <sup>18</sup> who reported that there was a significant decrease in edema with piezo surgery groups compared to conventional surgery group on day 3 postoperatively after removal of impacted teeth.

In our study there was a significantly less trismus with piezotome surgeries compared to rotary instruments after 2 days, 4 days and 7 days postoperatively. Schoen et al <sup>7</sup> reported similar results with our study with decreased trismus in the piezotome group on day 3, day 5 and day 7 postoperatively. Also another study by Rashad et al <sup>22</sup> reported better values in mouth opening on day 2 postoperatively with piezotome surgeries when compared to rotary surgeries.

In this study, our results showed that although the surgeries using piezotome required significantly more time when compared to rotary instruments, yet, it resulted in less pain, swelling and trismus. This agrees with Benediksdóttir et al <sup>23</sup> who reported that the post-operative outcomes is not related to the time required to finish the surgical procedure. However, this disagrees with a study performed by Oikarinen, <sup>24</sup> reporting that pain, swelling and trismus are directly related to the duration of the surgical procedure.

## CONCLUSION

Comparing the overall outcomes of the present study, and despite the increase in the operating time with the piezo surgery group, the postoperative pain, edema and trismus were significantly less in piezotome group compared to the conventional

rotary group due to less heat generation, smoother osteotomy and decreased damage to the surrounding soft tissues provided by the piezotome.

## REFERENCES

1. Renton T, Smeeton N, McGurk M. :Factors predictive of difficulty of mandibular third molar surgery. *Br Dent J*; 190:607-10, 2001.
2. Praveen G, Rajesh P, Neelakandan RS, Nandagopal CM.: Comparison of morbidity following the removal of mandibular third molar by lingual split, surgical bur and simplified split bone technique. *Indian J Dent Res*;18:15-8, 2007.
3. Yuasa H, Kawai T, Sugiura M. :Classification of surgical difficulty in extracting impacted third molars. *Br J Oral Maxillofac Surg* ;40:26-31, 2002.
4. Lago-Méndez L, Diniz-Freitas M, Senra-Rivera C, Gude-Sampedro F, Gándara Rey JM, García-García A. : Relationships between surgical difficulty and postoperative pain in lower third molar extractions. *J Oral Maxillofac Surg* ; 65:979-83, 2007.
5. Garcia Garcia A, Gude Sampedro F, Gandara Rey J, Gallas Torreira M. :Trismus and pain after removal of impacted lower third molars. *J Oral Maxillofac Surg* ; 55:1223-6, 1997.
6. Moore PA, Brar P, Smiga ER, Costello BJ. : Dexamethasone for prevention of pain and trismus following third molar surgery. *Oral Surg Oral Med Oral Pathol Oral Radiol Endod* ;99:E1-7, 2005.
7. Schoen PJ, Hulshoff AC, Raghoobar GM, Stegenga B, de Bont LG.: Complaints and complications associated with removal of the mandibular third molar. A prospective clinical study. *Ned Tijdschr Tandheelkd*;105:170-3, 1998.
8. Bui CH, Seldin EB, Dodson TB. :Types, frequencies, and risk factors for complications after third molar extraction. *J Oral Maxillofac Surg*; 61:1379-89, 2003.
9. Gbotolorum OM, Arotiba GT, Ladeinde AL. :Assessment of factors associated with surgical difficulty in impacted mandibular third molar extraction. *J Oral Maxillofac Surg*; 65: 1977–1983, 2007.
10. Vercellotti T, Nevins ML, Kim DM, Nevins M, Wada K, Schenk RK: Osseous response following respective therapy with piezosurgery. *Int J Periodontics Restorative Dent*; 25:543-9, 2005.

11. Maurer P, Kriwalsky MS, Block Veras R, Brandt J, Heiss C.: Light microscopic examination of rabbit skulls following conventional and piezosurgery osteotomy. *Biomed Tech (Berl)*; 52:351-5, 2007.
12. Goyal M, Marya K, Jhamb A, Chawla S, Sonoo PR, Singh : Comparative evaluation of surgical outcome after removal of impacted mandibular third molars using a Piezotome or a conventional hand-piece: a prospective study. *Br J Oral Maxillofac Surg*; 50:556-61, 2012.
13. Pederson GW. : Surgical removal of tooth. In: Pederson GW (ed) *Oral surgery*. WB Saunders, Philadelphia, 1988
14. Amin MM, Laskin DM. : Prophylactic use of indomethacin for prevention of postsurgical complications after removal of impacted third molars. *Oral Surg Oral Med Oral Pathol*; 55:448-51, 1983.
15. Horton JE, Tarpley TM Jr., Wood LD. : The healing of surgical defects in alveolar bone produced with ultrasonic instrumentation, chisel, and rotary bur. *Oral Surg Oral Med Oral Pathol*; 39:536-46, 1975.
16. Barone A, Marconcini S, Giacomelli L, Rispoli L, Calvo JL, Covani U: A randomized clinical evaluation of ultrasound bone surgery versus traditional rotary instruments in lower third molar extraction. *J Oral Maxillofac Surg*; 68:330-6, 2010.
17. Rullo R, Addabbo F, Papaccio G, D'Aquino R, Festa VM: Piezoelectric device vs. Conventional rotative instruments in impacted third molar surgery: Relationships between surgical difficulty and postoperative pain with histological evaluations. *J Craniomaxillofac Surg*; 41:e33-8, 2013.
18. Mantovani E, Arduino PG, Schierano G, Ferrero L, Gallesio G, Mozzati M. : A split-mouth randomized clinical trial to evaluate the performance of piezosurgery compared with traditional technique in lower wisdom tooth removal. *J Oral Maxillofac Surg*; 72:1890-7, 2014.
19. Tsai S-J, Chen Y-L, Chang H-H, Shyu Y-C, Lin C-P. : Effect of piezoelectric instruments on healing propensity of alveolar sockets following mandibular third molar extraction. *Journal of Dental Sciences*; 7: 296-300, 2012.
20. Sortino F, Pedullà E, Masoli V. : The piezoelectric and rotatory osteotomy technique in impacted third molar surgery: Comparison of postoperative recovery. *J Oral Maxillofac Surg*; 66:2444-8, 2008.
21. Sivoilella S, Berengo M, Bressan E, Di Fiore A, Stellini E. : Osteotomy for lower third molar germectomy: Randomized prospective crossover clinical study comparing Piezosurgery and conventional rotatory osteotomy. *J Oral Maxillofac Surg*; 69:e15-23, 2011.
22. Rashad A, Kaiser A, Prochnow N, Schmitz I, Hoffmann E, Maurer P.: Heat production during different ultrasonic and conventional osteotomy preparations for dental implants. *Clin Oral Implants Res*; 22:1361-5, 2011.
23. Benediktsdóttir IS, Wenzel A, Petersen JK, Hintze H.: Mandibular third molar removal: Risk indicators for extended operation time, postoperative pain, and complications. *Oral Surg Oral Med Oral Pathol Oral Radiol Endod*; 97:438-46, 2004.
24. Oikarinen K.: Postoperative pain after mandibular third-molar surgery. *Acta Odontol Scand*; 49:7-13, 1991.