

## **EMINECTOMY VERSUS EMINOPLASTY FOR TREATMENT OF RECURRENT TEMPOROMANDIBULAR DISLOCATION: RANDOMIZED CONTROLLED CLINICAL TRIAL**

Mostafa Talaat El Gengehy\*, Sherif Ali\* and Mohamed Ashraf\*

### **ABSTRACT**

**Purpose:** The aim of this study was to compare recurrence, operation time, and temporomandibular joint (TMJ) pain following eminectomy versus eminoplasty in patients with recurrent TMJ dislocation.

**Materials and methods:** 12 patients with bilateral TMJ recurrent dislocation were included in this study. Bilateral eminectomy was performed for 6 patients, and bilateral reduction eminoplasty was performed for the other 6 patients. Recurrence rate, operation time, TMJ pain, TMJ noise, postoperative complications were assessed and compared between the 2 groups.

**Results:** No recurrence was observed in the eminectomy group. While in the eminoplasty group, recurrent dislocation occurred in 33.3% of the patients. Operation time was shorter in the eminoplasty group compared to the eminectomy group ( $40.75 \pm 5.17$ ,  $47.3 \pm 7.27$  minutes. TMJ pain at different time points, and TMJ noise were comparable in the 2 groups.

**Conclusions:** Eminectomy is superior to eminoplasty for treatment of recurrent TMJ dislocation. Eminoplasty can represent an alternative for eminectomy in cases with risk of intracranial perforation, subjected for further investigations.

**KEYWORDS:** Temporomandibular joint, Temporomandibular joint dislocation, Eminectomy, Eminoplasty.

### **INTRODUCTION**

Dislocation of temporomandibular joint (TMJ) is a pathologic condition in which the patient suffers non-self limiting hypermobility in the joint due to the displacement of mandibular condyle outside its position within the glenoid fossa. Although lateral

and posterior dislocation is mentioned in literature, anteromedial position is the most common. In this condition, the condyle is stuck beyond the articular eminence anteriorly in a non-functional position.<sup>1-4</sup>

Pathogenesis of dislocation is not fully understood but many contributing factors may be

\* Lecturer, Oral and Maxillofacial Surgery Department, Faculty of Dentistry, Cairo University, Cairo, Egypt.

involved to cause this condition. Bony anatomy of the eminence, ligamentous and capsular condition in addition to muscle action on the joint may contribute to recurrent dislocation.<sup>5-7</sup> Patients suffering from internal derangement, as well as occlusal disturbance can be more prone to dislocation.<sup>8,9</sup> Dislocation is generally caused by lack of muscles coordination during closure. It is usually associated with spasms of masticatory muscles, inability to close the mouth, pain and loss of function.<sup>10,11</sup>

TMJ dislocation occurs in different forms, acute dislocation as a result of trauma or excessive opening, chronic dislocation as a result of capsule laxity due to prolonged disarticulation, and finally recurrent dislocation. Recurrent dislocation is a repeated sporadic acute TMJ dislocation. Unlike chronic dislocation, the mandibular condyle is located in its normal position between dislocation episodes.<sup>12,13</sup>

Recurrent TMJ dislocation treatment modalities can be organized according to the stability factor into ligaments alteration, musculature alteration, and bony anatomy alteration. Nonsurgical/minimally invasive and surgical/invasive therapies have been used. Conservative modalities are usually used before invasive modalities, yet surgical modalities are still superior to non surgical modalities due to its higher success rate.<sup>5,12,13</sup>

Eminectomy is one of the widely used surgical procedures to manage recurrent dislocation. It is considered as a "rescue procedure" by many surgeons.<sup>(14)</sup> It was first reported by Myrhaug<sup>15</sup> in 1951. The aim of the procedure was to remove the articular eminence, allowing the condyle to move freely backward. Since then, eminectomy has been successfully used alone or with other procedure for treatment of recurrent TMJ dislocation.<sup>10,12,13,16-19</sup> Partial eminectomy (reduction eminoplasty) has been introduced as a modification of complete eminectomy. In this procedure, the eminence is partially reduced instead of complete removal.

Eminoplasty lowers the risk of perforation into the middle cranial fossa compared to eminectomy, moreover it represent a reliable alternative in case of eminence pneumatization.<sup>16,20-23</sup>

Recent systematic reviews showed that despite the presence of numerous studies evaluating surgical management for recurrent TMJ dislocation, they are limited to case series and reports with low scientific evidence, and recommended well designed trials on this topic.<sup>13,24</sup> The aim of this study was to compare recurrence, operation time, and TMJ pain following eminectomy versus eminoplasty in patients with recurrent TMJ dislocation.

## MATERIALS AND METHODS

### A. Trial design

This was a parallel-groups randomized controlled trial conducted on 12 patients with recurrent bilateral TMJ dislocation. The patients were randomly allocated with a 1:1 ratio in 2 groups. Bilateral eminectomy was performed for 6 patients in the control group, and bilateral reduction eminoplasty was performed for 6 patients in the intervention group (fig. 1).

### B. Participants

Patients were selected according to the following criteria: patients with bilateral TMJ recurrent dislocation; at least 5 non self-reducing episodes per month; inability to perform normal jaw movement; failed conservative treatment; free from any systemic disease that may contraindicate the surgical procedure.

### C. Interventions

All patients were evaluated clinically, and a detailed history was taken. Personal data, age, gender, dislocation onset, and frequency were recorded. Preoperative, radiographic examination was performed using computed tomography (CT) to assess the articular eminence shape and height,

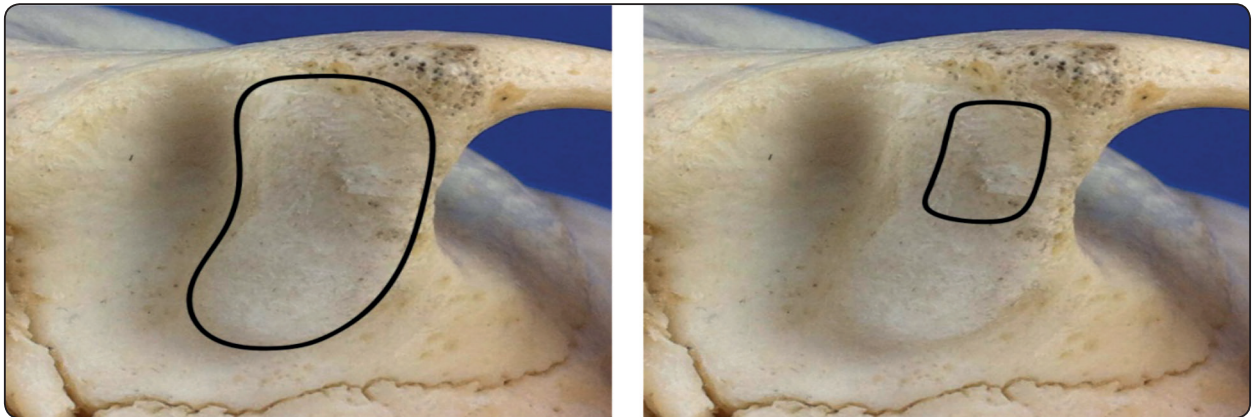


Fig. (1) Inferior view for the articular eminence showing amount of bone to be removed in eminectomy (left) and eminoplasty (right).

and to excluded pneumatization or cranialization of the articular eminence.

Surgical procedures were performed for all patients under general anesthesia with nasal intubation. The surgical field was prepared in regular surgical manner. Exposure of the TMJ and access to the eminence was performed by the endural approach (25). In the control group, eminectomy was performed using chisels, and/or rotating burs until the mandible moved smoothly without any locking, and then the bony surfaces was rounded and smooth to remove any irregularities (fig. 2). While in the intervention group, a rotatory bur was used to reduce the eminence at the antero-lateral

slope (fig. 3). Finally, the incision was sutured in layers. Excessive mouth opening and solid diet was prohibited for 3 weeks, and sutures ere reomoved after 7 - 10 days. All patients were recalled after one week for clinical assessment. Further clinical examination was scheduled after 1, 3, 6 months.

#### D. Outcomes

The primary end point of this study was the recurrence of dislocation. Secondary outcomes were: operation time, TMJ pain, TMJ noise, postoperative complications. All patients were followed up for at least 6 months to assess any recurrence of dislocation, and the percentage of recurrence was

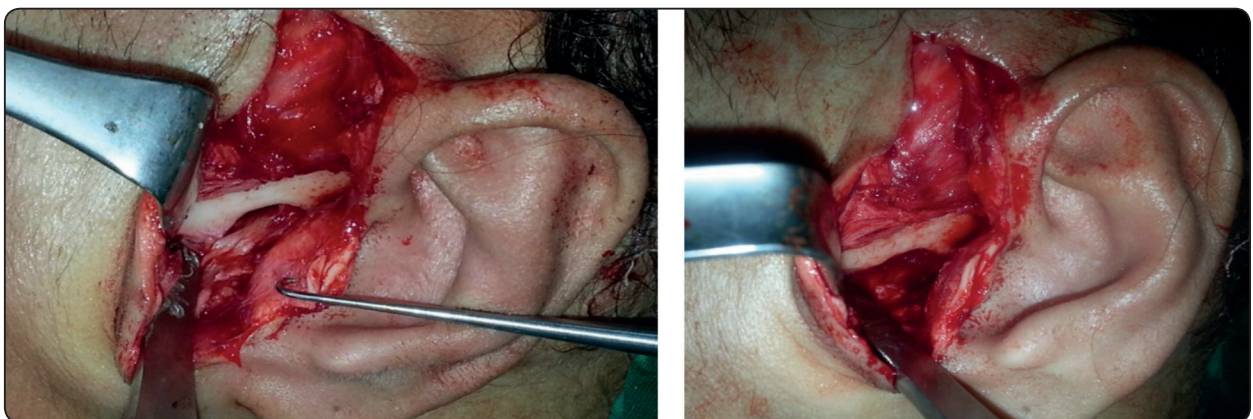

Fig. (2) Eminectomy a. Articular eminence exposed through the endural approach. b. Eminence completely removed.

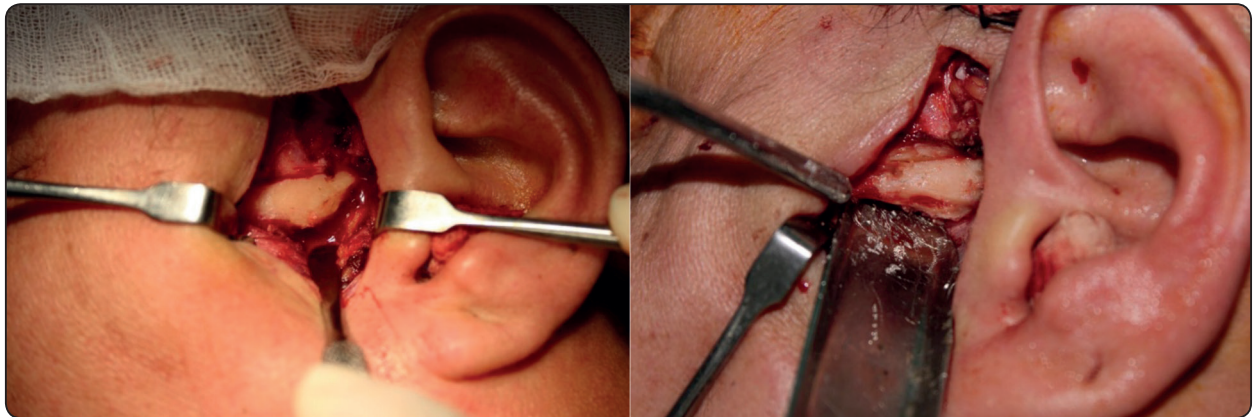


Fig. (3) Eminoplasty a. Articular eminence eminence exposed through the endural approach. b. Eminence partially removed.

calculated for each group. Operative time was measured for each joint from the start of skin incision till the skin closure. The operative time for the 12 joints in each group was collected (as mean) and compared between the 2 groups. Postoperative TMJ pain was assessed for each patient at 1 week, 1, 3, and 6 months using visual analog scales (VAS). Each patient was asked to mark a point on a VAS from 0 to 10 (0 as no pain- 10 sever pain). The mean pain score was calculated for each group at different time points and compared between the 2 groups. TMJ noise was evaluated by asking each patient for any joint noise at any time till the end of follow up period (as binary outcome for each patient), and the percentage of was calculated for each group. Any other postoperative complications were reported.

### G. Statistical analysis

Statistical analysis was performed using SPSS (Statistical package for the social sciences- IBM® SPSS® Statistics Version 20 for Windows, IBM Corp., Armonk, NY, USA). Data were explored for normality using Kolmogorov-Smirnov and Shapiro-Wilk tests. Quantitative data were represented as mean  $\pm$  standard deviation. For parametric data, Student's t-test was used to compare variables between the two groups. For non-parametric data, Mann-Whitney U test was used to compare variables between the two groups. Qualitative data were

represented as percentage. Fisher's exact test was used to compare variables between the two groups. The results were considered statistically significant if the p value was less than 0.05.

### RESULTS

This study was conducted on 12 patients (5 males, 7 females) with mean age of  $35.3 \pm 10.5$  years. The mean age was  $33.2 \pm 9.1$  years for the eminectomy group, and  $37.3 \pm 12.3$  years for the eminoplasty group. No recurrence was observed in the eminectomy group. While in the eminoplasty group, recurrent dislocation occurred in 33.3% of the patients (fig. 4), and there was no statistically significant difference between the 2 groups. Operation time was shorter in the eminoplasty group compared to the eminectomy group ( $40.75 \pm 5.17$ ,  $47.3 \pm 7.27$  minutes), and there was statistically significant difference between the 2 groups (fig 5). TMJ pain was comparable in the 2 groups at different time point, with no statistically significant difference (table 1, fig. 6). TMJ noise occurred in 5 patients, 3 in eminectomy group (50 %), and 2 in eminoplasty group (33.3 %). There was no statistically significant difference between the 2 groups. No other complications were observed except facial nerve weakness in one patient (eminectomy group).

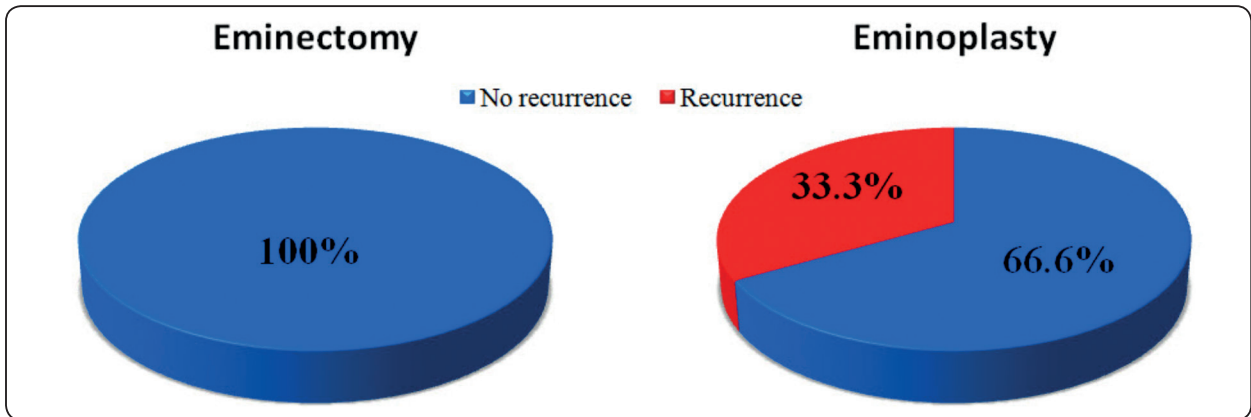


Fig. (4) Pie chart showing percentage of recurrence in each group.

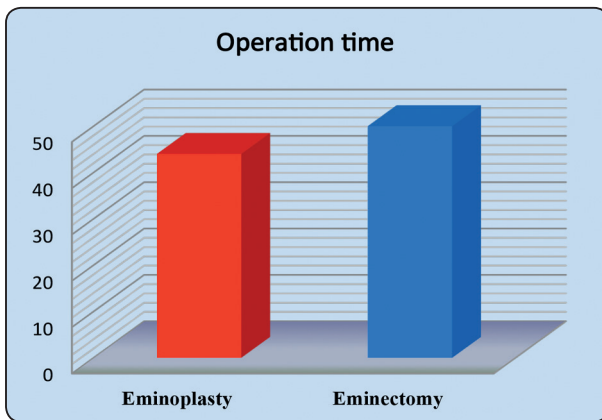


Fig. (5) Bar chart showing operation time.

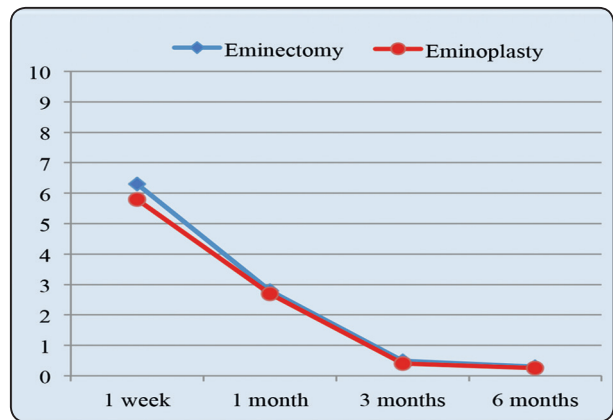


FiG. (6) Line chart showing change of TMJ pain with time.

TABLE (1) Showing TMJ pain VAS in the 2 groups at different time points (mean ±standard deviation).

	1 week	1 month	3 months	6 months
Eminectomy	6.3 ± 1.37	2.8 ± 1.17	0.5 ± 0.84	0.3 ± 0.52
Eminoplasty	5.8 ± 1.47	2.7 ± 1.63	0.4 ± 0.55	0.25 ± 0.5
P value	0.56	0.84	0.83	0.8

**DISCUSSION**

Different surgical modalities have been proposed for the treatment of recurrent TMJ dislocation. They aim either to limit the condylar path as temporalis scarification/lateral pterygoid myotomy, Dautrey’s Procedure, and other blocking procedures; or to enhance the condylar path as eminectomy.<sup>10</sup> All these methods have limitations, and variable rates of success. According to Pogrel<sup>26</sup>, no treatment can be identified as the gold standard.<sup>12,26</sup> To the contrary, many investigators consider eminectomy as the “gold standard” surgical technique for treatment of recurrent TMJ dislocation.<sup>14</sup>

The amount of bone removal is still controversy. Many authors recommended complete removal of

the eminence in the mediolateral direction. Irby highlighted the importance of eminence removal till its most medial portion.<sup>27</sup> Goode et al<sup>28</sup> and Helman et al<sup>29</sup> pointed that the eminence should be reduced medially as far as possible to exclude any restriction and prevent recurrence. Others recommended reduction eminoplasty, with only partial contouring and height reduction of the eminence.<sup>20,30</sup> Undt et al<sup>9</sup> pointed out some drawbacks regarding eminectomy. They claim that eminectomy may carry the risk of increasing hypermobility of the TMJ leading to further destruction of the surrounding tissues.<sup>9</sup> Segami et al<sup>21</sup> stated that significant reduction of the medial part of the eminence is not necessary, and considered eminoplasty as an effective method to reduce the risk of intracranial perforation.

The risk of intracranial perforation increased in patients with articular eminence pneumatization.<sup>30</sup> Articular eminence pneumatization is an asymptomatic condition. Panoramic radiograph studies showed low prevalence of eminences pneumatization, ranging from 1% to 6.2%.<sup>31-33</sup> However, recent computed tomography (CT) studies showed significantly higher percentage.<sup>30, 34, 35</sup> Buyuk et al<sup>34</sup> detected 29.6 % pneumatization of the roof of the glenoid fossa (296 in 1000 subjects) using cone beam CT. Heim et al<sup>30</sup> used high resolution CT to evaluate 600 articular eminence in 300 subjects. They detected 10 % eminence pneumatization (60 of 600 eminences) in 14.7% of the patients (44 of 300 patients). They developed a simple classification for eminence pneumatization and perforation risk during eminectomy. Single air cells, or 20% pneumatization was considered as type I with no or low risk of perforation. Pneumatization of 21% to 40%, and 41% to 70% was considered as Types II and III, with higher risk of perforation. Finally, type IV with more than 71% was considered as contraindication for eminence surgery. They recommended partial height reduction in Types II and III Pneumatization.<sup>30</sup>

In the current study, eminoplasty showed higher recurrence rate (33.3 %) when compared to eminectomy with no recurrence rate. Our recurrence rate was slightly higher than Sato et al study.<sup>22</sup> They reported a recurrence rate of 25% for arthroscopic eminoplasty. This rate may be accepted when eminoplasty is coupled with arthroscopy, but it questions the validity of open eminoplasty. Our study showed that operation time for eminoplasty (40.75 min) was shorter than the eminoplasty (47.3 min). This was attributed to the different time between complete and partial removal of the articular eminence. Despite the statistically significant difference, the observed difference of 13 minutes (for bilateral joints) has no clinical importance, especially with 33.3 % recurrence rate for the eminoplasty.<sup>36</sup>

The most common complains after joint surgeries that involve the articular eminence are joint pain and noise.<sup>22</sup> In the current study, TMJ pain and noise was comparable in the 2 groups with no statistical significant difference. Both groups showed moderate TMJ pain after 1 week. The pain declined significantly with time, almost all the patients have no pain after 6 months. TMJ noise occurred in 5 patients (41.66% of all patients), 3 patients in eminectomy group (50% of the group), and 2 patients in eminoplasty group (33.33 %). This may be attributed to the roughness caused by surface remodeling, irregularities of the articular eminence, or remaining part of the eminence.<sup>8, 21, 22</sup>

The major limitation of our study was the sample size, which hinder the power of detection of the difference between the two groups. This can elucidate the lack of statistical significant difference in recurrence rate between the two groups. The small sample size was attributed to the invasive nature of the examined techniques (36). Open TMJ surgery to treat chronic dislocation was done as a last resort, after failure of conservative techniques.<sup>22</sup> Conduction of multi-centered randomized controlled trials or well designed observational studies with large sample size can be a feasible option in such situations.

### Conclusions and recommendations

Within the limitations of this study, we pointed out that eminectomy is superior to eminoplasty for treatment of recurrent TMJ dislocation. Eminoplasty can represent an alternative for eminectomy in cases with risk of intracranial perforation. We recommend conduction of more studies, either randomized controlled trials with larger sample size or well designed observational, for further evaluation.

### REFERENCES

- Nitzan D. Temporomandibular joint open lock versus condylar dislocation: signs and symptoms, treatment and pathogenesis. *J oral Maxillofac surg.* 2002 May; 60(5):506-11.
- Sang LK, Mulupi E, Akama MK, Muriithi JM, Macigo FG, Chindia ML. Temporomandibular joint dislocation in Nairobi. *East Afr Med J.* 2010 Jan;87(1):32-7.
- Akinbami BO. Evaluation of the mechanism and principles of management of temporomandibular joint dislocation. Systematic review of literature and a proposed new classification of temporomandibular joint dislocation. *Head Face Med.* 2011 Jun 15;7:10.
- Sharma NK, Singh AK, Pandey A, Verma V, Singh S. Temporomandibular joint dislocation. *Natl J Maxillofac Surg.* 2015 Jan-Jun;6(1):16-20.
- Shorey CW, Campbell JH. Dislocation of the temporomandibular joint. *Oral Surg Oral Med Oral Pathol Oral Radiol Endod.* 2000 Jun;89(6):662-8.
- Kummoona R. Surgical reconstruction of the temporomandibular joint for chronic subluxation and dislocation. *Int J Oral Maxillofac Surg.* 2001 Aug; 30(4):344-8.
- Ugboko VI, Oginni FO, Ajike SO, Olasoji HO, Adebayo ET. A survey of temporomandibular joint dislocation: aetiology, demographics, risk factors and management in 96 Nigerian cases. *Int J Oral Maxillofac Surg.* 2005 Jul;34(5):499-502.
- Undt G, Kermer C, Piehlsinger E, Rasse M. Treatment of recurrent mandibular dislocation, Part I: Leclerc blocking procedure. *Int J Oral Maxillofac Surg.* 1997 Apr;26(2):92-7.
- Undt G, Kermer C, Rasse M. Treatment of recurrent mandibular dislocation, Part II: Eminectomy. *Int J Oral Maxillofac Surg.* 1997 Apr;26(2):98-102.
- Liddell A, Perez DE. Temporomandibular joint dislocation. *Oral Maxillofac Surg Clin North Am.* 2015 Feb;27(1):125-36.
- Nale JC, Tucker MR. Management of temporomandibular disorders. In: Happ J, Ellis III E, Tucker MR, editors. *Temporomandibular and other facial pain disorders in contemporary oral and maxillofacial surgery.* 6th ed. Elsevier Mosby; 2014.
- Tocaciu S, McCullough MJ, Dimitroulis G. Surgical management of recurrent dislocation of the temporomandibular joint: a new treatment protocol. *Br J Oral Maxillofac Surg.* 2018 Dec;56(10):936-40.
- Tocaciu S, McCullough MJ, Dimitroulis G. Surgical management of recurrent TMJ dislocation-a systematic review. *Oral Maxillofac Surg.* 2019 Mar;23(1):35-45.
- de Almeida VL, Vitorino Nde S, Nascimento AL, da Silva Júnior DC, de Freitas PH. Stability of treatments for recurrent temporomandibular joint luxation: a systematic review. *Int J Oral Maxillofac Surg.* 2016 Mar;45(3):304-7.
- Myrhaug H. A new method of operation for habitual dislocation of the mandible; review of former methods of treatment. *Acta Odontol Scand.* 1951 Sep;9(3-4):247-60.
- Martins WD, Ribas Mde O, Bisinelli J, França BH, Martins G. Recurrent dislocation of the temporomandibular joint: a literature review and two case reports treated with eminectomy. *Cranio.* 2014 Apr;32(2):110-7.
- Segami N. A modified approach for eminectomy for temporomandibular joint dislocation under local anaesthesia: report on a series of 50 patients. *Int J Oral Maxillofac Surg.* 2018 Nov;47(11):1439-44.
- Vyloppilli S, Joseph B, Manojkumar KP, Sayd S, Krishnakumar KS. Surgical Correction of TMJ Bilateral Dislocation with Eminectomy and Capsulorrhaphy as an Adjuvant: Case Reports. *J Maxillofac Oral Surg.* 2018 Sep;17(3):345-9.
- Iwanaga J, Nakamura Y, Kusukawa J, Tubbs RS. Eminectomy for Habitual Luxation of the Temporomandibular Joint with Sedation and Local Anesthesia: A Case Series. *Case Rep Dent.* 2016; 2016:2505864.
- Undt G. Temporomandibular joint eminectomy for recurrent dislocation. *Atlas Oral Maxillofac Surg Clin North Am.* 2011 Sep;19(2):189-206.
- Segami N, Kaneyama K, Tsurusako S, Suzuki T. Arthroscopic eminoplasty for habitual dislocation of the temporomandibular joint: preliminary study. *J Craniomaxillofac Surg.* 1999 Dec;27(6):390-7.

22. Sato J, Segami N, Nishimura M, Suzuki T, Kaneyama K, Fujimura K. Clinical evaluation of arthroscopic eminoplasty for habitual dislocation of the temporomandibular joint: comparative study with conventional open eminectomy. *Oral Surg Oral Med Oral Pathol Oral Radiol Endod.* 2003 Apr;95(4):390-5.
23. Cascone P, Ungari C, Paparo F, Marianetti TM, Ramieri V, Fatone M. A new surgical approach for the treatment of chronic recurrent temporomandibular joint dislocation. *J Craniofac Surg.* 2008 Mar;19(2):510-2.
24. Melo AR, Pereira Júnior ED, Santos LAM, Vasconcelos BCDE. Recurrent dislocation: scientific evidence and management following a systematic review. *Int J Oral Maxillofac Surg.* 2017 Jul;46(7):851-6.
25. Ellis E, Zide MF (eds): Approaches to the temporomandibular joint, in *Surgical Approaches to the Facial Skeleton* (ed 1). Philadelphia, PA, Lippincott Williams & Wilkins, 2006, pp 193- 215.
26. Pogrel MA. Temporomandibular joint disorders. In: Andersson L, Kahnberg KE, Pogrel MA, editors. *Oral and maxillofacial surgery.* Wiley-Blackwell; 2010.
27. Irby WB. Surgical correction of chronic dislocation of the TMJ not responsive to conservative therapy. *J Oral Surg.* 1957;15:307-12.
28. Goode RL, Linehan JW, Shorago G. Recurrent mandibular dislocation. Relieved by removal of articular eminence. *Arch Otolaryngol.* 1973 Aug;98(2):97-9.
29. Helman J, Laufer D, Minkov B, Gutman D. Eminectomy as surgical treatment for chronic mandibular dislocations. *Int J Oral Surg.* 1984 Dec;13(6):486-9.
30. Heim N, Götz W, Reich RH, Faron A. The prevalence of pneumatized articular eminence in the temporal bone. Do we need a high resolution computed tomography-based novel risk classification for eminectomy? *J Craniomaxillofac Surg.* 2018 Dec;46(12):1996-2002.
31. Yavuz MS, Aras MH, Güngör H, Büyükkurt MC. Prevalence of the pneumatized articular eminence in the temporal bone. *J Craniomaxillofac Surg.* 2009 Apr;37(3):137-9.
32. Shokri A, Noruzi-Gangachin M, Baharvand M, Mortazavi H. Prevalence and characteristics of pneumatized articular tubercle: First large series in Iranian people. *Imaging Sci Dent.* 2013 Dec;43(4):283-7.
33. Khojastepour L, Mirbeigi S, Ezoddini F, Zeighami N. Pneumatized Articular Eminence and Assessment of its Prevalence and Features on Panoramic Radiographs. *J Dent (Tehran).* 2015 Apr;12(4):235-42.
34. Buyuk C, Gunduz K, Avsever H. Prevalence and characteristics of pneumatizations of the articular eminence and roof of the glenoid fossa on cone-beam computed tomography. *Oral Radiol.* 2018 May 21. [Epub ahead of print]
35. Friedrich RE, Viezens L, Grzyska U. Pneumatization of the zygomatic process of temporal bone on computed tomograms. *GMS Interdiscip Plast Reconstr Surg DGPW.* 2016 Jun 14;5:Doc16.
36. Krousel-Wood MA, Chambers RB, Muntner P. Clinicians' guide to statistics for medical practice and research: part I. *Ochsner J.* 2006 Winter;6(2):68-83.