



Hepatoprotective and antioxidant effects of *Ocimum basilicum* extract in CCL₄-induced hepatotoxic rats compared with Silymarin.

Sarhan, Hasnaa, Farid, Ayman and Mostafa, Khalid

Clinical Pathology Department, Faculty of Veterinary Medicine, Benha University

ABSTRACT

The present study was designed to investigate the hepatoprotective and antioxidant effects of *Ocimum Basilicum* extract (OBE) on carbon tetra-chloride (CCl₄) induced rats hepatotoxicity compared with silymarin. Animals were divided into 6 groups. Group 1 was used as a control and received distilled water (1 ml/kg, p.o) daily for 21 days. Group 2 (Silymarin group): rats treated with silymarin (100 mg/kg, p. o. /day/ 21 days). Group 3 (OBE group) rats administered OBE (400 mg/kg, p. o./day/ 21 days). Group 4 (CCl₄ group) rats injected with CCl₄: corn oil (1:3) 2,5 ml/kg, s. c. on 15th day, 18th and 21st day. Group 5 (silymarin protected group) rats treated with silymarin (100 mg/kg, p.o/day/21days) then injected with CCl₄ dose as group 4. Group 6 (OBE protected group) rats administered OBE (400 mg/kg, p. o./day/ 21 days) then injected with CCl₄ : corn oil (1:3) 2,5 ml/kg, s. c. on 15th day, 18th and 21st day. Blood samples were separated into serum for liver functions determination (ALT, AST, GGT, ALP and bilirubin) and Liver tissue sample for antioxidant parameters determination (MDA, SOD, GPx and CAT), Immunological assay (TNF, IL-4 and NFκβ) and histopathology. The results revealed that in CCl₄ group, there were significant increases in ALT, AST, GGT, ALP, bilirubin, MDA, TNF, IL-4 and NFκβ, while parameters, SOD, GPx and CAT showed significant decreases. Moreover, histological examination of liver tissue of CCl₄ injected rats showed centrilobular hepatic degeneration and coagulative necrosis with marked fatty changes compared with the control.. Meanwhile, administration of Silymarin and OBE resulted in a significant decrease in all elevated mentioned parameters and increase in SOD, CAT and GPx. In addition, the liver tissues showed improved pathological alterations Therefore, it could be concluded that OBE has hepatoprotective and antioxidant role but silymarin has significant anti-oxidant effect than OBE..

Key words: OBE , silymarin, CCl₄ hepatotoxicity, antioxidant.

(<http://www.bvmj.bu.edu.eg>)

(BVMJ-36(2): 282-292, 2019)

1. INTRODUCTION

Liver plays important metabolic, detoxification, and secretory roles in the body. Liver disease is associated with distortion of these metabolic functions (Chaware et al., 2009). Human continuously exposed to different kinds of chemicals such as food additives, industrial chemicals, pesticides and other undesirable contaminants (Gabele et al., 2003).

Carbon tetrachloride (CCl₄) is a common hepatotoxin that is widely used to induce toxic liver injuries (Pereira-Filho et al., 2008). Search for newer drugs continues because the existing synthetic drugs have several limitations

(Gandhimathi and Saravana Kumar, 2012). Silymarin is a standardized extract obtained from the seeds of milk thistle plant (Kim et al., 2003). Silymarin has the ability to scavenge free radicals and has stabilizing effect. Moreover, it has anti-inflammatory, immunomodulatory, and lately antifibrotic properties in the liver (Fehér and Lengyel, 2012).

Ocimum basilicum Extract (OBE.), sweet basil, or Rehan in Egypt is an annual, widely cultivated herb known for its medicinal value. Most of the biological activities like antioxidant effects are associated with its volatile oil content (Shirazi et al., 2014). The phytochemical analysis of the plant reveal that

the plant is rich source of polyphenols (Arts and Hollman, 2005) which include flavonoids, phenolic acids, phenolic alcohols, stilbenes, and lignans (D'Archivio et al., 2007). In leaves extract, the total phenolic content has been found to be 32.23 ± 4.45 (Rafat et al., 2010)

The aim of this study was to evaluate the hepatoprotective effect of *ocimum basilicum* extract in CCl₄ induced hepatotoxicity comparing with silymarin as a standard drug through the investigation of liver functions (ALT, AST, GGT, ALP and bilirubin), antioxidant parameters (MDA, SOD, GPx and CAT), Immunological assay (TNF, IL-4 and NFκβ) and histopathological examination of liver.

2-MATERIAL AND METHODS

2.1. Animals:

Sixty male Wistar rats weighting about (150-170 g), were obtained from (The united company for chemicals, Abu zabal). They were housed in aluminium cage at 10 rats per cage and were fed ad libitum with standard commercial pelleted feed with free access to clean drinking water. They were kept at normal environmental temperature and natural light/darkness daily cycle.

2.2. Chemical experimental substances:

Silymarin from Madaus/Cid Company 100 mg/kg per os by gastric tube according method of Refaey et al., (2015) with some modification (daily silymarin treatment all over the experimental period). It is dissolved in corn oil.

CCl₄ was obtained from ALAMIA company for chemicals. It is diluted with corn oil as CCl₄: corn oil (1:3, 2,5 ml/kg, i/p.) (Refaey et al., 2015) with some modification. OBE obtained from Research Institute. The aqueous extract was used at a dose level of 500 mg/kg b.wt (Manikandan et al., 2007).

2.3. Experimental design:

In this study, 60 male albino rats were randomly divided into six groups (10 rats each) as follows: Group 1 (normal control rats):

received distilled water (1 ml/kg, p.o.) daily for 21 days. Group 2 (Silymarin group): received silymarin (100 mg/kg, p. o.) daily for 21 days. Group 3 (OBE group) received OBE (500mg/kg, p. o.) daily for 21 days. Group 4 (CCL4 group): received CCl₄: corn oil (1:3, 2,5 ml/kg, s. c.), on 15th day, 18th and 21st day of the treatment. Group 5 (silymarin protected group) received silymarin (100mg/ kg, p. o.) daily for 21 days +CCl₄ with same treatment of group 2. Group 6 (OBE protected group) received OBE same to group 3 and CCl₄ with same treatment of group 2.

2.4. Sampling:

Blood samples were collected after overnight fasting from retro-orbital plexus from all groups after 16th and 22nd of experimental beginning. Serum samples: 1ml blood samples were collected in gel tubes and separated by centrifugation at 2500 r.p.m. for 15 minutes for serum separation, then se-rum preserved in refrigerator at -20 °C for estimation of biochemical param-eters.

After collection of blood samples rats were sacrificed by cervical decapitation and liver specimen was perfused with cold saline to exclude the blood cells. The liver was divided into two parts. The first part (1gm) was suspended in 4ml physiological saline for homogenization then centrifugation. The supernatants were kept at -20°C till the time of determination of oxidative/antioxidant parameters (Yang et al., 2010). The second part was kept for gene expression at -80°C (22nd only). The third part was placed in 10 % formalin solution for histopathological investigations (22nd day only).

2.5. Biochemical parameters measurement:

AST and ALT estimated according to Schumann and Klauke, (2003). Kinetic determination of activity of GGT was determined colorimetrically according to the method of Szasz, (1969). Kinetic determination of ALP activity was determined colorimetrically according to the method of Tietz et al., (1983). Total and direct bilirubin were determined spectrophotometrically according to Burtis et al., (2012).

2.6. Antioxidant parameters Determination:

Malonaldehyde was determined by the reaction described by Ohkawa., et al., (1979). GPX is determined by the reaction described by Plgia and Velentine., (1967). Superoxide dismutase was performed according to the method of Nishikimi et al., (1972). Liver CAT activity was determined according to the method described by fossati et al., (1980).

2.7. Molecular investigation (real time PCR):

1. RNA extraction from liver tissues:

Pure RNA was extracted using total RNA Purification Kit following the manufacturer protocol (Thermo Scientific, Fermentas, #K0731). 2. cDNA synthesis: This technique was done using Revert Aid H minus Reverse Transcriptase which is a genetically modified M-MuLV RT, to convert RNA into complementary DNA (cDNA). 3. Quantification of RNA: was done by using Nanodrop.

2.8. Histopathological examinations:

Samples from the medial hepatic lobe were collected from animals of different groups, then fixed in 10% neutral buffered formalin. After dehydration and clearance, the tissues were embedded in paraffin and sectioned in 5 μ m thickness. The serial sections were subjected to staining with hematoxylin and eosin (Bancroft and Layton, 2013).

2.9. Statistical analysis:

The statistical analysis was carried out using one-way ANOVA using SPSS, ver. 22 (IBM Corp. Released 2013). Data of serum biochemistry, antioxidant assay and immunological assay were treated as a complete randomization design according to Steel et al., (1997). Multiple comparisons were carried out applying Tukey test. The significance level was set at $p < 0.05$.

3-RESULTS

1.3-Biochemical parameters: (table 1) in 1st check point and (table 2) in 2nd check point revealed that CCl₄ injected rats in group 4 showed significant increase in ALT, AST, GGT, ALP and bilirubin (total, direct and in-

direct) when compared with normal control rats. Rats protected with Silymarin or OBE revealed non-significant changes in ALT, AST, GGT, ALP and bilirubin (total, direct and indirect) compared with normal control rats.

In contrast, silymarin protected group and OBE protected group CCl₄ showed significant decrease in all elevated blood parameters comparing with CCl₄ injected rats.

2.3- Antioxidant parameters: (table 1) in 1st check point and (table 2) in 2nd check point revealed the following:

Compared with normal control rats, MDA was significantly increased in CCl₄ injected rats, while GPx was significantly decreased in 1st and 2nd check points. SOD and CAT levels showed a significant decrease in 1st check point, while non-significant changes in 2nd check point.

In comparison with normal control rats, silymarin administered rats revealed non-significant changes in MDA and GPx activities in 1st and 2nd check points. SOD and CAT showed non-significant changes in 1st check point, while a significant increase in 2nd check point.

Rats protected with Silymarin in 1st and 2nd check points showed significant increases in CAT, SOD and GPx activities, while a significant decrease in MDA compared with CCl₄ injected rats.

Concerning to OBE administered rats when compared with normal control rats showed significant decreases in SOD and GPx activities in 1st check point while non-significant changes in 2nd check points. Non-significant change in CAT activity and a significant increase in the level of MDA were observed in 1st and 2nd check points.

Rats protected with OBE revealed significant increases in GPx and SOD activities when compared with CCl₄ injected rats, while a significant decrease in MDA was recorded. A non-significant change in CAT activity was observed in 1st check point. Meanwhile there were non-significant changes in activities of SOD, GPx, CAT and MDA in 2nd check points.

3.3 Molecular analysis:

The obtained qPCR results in 2nd check point table (5) revealed a significant ($P \leq 0.05$) upregulation of (TNF α , IL4 and NF κ B/B genes) in liver of CCl₄ injected rats as compared to normal control rats.

Silymarin administered rats or OBE administered rats revealed non-significant

Hepatoprotective and antioxidant effects of *Ocimum basilicum* extract in

changes in the three genes expression when compared to normal control rats. The elevated expression of genes in CCl4 injected rats was significantly reduced following treatment by Silymarin and OBE. Rats protected with Silymarin revealed a significant decrease in the three genes expression when compared with rats protected with OBE.

3.4. Histopathology:

The liver of normal control rats showed normal hepatocytes arranged in cords around the central vein to form hepatic plates (figure 1A).

Comparing with normal control rats, CCl4 injected rats revealed marked hepatic tissue alteration represented by peculiar centrilobular

hepatic degeneration and necrosis. Most of hepatocytes around the central vein showed coagulative necrosis with marked fatty changes (figure 1B).

Silymarin administered rats or OBE administered rats showed no histopathological alteration and normal hepatocytes arranged in cords around the portal area when compared with normal control rats (figure 1C&1D).

Rats protected with Silymarin or OBE compared with CCl4 injected rats demonstrated noticeable decrease of fatty change (to mild and moderate degree), hepatic necrosis and inflammation (figure 1E&1F).

Table (1): Biochemical parameters of rats in different groups at 1st check point on 16th day of experiment

Group	Parameters						
	AST (U/L)	ALT (U/L)	GGT (U/L)	ALP (U/L)	T.B (mg/dl)	D.B (mg/dl)	Ind.B (mg/dl)
Control	96.23±3.9 ^c	53.84±3.60 ^b	9.68±0.80 ^b	117.98±5.39 ^b	0.81±0.05 ^b	0.2±0.02 ^b	0.58±0.04 ^b
Silymarin	95.92±4.24 ^c	54.12±4.62 ^b	9.48±0.92 ^b	123.66±5.66 ^b	0.81±0.06 ^b	0.24±0.03 ^b	0.58±0.05 ^b
Ocimum	96.85±4.28 ^c	54.67±4.64 ^b	9.58±0.93 ^b	124.87±5.71 ^b	0.82±0.06 ^b	0.24±0.03 ^b	0.58±0.06 ^b
CCL4	155.56±4.83 ^a	98.14±6.18 ^a	15.49±1.28 ^a	188.57±8.74 ^a	1.40±0.15 ^a	0.39±0.04 ^a	1.01±0.16 ^a
Silymarin + CCL4	113.55±4.60 ^b	63.53±4.24 ^b	11.42±0.94 ^b	139.22±6.35 ^b	0.96±0.06 ^b	0.27±0.02 ^b	0.69±0.05 ^b
Ocimum + CCL4	104.38±4.62 ^{bc}	58.89±5.03 ^b	10.31±1.00 ^b	134.56±6.16 ^b	0.88±0.06 ^{bc}	0.26±0.03 ^b	0.63±0.06 ^b

Results are expressed as mean ± S.E.M.

Superscript letters (a, b and c) indicate significant differences ($P \leq 0.05$) between any two means, within the same column

Table (2): Biochemical parameters of rats in different groups at 2nd check point on 22nd day of experiment

Group	Parameters						
	AST (U/L)	ALT (U/L)	GGT (U/L)	ALP (U/L)	T.B (mg/dl)	D.B (mg/dl)	Ind.B (mg/dl)
Control	106.46±4.52 ^b	65.79±3.67 ^b	9.42±0.49 ^b	115.51±9.39 ^b	1.13±0.02 ^b	0.39±0.02 ^b	0.74±0.02 ^b
Silymarin	110.70±4.71 ^b	68.49±3.87 ^b	9.79±0.51 ^b	120.13±9.76 ^b	1.17±0.03 ^b	0.41±0.02 ^b	0.76±0.02 ^b
Ocimum	113.49±5.72 ^b	70.45±4.76 ^b	10.24±0.49 ^b	115.39±10.19 ^b	1.18±0.03 ^b	0.40±0.02 ^b	0.79±0.03 ^b
CCL4	199.60±8.32 ^a	128.54±5.12 ^a	16.88±0.85 ^a	214.96±22.04 ^a	2.77±0.13 ^a	0.72±0.04 ^a	2.04±0.11 ^a
Silymarin + CCL4	122.41±5.21 ^b	75.73±4.28 ^b	10.83±0.56 ^b	132.84±10.80 ^b	1.30±0.03 ^b	0.45±0.02 ^b	0.85±0.02 ^b
Ocimum + CCL4	117.81±5.94 ^b	73.14±4.94 ^b	10.63±0.50 ^b	119.78±10.58 ^b	1.23±0.04 ^b	0.41±0.02 ^b	0.81±0.03 ^b

Results are expressed as mean ± S.E.M.

Superscript letters (a, b and c) indicate significant differences ($P \leq 0.05$) between any two means, within the same column

Table (3): Antioxidant parameters of rats in different groups at 1st check point on 16th day of experiment

Group	Parameters			
	MDA	SOD	GPX	CAT
	(nmol/mg)	(U/L)	(ng/mg)	(ng/mg)
Control	0.11±0.01 ^d	0.27±0.02 ^{ab}	0.34±0.03 ^a	0.27±0.01 ^{ab}
Silymarin	0.12±0.01 ^{cd}	0.32±0.02 ^a	0.29±0.02 ^{ab}	0.30±0.02 ^a
Ocimum	0.25±0.02 ^b	0.18±0.01 ^c	0.26±0.02 ^b	0.27±0.02 ^{ab}
CCL4	0.31±0.02 ^a	0.11±0.01 ^d	0.09±0.02 ^c	0.14±0.02 ^c
Silymarin + CCL4	0.17±0.02 ^c	0.31±0.01 ^a	0.26±0.02 ^b	0.25±0.04 ^{ab}
Ocimum + CCL4	0.23±0.01 ^b	0.22±0.02 ^{bc}	0.20±0.02 ^b	0.19±0.03 ^{bc}

Results are expressed as mean ± S.E.M.

Superscript letters (a, b and c) indicate significant differences ($P \leq 0.05$) between any two means, within the same column

Table (4): Antioxidant parameters of rats in different groups at 2nd check point on 22nd day of experiment

Group	Parameters			
	MDA	SOD	GPX	CAT
	(nmol/mg)	(U/L)	(ng/mg)	(ng/mg)
Control	0.12±0.00 ^c	0.16±0.01 ^b	0.27±0.03 ^{ab}	0.22±0.01 ^c
Silymarin	0.13±0.02 ^c	0.38±0.05 ^a	0.29±0.05 ^a	0.35±0.03 ^b
Ocimum	0.23±0.02 ^b	0.18±0.01 ^b	0.28±0.02 ^{ab}	0.23±0.01 ^c
CCL4	0.31±0.02 ^a	0.15±0.03 ^b	0.15±0.01 ^c	0.19±0.01 ^c
Silymarin + CCL4	0.16±0.04 ^c	0.31±0.04 ^a	0.33±0.06 ^a	0.41±0.03 ^a
Ocimum + CCL4	0.30±0.02 ^{ab}	0.18±0.03 ^b	0.22±0.03 ^{ab}	0.2±0.02 ^c

Results are expressed as mean ± S.E.M.

Superscript letters (a, b and c) indicate significant differences ($P \leq 0.05$) between any two means, within the same column.

Table (5). Relative expression of *TNF α* , *IL4* and *NFkB/B* gene in liver of different groups

Group	TNF alpha		IL4		NFkB/B	
	Fold change	SEM	Fold change	SEM	Fold change	SEM
	mean		Mean		mean	
Normal control (G1)	1.00 ^d	0.05	1.00 ^d	0.06	1.00 ^d	0.07
Silymarin group (G2)	0.96 ^d	0.05	1.15 ^d	0.07	1.04 ^d	0.08
Ocimum group (G3)	1.05 ^d	0.06	1.26 ^d	0.07	1.16 ^d	0.07
CCL4 group (G4)	5.54 ^a	0.31	10.06 ^a	0.37	6.45 ^a	0.34
Silymarin +CCL4 (G5)	2.69 ^b	0.10	3.01 ^b	0.16	3.16 ^b	0.20
Ocimum +CCL4(G6)	3.92 ^c	0.18	5.03 ^c	0.28	4.14 ^c	0.27

Results are expressed as mean ± S.E.M.

Superscript letters (a, b and c) indicate significant differences ($P \leq 0.05$) between any two means, within the same column.

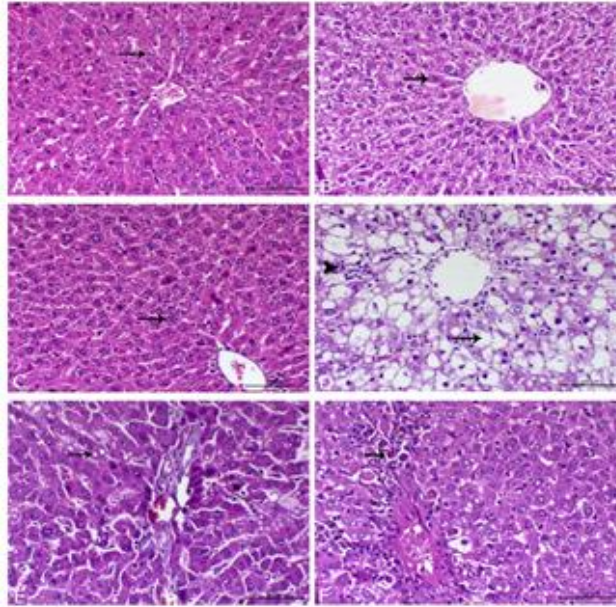


Fig.1.A: Liver of rat (control) showing normal hepatocytes arranged in cords around the central vein (arrow), H&E, bar= 100 μ m.; B: Liver of rat administered with silymarin showing normal hepatocytes arranged in cords around the central vein (arrow), H&E, bar= 100 μ m.; C: Liver of rat administered with *O. basilicum* showing normal hepatocytes arranged in cords around the central vein (arrow), H&E, bar= 100 μ m.; D: Liver of rat intoxicated with CCl₄ showing marked centrilobular hepatic vacuolation (arrow) associated with mononuclear cells infiltration (arrowhead), H&E, bar= 100 μ m.; E: Liver of rat intoxicated with CCl₄ and protected with silymarin showing mild to moderate degree of fatty change (arrow), H&E, bar= 100 μ m ; F: Liver of rat intoxicated with CCl₄ and protected with *O. basilicum* showing marked decrease of the hepatic necrosis and cellular apoptosis (arrow), H&E, bar= 100 μ m.

4. DISCUSSION

Regarding to liver enzymes, rats injected with CCl₄ showed significant increase in the ALT and AST activities in 1st and 2nd check points. These results agree with Shah et al., (2015) who attributed that CCl₄ causes injury of the membrane and so leakage of the cytosomal enzymes. That is may be due to the reactive intermediate free radicals which are produced by CCl₄ bioactivation by cytochrome P450 (Weber et al., 2003). Also, CCl₄ treatment causes an increase in the level of serum GGT, ALP and total, direct and indirect bilirubin. These results agree with Li et al., (2015). The increase may be attributed to the increase synthesis of GGT and ALP in case of the biliary pressure increase (Muriel et al., 1992). Silymarin protected group significantly reduced the elevated liver enzymes and bilirubin (total, direct and indirect) after CCl₄ administration in 1st and 2nd check points. These findings agree with Saller et al., (2007). Silymarin contain natural products as tocopherol and ascorbic acid 6 hexadecanoate, sterols, sterylglucosides and squalene, which could diminish the membrane peroxidation as well as the leakage of enzymes (Habib-ur-

Rehman et al., 2009).

In 1st and 2nd check points, the administration of OBE significantly decreased the serum ALT and AST, ALP, GGT, total, direct and indirect bilirubin close to normal control rats. Results from this study conform with Atangwho et al., (2014) and Meera et al., (2009) .. These results could be explained that OBE protects the hepatocytes from injuries and improves the function of liver (Chiu et al., 2012).

Concerning to antioxidants parameters, the increase of MDA in CCl₄ administered rats in 1st and 2nd check points compared to normal rats may be attributed to the trichloromethyl radicals that resulted from CCl₄ metabolism. Those radicals stimulate the process of lipid peroxidation with the formation of by-products such as MDA. (Madubuike et al., 2015)

Also, in the present study, the hepatic antioxidant enzymes SOD and CAT (in 1st check point) and GPx (in 1st and 2nd check points) were significantly decreased activities in CCl₄-intoxicated rats compared with control rats. These results partially match with Tsai et al., (2009). Decrease in enzyme activity may be attributed to the deactivation of their

isoenzymes by oxidation of a cysteine residue near the active centre (Tamai et al., 1990).

Rats protected with Silymarin showed a significant decrease in MDA levels. On the contrary, SOD, catalase and GPx activities were significantly elevated by administration of silymarin to CCl₄-intoxicated rats, that reflects its ability to restore these enzymes activities in the liver damaged by CCl₄. These result is in agreement with Trappoliere et al., (2009). Silymarin contain linoleic acid that could be converted into certain isomers of conjugated linoleic acids (CLA) in the gastrointestinal tract of rats. CLA inhibit lipoperoxidation and as a result, MDA decreased (Arab et al., 2006). Also due to its content of tocopherol (Sudheesh et al., 2013), CLA (Belury, 2002), sterols (Conforti et al., 2008), ascorbic acid 6-hexadecanoate (Klein and Weber., 2001) and sterylglucosides (Mirmiran et al., 2014), it recovers the activities of CAT and SOD, as well as of GPx as these substances have antioxidant effects.

Rats administered OBE only compared with normal rats showed significant increase in liver MDA in 1st and 2nd check points and significant decreases in liver SOD and GPx levels in 2nd check point. These results partially agree with Karaali et al., (2018) who found that pretreatment with basils extract caused increase in serum ALT and AST and MDA in liver.

OBE protected group demonstrated significant increases in GPx and SOD compared with CCl₄ injected rats, while a significant decrease in MDA was observed in the 1st check point. Dasgupta et al., (2007) found that *O. basilicum* increased the activity of xenobiotic metabolizing phase I and phase II enzymes, elevating antioxidant-enzyme response.

Regarding to proinflammatory and anti-inflammatory cytokine expression, CCl₄ cause a significant increase in TNF- α and NF κ B expression. The free radicals and ROS that generated from CCl₄ metabolism by cytochrome P450 2E1 (CYP2E1), stimulate the upregulation of TNF- α (Jeong, 2008).

Chávez et al., (2008) mentioned that CCl₄ increase NF κ B, which regulates the several genes transcription including cytokines in rat. Liver injury caused by CCl₄ leads to rapid recruitment of eosinophils, which secrete IL-4 to stimulate the proliferation of quiescent hepatocytes. IL-4 is able to stimulate cell cycle progression via IL-4R α in liver cells (Goh et

al., 2013).

Silymarin protected group showed a lower expression level of TNF- α , IL-4 and NF κ B compared to CCl₄ injected rats. This trend agrees with Schümann et al., (2003). That result reflects the ability of silymarin to ameliorate inflammatory markers (Altaei, 2012). Silibinin considered to be an immune-response modifier in vivo, suppressing the NF- κ B activation which suppresses the subsequent synthesis of TNF and stimulating synthesis of IL-10 within the liver. In addition, while the synthesis of IL-10 was stimulated, the intrahepatic production of IL-4 was inhibited (Abenavoli et al., 2008).

OBE causes a significant decrease in the expression of genes (TNF α , IL4 and NF κ B) comparing with CCl₄ injected rats. These results partially agree with Athari et al., (2018). Rosmarinic acid which present in large amounts in OBE (Makino et al., 1998), suppress the induction of TNF α by inhibiting the proliferation of mesangial cell which secretes TNF α as autocrine factors. The antiproliferative effects exhibited by rosmarinic acid are due to its suppressive effects on PDGF (platelet derived growth factor) and c-myc m-RNA expression which are essential in mesangial cell proliferation (Makino et al., 2000). *Ocimum labiatum* extract treatment causes down-regulation of the IL-4 cytokine by reconditioning the function of Th2 effector cells (Taylor et al., 2012).

Concerning to histopathological changes, CCl₄ causes centrilobular hepatic degeneration and coagulative necrosis with marked fatty changes. The present results are in accordance with those of Sreelatha et al., (2009). CCl₄ is metabolized by cytochrome P-450 enzymes that leads to liberation of free radicles as trichloromethyl and trichloro-methylperoxyl radicals. These radicals bind to hepatocyte components and also affect unsaturated fatty acids that results in phospholipid destruction (Cheeseman et al., 1985), which results in accumulation of fat (fatty liver) and damage of the liver (Chamulitrat et al., 1995).

The current results revealed that silymarin treatment was shown to decrease fatty change, hepatic necrosis and inflammation. These findings agree with those of Abdel-Salam et al., (2007). The hepatoprotective role of silymarin acted by antioxidative, anti-fibrotic, anti-lipid peroxidative, membrane stabilizing

and liver regenerating mechanisms (Chlopčiková et al., 2004; Pradhan and Girish, 2006). The anti-inflammatory effect of silymarin is mediated through inhibition of neutrophil migration (De La Puerta et al., 1996).

The present study showed that OBE decrease hepatic necrosis and vacuolation. These results agree with Ogaly et al., (2015). OBE has anti-inflammatory and hepatotonic effects acting by stimulating p450 detoxification enzymes help in neutralization of free radicals and overtly aggressive oxygen species. Moreover, ocimum basilicum contains methyl eugenol which has antioxidant and anti-inflammatory properties (Duke, 2003). In addition, ocimum basilicum can decrease the conversion of hepatic stellate cells into myofibroblasts (Salmah et al., 2005).

5. CONCLUSION

The results of present study demonstrate that OBE has hepatoprotective ability against CCl₄ hepatotoxicity in rats comparing with silymarin. The results also imply that the hepatoprotective effects of OBE may be due to the presence of flavonoids compounds with strong antioxidant activities. However, silymarin has more potent hepatoprotective and antioxidant effect than ocimum.

6. REFERENCES

- Abdel-Salam, O.M., Sleem, A.A. and Morsy, F.A., 2007. Effects of biphenyl-dimethyl-dicarboxylate administration alone or combined with silymarin in the CCL4 model of liver fibrosis in rats. *The Scientific World Journal* 7, 1242-1255
- Abenavoli, L., Capasso, R., Milic, N. and Capasso, F., 2010. Milk thistle in liver diseases: past, present, future. *Phytotherapy Research* 24, 1423-1432.
- Altaei, T., 2012. Protective effect of silymarin during coronary artery bypass grafting surgery. *Experimental & Clinical Cardiology* 17, 34-38.
- Arab, K., Rossary, A., Soulere, L. and Steghens, J.-P., 2006. Conjugated linoleic acid, unlike other unsaturated fatty acids, strongly induces glutathione synthesis without any lipoperoxidation. *British Journal of Nutrition* 96, 811-819.
- Arts, I. C. and Hollman, P. C., 2005. Polyphenols and disease risk in epidemiologic studies. *Am. J. Clin. Nutr.*, 81: 317S-325S.
- Atangwho, I.J., Yin, K.B., Umar, M.I., Ahmad, M. and Asmawi, M.Z., 2014. *Vernonia amygdalina* simultaneously suppresses gluconeogenesis and potentiates glucose oxidation via the pentose phosphate pathway in streptozotocin-induced diabetic rats. *BMC complementary and alternative medicine* 14-426.
- Athari, S.M., Nasab, E.M. and Athari, S.S., 2018. Study effect of *Ocimum basilicum* seeds on mucus production and cytokine gene expression in allergic asthma mice model. *Revue Française d'Allergologie* 58, 489-493.
- Bancroft, J. D. and Layton C., 2013. The haemtoxylins and eosin. Bancroft's Theory and practice of histological techniques, Expert consult: Online and print, 7: Bancroft's Theory and practice of histological techniques, 173-186.
- Belury, M.A., 2002. Dietary conjugated linoleic acid in health: physiological effects and mechanisms of action. *Annual review of nutrition* 22, 505-531.
- Burtis, C.A., Ashwood, E.R. and Bruns, D.E., 2012. *Tietz textbook of clinical chemistry and molecular diagnostics-e-book*. Elsevier Health Sciences 28(1), 104-105.
- Chamulitrat, W., Blazka, M.E., Jordan, S.J., Luster, M.I. and Mason, R.P., 1995. Tumor necrosis factor- α and nitric oxide production in endotoxin-primed rats administered carbon tetrachloride. *Life sciences* 57, 2273-2280.
- Chávez, E., Reyes-Gordillo, K., Segovia, J., Shibayama, M., Tsutsumi, V., Vergara, P., Moreno, M.G. and Muriel, P., 2008. Resveratrol prevents fibrosis, NF- κ B activation and TGF- β increases induced by chronic CCl₄ treatment in rats. *Journal of Applied Toxicology: An International Journal* 28, 35-43.
- Chaware, V., Joshi, Y. and Biyani, K., 2009. Hepatoprotective activity of Hydroalcoholic extract of *Momordica charantia* Linn. leaves against Carbon tetra chloride induced Hepatopathy in Rats 1, 355-358
- Cheeseman, K.H., Albano, E.F., Tomasi, A. and

- Slater, T.F., 1985. Biochemical studies on the metabolic activation of halogenated alkanes. *Environmental health perspectives* 64, 85-101.
- Chiu, C.-C., Huang, C.-Y., Chen, T.-Y., Kao, S.-H., Liu, J.-Y., Wang, Y.-W., Tzang, B.-S. and Hsu, T.-C., 2012. Beneficial effects of *Ocimum gratissimum* aqueous extract on rats with CCl₄-induced acute liver injury. *Evidence-Based Complementary and Alternative Medicine* 2012, 736-752.
- Chlopčíková, Š., Psotová, J., Miketová, P. and Šimánek, V., 2004. Chemoprotective effect of plant phenolics against anthracycline-induced toxicity on rat cardiomyocytes. Part I. Silymarin and its flavonolignans. *Phytotherapy Research: An International Journal Devoted to Pharmacological and Toxicological Evaluation of Natural Product Derivatives* 18, 107-110.
- Conforti, F., Sosa, S., Marrelli, M., Menichini, F., Statti, G.A., Uzunov, D., Tubaro, A., Menichini, F. and Della Loggia, R., 2008. In vivo anti-inflammatory and in vitro antioxidant activities of Mediterranean dietary plants. *Journal of ethno-pharmacology* 116, 144-151.
- D'Archivio, M., Filesi, C., Di Benedetto, R., Gargiulo, R., Giovannini, C. and Masella, R., 2007. Polyphenols, dietary sources and bioavailability. *Ann. Ist. Super. Sanita*, 43: 348-361
- Dasgupta, T., Rao, A. and Yadava, P., 2004. Chemomodulatory efficacy of basil leaf (*Ocimum basilicum*) on drug metabolizing and antioxidant enzymes, and on carcinogen-induced skin and forestomach papilloma-genesis. *Phytomedicine* 11, 139-151.
- De La Puerta, R., Martinez, E., Bravo, L. and Ahumada, M., 1996. Effect of silymarin on different acute inflammation models and on leukocyte migration. *Journal of Pharmacy and Pharmacology* 48, 968-970.
- Duke, J.A., 2003. *Handbook of Medicinal Herbs*, 2nd ed.; CRC Press, Boca Raton, FL, USA, p. 339.
- Fehér, J. and Lengyel, G., 2012. Silymarin in the prevention and treatment of liver diseases and primary liver cancer, *Curr. Pharm. Biotechnol* 13, 210–217.
- Fossati, P., Prencipe, L. and Berti, G., 1980. Use of 3, 5-dichloro-2-hydroxybenzene sulfonicacid/ 4-aminophenazone chromogenic system in direct enzymic assay of uric acid in serum and urine. *Clinical chemistry* 26, 227-231.
- Gabele, E., Brenner, D.A. and Rippe, R.A., 2003. signals leading to the amplification of the fibrogenic hepatic stellate cell, *Front. Biosci.* 8d 69– 77.
- Gandhimathi, R. and Saravana Kumar, A., 2012. Effect of *Malachra capitata* (L.) extracts on biogenic amines concentrations in rat brain after induction of seizure. *International Journal of Pharmacy* 2, 54-58.
- Goh, Y.S., Henderson, N.C., Heredia, J.E., Eagle, A.R., Odegaard, J.I., Lehwald, N., Nguyen, K.D., Sheppard, D., Mukundan, L. and Locksley, R.M., 2013. Eosinophils secrete IL-4 to facilitate liver regeneration. *Proceedings of the National Academy of Sciences* 110, 9914-9919.
- Habib-ur-Rehman, M., Mahmood, T., Salim, T., Afzal, N., Ali, N., Iqbal, J., Tahir, M. and Khan, A., 2009. Effect of silymarin on serum levels of ALT and GGT in ethanol induced hepatotoxicity in albino rats. *Journal of Ayub Medical College Abbottabad* 21, 73-75.
- Jeong, K.S., 2008. Therapeutic target for chronic liver fibrosis by regulation of transforming growth factor-beta. *Basic and Applied Pathology* 1, 56-60.
- Karaali, H.F., Fahmi, R.R. and Borjac, J.M., 2018. Effect of *Ocimum basilicum* leaves extract on acetaminophen-induced nephrotoxicity in BALB/c mice. *Journal of Complementary and Integrative Medicine*.
- Klein, E. and Weber, N., 2001. In vitro test for the effectiveness of antioxidants as inhibitors of thiyl radical-induced reactions with unsaturated fatty acids. *Journal of agricultural and food chemistry* 49, 1224-1227.
- Kim, N. C., Graf, T.N., Sparacino, C.M., Wani, M.C. and Wall, M.E., 2003. Complete isolation and characterization of silybins and isosilybins from milk thistle (*Silybum marianum*). *Organic & biomolecular chemistry* 1, 1684-1689
- Li, C., Yi, L.-T., Geng, D., Han, Y.-Y. and Weng, L.-j., 2015a. Hepatoprotective effect of ethanol extract from

- Berchemia lineate against CCL4-induced acute hepatotoxicity in mice. *Pharmaceutical biology* 53, 767-772.
- Madubuike, G.K., Onoja, S.O. and Ezeja, M.I., 2015. Antioxidant and Hepatoprotective Activity of Methanolic Extract of *Cassia sieberiana* Leaves in Carbon Tetrachloride-induced Hepatotoxicity in Rats. *J Adv Med Pharmaceut Sci* 2, 1-9.
- Makino, T., Ono, T., Muso, E. and Honda, G., 1998. Inhibitory effect of *Perilla frutescens* and its phenolic constituents on cultured murine mesangial cell proliferation. *Planta medica* 64, 541-545.
- Makino, T., Ono, T., Muso, E., Yoshida, H., Honda, G. and Sasayama, S., 2000. Inhibitory effects of rosmarinic acid on the proliferation of cultured murine mesangial cells. *Nephrology Dialysis Transplantation* 15, 1140-1145.
- Manikandan, P., Murugan, R.S., Abbas, H., Abraham, S. and Nagini, S., 2007. *Ocimum sanctum* Linn.(Holy Basil) ethanolic leaf extract protects against 7, 12-Dimethylbenz [a] Anthracene-induced genotoxicity, oxidative stress, and imbalance in xenobiotic-metabolizing enzymes. *Journal of medicinal food* 10, 495-502.
- Meera, R., Devi, P., Kameswari, B., Madhumitha, B. and Merlin, N., 2009. Antioxidant and hepatoprotective activities of *Ocimum basilicum* Linn. and *Trigonella foenum-graecum* Linn. against H₂O₂ and CCl₄ induced hepatotoxicity in goat liver. *Indian Journal of Experimental Biology (IJEB)* 47, 584-590.
- Mirmiran, P., Bahadoran, Z. and Azizi, F., 2014. Functional foods-based diet as a novel dietary approach for management of type 2 diabetes and its complications: A review. *World journal of diabetes* 5, 267.
- Muriel, P., Garcapiña, T., Perez-Alvarez, V. and Mourelle, M., 1992. Silymarin protects against paracetamol-induced lipid peroxidation and liver damage. *Journal of Applied Toxicology* 12, 439-442.
- Negi, A.S., Kumar, J., Luqman, S., Shanker, K., Gupta, M. and Khanuja, S., 2008. Recent advances in plant hepatoprotectives: a chemical and biological profile of some important leads. *Medicinal Research Reviews* 28, 746-772.
- Nishikimi, M., Roa, N. and Yogi, K., 1972. Measurement of superoxide dismutase. *Biochem. Biophys. Res. Common* 46, 849-854.
- Ogaly, H.A., Eltablawy, N.A., El-Beairy, A.M., El-Hindi, H. and Abd-Elsalam, R.M., 2015. Hepatocyte growth factor mediates the antifibrogenic action of *Ocimum basilicum* essential oil against CCl₄-induced liver fibrosis in rats. *Molecules* 20, 13518-13535.
- Ohkawa, H., Ohishi, N. and Yagi, K., (1979). Assay for lipid peroxides in animal tissues by thiobarbituric acid reaction. *Analytical biochemistry* 95, 351-358.
- Pereira-Filho, G., Ferreira, C., Schwengber, A., Marroni, C., Zettler, C. and Marroni, N., 2008. Role of N-acetylcysteine on fibrosis and oxidative stress in cirrhotic rats, *Arq. Gastroenterol* 45, 156-162.
- Plagia, D. and Valentine, W., 1967. Assessment of blood glutathione peroxidase activity. *J. Lab. Clin. Med* 70, 158-169.
- Pradhan, S. and Girish, C., 2006. Hepatoprotective herbal drug, silymarin from experimental pharmacology to clinical medicine. *Indian Journal of Medical Research* 124, 491-504.
- Rafat, A., Philip, K. and Muniandy, S., 2010. Antioxidant potential and phenolic content of ethanolic extract of selected Malaysian plants. *Research Journal of Biotechnology* Vol 5, 1 16-19.
- Refaey, M., Mustafa, M., Mohamed, A. and Ali, A., 2015. Hepatoprotective and antioxidant activity of *Odontonema cuspidatum* (Nees) Kuntze against CCl₄-induced hepatic injury in rats. *Journal of Pharmacognosy and Phytochemistry* 4, 89-96.
- Saller, R., Melzer, J., Reichling, J., Brignoli, R. and Meier, R., 2007. An updated systematic review of the pharmacology of silymarin. *Complementary Medicine Research* 14, 70-80.
- Schumann, G. and Klauke, R., 2003. New IFCC reference procedures for the determination of catalytic activity concentrations of five enzymes in serum: preliminary upper reference limits obtained in hospitalized subjects.

- Clinica chimica acta 327, 69-79
- Shah, M.D., Gnanaraj, C., Haque, A.E. and Iqbal, M., 2015. Antioxidative and chemopreventive effects of *Nephrolepis biserrata* against carbon tetrachloride (CCl₄)-induced oxidative stress and hepatic dysfunction in rats. *Pharmaceutical biology* 53, 31-39.
- Shirazi, M.T.; Gholami, H.; Kavooosi, G.; Rowshan, V. 2014. Chemical composition, antioxidant, antimicrobial and cytotoxic activities of *Tagetes minuta* and *Ocimum basilicum* essential oils. *Food Sci. Nutr.*, 2, 146–155.
- Sreelatha, S., Padma, P. and Umadevi, M., 2009. Protective effects of *Coriandrum sativum* extracts on carbon tetrachloride-induced hepatotoxicity in rats. *Food and Chemical Toxicology* 47, 702-708.
- Steel, R.G. and Torrie, J.H., 1980. Principles and procedures of statistics, a biometrical approach. McGraw-Hill Kogakusha, Ltd 2, 633.
- Sudheesh, N., Ajith, T. and Janardhanan, K., 2013. Hepatoprotective effects of DL- α -lipoic acid and α -Tocopherol through amelioration of the mitochondrial oxidative stress in acetaminophen challenged rats. *Toxicology mechanisms and methods* 23, 368-376.
- Szasz, G., 1969. A kinetic photometric method for serum γ -glutamyl transpeptidase. *Clinical chemistry* 15, 124-136.
- Tamai, K., Satoh, K., Tsuchida, S., Hatayama, I., Maki, T. and Sato, K., 1990. Specific inactivation of glutathione S-transferases in class Pi by SH-modifiers. *Biochemical and biophysical research communications* 167, 331-338.
- Taylor, M.D., van der Werf, N. and Maizels, R.M., 2012. T cells in helminth infection: the regulators and the regulated. *Trends in immunology* 33, 181-189.
- Tietz, N., Rinker, A. and Shaw, L., 1983. IFCC methods for the measurement of catalytic concentration of enzymes Part 5. IFCC method for alkaline phosphatase (orthophosphoric-monoester phosphohydrolase, alkaline optimum, EC 3.1. 3.1). *Journal of clinical chemistry and clinical biochemistry. Zeitschrift fur klinische Chemie und klinische Biochemie* 21, 48-731.
- Trappoliere, M., Caligiuri, A., Schmid, M., Bertolani, C., Failli, P., Vizzutti, F., Novo, E., di Manzano, C., Marra, F. and Loguercio, C., 2009. Silybin, a component of silymarin, exerts anti-inflammatory and anti-fibrogenic effects on human hepatic stellate cells. *Journal of hepatology* 50, 1102-1111
- Tsai, C.-F., Hsu, Y.-W., Chen, W.-K., Chang, W.-H., Yen, C.-C., Ho, Y.-C. and Lu, F.-J., 2009. Hepatoprotective effect of electrolyzed reduced water against carbon tetrachloride-induced liver damage in mice. *Food and Chemical Toxicology* 47, 2031-2036.
- Weber, L.W., Boll, M. and Stampfl, A., 2003. Hepatotoxicity and mechanism of action of haloalkanes: carbon tetrachloride as a toxicological model. *Critical reviews in toxicology* 33, 105-136.
- Yang, L., Tan, G.-Y., Fu, Y.-Q., Feng, J.-H. and Zhang, M.-H., 2010. Effects of acute heat stress and subsequent stress removal on function of hepatic mitochondrial respiration, ROS production and lipid peroxidation in broiler chickens. *Comparative Biochemistry and Physiology Part C: Toxicology & Pharmacology* 151, 204-208.