



## CAN ORTHOPANTOMOGRAM BE UTILIZED IN DENTOSKELETAL MEASUREMENTS AS COMPARED TO LATERAL CEPHALOGRAMS?

Marwa Sameh Shamaa\* and Marwa Ali Tawfik\*

### **ABSTRACT**

**Objective:** To enhance the orthopantomogram's (OPG) clinical application by establishing its capability in investigating some dentoskeletal specifications compared to lateral cephalograms (LCRs) in light of the importance of reducing routine patient's exposure to radiation.

**Methods:** Pretreatment OPGs and LCRs of 120 patients (ranging in age from 10-15 years) with dental and skeletal class I, II and III relationships (40 patients/group) respectively, were collected randomly from the Orthodontic Department, Faculty of Dentistry, Mansoura University. The selected OPGs and LCRs had to be taken in the same day by the same apparatus and in ideal position according to the manufacturer's instructions. Two-way ANOVA was used to detect possible differences between classes and types of radiographs followed by multiple comparisons (post hoc test) between each 2 groups using the Bonferroni correction if significant differences were noted.

**Results:** There was a statistically significant difference in the assessed parameters using OPGs between groups for the anterior mandibular height (AHMn), the distance from the incisal edge of the most extruded lower central incisor to the anterior mandibular line (ii-Mla) and the distance from the mesial cusp tip of the mandibular permanent first molar to the mandibular line (mi-ML) only. In LCRs, there was a significant difference between classes for AHMn and mi-ML only. A significant difference was detected between OPGs and LCRs for AHMn and mi-ML only ( $p < .05$ ). However, no difference was found in the other parameters between the two types of radiographs for all classes. Measurements of panoramic radiographs were significantly higher than cephalometric radiographs for AHMn and mi-ML.

**Conclusion:** OPG could be considered a reliable alternative for LCR for assessment of many angular and linear dentoskeletal characteristics in different classes to reduce the radiation dose involved in routine diagnostic purposes, so that the use of LCRs could be restricted to certain indications.

**KEY WORDS:** Orthopantomogram; panoramic radiograph, cephalogram.

---

\* Lecturer of Orthodontics, Faculty of Dentistry, Mansoura University, Egypt.

## INTRODUCTION

Orthodontic treatment comprises not only treatment of dental malocclusions, but also encompasses the diagnosis and management of facial and skeletal problems, aberrant myofunctional habits and temporomandibular dysfunctions.<sup>1</sup>

Radiographs enable visibility of bone that cannot be seen by the naked eye. Numerous potential landmarks provide diagnostic guidance about development and growth of maxilla and mandible, which are the areas of interest in dentistry. These diagnostic data are required in different fields of dentistry such as orthodontics, endodontics and periodontics.<sup>2</sup>

Orthopantomogram (OPG) makes provision of the orthodontist with an inclusive overview of the maxillofacial complex with comparatively decreased risk of radiation. It forms a substantial diagnostic aid by its capability to obtain a single view of the jaws, teeth, temporomandibular joints, the whole stomatognathic system and sinuses. OPG is often utilized in orthodontic practice to give essential information about the dentition, their eruption status, axial inclinations and the surrounding tissues. Both right and left side landmarks could be clearly seen separately using panoramic radiography, preventing structures' overlapping or superimposition observed in lateral cephalograms (LCRs).<sup>3</sup>

Lateral cephalogram is considered a fundamental tool for orthodontic diagnosis and treatment planning. It is used for evaluation of the skeletal relation, growth pattern, teeth and alveolar process.<sup>4</sup> Although LCR supply us with abundant information concerning the craniofacial structures, it is not possible to precisely visualize the right and left sides of these structures in the same radiograph as a result of superimposition of both sides.<sup>5</sup>

Shahabi et al<sup>6</sup> revealed that orthopantomograms

might be preferable than lateral cephalograms for gonial angle determination in class I patients. The gonial angle represents an important indicator of the growth pattern and craniofacial disorders in orthodontics.<sup>7</sup> It is one of the parameters which influences the decision of teeth extraction in class II patients, while in class III malocclusions, this angle can impact the treatment plan and affects the decision of surgical intervention.<sup>8</sup>

Inter-jaw base angle determines the vertical relation of the maxilla and mandible. Its increase is correlated with posterior growth rotation and decreased overbite or anterior open bite tendency. Extrusive mechanics should be avoided during its treatment as they cause further overbite reduction. Its decrease is accompanied by anterior growth rotation which results in a tendency towards overbite increase that may worsen with growth. Non extraction treatment may be indicated in these cases due to the difficulty that may be encountered during space closure.<sup>9</sup>

Evaluation of craniofacial dimensions, particularly those of the maxilla and mandible, permits the orthodontist to decide if there is an abnormality that entails meticulous intervention and is essential in establishing the proper treatment plan.<sup>10</sup> Also, vertical dental measurements are valuable in orthodontic diagnosis as they indicate the teeth eruption in respect to their supporting bone. Increased posterior dental height can be associated with anterior open bite.<sup>11</sup>

In light of the importance of reducing routine patient's exposure to radiation, the aim of this study was to investigate the potential employment of orthopantomograms in various dentoskeletal measurements in dental & skeletal class I, II and III patients and comparing them with those obtained from lateral cephalograms, so that the use of LCRs might be limited to certain indications.

## MATERIAL AND METHODS

Preoperative panoramic radiographs and lateral cephalograms of 120 patients (ranging in age from 10-15 years) with dental and skeletal class I, II and III relationships were collected randomly from the Orthodontic Department, Faculty of Dentistry, Mansoura University. They were selected based on the following inclusion criteria: (1) fully erupted permanent incisors and first molars, (2) high quality radiographs, (3) no history of trauma or syndromes affecting the facial symmetry, (4) no history of systemic disease impacting growth and development. The sample size of 120 patients (40 patients /group) was selected to give 99% power in the results of this study (effect size =0.317,  $\alpha=.05$ ) based on the findings of a previous work of Sharma et al <sup>5</sup> in which the authors found a significant difference in the mandibular length between PRs and LCRs using a similar study design. All participants were informed about the study and written consents were obtained from them.

Both panoramic and lateral cephalometric radiographs of every patient had to be taken in the same day by the same apparatus and in ideal position according to the manufacturer's instructions. The midfacial plane was kept in a vertical position with the Frankfort horizontal plane parallel to the floor. Printed pictures of OPGs and LCRs with a ratio of 1:1 were utilized for assessment. The selected radiographs had been traced, after locating landmarks, lines and angles were drawn and different parameters were measured. For lateral cephalograms, double contours were averaged, whereas in orthopantomograms the right and left sides were measured separately and the mean was calculated and compared with LCRs.

### *OPG & LCR reference points and lines<sup>12</sup>:(fig 1)*

1. **Co (Condylion):** highest point on the condylar head.
2. **Cod (Condylion dorsale):** most posterior point on the condylar head.
3. **Gn (Gnathion) (OPG):** most inferior point of the mandible in the canine region of each side.  
**Gn (Gnathion) (LCR):** most anterior and inferior point of the bony chin.
4. **m (Gnathion mediana) (OPG):** most inferior point of the contour of the bony chin in the median plane.
5. **Tgc (Corpus tangent point):** contact point in the gonial area of the tangent to the lower border of the mandible, which passes through Gn.
6. **Go (Gonial tangent point):** intersection of a tangent to the posterior border of the ramus through Cod and a tangent through Tgc and Gn.
7. **Sp (Spina nasalis anterior) (OPG):** most inferior point in which the nasal borders of the maxillary bones meet in the median sagittal plane.  
**Sp (Spina nasalis anterior) (LCR):** tip of the anterior nasal spine.
8. **Pm (Pterygomaxillare):** intersection of the nasal line and the pterygomaxillary fissure.
9. **NL (Nasal line):** it is line joining Sp and Pm.
10. **RL (Ramus tangent):** tangent to the posterior border of the ramus through Cod.
11. **ML (Mandibular line):** it is line joining Tgc and Gn.  
**MLa (OPG) Anterior mandibular line:** it is line joining Gn of each side.
12. **al-is (Limbus alveolaris incision superior):** the most superior point of the alveolar ridge in the maxillary incisor area.
13. **al-ms (Limbus alveolaris molar superior):** the most superior point of the alveolar ridge between the maxillary first and second molars.
14. **al-ii (Limbus alveolaris incision inferior):** the most superior point of the alveolar ridge in the mandibular incisors area.
15. **al-mi (Limbus alveolaris molar inferior):** the most superior point of the alveolar ridge between the mandibular first and the second molars.

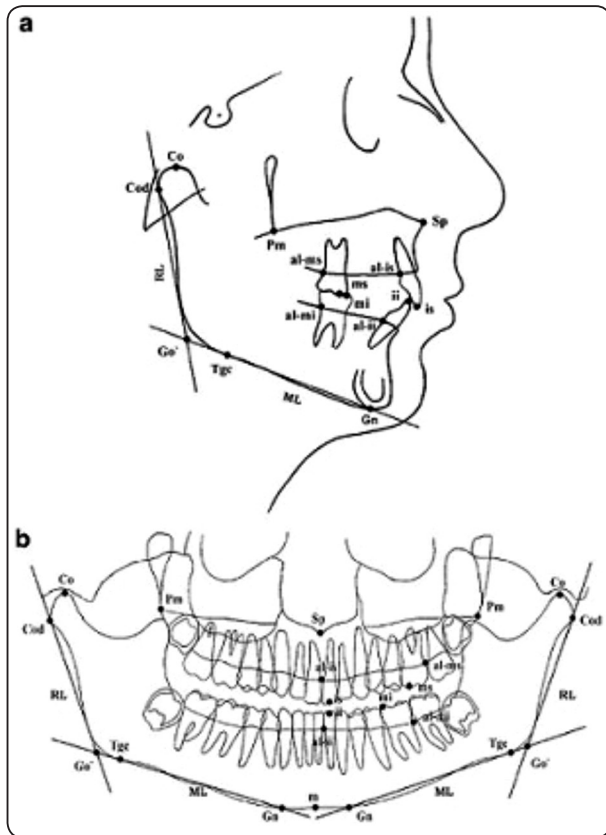


Fig. (1): Reference points and lines utilized in analysis of LCR (a) and OPG (b)

The dentoskeletal parameters measured were as follow<sup>12</sup>:(fig 2&3)

1. **Gonial angle:** it is the angle formed between ML and RL lines.
2. **Inter-jaw base angle:** it is the angle formed between mandibular and nasal lines.
3. **Total mandibular length:** it is the distance between Co and Gn.
4. **Anterior maxillary height (AHMx):**  
(OPG): it is the distance between al-is and Sp.  
(LCR): it is the vertical distance between al-is and nasal line.
5. **Posterior maxillary height (PHMx):** it is the vertical distance between al-ms and nasal line.
6. **Anterior mandibular height (AHMn):**  
(OPG): it is the distance between al-ii and m.  
(LCR): it is the vertical distance between al-ii and mandibular line.

7. **Posterior mandibular height (PHMn):** it is the vertical distance between al-mi and mandibular line.
8. **Distance from the incisal edge** of the most extruded upper incisor to the nasal line (is-NL).
9. **Distance from the incisal edge** of the most extruded lower central incisor to:  
MLa (ii-MLa) in OPG.  
ML (ii-ML) in LCR.
10. **Distance from the mesial cusp tip** of the maxillary permanent first molar to the nasal line (ms-NL).
11. **Distance from the mesial cusp tip** of the mandibular permanent first molar to the mandibular line (mi-ML).

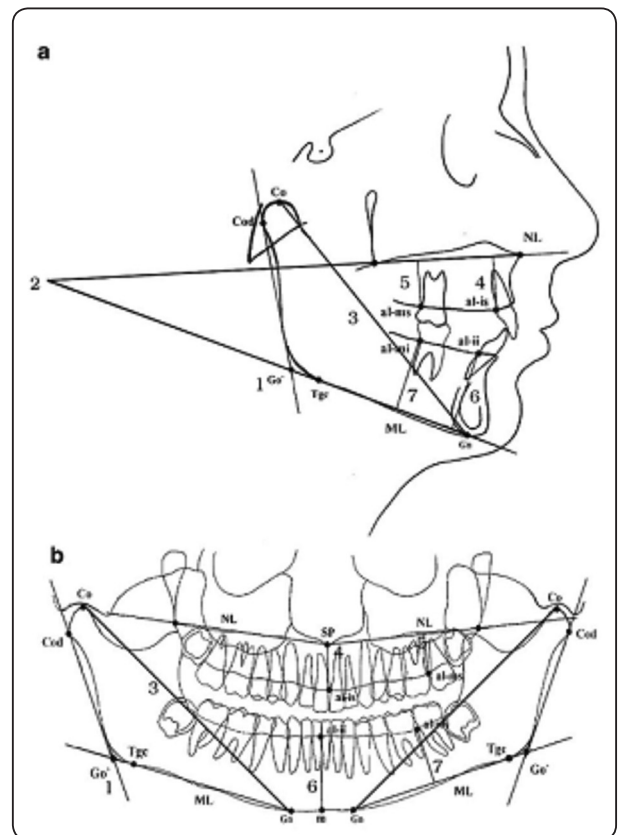


Fig. (2): The assessed skeletal parameters: (1) ML/RL angle, (2) ML/NL angle, (3) Co-Gn and alveolar parameters: (4) AHMx, (5) PHMx, (6)AHMn, (7) PHMn.

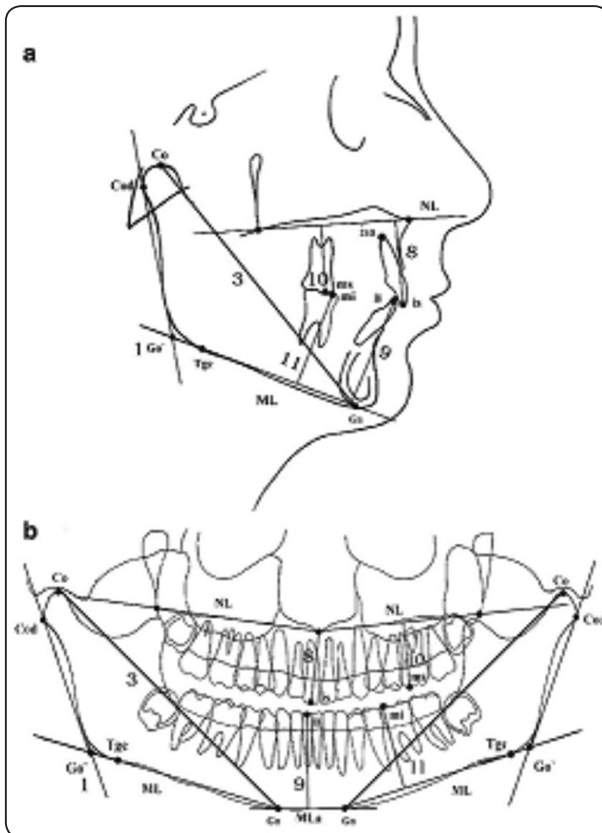


Fig. (3): The assessed dental parameters: (8) is-NL, (9) ii-ML & ii-MLa, (10) ms-NL, (11) mi-ML.

To verify measurement precision, forty radiographs were randomly selected from the groups two weeks later and measured again by the same examiner. Intraclass correlation coefficient was found greater than 80% which indicates the reliability of the data.

### Statistical analysis

The data were parametric and normally distributed. Two-way ANOVA was used to detect possible differences between classes and types of radiographs followed by multiple comparisons (post hoc test) between each 2 groups using the Bonferroni correction if significant differences were noted. The SPSS statistical package for social science version 25 (SPSS Inc., Chicago, IL, USA) was used for data analysis. P is significant if  $< 0.05$  at confidence interval 95%.

### RESULTS

Comparison of all parameters between classes using panoramic radiographs is presented in table 1. There was a significant difference in the assessed parameters between classes for the anterior mandibular height (AHMn), the distance from the incisal edge of the most extruded lower central incisor to the anterior mandibular line (ii-MLa) and the distance from the mesial cusp tip of the mandibular permanent first molar to the mandibular line (mi-ML) only. However, no difference between classes was noted for other parameters ( $p$  value  $< .022$ ). The highest measurements were noted for Class II, followed by class I and the lowest measurements were noted for class III. Multiple comparisons between each 2 classes (Bonferroni test) are presented in the same table. For AHMn, iiMLa and miML, there was a significant difference between class I and class III and between class II and class III, but no difference was detected between class I and class II.

Comparison of different parameters between classes using cephalometric x-ray is presented in table 2. There was a significant difference in parameters between classes for the anterior mandibular height (AHMn), and the distance from the mesial cusp tip of the mandibular permanent first molar to the mandibular line (mi-ML) only. However, no difference between classes was noted for other parameters ( $p$  value  $< .022$ ). The highest measurements were noted for Class II, followed by class I and the lowest measurements were noted for class III. Multiple comparisons between each 2 classes (Bonferroni test) are presented in the same table. For AHMn and mi-ML, there was a significant difference between class I and class III and between class II and class III, while no difference was observed between class I and class II.

Comparison of dentoskeletal parameters between panoramic and cephalometric radiographs for Class I, class II and class III are shown in fig 4, fig. 5 and fig 6, respectively. For all classes, there



was a significant difference between PRs and LCRs for the anterior mandibular height (AHMn) and the distance from the mesial cusp tip of the mandibular permanent first molar to the mandibular line (mi-ML) only ( $p < .05$ ). However, no difference was detected in the other parameters between the two

types of x-rays for all classes. Measurements of panoramic radiographs were significantly higher than cephalometric radiographs for the anterior mandibular height (AHMn) and the distance from the mesial cusp tip of the mandibular permanent first molar to the mandibular line (mi-ML).

TABLE (1): Comparison of parameters between classes using Panoramic radiographs

Parameter	Class I		Class II		Class III		ANOVA p value
	X	SD	X	SD	X	SD	
Gonial Angle (degree)	121.0 <sup>A</sup>	6.2	122.8 <sup>A</sup>	6.6	127.0 <sup>A</sup>	2.5	.21
Inter-jaw Base angle (degree)	20.2 <sup>A</sup>	3.4	20.4 <sup>A</sup>	3.5	21.2 <sup>A</sup>	4.4	.89
Total Mand. Length (mm)	104.9 <sup>A</sup>	8.3	102.0 <sup>A</sup>	11.6	97.0 <sup>A</sup>	4.0	.33
Ant Max height (mm)	16.4 <sup>A</sup>	2.9	18.6 <sup>A</sup>	3.0	16.6 <sup>A</sup>	2.4	.32
Post Max height (mm)	13.3 <sup>A</sup>	2.7	14.6 <sup>A</sup>	2.9	11.9 <sup>A</sup>	1.3	.24
Ant Mand. height (mm)	29.0 <sup>A</sup>	2.9	31.0 <sup>A,B</sup>	2.5	24.5 <sup>C</sup>	1.5	.004*
Post Mand. height (mm)	20.0 <sup>A</sup>	5.2	21.8 <sup>A</sup>	3.3	18.6 <sup>A</sup>	3.4	.38
is-NL (mm)	25.7 <sup>A</sup>	3.2	28.6 <sup>A</sup>	3.9	23.8 <sup>A</sup>	2.3	.079
ii-Mla (mm)	36.6 <sup>A</sup>	3.0	38.9 <sup>A,B</sup>	3.7	32.3 <sup>C</sup>	2.9	.007*
ms-NL (mm)	23.6 <sup>A</sup>	2.7	23.6 <sup>A</sup>	2.9	20.9 <sup>A</sup>	2.1	.15
mi-ML (mm)	32.0 <sup>A</sup>	3.0	30.6 <sup>A,B</sup>	4.3	26.6 <sup>C</sup>	2.4	.021*

\*p is significant at 5%.

Different letters denote significant difference between each two classes

TABLE (2): Comparison of parameters between classes using Cephalometric radiographs

Parameter	Class I		Class II		Class III		ANOVA p value
	X	SD	X	SD	X	SD	
Gonial Angle (degree)	121.6 <sup>A</sup>	5.7	125.0 <sup>A</sup>	6.4	130.4 <sup>A</sup>	3.1	.051
Inter-jaw Base angle (degree)	23.6	3.3	23.6	2.9	22.0	3.9	.72
Total Mand. Length (mm)	101.2	8.4	96.8	9.5	96.2	5.6	.85
Ant Max height (mm)	16.4	2.6	17.2	1.9	15.1	2.0	.42
Post Max height (mm)	12.8	1.8	14.7	3.8	11.6	1.5	.15
Ant Mand. height (mm)	26.6 <sup>A</sup>	4.2	27.0 <sup>A,B</sup>	3.6	22.9 <sup>C</sup>	1.0	.049*
Post Mand. height (mm)	19.1	3.9	19.3	2.4	16.5	2.5	.39
is-NL (mm)	27.0 <sup>A</sup>	2.7	27.2 <sup>A</sup>	3.8	24.7 <sup>A</sup>	2.4	.38
ii-ML (mm)	35.5 <sup>A</sup>	2.5	36.6 <sup>A</sup>	3.6	33.5 <sup>A</sup>	2.2	.27
ms-NL (mm)	22.0 <sup>A</sup>	2.0	22.7 <sup>A</sup>	3.3	19.8 <sup>A</sup>	.8	.16
mi-ML (mm)	27.0 <sup>A</sup>	2.2	28.8 <sup>A,B</sup>	3.3	23.0 <sup>C</sup>	1.5	.022*

\*p is significant at 5%.

Different letters denote significant difference between each two classes

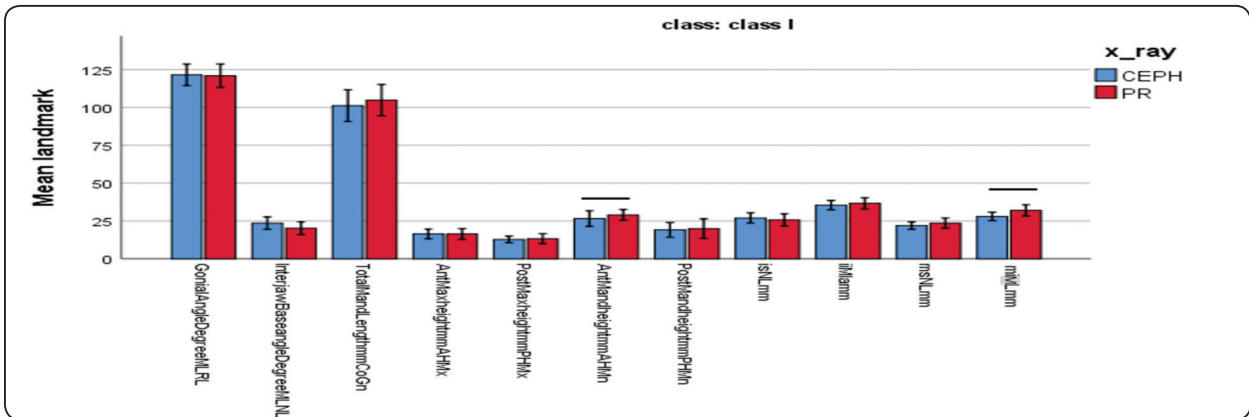


Fig. (4): Comparison of dentoskeletal parameters between PRs and LCRs in class I  
Line connecting bars showed significant difference between X-ray types

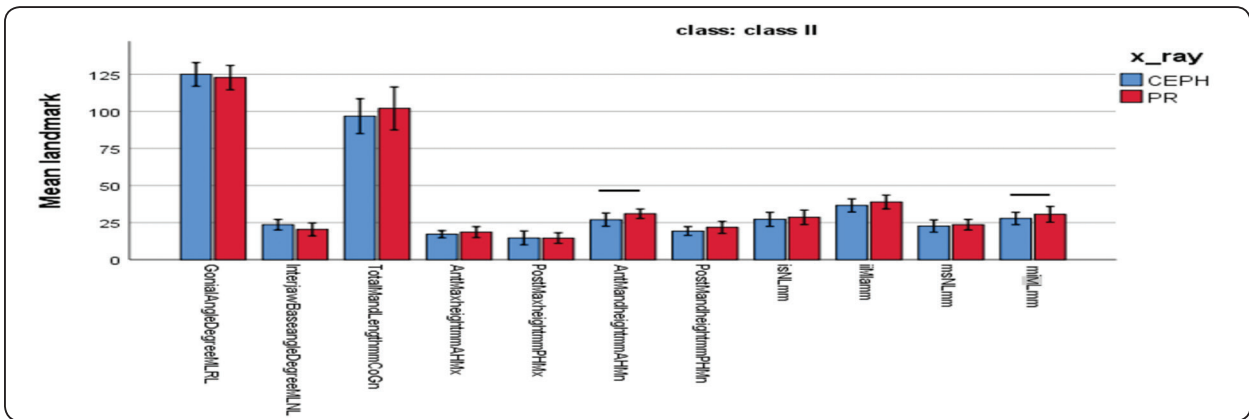


Fig. (5): Comparison of dentoskeletal parameters between PRs and LCRs in class II  
Line connecting bars showed significant difference between X-ray types

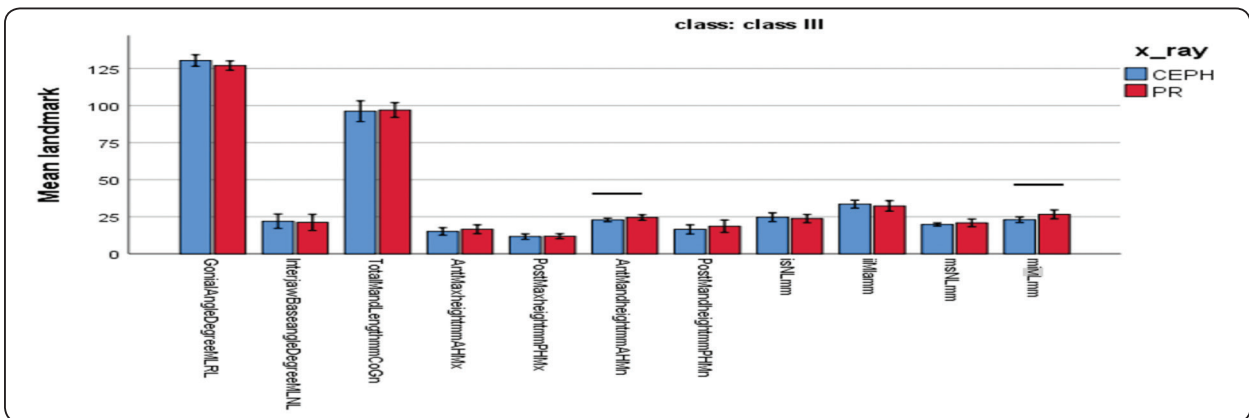


Fig. (6): Comparison of dentoskeletal parameters between PRs and LCRs in class III  
Line connecting bars showed significant difference between X-ray types

## DISCUSSION

Orthodontic diagnosis comprises series of combined clinical expertise that entails substantial information gathering through diagnostic aids like clinical examination and records assessment that are not limited to preliminary casts, clinical photographs but also radiographs.<sup>13</sup>

Cephalometric and panoramic radiographs are routinely taken for orthodontic patients. The cephalometric analysis aim is to determine the vertical and horizontal relationships of the essential functional constituents of the face which are: the cranium and cranial base, the skeletal maxilla and mandible, the dentition and alveolar process. Both vertical and horizontal relationships of these structures affect the treatment plan and outcome.<sup>14</sup> However, in LCRs we are unable to measure the right and left side structures independently as a result of both sides overlapping and superimposed images that appear on lateral cephalograms.<sup>15</sup>

Panoramic x- ray technology is commonly utilized in orthodontic practise to provide substantial data about the number and shape of teeth, their path of eruption, maturation stages, vital structures and surrounding tissues.<sup>16</sup> PRs enable visualization of both sides of the craniofacial structures individually by obtaining an accurate image of the whole dentition and adjacent structures with the least dose of radiation to both patient and operator and in the shortest feasible time.<sup>17</sup>

Previous studies<sup>18,19</sup> have focused on the use of panoramic radiography in evaluating mandibular asymmetries and there is limited data regarding its utilization in assessment of dentoskeletal specifications in different classes. The purpose of this study was to enhance the PR's clinical application by establishing its capability in investigating important angular parameters which are the gonial and Inter-jaw base angles in different classes. In addition, various substantial linear parameters were assessed, which are: total mandibular length, anterior and posterior maxillary heights, anterior and posterior

mandibular heights, distance from the incisal edge of the most extruded upper and lower incisors to the nasal and mandibular line, respectively and the distance from the mesial cusp tip of the maxillary and mandibular permanent first molars to the nasal and mandibular line, respectively. Then, the measurements taken from PR were compared with those recorded from LCR to evaluate its accuracy.

Orthopantomogram provokes inclusive information on the vertical dimensions of the craniofacial structures.<sup>20</sup> In our work, there was a significant difference between groups in the assessed parameters using panoramic radiographs for the anterior mandibular height (AHMn), the distance from the incisal edge of the most extruded lower central incisor to the anterior mandibular line (iiMla), and the distance from the mesial cusp tip of the mandibular permanent first molar to the mandibular line (mi-ML) only. For these three parameters, there were significant differences between class I and class III and between class II and class III, but no difference was detected between class I and class II. The highest measurements were noted for Class II, followed by class I and the lowest measurements were noted for class III. This is in accordance with Nguen and Proffit<sup>11</sup> who stated that excessive lower incisors eruption is associated with most class II malocclusions.

No difference between groups was noted neither for the remaining linear parameters nor for the angular ones. According to Ongkosuwito et al<sup>21</sup>, vertical parameters are more dependable than horizontal ones. Akcam et al<sup>22</sup> suggested that angular measurements are more reliable. The gonial angle is routinely used in orthodontics to assess the mandibular rotation and it represents a considerable indicator in the diagnosis of the patient's growth pattern.<sup>23</sup> Kurt et al<sup>19</sup> utilized panoramic radiographs for evaluating the gonial angle and ramal asymmetry index values to detect mandibular asymmetry in class II patients. They reported that reasonable results can be obtained with OPG.



In the present study, significant difference was detected among classes using cephalometric radiographs in AHMn and miML only. For these two parameters, there were significant differences between class I and class III and between class II and class III, but there was no difference between class I and class II. The highest measurements were noted for Class II, followed by class I and the lowest measurements were noted for class III. Rojo et al<sup>24</sup> reported that class II malocclusion in lateral cephalograms showed higher maxillary height values that may induce downward mandibular rotation, while class III recorded the lowest maxillary height values than other malocclusions which can promote anterior mandibular rotation. In the current work, no difference between classes was noted for other parameters. Akcam et al<sup>22</sup> concluded that lateral cephalogram provides accurate information about the vertical dimensions of the craniofacial structures.

Comparison of the measurements between panoramic and cephalometric radiographs for Class I, class II and class III showed that there was a significant difference between OPGs and LCRs in all classes for AHMn and miML only, while no significant difference was observed for the remaining linear and angular parameters between the two types of radiographs. These findings are in accordance with those of Oksayan et al<sup>25</sup> who concluded that there was no significant differences among class I, II and III groups in the values of gonial angle determined by both PRs and LCRs. Also, Thilagarani et al<sup>26</sup> reported that there was no statistically significant difference in gonial angle between Tweeds mandibular plane on orthopantomogram and on lateral cephalometric x-ray in class I, II and III groups. Sharma et al<sup>27</sup>, similarly, detected a statistically significant correlation for total mandibular length between panoramic and lateral cephalometric radiographs in their studied (normodivergent, hyperdivergent and hypodivergent) groups. The results of the present work are consistent with those of Nohadani and Ruf<sup>28</sup> who revealed that dentoskeletal measurements on lateral cephalogram and orthop-

antomogram showed moderate to high statistically significant interrelationship.

In the current study, measurements of panoramic radiographs were significantly higher than cephalometric radiographs for AHMn and miML. These results are in line with the study of Sharma et al<sup>27</sup> who reported that many parameters in orthopantomogram were slightly higher when compared with cephalometric radiographs.

## CONCLUSION

Orthopantomogram could be considered a reliable alternative for lateral cephalogram for assessment of:

- 1- Skeletal parameters like gonial angle, interjaw base angle and total mandibular length.
- 2- Alveolar parameters like anterior maxillary height, posterior maxillary height and posterior mandibular height.
- 3- Dental parameters such as is-NL, ii-MLa and ms-NL.

## REFERENCES

- 1- Suliman MF, Dawjee SM. The orthopantomograph as an indicator of vertical jaw relations. *South African Dental Journal*. 2018 Nov; 73 (10):597-603.
- 2- Rachmadiani DT, Makes BN, Iskandar HH. The average value of mandible measurements in panoramic radiographs: a comparison of 14–35 and 50–70 year old subjects. *Journal of Physics: Conference Series* 2017 Aug 884 (1):012049.
- 3- Kumar SS, Thailavathy V, Srinivasan D, Loganathan D, Yamini J. Comparison of orthopantomogram and lateral cephalogram for mandibular measurements. *Journal of pharmacy & bioallied sciences*. 2017 Nov; 9 (5):S92-S95.
- 4- Radhakrishnan PD, Varma S, Kovilakam N, Ajith VV. Dilemma of gonial angle measurement: Panoramic radiograph or lateral cephalogram. *Imaging science in dentistry*. 2017 Jun 1; 47 (2):93-7.
- 5- Sharma VK, Tandon P, Singh GK, Yadav K, Singh GP. Evaluation of Skeletal Patterns Using Panoramic Radiography. *Journal of Advanced Research in Dental & Oral Health* 2017; 2 (1&2):1-8.

- 6- Shahabi M, Ramazanzadeh BA, Mokhber N. Comparison between the external gonial angle in panoramic radiographs and lateral cephalograms of adult patients with Class I malocclusion. *Journal of oral science*. 2009; 51 (3):425-9.
- 7- Xiao D, Gao H, Ren Y. Craniofacial morphological characteristics of Chinese adults with normal occlusion and different skeletal divergence. *The European Journal of Orthodontics*. 2010 Sep 13; 33 (2):198-204.
- 8- Tahmina K, Tanaka E, Tanne K. Craniofacial morphology in orthodontically treated patients of Class III malocclusion with stable and unstable treatment outcomes. *American Journal of Orthodontics and Dentofacial Orthopedics*. 2000 Jun 1; 117 (6):681-90.
- 9- Matyn T, Cobourne, Padhraig S, Fleming, Andrew T, Dibise and Sofia Ahmad. *Clinical and Cephalometric analysis*. 1<sup>st</sup> Ed. John Wiley & Sons, Ltd. 2012: 1-27.
- 10- Enikawati M, Soenawan H, Suharsini M, Budihardjo SB, Sutadi H, Rizal MF, Fauziah E, Wahano NA, Indriati IS. Maxillary and mandibular lengths in 10 to 16-year-old children (lateral cephalometry study). *Journal of Physics: Conference Series* 2018 Aug 1073 (2):022015.
- 11- Ngugen T and Proffit W. *The Decision- Making Process in Orthodontics*. Orthodontics current principles and techniques. 6<sup>th</sup> Ed. Elsevier, Inc. 2017: 208-244.
- 12- Nohadani N, Ruf S. Assessment of vertical facial and dental-alveolar changes using panoramic radiography. *The European Journal of Orthodontics*. 2008 Jan 21; 30 (3):262-8.
- 13- Ul Haq MH, Memon S, Agha D. Comparison between three methods of gonial angle formation on lateral cephalogram and orthopantomogram. *Journal of the Pakistan Dental Association* 2018; 27 (2):57-61.
- 14- Sung-Hee Park, Young-Jae Kim, Sang-Hoon Lee, Chong-Chul Kim, Ki-Taeg Jang. The Simple Regression Model of Gonial Angles: Comparison between Panoramic Radiographs and Lateral Cephalograms. *Journal of Korean academy of pediatric dentistry* 2017; 44 (2): 129-137.
- 15- Kumar SS, Thailavathy V, Srinivasan D, Loganathan D, Yamini J. Comparison of orthopantomogram and lateral cephalogram for mandibular measurements. *Journal of pharmacy & bioallied sciences*. 2017 Nov; 9 (5): S92-S95.
- 16- Nejad AM, Jamilian A, Meibodi SE, Hafezi L, Khosravi S, Cappabianca S, et al. Reliability of panoramic radiographs for determination of gonial and Frankfurt mandibular horizontal angles in different skeletal patterns. *Stomatology Edu Journal* 2016; 3:18-22.
- 17- Singh JH, Kenneth T. To investigate the reliability of panoramic radiograph compared to that of a lateral cephalogram for assessing dentoskeletal pattern- In vitro study. *Indian Journal of Dental Sciences* 2010; 2:49-60.
- 18- Ramirez-Yañez GO, Stewart A, Franken E, Campos K. Prevalence of mandibular asymmetries in growing patients. *The European Journal of Orthodontics*. 2010 Aug 19; 33 (3):236-42.
- 19- Kurt G, Uysal T, Sisman Y, Ramoglu SI. Mandibular asymmetry in Class II subdivision malocclusion. *The Angle Orthodontist*. 2008 Jan; 78 (1):32-7.
- 20- Geelen W, Wenzel A, Gotfredsen E, Kruger M, Hansson LG. Reproducibility of cephalometric landmarks on conventional film, hardcopy, and monitor-displayed images obtained by the storage phosphor technique. *The European Journal of Orthodontics*. 1998 Jun 1; 20 (3):331-40.
- 21- Ongkosuwito EM, Deileman MMJ, Jagtman A et al. Linear mandibular measurements: Comparison between orthopantomograms and lateral cephalograms. *Cleft Palate-Craniofacial Journal* Mar 2009; 46 (2).
- 22- Akcam MO, Altioek T, Ozdiler E. Panoramic radiographs: a tool for investigating skeletal pattern. *American Journal of Orthodontics and Dentofacial Orthopedics* 2003; 123 (2): 175-81.
- 23- Xiao D, Gao H, Ren Y. Craniofacial morphological characteristics of Chinese adults with normal occlusion and different skeletal divergence. *The European Journal of Orthodontics*. 2010 Sep 13; 33 (2):198-204.
- 24- Gutiérrez Rojo JF, Padilla GD, Peña IS, Rivas Gutiérrez R. Differences in maxillary height in patients with malocclusion versus patients without malocclusion. *Revista Mexicana de Ortodoncia*. 2014; 2 (3):183-6.
- 25- Okşayan R, Aktan AM, Sökcü O, Haştar E, Ciftci ME. Does the panoramic radiography have the power to identify the gonial angle in orthodontics?. *The Scientific World Journal*. 2012 Nov.
- 26- Nadkerny PV, Kumar DA, Nadkerny VD. Assessing reliability of mandibular planes in determining gonial angle on lateral cephalogram and panoramic radiograph. *Journal of Orthodontic Research*. 2015 Jan 1; 3 (1):45.
- 27- Sharma VK, Tandon P, Singh GK et al. Evaluation of Skeletal Patterns Using Panoramic Radiography. *Journal of Advanced Research in Dental & Oral Health* 2017; 2 (1&2):1-8.
- 28- Nohadani N, Ruf S. Assessment of vertical facial and dental-alveolar changes using panoramic radiography. *The European Journal of Orthodontics*. 2008 Jan 21; 30 (3):262-8.