



## ALGORITHM IN THE MANAGEMENT OF LARGE ODONTOGENIC CYSTIC LESIONS OF THE MANDIBLE

Yasser Nabil\*

### **ABSTRACT**

Odontogenic cystic lesions are among most common diseases affecting maxillofacial region. There are two main lines of treatment for odontogenic cysts, enucleation and marsupialization or a combination of them. Marsupialization has the advantage of being simple procedure with minimal surgical trauma. However it has many disadvantages including limited accessibility for cyst de-roofing and frequent irrigation in certain areas such as mandibular ramus region. The commonest marsupialization techniques uses an acrylic bulb that prevent the marsupialized opening from closure, this technique is extremely difficult or even impossible to use in inaccessible areas, as the ascending ramus of the mandible. It is very difficult for children to maintain the a large marsupialized area cleaned. The present study presents our 3 years follow up of the use of our algorithm in the management of odontogenic cystic lesions, with the use of the marsupialization decompression tube which facilitate flexible hygienic method of decompressing large in accessible odontogenic lesions in adults and children.

**KEY WORDS:** Marsupialization, tube decompression, dentigerous cyst, keratocyst

### **INTRODUCTION**

Odontogenic cysts constitute a major part of the maxillofacial pathology<sup>(1)</sup>.

Developmental and inflammatory odontogenic cysts are epithelial in origin, exhibiting slow growth and a tendency toward expansion. These lesions can reach large size if they are not diagnosed and treated early<sup>(2)</sup> fluid accumulates between the crown and enamel organ of an unerupted tooth<sup>(3)</sup>. These type of cyst usually expands Buccaly<sup>(4)</sup>.

The size of the cyst increases by epithelial proliferation, release of bone resorbing factors and an increase in cyst fluid osmolality<sup>(5)</sup>. The exact histogenesis of dentigerous cyst is unclear It could be inflammatory or developmental in origin <sup>(5,6)</sup>.

Odontogenic keratocysts (OKCs), now known by the World Health Organization as keratocystic odontogenic tumor<sup>(7)</sup>. OKC represents an aggressive form of odontogenic cyst, it have a higher recurrence rate. Although it is considered benign in nature, aggressive treatment of kerato cyst is required<sup>(8,9)</sup>.

\* Associate Professor and Head of Oral and Maxillofacial Surgery, Specialized Dental Teaching Hospital, Cairo, Egypt

The advised treatment protocol included curettage and use of application of Carnoy's solution<sup>(10)</sup> curettage in addition to the application of liquid nitrogen cryotherapy<sup>(11)</sup>, segmental aggressive curettage<sup>(12)</sup> localized segmental resection<sup>(13)</sup>. Other advised more aggressive resection<sup>(13,14)</sup>. Cystic lesions of the jaw can be treated either by enucleation or marsupialization depending on their size, location and proximity to vital structures as teeth, maxillary sinus, nasal cavity and mandibular canal as well as continuity of bone margins<sup>(15)</sup>. Small cysts are enucleated while large cysts are marsupialized initially and then enucleated at later stage<sup>(16)</sup>.

The choice depends on the topography of the cyst as well as the integrity and proximity of adjacent structures. In dentegrouse cysts marsupialization procedure is indicated, mainly to preserve the associated tooth and minimize surgical trauma in pediatric population<sup>(17)</sup>.

Marsupialization, has been used as a more conservative form of treatment for large OKCs to minimize the cyst size and limit the extent of surgery<sup>(18-22)</sup>.

Another important factor is the accessibility of the cystic cavity for surgical intervention and regular irrigation. A new technique (tube decompression procedure) used in this study facilitate surgical deroofting as well as frequent irrigation of inaccessible areas such as mandibular ramus region.

## MATERIALS AND METHODS

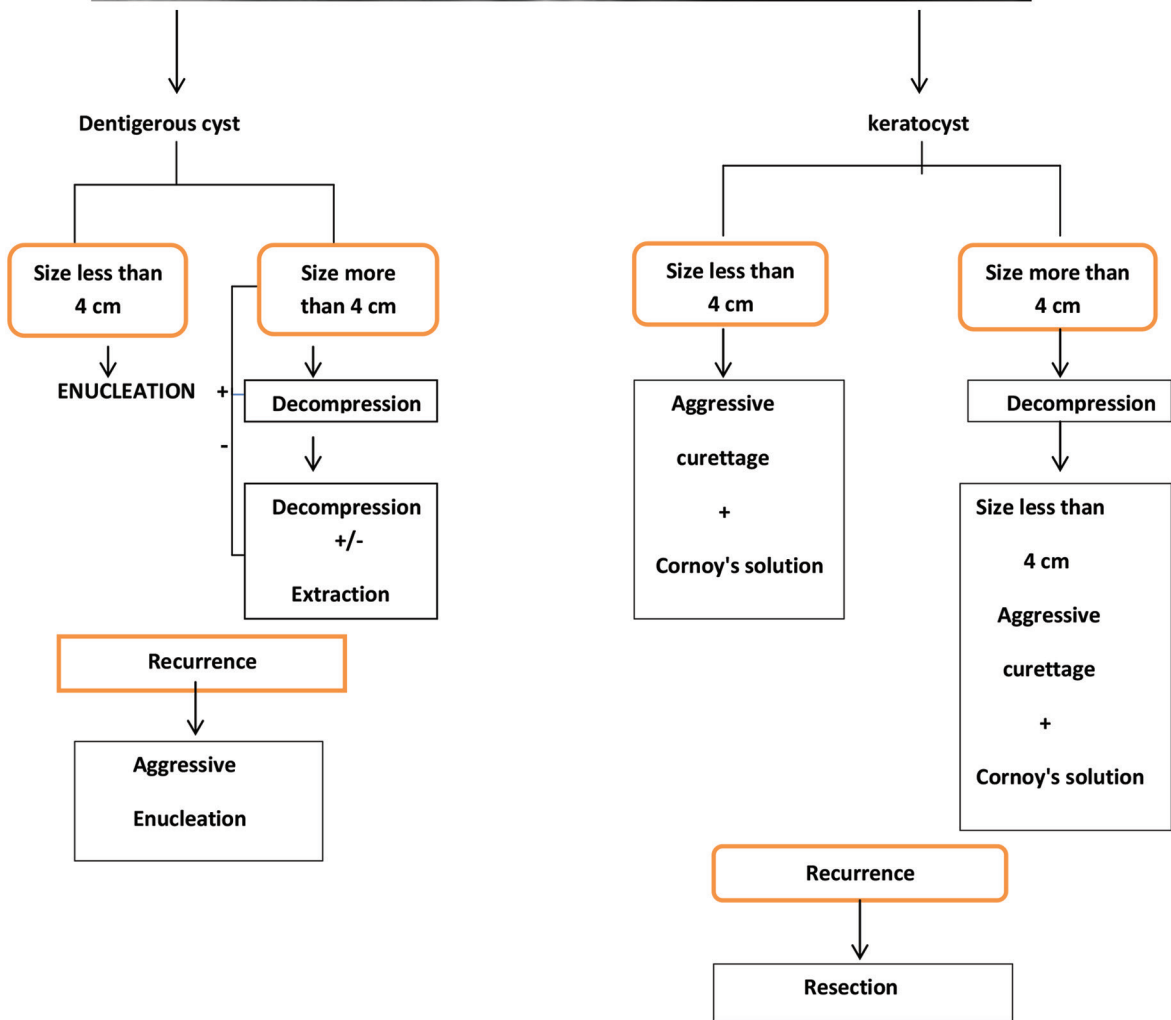
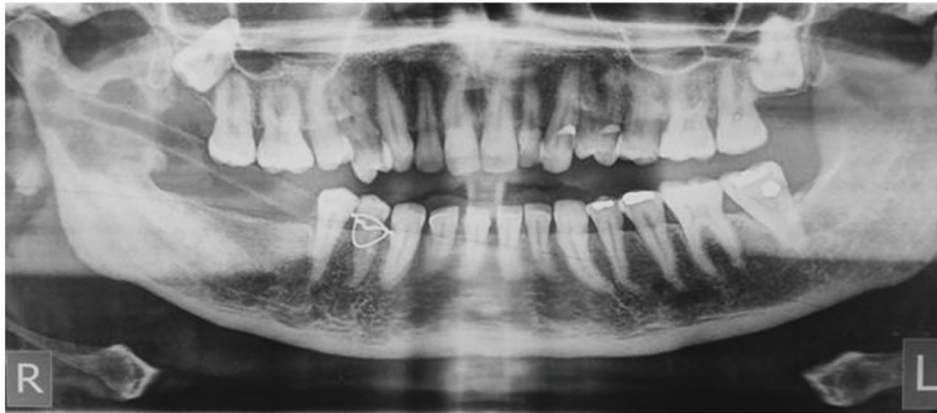This study presents three years follow up of use of our algorithm in management of large odontogenic cystic lesions of the mandible. The study included two groups of patients who attended the oral and maxillofacial department, specialized dental teaching hospital. The first group twenty patients suffering from large mandibular dentegrouse cysts. The other group, twenty patients who had large keratocyst. The female male ratio were equally distributed in both groups. The lesion minimum size

was 4 cm. The mean age ranged from 7-45 years All patients underwent preoperative

Panoramic (OPG) radiography and computed tomography(CT) scanning the size of the lesion. All patients signed an informed consent form before undergoing any procedure included in this study. Histopathology confirmed their diagnosis of dentegrouse or keratocyst. Decompression of the lesions was done through irrigation tube both groups. The algorithm of management was followed Fig. (1). In dentigerous cystic of lesion with lesion size less than 4 cm,enucleation was the treatment of choice. Lesions with average size more than 4 cm will have decompression irrigation tube, with or without extraction of the associated impacted teeth. Lesions that showed recurrence will be aggressively enucleated. In OKC lesions, if the lesion is less than 4 cm, that will be enucleated aggressively, Carnoy's solution will be applied. Lesions more than 4 cm will have irrigation decompression tube, till decrease in size with the application of cornoy's solution. Cases that showed recurrence, marginal resection of the lesion will be carried out.

## Surgical procedure

Endotracheal intubation was performed using Isoflurane orion, Egypt. Profound regional anesthesia with Articaine hydrochloride 4% (3M ESPE, Germany). The cystic lesions were marsupialized by creating a soft tissue opening in the facial aspect of the cystic cavity (about 1cm in diameter, taken as incisional biopsy).The cyst wall was sutured to the oral mucosa. After that a plastic tube catheter was introduced into the depth of the cystic cavity through the soft tissue opening, the distal end of the tube was fixed using stainless wire into adjacent tooth (1). The cystic cavity irrigated with Povidone-iodide solution (The Nile Co. for pharmaceuticals and chemical industries, Cairo, Egypt), and warm 0.9% saline through the plastic tube. The Patient or his parents were instructed to irrigate the tube after each meal and at least three times daily with the same irrigation solutions.



**Follow-up:**

Post-operative medications including mild analgesic and short course of oral antibiotic were prescribed. Patients were instructed to irrigate the cyst cavity through the plastic tube five times daily using 0.9% saline and Povidone-iodide solution. All cases were recalled every two weeks to assure wound condition and adequate irrigation of cystic cavity. All cases were evaluated using digital panorama (OPG), and CT, pre-operatively, 3 & 6 months post-operatively until complete resolution of the lesion and annually for three years Fig2 (a,b,c,d,e) of dentigerous cysts or considerable decrease in the cyst cavity in keratocystic lesions Fig 3(a,b,c,d)

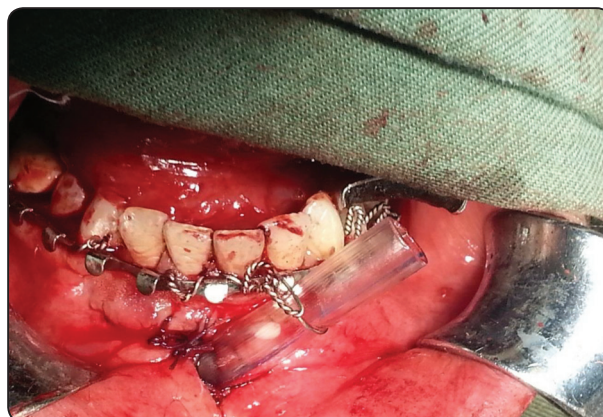

Fig. (1) Intra-operative clinical photograph, the tube introduced inside the cystic cavity through the mucosal opening and fixed to the mandibular arch bar.

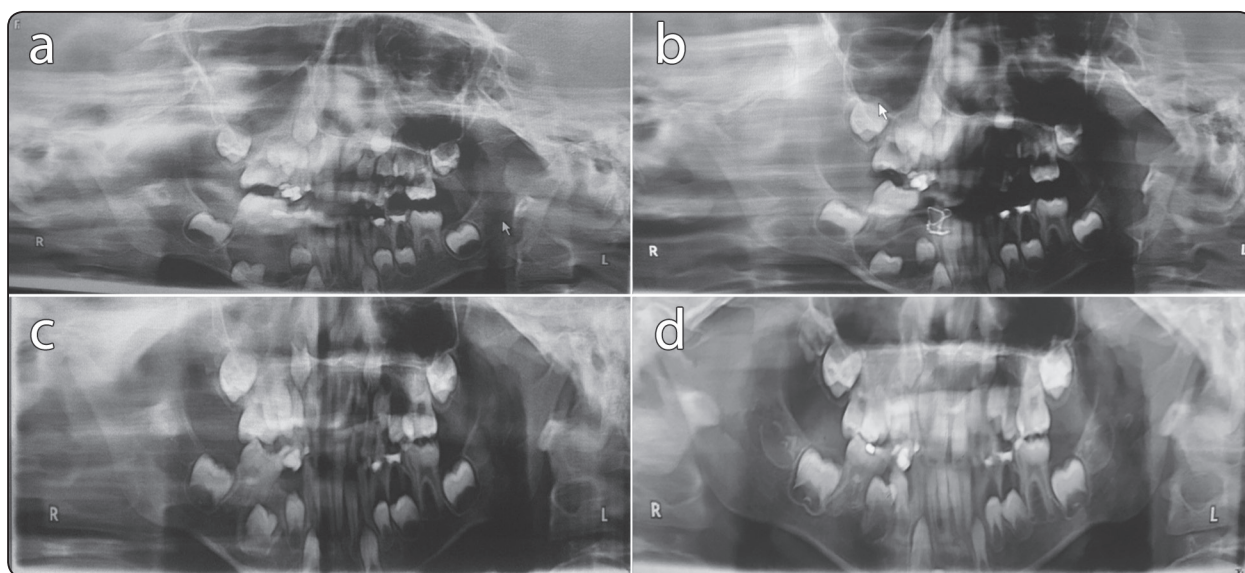


Fig. (2a) OPG panoramic radiograph showing a large dentigerous cyst at the right mandibular area of 8th year boy.

Fig. (2b) OPG panoramic radiograph showing a large dentigerous cyst at the right mandibular area of 8th year boy during 3 months follow up.

Fig. (2c) OPG panoramic radiograph showing a large dentigerous cyst at the right mandibular area of 8th year boy at 6 months follow up.

Fig. (2d) OPG panoramic radiograph showing a large dentigerous cyst at the right mandibular area of 8th year boy at the end of treatment showing eruption of the impacted premolars.

Fig (2 a,b,c,d) OPG panoramic radiograph showing the tube inserted in a large dentigerous cystic cavity occupying the right mandibular body in 8 years old boy and its follow up until complete resolution of the lesion and eruption of the permanent premolars.

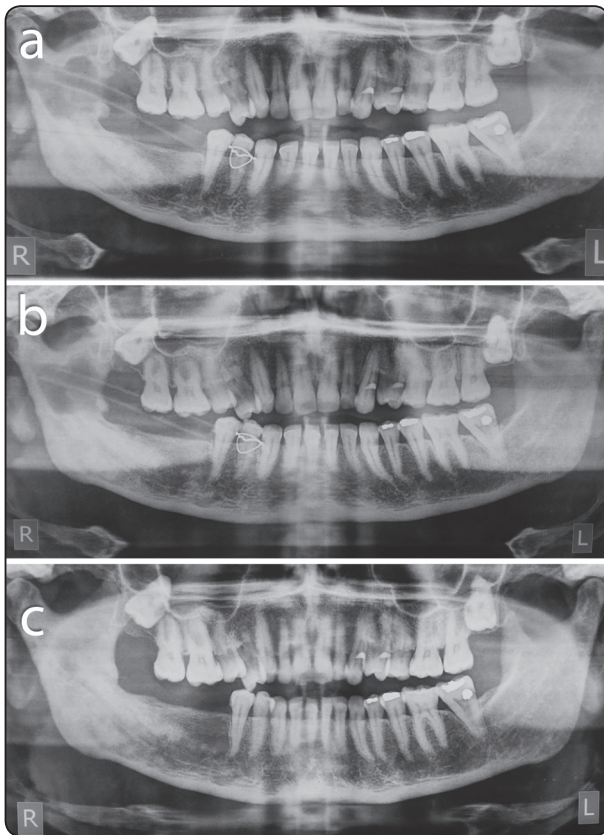


Fig. (3a) Panoramic radiograph showing a large keratocyst cyst at the right ramus area

Fig. (3b) Panoramic radiograph showing a large keratocyst cyst at the right ramus area at three months follow up.

Fig. (3c) Panoramic radiograph showing a large keratocyst cyst at the right ramus area at six months follow up.

Fig. (3a,b,c,) OPG panoramic radiograph showing the tube inserted large keratocystic cavity in the right ramus and its follow up.

## RESULTS

The surgical procedure was well tolerated by all patients. No complications were encountered except accidental tube displacement in two pediatric cases; the tube was reinserted again and fixed. Complete resolution of the cystic lesion was achieved during follow-up period. In all dentigerous cyst cases, in 15 cases the associated impacted teeth were removed during the primary surgery, in 5 cases of

the impacted tooth erupted during follow up. On the other hand although, significant decrease in the cystic cavity of kerato cysts was achieved, all of the cases required second surgery to excise the rest of the lesions.

No change of inferior alveolar nerve was reported. In both groups in the dentigerous cyst group; the associated impacted tooth was preserved in four cases; even erupted in two cases, the other four cases were associated with impacted third molar which have been extracted at the end of treatment. Post-operative radiograph revealed successful new bone formation within the cystic cavity with re-establishment of mandibular outline. In the kerato cyst group similar results were achieved; no nerve affection was noticed in all cases, eruption of the associated impacted teeth was found in six cases. However, no complete resolution of the lesion was found; therefore all the cases in that group required secondary surgery, curettage or segmental resections after the cyst size has decreased Fig (4a,b,c). Significant increases in bone density and a remarkable decrease in the cyst cavity were found 3 months after marsupialization, compared with the preoperative values, indicating that significant bone regeneration had occurred in the cyst site. Bone density measurements of the two groups showed marked increase after 6 month follow up, with comparable values of the lesion after 12 months.

Lesions less than 4 cm in size showed no recurrence in both groups, on the other hand lesions measured more than 4 cm, behaved differently between the two groups, in the dentigerous cyst group no recurrence were found with complete resolution of the lesions. The OKC group recurrence were found in two patients after 12 months, those required aggressive resection of the lesion. There was no difference in the behavior of the lesions between orthokeratinized and parakeratinized lesions.

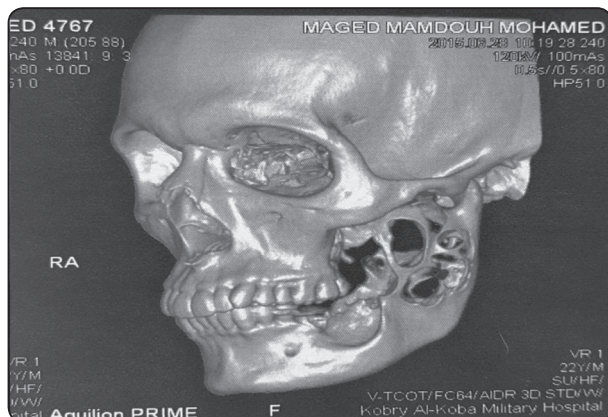


Fig. (4a) Preoperative CT scan of a large aggressive kerato cyst of the ramus and body

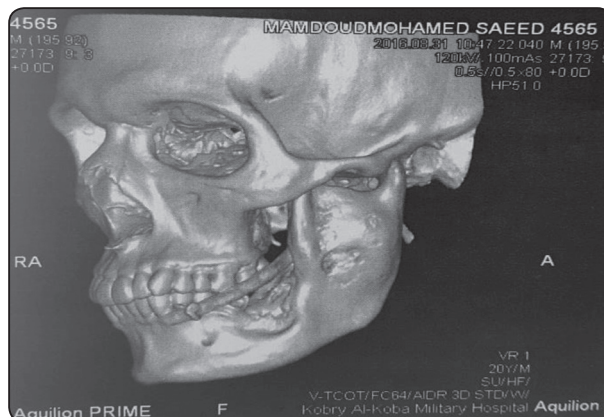


Fig. (4b) Post decompression of the lesion through the irrigation tube, showing the amount of bone formed.

Fig (4a,b) CT Computed tomography showing aggressive Keratocystic lesion preoperatively, and at the end of tube decompression showing the amount of bone formed.

## DISCUSSION

There are two basic surgical procedures, namely marsupialization and enucleation<sup>(23)</sup>. marsupialization procedure and consists of surgically producing a window in the cystic wall to relieve intra-cystic tension<sup>(24)</sup> The technique have the disadvantages that it is a two-stage surgical procedure, pathological tissue is left behind and a more aggressive pathological lesion might arise from it, in a large cystic cavity, it takes a long time to resolute. So, enucleation with primary closure is the treatment of choice<sup>(3,22)</sup>. It could be considered when the cystic cavity is small and there is good bone adjacent to the cyst cavity<sup>(4)</sup>.

Marsupialization is a surgical technique by which a window is produced in the wall of the cyst to relieve the intra-cystic pressure so, enable the cavity to decrease gradually in size. This approach was first introduced by Partsch 1892 and has become known as Partsch I technique.<sup>26</sup> the difference in bone healing mechanism after enucleation and marsupialization is the key to plane treatment strategy for cystic lesion. After cyst enucleation and primary closure bone formed through the cavity with ground glass appearance while after marsupialization the center of the cavity is regenerated by creeping

substitution from the adjacent bone with longer healing time<sup>(27,28)</sup>.

Therefore that if the cystic lesion is inaccessible that primary closure is questionable, marsupialization alone or marsupialization with secondary enucleation is the treatment of choice. In another words primary cyst enucleation with primary closure should be the first treatment option for small accessible lesions<sup>(29)</sup>.

Another factor influence the treatment plane of the odontogenic cyst is the histopathology of the lesion itself, dentegrouse and residual cysts could be managed by marsupialization; while odontogenic keratocyst and unicystic ameloblastoma are not amenable for such technique<sup>(30,31,32)</sup>.

Marsupialization considered is a well-established minimally invasive treatment of large odontogenic cysts. It offers the advantages of preservation of the vital structures, minimal surgical trauma and less risk of pathological fracture; the patient however should be compliant and accepting the prolonged treatment period<sup>(33)</sup>.

The principal of marsupialization is creating an opening in the cyst wall to decrease intra cystic pressure and hence reverse resorptive bone activity, however the maintenance of this opening

requires the use of cyst bulge which need frequent adjustment and not practical especially in pediatric population<sup>(34)</sup>. The tube decompression procedure offers a better tool to keep the cystic cavity patent and facilitates regular irrigation by the patient. The present technique minimizes the disadvantages of marsupialization procedure especially in inaccessible regions and in pediatrics. An impacted tooth is reported to be able to erupt more rapidly if marsupialization therapy is performed at a time when the tooth has the ability to erupt<sup>(35)</sup>

The technique allow partial resolution and decrease in size in the keratocyst so that teeth or the inferior alveolar nerve may be spared<sup>(36)</sup>

Radiographic examinations at regular intervals to observe the progress of bone regeneration of the defect and it also allows pathologic examination of the entire specimen for histopathologic diagnosis.

Radiography is the major nonoperative method for detecting bone formation in a healing osseous wound or defect. Bone formation is radiographically expressed as an increase in radiopacity, resulting in greater optical density of the bone image. To determine the process or progression of bone formation, the radiopacity changes between radiographs should be compared using quantitative analysis and objective evaluation of the radiographic images<sup>(40-42)</sup>.

Cysts can be enucleated safely as early as 3 months after marsupialization. However, if the cyst volume is larger than 80 mL and the cortex is very thin or even absent before marsupialization, secondary enucleation should be delayed for another 1 to 3 months<sup>(43,44)</sup>.

## CONCLUSIONS

The Algorithm provide successful surgical protocol suitable for large odontogenic cystic lesions. The current technique provides simple surgical procedure suitable for inaccessible large cystic lesions such mandibular ramus region,

the use of arch bar and possible tube displacement are the only recorder disadvantages of the technique. Decompression does require a cooperative patient who will irrigate the cyst on a regular basis and will follow up regularly therefore, only a select group of patients may be suitable for this treatment. The denigerous cystic lesion achieved complete resolution, while in the keratocystc lesions it decreased in size only, that required second surgery to excise the lesion.

## REFERENCES

1. M.C.Z. Deboni, M.A. Brozoski, A.A. Traina, R.R. Acay, M.daG. Nacle´rio-Homem, Surgical management of dentigerous cyst and keratocystic odontogenic tumor in children: a conservative approach and 7-year follow-up, *Journal of Applied Oral Science* :2012, 20, 268–271.
2. Y. Ishihara, H. Kamioka, T. Takano-Yamamoto, T. Yamashirod, Patient with nonsyndromic bilateral and multiple impacted teeth and dentigerous cysts, *American Journal of Orthodontics and Dentofacial Orthopedics* :2012, 141, 228–241.
3. A. Tamgadge, S. Tamgadge, D. Bhatt, S. Bhalerao, T. Pereira, M. Padhye, Bilateral dentigerous cyst in a non-syndromic patient: report of an unusual case with review of the literature, *Journal of Oral and Maxillofacial Pathology* :2011, 15:91–95.
4. Y.H. Hu, Y.L. Chang, A. Tsai, Conservative treatment of dentigerous cyst associated with primary teeth, *Oral Surgery, Oral Medicine, Oral Pathology, Oral Radiology and Endodontics* 2011, 112, 5–7.
5. G.Z. Xu, Q. Jiang, C. Yang, C.G. Yu, Z.Y. Zhang, Clinico-pathologic features of dentigerous cysts in the maxillary sinus, *Journal of Craniofacial Surgery* :2012, 23, 226–231.
6. D.S. Pramod, J.N. Shukla, Dentigerous cyst of maxilla in a young child, *National Journal of Maxillofacial Surgery*: 2011, 2,196–199.
7. Philipsen HP: Keratocystic odontogenic tumor, in Barnes L, Eveson JW, Reichart P, et al (eds): *World Health Organization Classification of Tumors*. Lyon, France, IARC Publishing Group, 2005, p 306-307
8. Jensen J, Sindet-Pedersen S, Simonsen EK: A comparative study of treatment of keratocysts by enucleation or enucleation combined with cryotherapy. A preliminary report. *J Craniomaxillofac Surg* :1988,16: 362-365

9. Voorsmit RA, Stoelinga PJ, van Haelst UJ: The management of keratocysts. *J Maxillofac Surg* 9:228, 1981
10. Stoelinga PJ: Long-term follow-up on keratocysts treated according to a defined protocol. *Int J Oral Maxillofac Surg*: 2001, 30:14-25
11. Schmidt BL, Pogrel MA: The use of enucleation and liquid nitrogen cryotherapy in the management of odontogenic keratocysts. *J Oral Maxillofac Surg* :2001, 59:720-725
12. Irvine GH, Bowerman JE: Mandibular keratocysts: Surgical management. *Br J Oral Maxillofac Surg*:1985, 23:204-209
13. Bramley P: The odontogenic keratocyst—an approach to treatment. *Int J Oral Surg*:1974, 3:337-341
14. Bataineh AB, al Qudah M: Treatment of mandibular odontogenic keratocysts. *Oral Surg Oral Med Oral Pathol Oral Radiol Endod*:1998, 86:42-47
15. L.Bodner and Jbar\_Ziv. Dentomaxillofacial Characteristics of bone formation following marsupialization of jaw cysts. *Radiology*: 1998, 27,166-171.
16. Ertas, S., N.Umit, M. Yuvuz & A. Sliem, Interesting irruption of four teeth associated with dentegrouse cyst in the mandible by inlay marsupialization. *J.Oral. Maxillofacial.Surg*: 2003, 61(6):728-730.
17. Killy HC, Kay LW, Seward GR. Benign cystic lesions of the jaw their diagnosis and treatment. 3rd ed. Churchill. Livington. Edinbrugh 1977.
18. Bodner Lipa Cystic lesions of the jaws in children international Journal of Pediatric Otorhinolaryngology, 2002, 62, II 25-29
19. Nakamura N, Mitsuyasu T, Mitsuyasu Y, Higuchi Y, Ohishi M.: Marsupialization for odontogenic keratocysts: Long-term follow-up analysis of the effects and changes in growth characteristics. *Oral Surg Oral Med Oral Pathol Oral Radiol Endod*, 2002, 94:543-553
20. Ninomiya T, Kubota Y, Koji T, Marsupialization inhibits interleukin-1<sub>β</sub> expression and epithelial cell proliferation in odontogenic keratocysts. *J Oral Pathol Med*: 2002, 31:526-528
21. Zhao YF, Wei JX, Wang XP: Treatment of odontogenic keratocysts: A follow-up of 255 Chinese patients. *Oral Surg Oral Med Oral Pathol Oral Radiol Endod* : 2002, 94:151-156
22. Pogrel MA: Decompression and marsupialization as a treatment for the odontogenic keratocysts. *Oral Maxillofac Surg Clin North Am* :2003, 15:415-427
23. R. Scariot, D.J. da Costa, N.L. Rebellato, P.R. Müller, R.C. Gugisch, Treatment of a large dentigerous cyst in a child, *Journal of Dentistry for Children (Chicago)* :2011, 78,111–114.
24. E. Manor, L. Kachko, M.B. Puterman, G. Szabo, L. Bodner, Cystic lesions of the jaws – A clinicopathological study of 322 cases and review of the literature, *International Journal of Medical Sciences* :2012, 9, 20–26.
25. R.R. Kalaskar, A. Tiku, S.G. Damle, Dentigerous cysts of anterior maxilla in a young child: a case report, *Journal of the Indian Society of Pedodontics and Preventive Dentistry* 2007, 25, 187–190.
26. Partsch. Uber Zwei: Fall von odontomen. *Dtsch Mschr Zahnheilk.*:1892, 10:223-233.
27. Bodner L. Effect of decalcified freeze-dried bone allograft on the healing of the jaw defect after cyst enucleation. *J. of oral and maxillofac surg.*, :1996, 54:1282-1286.
28. Anisha.M, Sharma. Y, Chabbaria A. Marsupialization as a treatment option of a large odontogenic keratocyst: A case report with a review of literature. *Peoples Journal of scientific research.* (2011). Vol.(5)1:46-51.
29. Soliman M, Hassan H, Elgazealy H, Swedan T Marsupialization as a treatment modality of large jaw cysts. *World applied sciences journal*.:2013, 12, 1752-1759.
30. Pogrel, MA. & R.C. Jordan marsupialization as a definitive treatment of odontogenic keratocyst. *J oral & maxillofac surg.* :,2004, 62(6):651-655
31. Kolokythas A, Fernands R.P, Pazzoki.A, Ord RA odontogenic keratocyst to decompress or not to decompress a comparative study of decompression Vs resection, peripheral osteotomy. *J oral & maxillofac surg.* :2006, 65(4):640-644.
32. POGRELA and JORDAN R.C.K. Marsupialization as a Definitive Treatment for the Odontogenic Keratocyst *J Oral Maxillofac Surg* 62:651-655, 2004
33. Sakkas, N., R. Schoen, D. Schulze J.E Ohen & R. Schmelzeisen. Obturator after marsupialization of recurrent radicular cyst of the mandible. *Oral surg.Oral med.Oral path.Oral rad. Endod.* :2007, 47, 103, 16-18
34. Kertanya BC, sachder V. singla A, sharma.A.K. (2010) J. Indian. Soc. pedod. prev.dent., 28:203-208. Marsupialization a conservative approach for treating dentegrouse cyst in children in the mixed dentition.
35. Thoma KH. *Oral surgery II*, 5th edition. St Louis: Mosby Co; 1969; p.891-904.



36. Marker P, Brondum N, Clausen PP, et al: Treatment of large odontogenic keratocysts by decompression and later cystectomy long-term follow-up and a histologic study of 23 cases. *Oral Surg Oral Med Oral Pathol Oral Radiol Endod* :1996,82,122-131
37. Maurette PE, Jorge J, de Moraes M: Conservative treatment protocol of odontogenic keratocyst: A preliminary study. *J Oral Maxillofac Surg* :2006, :64:379-383
38. Enislidis G, Fock N, Sulzbacher I, et al: Conservative treatment of large cystic lesions of the mandible: A prospective study of the effect of decompression. *Br J Oral Maxillofac Surg*., 2004,42:546-550
39. Pogrel MA: Treatment of keratocysts: The case for decompression and marsupialization. *J Oral Maxillofac Surg* : 2005,63:1667-1673
40. Nakamura N, Higuchi Y, Tashiro H, Ohishi M: Marsupialization of cystic ameloblastoma: A clinical and histopathologic study of the growth characteristics before and after marsupialization *Journal of Oral and Maxillofacial Surgery*, 1995, 53, 7, 748-754
41. Zhao YF, Wei JX, Wang XP: Treatment of odontogenic keratocysts: A follow-up of 255 Chinese patients. *Oral Surg Oral Med Oral Pathol Oral Radiol Endod* : 2002,94:151-156
42. Chiapasco M, Rossi A, Motta JJ, et al: Spontaneous bone regeneration after enucleation of large mandibular cysts: A radiological computed analysis of 27 consecutive cases. *J Oral Maxillofac Surg*: 2000,58,942-948
43. Chi A, and Neville B: *Odontogenic Cysts and Tumors Surgical Pathology Clinics*, 2011, 4, 1027-1091
44. Zhao Yi, Liu B, Han Qi-Bing, Wang Shi-Ping Changes in Bone Density and Cyst Volume After Marsupialization of Mandibular Odontogenic Keratocysts (Keratocystic Odontogenic Tumors) *J Oral Maxillofac Surg*:2011, 69:1361-1366