

## **BONE REGENERATION POTENTIAL OF BETA TRI-CALCIUM PHOSPHATE AND PLATELET RICH FIBRIN IN LOCALIZED ALVEOLAR RIDGE DEFECT WITH IMMEDIATELY PLACED DENTAL IMPLANT. (AN EXPERIMENTAL STUDY IN DOG)**

Abeer Kamal\*, Reham AA Morsy \*\* and Eman K \*\*\*

### **ABSTRACT**

**Background:** Augmentation of localized alveolar bone defect is one of major problems in implant dentistry. Beta tri-calcium phosphate ( $\beta$ -TCP) is considered a source of synthetic bone substitute for bone regeneration. If it is combined with platelet rich fibrin (PRF) with immediately placed dental implant it may encounter a promising result for bone formation.

**Objective:** The aim of the present study was to compare the regenerative bone potential around immediately placed dental implant in localized alveolar bony defect by the use of  $\beta$ -TCP alone or in combination with PRF.

**Materials and Methods:** Eight clinically healthy dogs were included in this study. Localized alveolar bone defect was created after extraction of the second mandibular premolar bilaterally. After immediate implants were inserted the defect was augmented with following: Group I:  $\beta$ -TCP. Group II:  $\beta$ -TCP with PRF. Group III: Control group without adding any material.

After 12 weeks, the animals were sacrificed and bone regeneration in the created defect was evaluated through histological examination, immunohistochemically and histomorphometric analysis.

**Results:** Groups analysis demonstrated signs of bone regeneration with variable degrees. Histomorphometrically, the control group revealed the lowest mean area percentage. Group I:  $\beta$ -TCP and group II:  $\beta$ -TCP combined with PRF showed the highest mean area percentage and both were significantly higher than control group. However, no significant difference observed between group I and II. The results were supported by both histological and immunohistochemical analysis. The signs of bone maturation in group I & group II were more than control group.

\* Associate Professor of Oral and Maxillofacial Surgery, College of Oral and Dental Surgery, Misr University for Science and Technology (MUST), Egypt.

\*\* Associate Professor of Oral Pathology. Basic Dental Science Department, Oral and Dental Medicine Research Division, NRC. Egypt.

\*\*\* Lecturer of Oral Medicine, Periodontology, and Oral Diagnosis, Faculty of Dentistry, British University in Cairo (BUE), Egypt.

**Conclusion:** Beta tri-calcium phosphate with platelet rich fibrin is a promising osteogenic bone substitute with high bone regenerative potential. It could be used as an alternative method for bone regeneration around dental implant in localized alveolar bone defect.

**KEYWORDS:** Beta tri-calcium phosphate  $\beta$ -TCP - Bone regeneration - Platelet rich fibrin PRF – Dental implant.

## INTRODUCTION

Ridge augmentation of localized alveolar bone defect resulting from prolonged time after teeth loss without replacement, ageing process, trauma, ablative surgery or pathology, remains a clinical challenge for implant placement. This leads to surgical and anatomical limitations. Autogenous bone was considered the best material for augmentation for large defects<sup>(1-3)</sup>. The morbidity associated with harvesting bone could be a limiting factor. Allogeneic, xenogeneic and alloplastic bone substitutes were used as an alternative material for reconstruction. The main reasons for failure to restore alveolar defect and replacement the missing teeth with implant are poor bone augmentation and graft shrinkage. Lack of adequate bone callus formation is generally caused by graft instability, exposure of graft material and infection.<sup>(4-10)</sup>

Platelet rich fibrin PRF is fibrin mesh enriched with platelets and growth factors as, transforming growth factor b1, platelet-derived growth factor, and vascular endothelial growth factor. It has a complex architecture of strong fibrin matrix with favorable mechanical properties that no other platelet concentrate can offer<sup>(11)</sup>. The fibrin is a bridging molecule that allows a series of cell interactions and supplies a provisional matrix for cell proliferation and organization, at the site of injury or inflammation<sup>(12)</sup>. It has been reported that PRF is a healing biomaterial with a great potential for bone and soft tissue regeneration. The inherent osteoconductive and/or osteoinductive property of PRF is beneficial for bone regeneration.<sup>(13,14)</sup>

It has been advocated that PRF in the form of graft material or guided tissue regeneration membrane can be used alone or in combination with bone substitutes. It increases the regenerative

effects of bony defects, promoting hemostasis, bone growth, and maturation. The best result for filling of bony defect could be achieved with a combination of bone graft and guided tissue regeneration.<sup>(14-16)</sup> PRF when used as guided tissue regeneration creates an improved space and facilitates cell migration that is favorable for bony regeneration.<sup>(17-19)</sup> PRF as a grafting material helps in wound healing, protects the surgical site and promote soft tissue repair. Combination of (PRF) with bone graft act as a biological connector that attracts stem cell and favors migration of osteoprogenitor cells to the center of the graft. It enhances revascularization of the graft by supporting angiogenesis<sup>(20,21)</sup>.

Beta tri-calcium phosphate  $\beta$ -TCP is the most commonly used type of porous form of calcium phosphate. It is used as partially resorbable filler. It allows bone formation and replacement<sup>(22-23)</sup>.  $\beta$ -TCP has gained high acceptance as a bone filler material. It is biocompatible and osteoconductive bone substitute. It leads to bone apposition in the areas contacting with the material. Some studies have been reported that there is bone deposition with  $\beta$ -TCP in human periodontal osseous defects<sup>(24-27)</sup>. Vertical and horizontal ridge augmentation using  $\beta$ -TCP has been evaluated in animal and clinical studies with variable results<sup>(28-30)</sup>.

The aim of the present research was designed to assess regenerative bone potential of beta tri-calcium phosphate alone or in combination with platelet rich fibrin in localized alveolar ridge defect with immediately placed dental implant in an experimental animal. Assessment was achieved through histological examination, immunohistochemistry and histomorphometric analysis.

## MATERIAL AND METHODS

Eight clinically healthy mongrel dogs (1- 2 years-old, weighting 8 to 10kg) were used in the current study. All procedures were performed according to the guidelines for the experimental research ethics committee of the animal house, Faculty of Medicine, Cairo University. Each animal was checked and supervised by the veterinarian.

The following materials were utilized in the current study; dental implants (Super Line Dentium Implant System. Dentium Co., Ltd. Seoul, Korea) and Beta tri-calcium phosphate (Guidor ® easy graft ® classic. Alloplastic bone grafting granules system. Switzerland)

The 8 dogs (16 mandibular side right and left) were classified into 3 groups, group I and II contained 3 animals in each while group III included 2 dogs and considered as control group. Each animal were subjected to surgical procedure for extraction of the second premolar with its two roots bilaterally. A localized class III alveolar bone defects were created using by the use of a predetermined size surgical template. Immediately placed two dental implants were inserted one in each root of the extracted premolar teeth bilaterally. The exposed threads of the dental implant were augmented by the following;

**Group I (6 sides):** Beta tri-calcium phosphate

**Group II (6 sides):** Beta tri-calcium phosphate in combination with platelet rich fibrin PRF. The PRF was prepared according the technique described by Lekovic <sup>(14)</sup> (Fig. 1).

**Group III (4 sides):** Control group the defect site was left uncovered without any augmentation material.

Surgical procedures were carried out under aseptic conditions and general anesthesia. The animals were premedicated with Ketamine (Ketamine HCL injection USP, Rotexmedica,

Germany) and Xylazine (Rompun. Bayer AG, Leverkusen. Germany). Anesthetization of the animal was performed by using pentobarbital sodium (1 mg/100 gml). The perioral tissues and gingiva were disinfected with antiseptic solution (Betadine 10% - SOL The Nile Co. for Pharmaceuticals and Chemical Industries - A.R.E).

Gingival incision was performed and full thickness flap was elevated at mandibular premolar area bilaterally. Extraction of second premolar was done and localized defects in the alveolar ridge (vertically and horizontally) were performed using surgical bur. The alveolar ridge was reduced in horizontal and vertical dimension to create class III alveolar bone defect. (10 mm mesio-distally, 3-5 mm coronal–apically and 3-5 mm bucco-lingually) <sup>(31-32)</sup>. To ensure the unification of the size of alveolar bone defect a surgical sterile template previously made were used with accurately predetermined size. Implant site were prepared bilaterally. The procedures were performed under copious irrigation with sterile saline solution (0.9% NaCl 500 ml. Egypt Otsuka Pharmaceutical Co., S.A.E. - A.R.E) and the two implants (were inserted one in each root with good primary stability (3.4 mm in diameter and 10 mm in length). The exposed threads of the implants were covered by either;

**Group I:** Beta tri-calcium phosphate

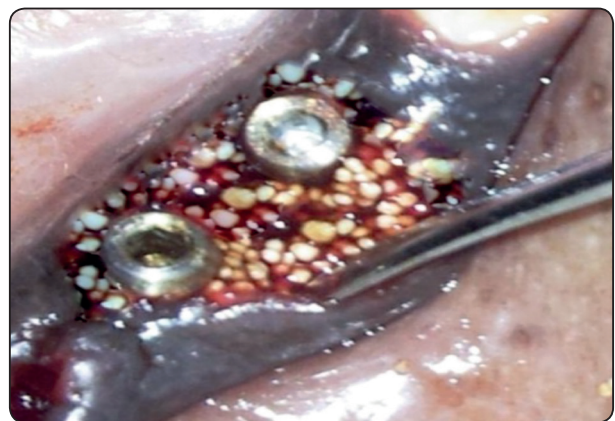

Fig. (1) Exposed threads covered by  $\beta$ -TCP with  $\beta$ -TCP and PRF

**Group II:** Beta tri-calcium phosphate in combination with platelet rich fibrin PRF.

**Group III:** ( Control group) the defect site was left without augmentation.

The flaps were replaced and sutured with 3-0 Vicryl sutures material (polyglaction 910 ethicon) using interrupted suture technique.

The following drugs were prescribed postoperatively: Crystalline penicillin (Misr Co. for pharm. Ind. Cairo. Egypt). I.M injection every 12 hour for 5 days and Ketoprofen (Ketofan 100mg.) ampoule I.M injection per day for 3 days.

Twelve weeks later, the animals were sacrificed for sample preparation. Assessments of the results of bone formation were performed through histologic section, immunohistochemistry and histomorphometric analysis.

#### **Specimens' preparation for histological examination**

After preparation of harvested bone blocks accompanied with implants, the specimens were fixed in 10% buffered natural formaldehyde for 24 hours. The samples were kept in separate coded dishes containing 10% ethylene diamine tetra acetic acid (EDTA) for 8 weeks. As decalcification is completed, the specimens were washed in running water to remove all traces of EDTA and prepared in a paraffin block. The specimens were cut parallel to the long axis of implant that serial sections could be performed and representing most of the induced defective area.

#### **Immunohistochemical analysis**

Immunohistochemical staining was performed on 4 $\mu$ m paraffin embedded sections which were deparaffinized, dehydrated and treated with H<sub>2</sub> O<sub>2</sub> in 0.3% for 30min to block endogenous peroxidase activity. For antigen retrieval, AR solution was used (code no. S3308 Dako), & heated in microwave oven at 100° C for 15 min. The slides were incubated

with anti-Osteopontin antibody (Dako Cytomation, Denmark) in dilution range 1:100 overnight at room temperature in a humidified chamber. After washing with PBS, the slides were treated with biotin labeled link antibody, then the streptavidin conjugated to horseradish peroxidase was used. DAB chromogen was applied to visualize Antigen-Antibody reaction (code no.K0673 Dako Cytomation, Denmark). The ordinary light microscope was used to detect and localized the positive osteopontin cytoplasmic or membranous immunostaining.

#### **Quantitative Histomorphometric image analysis**

The area percent of newly formed bone was estimated using Leica Quin 500 analyzer computer system, (Leica Microsystems, Switzerland). Oral Pathology Department. Faculty of Oral and Dental Medicine. Cairo University. The cursor was used to outline the areas of newly formed bone trabeculae, which were then masked by a binary color that could be measured by the computer. The image analyzer is calibrated automatically to convert the measurement units (pixels) produced by the image analyzer program into actual micrometer units. The area percent of newly-formed bone was estimated in 8 different fields in each group using magnification (X100). Mean values and standard deviation (SD) were calculated for each group. Analysis of variance (ANOVA) test was used for statistical analysis of the difference between groups. Tukey's post hoc test as well as ANOVA test was performed to reveal any significant difference. Unpaired t test was used for pairwise comparisons. P value  $\leq$  0.05 was considered statistically significant.

## **RESULTS**

### **Histological findings:**

Group I augmented with beta tri-calcium phosphate alone, revealed residual layer of granulation tissue with mild inflammatory response could be seen in contact with the newly formed



woven bone which was thinner, less dense and less mature than in group II augmented with  $\beta$ -TCP in combination with PRF. Moderate bone remodeling was detected in the form of in-growing areas of lamellar bone in close proximity to the woven bone with less detected and unevenly arranged marrow spaces. The number of bone forming cells entrapped in bone trabeculae was little. The newly formed bone and the number of bone forming cells were higher in this group compared to the control group but less than group II (Fig. 2).

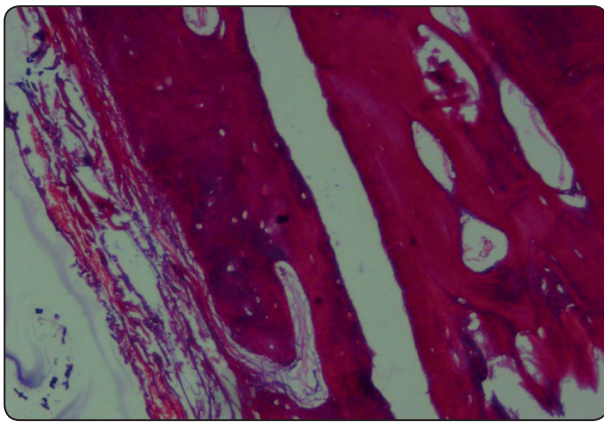


Fig. (2) Photomicrograph of group I ( $\beta$ -TCP) showing newly formed osteoid bone trabeculae replacing the granulation tissue with more entrapped osteocytes and irregularly arranged marrow spaces (H&E X100).

Group II augmented with  $\beta$ -TCP and PRF nearly all the granulation tissue was replaced by both woven & lamellar bone that had filled most of the space of the defect. Bone remodeling was extensive with clearly detected and regularly arranged marrow spaces. The newly formed bone was thicker, denser and more mature than that of control group. Osteocytes were detected entrapped inside the formed bone trabeculae. No evidence of inflammatory reaction or fibrosis. The newly formed bone and the number of bone forming cells were greater in this group compared to the control group (Fig. 3).

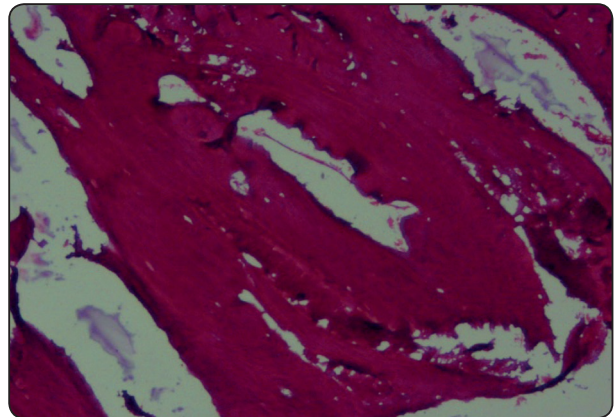


Fig. (3) Photomicrograph of group II ( $\beta$ -TCP with PRF) showing thick, dense and mature newly formed osteoid bone and increasing number of osteocytes entrapped inside trabeculae. Note, there is no inflammatory reaction or fibrosis. (H&E X100).

Control group III revealed condensed collagen fibers with little fibroblast, inflammatory cells in collagen-rich CT matrix suggesting granulation tissue. Mild bone remodeling could be detected at the expense of granulation tissue in the form of multiple small ectopic foci of osteoid bone formation with limited number of bone forming cells. (Fig. 4).

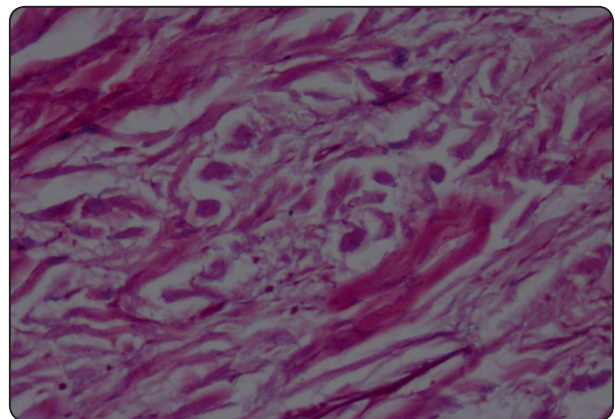


Fig. (4) Photomicrograph of group III (control) showing condensation of granulation tissue with ectopic bone formation within the granulation tissue & few inflammatory cells (H&E X100).

### Immunohistochemical Findings

Immunohistochemical examination revealed widespread positive immunostaining of osteopontin antibody in the bone forming cells (osteocyte lacunae) entrapped in the osteoid tissue and endothelial cells lining the blood vessels. Bone matrix was devoid of immunostaining; also some accentuated cemental lines of bone trabeculae showed mild immunostaining for OPN. In addition, the immunostaining for OPN was greater in group II than group I and control group (Fig. 5 and 6)

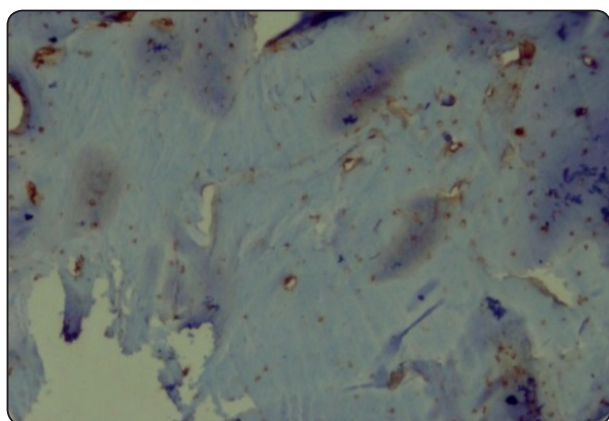


Fig. (5) Photomicrograph of group II (β-TCP with PRF) showing prevalent positive immunostaining in the osteocyte lacunae. Note, positive immunostaining lining of some blood vessels and negative immunostaining in the bone matrix (anti-OPN antibody X100).

### Histomorphometric image analysis Results

The greatest mean area percent of newly formed bone was recorded in group II augmented with β-TCP and PRF (41.041 %), whereas the least mean value was recorded (22.03 %) in Group III (control). ANOVA test revealed an increase in the mean area of bone percentage in group I and II when compared with control group and this increase was statistically significant with P value (0.0201 and 0.0004) respectively. On comparison of group I with group II it has been detected that there was no statistically significant difference. (Table 1. Fig. 7)

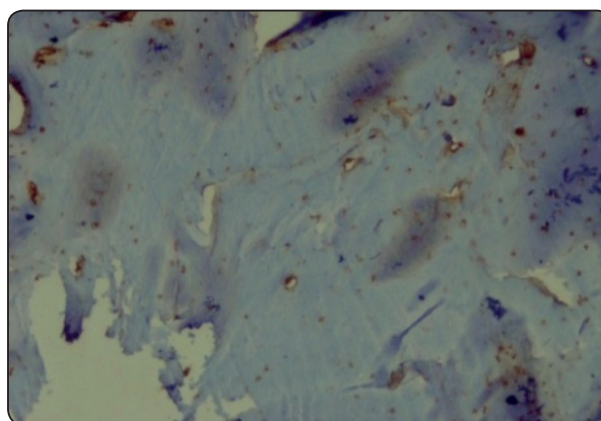


Fig. (6) Photomicrograph of group I (β-TCP) showing positive immunostaining in the dispersed osteocyte lacunae. Note negative immunostaining in the bone matrix (anti-OPN antibody X100).

TABLE (1) Mean area percent of newly formed bone and significance of difference between groups

	Mean of area % of bone	SD	P value
Gp I (β-TCP)	37.85 %	13.05	0.6103
Gp II (β-TCP with PRF)	41.041 %	7.19	
Gp I (β-TCP)	37.85 %	13.05	<b>0.0201*</b>
Gp III (control)	22.03 %	5.15	
Gp II (β-TCP with PRF)	41.041 %	7.19	<b>0.0004*</b>
Gp III (Control)	22.03 %	5.15	

\*significant

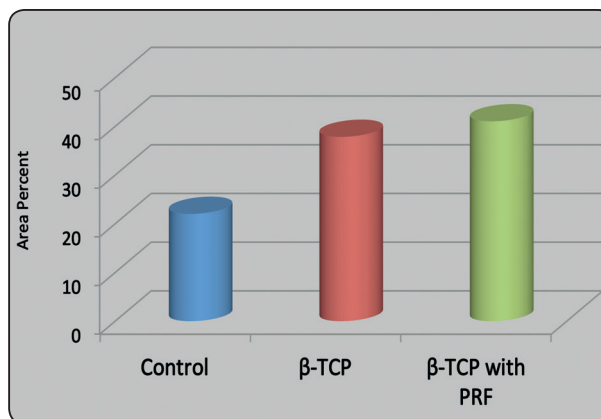


Fig. (7) mean of area percent of newly formed bone in all groups

## DISCUSSION

Regeneration of defective alveolar bone ruined by periodontal diseases, tumor resection or traumatic injury represents a major problem in oral and maxillofacial surgery. Severe vertical and horizontal alveolar bone resorption is a limiting factor to support dental implant. Review of literature revealed that Beta tri-calcium phosphate ( $\beta$ -TCP) as synthetic bone substitute combined with platelet rich fibrin (PRF) as an autogenous graft improve bone regeneration. In the present study placement of immediate dental implant in localized alveolar bone defect add a promising alternative method for vertical support of the combined graft material to enhance bone generation in such defects. It was hoped to achieve significant bone volume to support the dental implant for better esthetic and functional replacement.

Beta tri-calcium phosphate is an alloplastic ceramic synthetic bone material used extensively in the past. It was used in the present study being bioactive (inducing specific biologic reactions) and biocompatible (not stimulating inflammatory or foreign-body giant cell activity). It is composed of Ca and P ions, the main component of bone<sup>(33-35)</sup>. It contains faster resorbing material creating many pores to ensure migration of the newly formed growing bony tissue into the defect. This idea is supported by the study of LeGeros<sup>(36)</sup>, Metsger et al<sup>(37)</sup> and Trisi et al<sup>(38)</sup>.

In the current research platelet rich fibrin PRF was selected being preferred over platelet rich plasma PRP. PRF does not contain any synthetic or anticoagulant materials; it is cheaper with shorter production time and provides a scaffold for attraction of tissue cells to the injured site. The higher concentration of platelet contained in the fibrin matrix allow slow release of its contents (growth factors and cytokines) and prevents them from undergoing proteolysis and enhance the regenerative potential of the bone. This opinion is in agreement with many authors.<sup>(39-41)</sup>

In the present study dental implant has been used in the created localized alveolar bone defect (Class III defect). This was planned to provide vertical and horizontal support and preservation of graft material. The core of the dental implant supports the graft material vertically while the threads support the material horizontally.

Histomorphometric analysis with its degree of objectivity, accuracy, reproducibility and suitability for statistical analysis was used in the present research for evaluation of bone regeneration potential through assessment of percentage of bone along the induced surgical defect. This opinion is supported by Pastoureau et al<sup>(42)</sup>. Immunohistochemistry was used with Osteopontin (OPN) as a marker for evaluation of new bone formation. OPN is detected in both osteoclasts and osteoblasts and has been implicated as an important factor in bone remodeling as reported by Gul Gursoy et al<sup>(43)</sup>. It helps the migration of osteoblasts to intercellular matrix and mediates attachment of both osteoblasts and osteoclasts to bone mineral through interaction with integrin. OPN is intimately implicated in the regulation of both physiological and pathological mineralization. It is associated with cellular regeneration and tissue repair.

The animal model used in this study has represented an effective sample for assessing the regeneration of bone and suitable for examining bone formation because it is a simple method, reproducible and it is easy to be accessible to produce an experimental defect. The mongrel dogs wound healing kinetics and anatomy of the tooth bear a resemblance to that of the humans. Moreover, the surgical creation of uniform alveolar bone defects and reconstruction of such deficiencies in dogs is a commonly used procedure to evaluate bone regeneration adjacent to titanium implants. This procedure is in agreement with Barboza et al<sup>(31)</sup> and Seibert<sup>(32)</sup>.

In the present study, the three groups showed signs of bone regeneration at the defective side



of alveolar bone with variable degrees. Bone regeneration was minimally and non-significant in control group. The immunohistochemical finding for OPN and histomorphometric analysis support the histological results. The results of this research were in accordance with the study of Shalash et al<sup>(28)</sup> Yilmaz et al<sup>(44)</sup>, and Triveni et al<sup>(45)</sup>. The graft material can act as scaffold for the growth of cellular and vascular components to be replaced by new bone of acceptable quality and quantity within a healing period.

In the current research group I and II showed newly formed osteoid tissue with increasing number of osteocytes. Presence of such cells indicates formation of bony tissue in the defective area. In contrast to control group, granulation tissue with ectopic bone formation was observed. It was supposed that, beta tricalcium phosphate granules works only by osteoconduction and guiding osteogenic cells from existing bone. These cells differentiate into osteoblasts to form bone. This finding is in agreement with those results of Stahl et al<sup>(34)</sup> and MG Triveni et al<sup>(45)</sup>.

Group II treated by  $\beta$ -TCP combined with PRF exhibited signs of bone maturation more than the other two groups. All the granulation tissue was replaced by woven & lamellar bone and filled the space surrounding the implant. This finding was supported with the finding of other studies<sup>(44, 46, 47)</sup>. The addition of PRF to synthetic bony particles increase beta-tri-calcium phosphate transformation into bony tissue, reduce the time required to promote graft consolidation, maturation, and improve the density of trabecular bone. The combined use of both PRF and  $\beta$ -TCP accelerate healing processes by the synergic effect of the inherent regenerative potential of PRF and the osteoconductive property of  $\beta$ -TCP.

Increasing number of osteocytes was observed in Group II more than group I indicated bone regeneration potential in that group. PRF acts as a biologic adhesive to hold the particles together,

making manipulation of the bone grafting material much easier. PRF accelerates the healing effect by keeping the particles of  $\beta$ -TCP together via its adhesive property and adapting them tightly in the defective alveolar bone area.

## CONCLUSION

Beta-tri-calcium phosphate as an alloplastic bone substitute is effective material in alveolar ridge augmentation. PRF can enhance the reparative bony potential of  $\beta$ -TCP. Dental implants can support the combined material when placed in class III localized alveolar bone defect. This combination needs further wide scale explorations.

## CONFLICTS OF INTEREST

There are no conflicts of interest.

## REFERENCES

- 1- Corbella S, Taschieri S, Weinstein R & Del Fabbro M : Histomorphometric outcomes after lateral sinus floor elevation procedure: a systematic review of the literature and meta-analysis. *Clin Oral Implants Res* 2016;27; 1106-22\_
- 2- Fretwurst T, Gad LM, Nelson K & Schmelzeisen R: Dent-toalveolar reconstruction. *Modern approaches. Curr Opin Otolaryngol Head Neck Surg* 2015; 23; 316–22
- 3- Götz C, Warnke PH, & Kolk A: Current and future options of regeneration methods and reconstructive surgery of the facial skeleton. *Oral Surg Oral Med Oral Pathol Oral Radiol* 2015;120; 315–23.
- 4- Rocchietta I, Fontana F& Simion M: Clinical outcomes of vertical bone augmentation to enable dental implant placement: A systematic review. *J Clin Periodontol.* 2008; 35; 203–15.
- 5- Goto T: Osseointegration and dental implants. *Clin Calcium* 2014; 24; 265–71.
- 6- Zeeshan Sheikh, Corneliu Sima & Michael Glogauer: Bone Replacement Materials and Techniques Used for Achieving Vertical Alveolar Bone Augmentation. *Materials* 2015; 8; 2953-2993
- 7- Tonetti MS, & Hammerle CH: Advances in bone augmentation to enable dental implant placement: Consensus



- report of the sixth European workshop on periodontology. *J Clin Periodontol.* 2008; 35; 168–72.
- 8- Tevlin R, McArdle A, Atashroo D, Walmsley GG, Senarath-Yapa, K, Zielins ER., Paik KJ, Longaker MT, & Wan DC: Biomaterials for craniofacial bone engineering. *J Dent Res.* 2014, 93, 1187–95.
  - 9- Von Arx T & Buser, D: Horizontal ridge augmentation using autogenous block grafts and the guided bone regeneration technique with collagen membranes: A clinical study with 42 patients. *Clin Oral Implant Res.* 2006; 17; 359–66.
  - 10- Von Arx T, Hardt N & Wallkamm B: The time technique: A new method for localized alveolar ridge augmentation prior to placement of dental implants. *Int J Oral Maxillofac Implant.* 1996; 11; 387–94.
  - 11- Balaram Naik, P Karunakar, M Jayadev, & V Rahul Marshal: Role of Platelet rich fibrin in wound healing: A critical review. *J Conserv Dent.* 2013; 16; 284–293
  - 12- Laurens N, Koolwijk P & de Maat MP: Fibrin structure and wound healing. *J Thromb Haemost.* 2006; 4; 932-9.
  - 13- Chang IC, Tsai CH, & Chang YC: Platelet-rich fibrin modulates the expression of extracellular signal-regulated protein kinase and osteoprotegerin in human osteoblasts. *J Biomed Mater Res.* 2010; 95; 327–32.
  - 14- Lekovic V, Milinkovic I, Aleksic Z, Jankovic S, Stankovic P, Kenney EB & Camargo PM: Platelet-rich fibrin and bovine porous bone mineral vs. platelet-rich fibrin in the treatment of intrabony periodontal defects. *J Periodontal Res.* 2012;47; 409–17.
  - 15- Panda S, Jayakumar ND, Sankari M, Varghese SS, & Kumar DS: Platelet rich fibrin and xenograft in treatment of intrabony defect. *Contemp Clin Dent.* 2014; 5; 550–4.
  - 16- Juneja G & Bharti V: Treatment of periodontal intrabony defects with platelet-rich fibrin and porous hydroxyapatite bone graft: A comparative clinical and radiographic study using Dentascan. *Saint Int Dent J.* 2015; 1; 22-7
  - 17- Bosshardt DD & Sculean A: Does periodontal tissue regeneration really work? *Periodontology.* 2009; 51; 208–19.
  - 18- Sharma A & Pradeep AR.: Treatment of 3-wall intrabony defects in patients with chronic periodontitis with autologous platelet rich fibrin: a randomized controlled clinical trial. *J Periodontol.* 2011; 82; 1705–12.
  - 19- Thorat M, Pradeep AR & Pallavi B: Clinical effect of autologous platelet-rich fibrin in the treatment of intra-bony defects: a controlled clinical trial. *J Clin Periodontol.* 2011; 38; 925–32.
  - 20- Chang YC & Zhao JH: Effects of platelet-rich fibrin on human periodontal ligament fibroblasts and application for periodontal infrabony defects. *Aust Dent J.* 2011; 56; 365-71
  - 21- Toffler M, Toscano N, Holtzclaw D, Corso MD & Ehrenfest DD: Introducing Choukroun's platelet rich fibrin (PRF) to the reconstructive surgery milieu. *The Journal of Implant & Advanced Clinical Dentistry.* 2009; 1; 21-31.
  - 22- Ajay Kumar Bhatt, Vandana A Pant & Mayank Pandey: Alveolar Ridge Preservation with beta-tricalcium phosphate Bone Graft and Implant Placement: A Case Report. *IJSS Case Reports & Reviews* 2015; 1; 28-31
  - 23- Tamimi F, Sheikh Z & Barralet J: Dicalcium phosphate cements: brushite and monetite. *Acta Biomater.* 2012; 8; 474–87.
  - 24- Hashimoto-Uoshima M, Ishikawa I, Kinoshita A, Weng HT, & Oda S: Clinical and histologic observation of replacement of biphasic calcium phosphate by bone tissue in monkeys. *Int J Periodontics Restorative Dent.* 1995; 15; 205–; 13.
  - 25- Strub JR, Gaberthuel TW, & Firestone AR: Comparison of tri-calcium phosphate and frozen allogenic bone implants in man. *J Periodontol.* 1979; 50; 624–9.
  - 26- Amler MH: Osteogenic potential of non-vital tissues and synthetic implant materials. *J Periodontol.* 1987;58;758–61.
  - 27- Baldock WT, Hutchens LH Jr, McFall WT Jr & Simpson DM: An evaluation of tricalcium phosphate implants in human periodontal osseous defects of two patients. *J Periodontol.* 1985; 56; 1–7.
  - 28- Shalash MA, Rahman HA, Azim AA, Neemat AH, Hawary HE, & Nasry SA: Evaluation of horizontal ridge augmentation using beta tricalcium phosphate and demineralized bone matrix: A comparative study. *J Clin Exp Dent.* 2013; 5; 253–9.
  - 29- Wang S, Zhang Z, Zhao J, Zhang X, Sun X, Xia L, Chang Q, Ye D & Jiang X: Vertical alveolar ridge augmentation with beta tri-calcium phosphate and autologous osteoblasts in canine mandible. *Biomaterials* 2009; 30; 2489–98.
  - 30- Nyan M, Miyahara T, Noritake K, Hao J, Rodriguez R & Kasugai S: Feasibility of alpha tricalcium phosphate for vertical bone augmentation. *J Investig Clin Dent.* 2014; 5; 109–16.

- 31- Barboza EB, Duarte ME, Geolás L, Sorensen RG, Riedel GE & Wikesjo UM: Ridge Augmentation Following Implantation of Recombinant Human Bone Morphogenetic Protein-2 in the Dog. *J Periodontol.* 2000; 71; 488-96
- 32- Seibert JS.: Reconstruction of deformed, partially edentulous ridges, using full thickness onlay grafts. Part I. Technique and wound healing. *Compend Contin Educ Dent.* 1983; 4; 437-53.
- 33- Jarcho M.: Biomaterial aspects of calcium phosphates: properties and applications. *Dent Clin North Am.* 1986; 30; 25-47.
- 34- Stahl S & Froum S.: Histological evaluation of human intraosseous healing responses to the placement of tricalcium phosphate ceramic implants. I. Three to eight months. *J Periodontol.* 1986; 57:211-17.
- 35- Driessens FCM, Ramselaar MMA, Schaeken HG, Stols ALH, Van Mullem PJ& De Wijn JR: Chemical reactions of calcium phosphate implants after implantation in vivo. *J Mater Science Mater Med.* 1992; 3:413- 417.
- 36- LeGeros RZ: Properties of osteoconductive materials: calcium phosphates. *Clin Orthop Rel Res.* 2002; 395; 81-98.
- 37- Metsger DS, Driskell TD& Paulsrud JR: Tricalcium phosphate ceramic, a resorbable bone implant: Review and current status. *J Am Dent Assoc.* 1982; 105; 1035-8.
- 38- Trisi P, Rao W, Rebaudi A & Fiore P: Histologic effect of pure phase beta-tricalcium phosphate on bone regeneration in human artificial jawbone defects. *Int J Periodontics Restorative Dent.* 2003;23;69- 77
- 39- Dohan Ehrenfest DM, Rasmusson L& Albrektsson T: Classification of platelet concentrates from pure platelet-rich plasma (P-PRP) to leucocyte and platelet-rich fibrin (L-PRF). *Trends Biotechnol.* 2009; 27; 158-67.
- 40- Mosesson MW, Siebenlist KR& Meh DA: The structure and biological features of fibrinogen and fibrin. *Ann NY Acad Sci.* 2001; 936; 11-30.
- 41- Lee HJ, Choi BH, Jung JH, Zhu SJ, Lee SH, Huh JY, You TM & Li J: Maxillary sinus floor augmentation using autogenous bone grafts and platelet-enriched fibrin glue with simultaneous implant placement. *Oral Surg Oral Med Oral Pathol Oral Radiol Endod.* 2007; 103; 329-33.
- 42- Pastoureau PC, Hunziker EB & Pelletier JP. : Cartilage, bone and synovial histomorphometry in animal models of osteoarthritis. *Osteoarthritis Cartilage.* 2010; 18; 106-12.
- 43- Gul Gursoy, Yasar Acar& Selma Alagoz: Osteopontin: A multifunctional molecule. *Journal of Medicine and Medical Sciences.* 2010; 1; 55-60.
- 44- Yilmaz D, Dogan N, Ozkan A, Sencimen A, Ora BE & Mutlu I: Effect of platelet rich fibrin and beta tricalcium phosphate on bone healing. A histological study in pigs. *Acta Cir. Bras.* 2014; 29;59-65
- 45- MG Triveni, AB Tarunkumar, Vinita jain, & Dhoom S Mehta: Alveolar ridge preservation with  $\beta$ -TCP graft and platelet rich fibrin. *Int J Oral Implant Clin Res* 2012; 3; 96-100
- 46- Wiltfang J, Kloss FR, Kessler P, Nkenke E, Schulze-Mosgau S, Zimmermann R & Schlegel KA: Effects of platelet-rich plasma on bone healing in combination with autogenous bone and bone substitutes in critical-size defects. An animal experiment. *Clin Oral Implants Res.* 2004; 15; 187-93.
- 47- Podaropoulos L, Veis AA, Papadimitriou S, Alexandridis C & Kalyvas D: Bone regeneration using beta-tricalcium phosphate in a calcium sulfate matrix. *J Oral Implantol.* 2009; 35; 28-36