



## **OUTCOME OF ARTHROSCOPIC LYSIS AND LAVAGE FOR INTERNAL DERANGEMENT OF THE TEMPOROMANDIBULAR JOINT**

Reem H. Hossameldin\* and Mamdouh S. Ahmed\*\*

### ***ABSTRACT***

**Background:** Temporomandibular Joint (TMJ) diseases have been established to be differentiated between intra-articular and extra-articular problems. TMJ internal derangement categories are the diseases with orthopedic obstacles that require management which might require surgical intervention. Among different surgical interventions, TMJ arthroscopy has been proven to be one of the minimally invasive surgical approaches to tackle TMJ internal derangement. Arthroscopic surgery appears to be a safe, minimally invasive and effective method for treating internal derangements (ID) of the temporomandibular joint (TMJ).

**Aim:** the purpose of this study is to assess the outcome of using arthroscopic lysis and lavage for TMJ ID.

**Patient and Method:** This is a prospective, cohort (27-52y), single institutional clinical study. TMJ ID subjects who failed conservative treatment for two months were presented and treated at the oral and maxillofacial surgery department, faculty of oral and dental medicine, Cairo University. The primary outcome variable was the absence of joint pain at 6 months postoperatively. Secondary outcome variables included joint function and maximum inter-incisal opening (MIO). Patients were followed up for six months postoperatively. Statistical analyses included paired t test and Chi square test.

**Results:** 28 subjects (45;11 unilateral & 34 bilateral), with a mean age of 38.3 years. 24 (85.7%) were females. Successful outcome was seen in 64.4% of the studied subjects. Maximum painless inter-incisal opening as well as visual analog scale for joint pain and function showed a statistical significant improvement at the end of the follow up period.

**Conclusion:** This study showed that TMJ arthroscopic lysis and lavage is an effective and predictable treatment for TMJ ID patients who failed conservative treatment.

\* Lecturer of Oral and Maxillofacial Surgery, Oral and Maxillofacial Surgery Department, Faculty of Oral and Dental Medicine, Cairo University

\*\* Assistant Professor of Oral and Maxillofacial Surgery, Oral and Maxillofacial Surgery Department, Faculty of Oral and Dental Medicine, Cairo University

## INTRODUCTION

Internal derangement (ID) of the temporomandibular joint (TMJ) may be defined as a disruption within the internal aspects of the TMJ in which there is a displacement of the articular disc from its normal functional relationship with the mandibular condyle and the articular portion of the temporal bone. Farrar<sup>1</sup> estimated that up to 25% of the entire populations has an internal derangement, which is usually treated with non-surgical methods initially.<sup>2</sup> Should these methods prove unsuccessful, they are often followed by surgical methods such as disc repositioning procedures, meniscectomy, and condylotomy. More recently, studies utilizing magnetic resonance imaging suggest that the articular disc is displaced in 35% of asymptomatic individuals.<sup>3,4,5</sup>

The most commonly used classification to describe the severity of ID was proposed by Wilkes in 1989.<sup>6</sup> The Wilkes classification consists of five stages based on clinical, radiologic, and intraoperative findings, varying from a slight forward displacement with symptom-free normal joints to essentially degenerative arthritic changes with severe clinical symptoms.

The primary treatment of ID of the TMJ is conservative management. Occlusal splint insertion and physical treatment are the most common options.<sup>7,8</sup> Around 90% of all temporomandibular disorders (TMD) can be successfully treated by these conservative methods.<sup>9</sup> However, the 10% that are refractory to non-surgical procedures need more invasive treatment, such as arthroscopic surgery.<sup>10</sup>

A small joint arthroscope was first used in the human temporomandibular joint by Ohnishi in 1975.<sup>11</sup> The landmark thesis by Murakami and Hoshino<sup>12</sup> was the impetus for arthroscopic surgery being developed into a clinical technique.<sup>13</sup>

The standard arthroscopic technique involves lysis and lavage of the superior joint space under

direct arthroscopic vision.<sup>14-18</sup> This procedure improves both TMJ pain and limitation in mouth opening. Bronstein and Merrill<sup>18</sup> noticed higher success rates of arthroscopic surgery in early than in advanced Wilkes stages. Murakami et al.<sup>19</sup> found no significant differences in the efficiency of arthroscopic surgery between different stages of TMD.<sup>20</sup> However, these studies did not focus on a specific arthroscopic treatment, using different operation techniques in different Wilkes stages. It is still unknown whether there are differences in efficiency of arthroscopic lysis and lavage in relation to the severity of the TMD.

The recent development of TMJ arthroscopic surgery — a minimally invasive procedure — appears to have filled the clinical void between failed non-surgical treatment and open arthrotomy. In the past decade, arthroscopic surgery and, more recently, arthrocentesis have been used with increasing frequency to treat TMJ internal derangements that failed to improve following a reasonable course of non-surgical therapy.<sup>6</sup>

**The aim** of the present study was to clinically evaluate, the outcome of a standard arthroscopic lysis and lavage of the TMJ in internal derangement of varying severity according to Wilkes classification.

## SUBJECTS AND METHODS

28 patients were randomly selected from the outpatient clinic of Oral and Maxillofacial Surgery, Faculty of oral and dental medicine, Cairo University, Egypt.

### **Inclusion criteria consisted of:**

- Clinically reduced mouth opening and/or painful maximum mouth opening.
- Magnetic Resonance Imaging (MRI) demonstration of different Wilkes stages of ID<sup>7</sup>
- Unsuccessful non-surgical treatment for at least two months prior to surgery.

**Exclusion criteria:**

- Patients with evidence of major jaw trauma.
- Patients with systemic joint or muscle disease: such as rheumatoid arthritis or any other immune arthritis and synovial chondromatosis, ..etc.
- Patients with major jaw deformities. Such as avascular condylar necrosis, condylar hyperplasia, condylar osteochondroma, .. etc.

Arthroscopic lysis and lavage was performed within one month of reevaluation after unsuccessful conservative treatment.

**Before the arthroscopic treatment, the patients were examined clinically, based on TMJ assessment standardized form consisting of:**

**Patient History:****Patient's Demographics:**

- Included patient's name, age, gender, occupation, address and marital status.
- Chief Complaint: the patients reported only one, or a variety of, symptoms, such as: limitation in mouth opening, joint noises, joint pain, earache, headaches, ...etc.
- History of Present illness:
- A pertinent documentation of events took place in accordance with patient's narrative description of the disease progression.
- Para-function and associated causes:

As bruxism or clenching habits being witnessed or non-witnessed and presence of masticatory musculature spasm ("jaw stiffness"), mental or physical stress was reported for every patient.

- Diet: whether was regular, regular-compromised or soft.
- Previous treatment options attempted.

- Visual analogue scale (VAS):

All patients were guided to a form for functional and pain analogs regarding mouth opening and shift of central line of jaws.

**Clinical Examination:**

Maximal Inter-incisal Opening and Range of Motion (MIO): by using millimeter ruler to measure distance between incisal edges of upper central incisor and lower incisor at maximal mouth opening both assisted and unassisted. Joint noise: by digital palpation and feeling and/or hearing any noises accompanying jaw motion. Pain assessment of joint and adjacent musculature: via digital palpation and pressure of masseter muscles bilaterally via extra-oral examination, and pterygoid muscles bilaterally via intraoral examination. Finally; head, eyes, ears, Nose and throat (HEENT): as standard for any abnormalities

**Surgical Procedure:**

Under general anesthesia using naso-tracheal intubation, arthroscopic lysis and lavage with mandibular manipulation was performed using a 2.0mm mini-scope set of 1.9mm diameter, 30-degree scope\*.

**I. Operative Steps:**

1. Examination under anesthesia: to examine jaw motions and re-examine the joints clinically for noises and any restriction in jaw motion or function.
2. Palpation of TMJ anatomy (Fig. 1).
3. Insufflation of the superior joint space: the purpose for distension of the joint was to expand the target area. 3ml 0.5% bupivacaine in a 3cc syringe with a 25 gauge, 1 ½ inch needle were used in the process (Fig. 2)

\* Smith & Nephew Andover MA, USA

- 4. Fossa puncture: The puncture was placed at maximum concavity of the glenoid fossa. The cannula was not to be inserted more than 20-25 mm from skin surface to the center of the joint. Before inserting the scope, the joint was back-washed in order to remove all blood and synovial fluid. The image on the monitor confirmed correct entry into the joint space (Fig.3)
- 5. Outflow needle puncture: With the mandible protruded, the scope was directed to the center of the fossa area of the joint. The assistant insufflated the joint with 2-3 cc of fluid in order to maintain joint distension. A 22 gauge, 1 ½ inch

needle was inserted approximately 5 mm anterior and 5 mm inferior to the fossa puncture site, under joint insufflation (Fig.4)

- 6. Diagnostic sweep:
  - a. The seven points of interest of the TMJ arthroscopic examination were examined which included: Medial synovial drape, Pterygoid shadow, Retrodisical synovium, Posterior slope of the articular eminence and glenoid fossa, Articular disc, Intermediate zone, and Anterior recess, along with Joint dynamics and disc mobility (Fig.5)

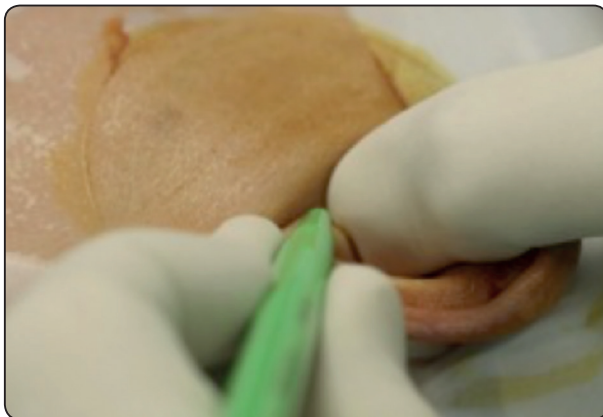

Fig. (1) Palpation of joint anatomy

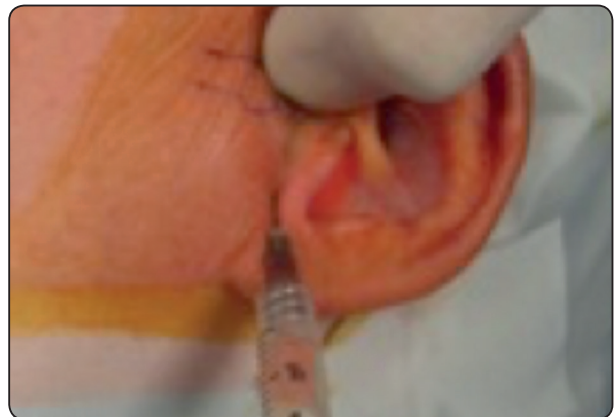

Fig. (2): Insufflation of superior joint space

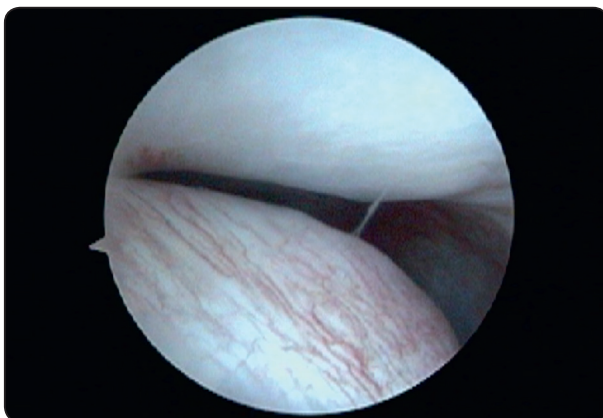


Fig. (3): Arthroscopic photo of left TMJ showing an anterior displacement of disc with retrodisical tissue covering the mandibular condyle.

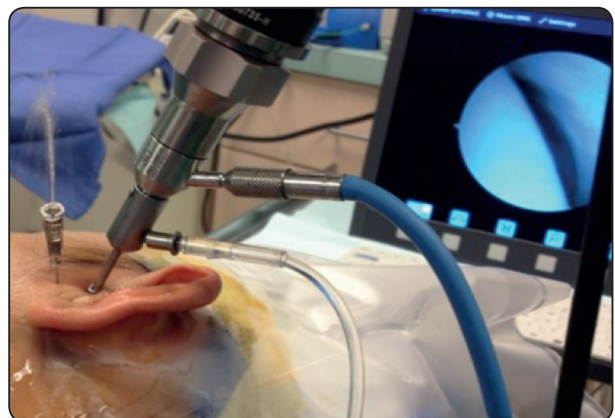


Fig. (4): outflow needle puncture

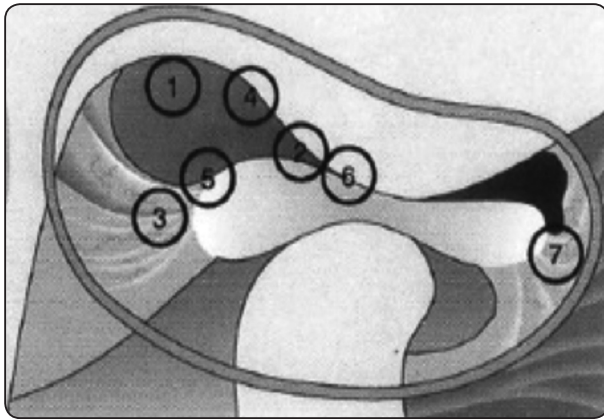


Fig. (5): Diagnostic sweep

7. Intra-articular medications: Hyaluronic acid (HA) HEALON® OVD Abbott Laboratories Inc. Abbott Park, Illinois, USA 0.55 ml of 10 mg sodium hyaluronate was injected intra-articularly through lavage track of fossa portal cannula after removal lavage needle.
8. Then, the scope-cannula system was removed from the joint, with the head of the patient elevated above heart level, followed by skin suturing of only the fossa puncture site using non resorbing 5-0 suture on in one interrupted suture manner. Surgical site is covered with antibiotic ointment and covered with small circular band-aid spots.
9. Manipulation under anesthesia: Assisted maximal inter-incisal maximal opening were performed to record the maximal inter-incisal mouth opening reached. Finally, patients got extubated, with reversal of anesthesia gently.

## II. Post-operative patient management:

**Analgesia/pain management:** A regimen of oral Ketolac (Amriya Pharmaceutical Industries), if tolerated, was instituted for the next 5-7 days. **Anti-inflammatory management:** On occasion, the patient diagnosed with osteoarthritis, then he/she was prescribed a longer (up to 4 weeks) regimen of NSAIDS. **Diet:** The full liquid diet is advanced to a strictly soft diet in a very gradual fashion; clear to full liquid diet for the immediate post operative period of hospital stay (1 day), followed by soft diet

for 6 weeks, then semi solid consistency diet for 4 months, reaching regular compromised diet from this point forward. Skin suture was removed 1 week after surgery during the immediate post-operative follow up visit.

## III. Post-operative rehabilitation:

- Full - coverage occlusal stabilization splint is resumed to be used on immediate post operative day 1
- Stage I Physiotherapy (PT): Stage I exercises consisted of limited ROM exercises and gentle isometrics. Exercises were conducted by patient starting the day after surgery in a repeated fashion and followed up in outpatient clinic to assure efficacy.
- Stage II Physiotherapy:
- Stage II followed the same basic pattern and frequency as described for stage I. To increase the ROM of excursions, the exercises described for stage I were performed in a “past-borders” fashion.
- Stage III Physiotherapy: This stage consisted of muscle reeducation.

## IV. Post-operative Assessment:

All patients were clinically assessed at 1, 3, 6, 12 and 24 weeks

This study was assessed by careful categorization of cases according to different stages of internal derangements, which have been specified by Wilkes classification into five stages according to clinical, MRI, and arthroscopic examinations. Such findings were correlated to the general outcome of surgical procedures using clinical assessment in terms of:

- Functional jaw pain was evaluated by using a visual analog scale (VAS) ranging from 0 to 100 (100 = no pain/ good function, 0 = severe maximum pain/ dysfunction)
- The improvement in the painless range of mandibular motion measured by the maximum inter-incisal distance in millimeters



- The outcome assessment was based on the difference between the preoperative and post-operative values in VAS of pain. When the difference was more than zero; this was considered a success, if equal to or less than zero, this considered a failure.

### V. Statistical Analysis:

Statistical analysis was performed using SPSS (Statistical package for the social sciences) version 20, IBM corp., U.S.A. Data were represented as means  $\pm$  standard deviations or frequencies and percentages. Paired Student t-tests were used to compare continuous variables; Chi square test was used to show relationships between binary variables. In all tests results were considered statistically significant if the *p*- value was less than 0.05

## RESULTS

Temporomandibular joint Arthroscopic lysis and lavage was performed to 28 patients 4 (14.3%) males and 24 (85.7%) females with unilateral (11 patients) and bilateral (17 patients) temporomandibular joint internal derangement in Department of OMFS, Faculty of oral and dental medicine, Cairo University, Egypt between January 2015 and February 2016. The number of unilateral joint affection was 11 joints and bilateral joint affection was 34 joints with a total number of 45 joints. The age of the selected subjects ranged from 27 to 52 with a mean of 38.3 years. All Patients were followed up for a period ranging from 6 to 12 months with a mean of  $9 \pm 1.3$  months.

No perioperative or postoperative major complications occurred; none of the patients developed transient or permanent neurosensory deficits of the facial nerve. There were no signs of infection, bleeding, or hematoma. However, some patients presented by minimal edema and tenderness at one week postoperatively with subsequent normal wound healing and they regained their normal ability within the next week.

The mean values of the painless maximum inter-incisal mouth opening showed statistically

significant increase by the end of the follow up period when compared to their preoperative values. Similarly visual analog scale was performed for joint pain and function for all selected patients preoperatively and at six months. There was a statistical significant improvement of both joint pain and function at the end of the follow up period (Table 2).

TABLE (1) Preoperative clinical and MRI diagnosis.

Preoperative Diagnosis	Frequency	Percent
I	1	2.2
II	7	15.6
III	13	28.9
IV	9	20
V	8	17.8
Synovitis	1	2.2
Others*	6	13.3
Total	45	100.0

\* *Others included: Ankylosing Osteoarthritis, Inflammatory Arthritis, Subluxation.*

TABLE (2) MIO and Visual Analog Scale

	Mean	STD.	P value
Preoperative MIO (mm.)	33.3	9.1	0.001*
MIO At Six Months (mm.)	38.7	6.5	
Preoperative Joint Pain (VAS)	47.3	26.9	0.001*
Joint Pain At Six Months (VAS)	65.7	27.05	
Preoperative Joint Function (VAS)	44.7	22	0.001*
Joint Function At Six Months (VAS)	65.4	25.5	

The main outcome variable of the current study was to assess the degree of joint pain at six months postoperatively. Table 3 shows the change in joint pain intensity at the 6 month follow up assessment. Chi square test showed a significant statistical difference between the percentages of patients with successful outcome and those with failure outcome (Fig. 6).

TABLE (3) Joint Pain Intensity outcome at six months.

Outcome	Joint Pain	Frequency	Percent	P value
Success	Improvement	29	64.4	<0.001*
Failure	No Change	7	15.6	
	Worse	9	20	
Total		45	100.0	

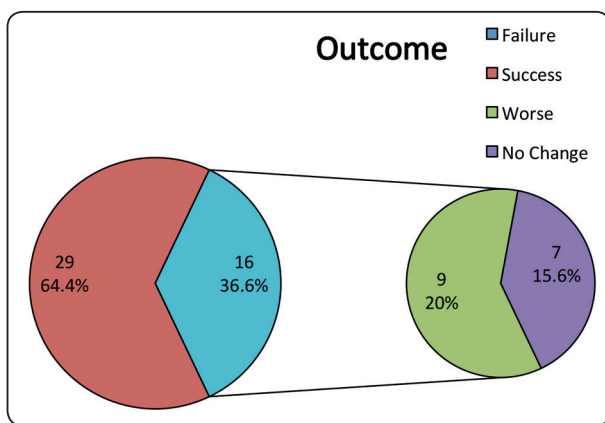


Fig. (6) Outcome of Pain improvement postoperatively

The impact of Wilkes classification on outcome showed that Wilkes I patients had the maximum success rate 100%, followed by Wilkes II patients who had a 85.7% success rates, then Wilkes III patients whom success rate was 77.9%. On the other hand Wilkes IV and V patients had significantly lower success rates of 66.7% and 62.5% respectively. (Table 4).

TABLE (4) The impact of Wilkes classification on the outcome

	I	II	III	IV	V	p value
Success	100%	85.7%	77.9%	66.7%	62.5%	0.13 <sup>a</sup>
Failure	0%	14.3%	22.1%	33.3%	37.5%	

<sup>a</sup> Insignificant

### DISCUSSION

Despite of the diversity in the management beliefs of TMJ diseases, almost all TMJ specialists agreed upon the management with the most conservative approaches. This directed more interest towards the minimal invasive TMJ surgical management. One of those modalities is the TMJ arthroscopy with its different levels. It is established that TMJ arthrocentesis has been developed after the invention and use of TMJ arthroscopy and from its rational. The advantage of arthroscopy versus arthrocentesis is the ability to visualize and conform a final diagnosis that can be missed by using blind lysis and lavage in arthrocentesis. However, there is no statistical difference in complications between the two techniques.

In the current study, patients with evidence of major jaw trauma, systemic joint or muscle disease, and /or with major jaw deformities, were excluded from the study, in order to ascertain the homogeneity of the study sample that coordinate with the indications for TMJ diagnostic arthroscopy procedure, so that all patients would benefit from such procedure.

According to the current TMJ established literature, the most commonly used classification to describe the severity of internal derangement was proposed by Wilkes in 1987<sup>5</sup>. This is why the current study used it as a reference for clinical, and MRI diagnosis of TMJ patients' classifications and groupings. However, among the limitations of the Wilkes classification, is that other established

pathological entities of ID are not included, while they are still existing, like: subluxation, primary osteoarthritis, or inflammatory arthritis.

This is why in the present study; those categories were recorded in separate groups. Synovitis cases with no arthritic condylar changes were grouped as a separate entity to differentiate them from other arthritic conditions manifested by inflammatory synovitis findings. The protocol and philosophy behind selecting the surgical patients in the current study, were to be confined to the ones who have failed a minimum of two months of conservative non-surgical management. According to

Randolph, who established in 1990, that around 90% of all TMD can be successfully treated by conservative non-surgical methods as occlusal splints and physical therapy.<sup>9</sup> The 10% that are refractory to nonsurgical procedures, and need more invasive treatment, such as arthroscopic surgery.

All procedures have been done under general anesthesia to assure comfort of patient and ensure the minimal invasiveness of the procedure as well as giving the surgeon the ability to maximize the benefit to patient with no limiting variables. This study was designed to test the efficacy of arthroscopic lysis and lavage in management of TMJ internal derangement. The current study showed a significant statistical difference between the percentages of patients with successful outcome (64.2 %) and reduction in their pain level, and those with failed outcome (35.8 %). Significant difference between the preoperative maximal inter-incisal opening (MIO) (Mean 33.3 mm) and post-operative (Mean 38.7 mm) was recorded ( $p=0.001$ ).

Reviewing the literature, success rates of arthroscopic lysis and lavage for the treatment of ID have ranged from 80% to 86%.<sup>10,13,14,15,18</sup> In those earlier studies, the success rates were calculated based on two main criteria: improvement of mandibular movement in terms of MIO and reduction of pain levels. Mandibular movement was considered to be satisfactory when inter-

incisal mouth opening was 35-38 mm after surgery. The reduction of pain levels is usually evaluated using VAS for pain. The treatment is considered to be successful when pain levels of 20-33 on the VAS were achieved after surgery. Those studies used the cut off values for assessing their outcome, which might be unrealistic to the individual variations among patients especially when we assess the maximal inter-incisal opening, which might vary from patient to the other, as well as the difference in the degree of compliant perception among the.

As the present study was consistent with other studies in assessing the outcome of all patients in general. Where Dimitroulis<sup>21</sup> and Kondoh<sup>22</sup> reported their outcome of arthroscopic lysis and lavage based on general improvement scale (good to excellent, mild, and no improvement) for all patients with ID with no specification. However, the question remained of whether the severity of ID affected the success rate of arthroscopic lysis and lavage in cases of TMD. To this end, prior staging of ID according to the Wilkes classification is helpful. The present study showed that different stages of ID do have a significant clinical but not statistical impact on the outcome, most probably due to small sample size; it showed 85.7% success rates in Wilkes II patients, then Wilkes III patients whom success rate was 77.2%. On the other hand Wilkes IV and V patients had significantly lower success rates of 66.7% and 62.5% respectively. This polysaccharide of the glucosaminoglycans family is a component of many extracellular tissues, including synovial fluid and cartilage. It is a product of the articular chondrocytes and synoviocytes. The concept behind TMJ injection of hyaluronate is the stimulation of the endogenous synthesis of hyaluronic acid (HA) by the exogenous HA. Hyalgan is a 500 to 730 kDa molecular weight fraction of highly purified avian sodium hyaluronate buffered (pH 6.8–7.5) in physiologic saline. We believe that hyaluronate is an excellent intra-articular lubricating agent that facilitates navigation while minimizing iatrogenic intraarticular injury (scuffing) and coagulates microbleeders in the joint.



Those results were consistent with Bronstein and Merrill<sup>19</sup> who reported a success rate of 96% for stage II, 83% for stage III, 68% for stage IV, and 63% for stage V disease.

## REFERENCES

- Dolwick MF, Katzberg RW, Helms CA. Internal derangements of the Temporomandibular joint: fact or fiction? *J Prosthet Dent.* 49:415, 1983. Farrar WB. Myofascial pain dysfunction syndrome [letter]. *J Am Dent Assoc.* 102:10, 1981.
- Katzberg RW, Westesson PL, Tallents RH, Drake CM. Anatomic disorders of the temporomandibular joint disc in asymptomatic subjects. *J Oral Maxillofac Surg.* 54:147, 1996.
- Ribeiro RF, Tallents RH, Katzberg RW, Murphy WC, Moss ME, Magalhaes AC. The prevalence of disc displacement in symptomatic and asymptomatic volunteers aged 6 to 25 years. *J Orofac Pain.* 11:37, 1997.
- Barkin S, Weinberg S. Internal derangements of the temporomandibular joint: The role of arthroscopic surgery and arthrocentesis. *J Can Dent Assoc.* 66 (4): 199, 2000.
- Wilkes CH. Internal derangements of the temporomandibular joint. Pathological variations. *Arch Otolaryngol Head Neck Surg.* 115:469, 1989.
- Chung SC, Kim HS. The effect of the stabilization splint on the TMJ closed lock. *Cranio.* 11:95, 1993.
- Mongini F, Ibertis F, Manfredi A. Long-term results in patients with disk displacement without reduction treated conservatively. *Cranio.* 14:301, 1996.
- Randolph CS, Greene CS, Moretti R, Forbes D, Perry HT. Conservative management of temporomandibular disorders: post treatment comparison between patients from a university clinic and from private practice. *Am J Orthod Dentofacial Orthop.* 98:77, 1990.
- Smolka W, Yanai C, Smolka K, Iizuka T. Efficiency of arthroscopic lysis and lavage for internal derangement of the temporomandibular joint correlated with Wilkes classification. *Oral Surg Oral Med Oral Pathol Oral Radiol Endod.* 106(3): 317, 2008.
- White RD. Arthroscopy of the temporomandibular joint: technique and operative images. *Atlas Oral Maxillofac Surg Clin North Am.* 11(2): 129, 2003.
- Murakami K, Hoshino K. Histologic studies on the inner surfaces of the articular cavities of human temporomandibular joints with special reference to arthroscopic observations. *Anat Anz Jena.* 160:167, 1985.
- Indresano AT. Surgical arthroscopy as the preferred treatment for internal derangements of the temporomandibular joint. *J Oral Maxillofac Surg.* 59(3): 308, 2001.
- Sanders B. Arthroscopic surgery of the temporomandibular joint: treatment of internal derangement with persistent closed lock. *Oral Surg Oral Med Oral Pathol Oral Radiol Endod.* 62:361, 1986.
- Moses JJ, Sartoris D, Glass R, Tanaka T, Poker I. The effect of arthroscopic surgical lysis and lavage of the superior joint space on TMJ disc position and mobility. *J Oral Maxillofac Surg.* 47:674, 1989.
- McCain JP, Sanders B, Koslin MG. Temporomandibular joint arthroscopy: a 6-year multicenter retrospective study of 4831 joints. *J Oral Maxillofac Surg.* 50:926, 1992.
- Koslin MG, Martin JC. The use of holmium laser for temporomandibular joint arthroscopic surgery. *J Oral Maxillofac Surg.* 51:122, 1993.
- Murakami K, Segami N, Okamoto M, Yamamura I, Takahashi K, Tsuboi Y. Outcome of arthroscopic surgery for internal derangement of the temporomandibular joint: long-term results covering 10 years. *J Craniomaxillofac Surg.* 28:264, 2000.
- Bronstein SL, Merrill RG. Clinical staging for TMJ internal derangement: application to arthroscopy. *J Craniomandib Disord.* 6:1, 1992.
- Murakami K, Tsuboi Y, Bessho K, Yokoe Y, Nishida T, Iizuka T. Outcome of arthroscopic surgery to the temporomandibular joint correlates with stage of internal derangement: five-year follow-up study. *Br J Oral Maxillofac Surg.* 36:30, 1998.
- Dimitroulis G. A review of 56 cases of chronic closed lock treated with temporomandibular joint arthroscopy. *J Oral Maxillofac Surg.* 60:519-24, 2002.
- Kondoh T, Dolwick MF, Hamada Y, Seto K. Visually guided irrigation for patients with symptomatic internal derangement of the temporomandibular joint: a preliminary report. *Oral Surg Oral Med Oral Pathol Oral Radiol Endod.* 95: 544, 2003.