

MORPHOLOGICAL CHANGES IN THE TEMPOROMANDIBULAR JOINT (TMJ) AFTER MANDIBULAR LENGTHENING BY DISTRACTION OSTEOGENESIS. A CLINICAL STUDY

Ashraf Ghanem* and Hamed Gad**

ABSTRACT

The purpose of this study was to evaluate the morphological changes in the TMJ after mandibular body lengthening by distraction osteogenesis (DO). This study was conducted on 10 patients suffered from unilateral mandibular body deficiency and corrected through mandibular lengthening following standard distraction osteogenesis (DO). The impacts of DO on TMJs were examined and evaluated with magnetic resonance images through pre-operative- and post-distraction. The results revealed that; comparing pre-operative and post-distraction interpretation of TMJs magnetic resonance images; there was no morphological effect on TMJ following mandibular body distraction osteogenesis; on the other hand there was improvement of 4 cases suffered from anterior disk displacement with reduction (ADDWR) following mandibular body lengthening by distraction osteogenesis (DO).

KEY WORDS: Mandibular lengthening, distraction osteogenesis, TMJ, mandibular lengthening by distraction osteogenesis and Morphological changes.

INTRODUCTION

Distraction osteogenesis techniques were primarily applied to adult patients pre-dominantly with tumor related segmental defects of the mandible. However, distraction osteogenesis applications continue to expand with severe mandibular retrognathia.¹

The TMJ is considered a unique joint in the human skeletal system. As it varies from all other joints of the body, primarily through its two folds

components of two joints acting concurrently (bipedalism), its sliding function, and having joint surfaces and a disk of fibrocartilage are performing.²

During mandibular distraction, although the body of the mandible receives a direct stretch, the distant condyle against the articular fossa undergoes indirect compression. Consequently; the proximal segment with the condyle may be moved backward

* Associate Professor; Department of Oral & Maxillofacial Surgery, Faculty of Dentistry, Minia University, Egypt.

** Lecturer; Department of Oral & Maxillofacial Surgery, Faculty of Dentistry, Minia University, Egypt.

and exert stress on the condyle surface.³ this compressive loading may induce alterations in the disk, condyle, and disk-condyle relationship, and posterior displacement of the condyle which could result in a degenerative changes in the articular cartilage.⁴ Therefore, there has been a great concern that mandibular osteo-distraction may create TMJ disorders. The purpose of the current study was to evaluate the morphological changes in the TMJ component following mandibular lengthening by distraction osteogenesis.

PATIENTS AND METHODS

The current prospective study was conducted on ten human patients with unilateral mandibular deficiency, six females and 4 males ranging from 10-14 years (mean 12 years). They were selected from the outpatient clinic of the department of Oral and Maxillofacial Surgery of Minia University Dental Hospital (MUDH).

Daignosis

- a) Complete case history was collected and recorded in standard sheet.
- b) Clinical examination including: Inspection of extra-oral facial deformity and scar as well as

the intra-oral examination (teeth and Occlusion), inter-incisal opening (I.I.O) and Oral hygiene. Palpation for detection of mobility of TMJ was performed; laterally in the pre-auricular area and posteriorly through the external auditory meatus during opening and closing.

- c) Radiographic examination: Standard panoramic view and pre-operative axial, coronal and (3-D) computed tomography of TMJ (Figure 1).
- d) Magnetic resonance image (MRI) examination: Pre-operative MRIs were used to assess the following parameters: Disk (position, morphology, and mobility), morphology of (the condyle, articular eminence, and glenoid fossa), joint effusion, and edema of the medullary bone.

Surgical procedures of distraction osteogenesis:
All surgical procedures were performed in MUDH under general anesthesia by using of nasal endotracheal intubation. Induction of general anesthesia was done through intravenous injection of Thiopental sodium* 0.5 mg of 2.5 % concentration. It was maintained in the all cases with a mixture of oxygen and halothane**. Surgical access was approached via an intraoral incision along the external oblique ridge. A full-thickness muco-periosteal flap was raised, and the lateral aspect

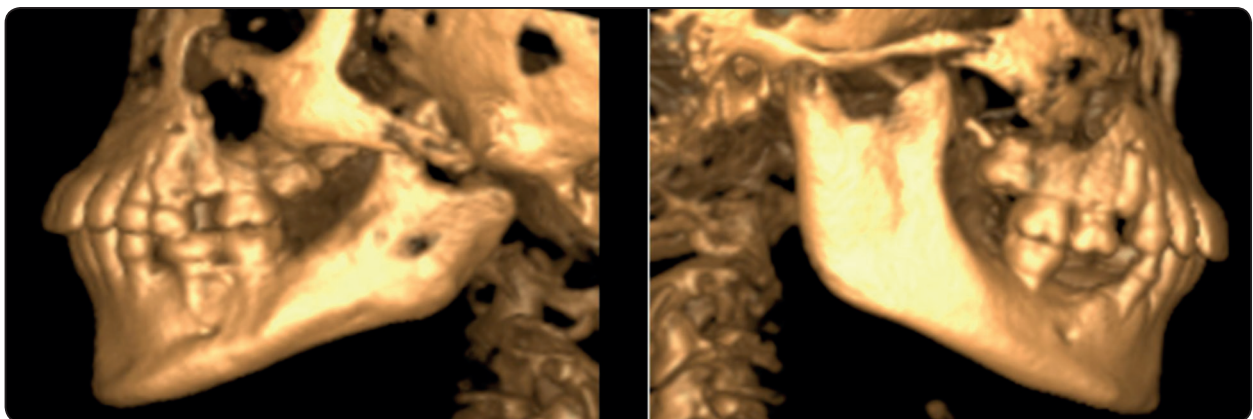


Fig. (1) Photos of three dimensional CT scan showing pre-operative view of post-ankyrotic patient.

* Thiopental sodium 0.10 gmbiochemie. GmbhVienna, Austria.

** Halothane B.P. Kahira- Pharmaceutical, Egypt.

of the mandible is exposed. The mental nerve was dissected and protected to avoid its injury during distraction procedures. The planned bone cut was marked and partially completed with a reciprocating saw with an appropriate size blade. Before converting the corticotomy into an osteotomy, the distractor device was placed; a single percutaneous stab incision is made for the placement of the activating arm of the device extraorally. The device was fixed in the center (sides of corticotomy) with self-taping screws and then removed it. A 3-mm osteotome completed the medial wall osteotomy, liberating the mandibular segments for distraction. The osteotomy at the inferior border of the mandible is completed after placement of the distractor with a thin sharp osteotome, making sure that no damage of the mandibular neurovascular bundle. After the distractor is secured, the cut around the mandibular body was completed with an osteotome. At this point, the distractor is activated 4 to 6 mm to verify completeness of the osteotomy. The device was then deactivated, allowing for the bone segments to be in close proximity. Vertical vectors of distraction along the ascending ramus were used for lengthen a vertically deficient ramus. Soft tissue incisions are closed in layers using 3-0 bio-absorbable suture (Figure 2). Routine postoperative vital sign were monitored until it became of normal reading. Also assessment of the integrity of the facial and mental nerves was carried out.

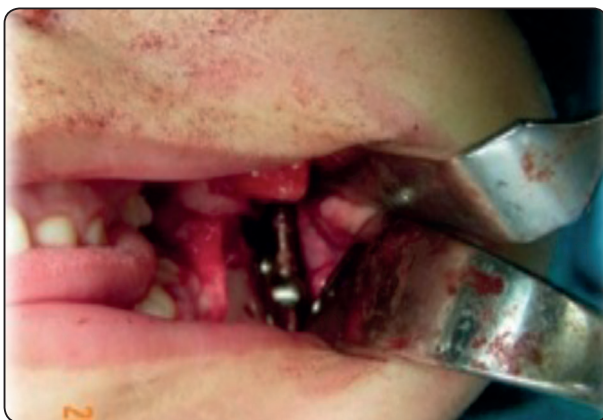

Fig. (2) Distractor was deactivated before closure.

After a latency period of 7 to 10 days, distractor was activated at a rate of 1 mm per-day. This rate was continued until the mandibular length is overcorrected by several millimeters. The device is left in place to serve as a fixator for 8 weeks, until there is radiographic evidence of mineralization. This stage is known as the consolidation phase.

MRI Interpretation

MRI was done using the same machine for each patient. Static sagittal T1 in the fully closed and maximum open mouth positions and Static sagittal T2 in the fully closed and maximum open mouth positions were performed.

Pre-operative and postoperative images acquired were used to assess the following Parameters: disk (position, morphology, and mobility), morphology of (the condyle, articular eminence, and glenoid fossa), joint effusion, and edema of the medullary bone. Normal disk position was defined by location of the posterior band of the disk at the superior or 12 o'clock position relative to the condyle in closed mouth position, while in open mouth position normal disk position was identified by interposition of intermediate zone between condylar head and articular eminence.¹⁰ The disk displacement was defined as the posterior band of the disk being in an anterior to 12 o'clock position relative to the superior part of the condyle in closed mouth position. A disk was considered reduced when the disk returned to a superior position on jaw opening. If there was no reduction and the disk remained anterior, this was considered disk displacement without reduction.¹⁴ Disk was considered not visible when, neither signal intensity nor outlines make it possible to define a structure as the disk.¹⁷

Normal disk morphology was defined as biconcave in appearance in the sagittal plane in closed-mouth projection and bow tie appearance in open mouth projection with a definable anterior band, intermediate zone, and posterior band.

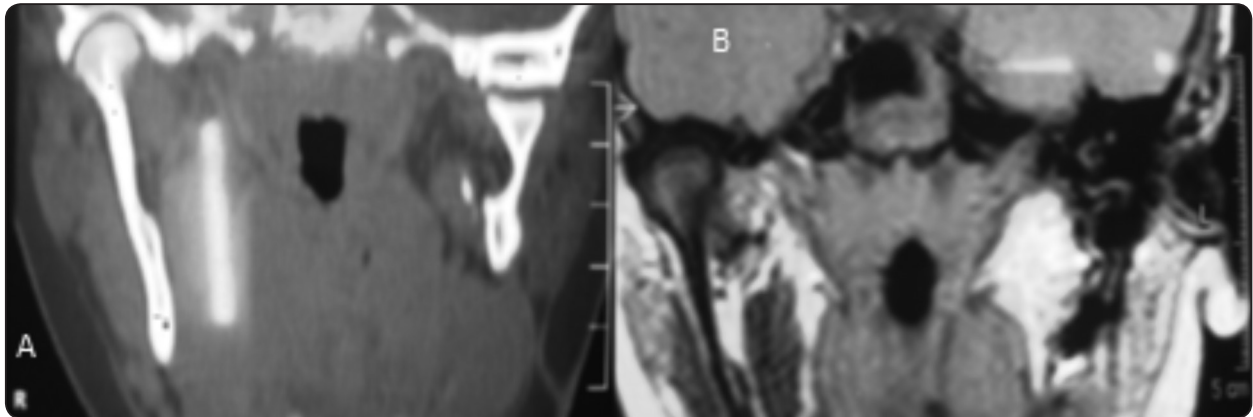


Fig. (3) (A), CT coronal cut showing normal Rt. Joint and gap-arthroplasty of Lt. Joint. (B), MRI images of coronal cut showing normal disk position of Rt. Joint.

Morphological changes of the disk include atrophy of the anterior band, thickening of the posterior band, and shortening of the entire antero-posterior length. The biconvex folded or amorphous disk shapes, were also considered as abnormal disk morphology (Figure 3).

RESULTS

The study was conducted on 10 patients; 4 males (40%) and 6 females (60%). The mean age was 12 years with a minimum of 10 years and a maximum of 14 years old. The post-operative course was uneventful. The patients resumed their activities rapidly and so they were encouraged for early ambulating and discharge from the hospital. Blood loss was minimal and did not necessitate replacement during or after surgery.

Interpretation of TMJ scanning using MRI pre-distraction and post-distraction consolidation phase of the mandibular body lengthening through the following:

1. Disk position: Pre-operatively, 4 (40%) patients had unilateral ADDWR (anterior disk displacement with reduction), four joints (40%) patients had unilateral post-ankyrotic joint and two patients (20%) was normal TMJ. Postoperatively, 60% of TMJs showed normal closed and opened

disk position. There was improvement of the two cases of ADDWR (Figure 4).

2. Disk morphology: Pre-operatively, the TMJs of all cases showed normal disk morphology except the four cases which had unilateral post-ankyrotic joints. Postoperatively, all TMJs showed normal disk morphology except the four unilateral post-ankyrotic joints (Figure 5).

3. Condylar morphology: Pre-operatively, the TMJs of all cases showed normal condylar morphology except the four cases had unilateral post-ankyrotic joints. Postoperatively, all TMJs showed normal condylar morphology except the four cases had unilateral post-ankyrotic joints.

4- Glenoid fossa morphology: Pre-operatively; the TMJs of all cases showed normal glenoid fossa morphology except the four cases which had unilateral post-ankyrotic joints.. Postoperatively, all TMJs showed normal glenoid fossa morphology except the four cases with unilateral post-ankyrotic joints.

5- Bone marrow edema and effusion: Pre-operatively, all cases showed absent of bone marrow edema and effusion. Postoperatively: all cases showed absence of bone marrow edema and effusion. As mentioned in table (1) .

TABLE (1) MRI fining of disk (position, morphology, and mobility), morphology of the condyle, articular eminence, glenoid fossa, joint effusion, and edema of the medullary bone.

1- MRI findings of Disk position	Patients No.=10, & % (Pre-operative)	(Patients No.=10, & % Post-operative)
Normal: No. (%)	2 (20%)	6 (60%)
Unilateral post-ankylotic joint (%)	4 (40%)	4 (40%)
ADDWR: No (%)	4 (40%)	0 (0%)
2- MRI findings Disk morphology	Patients No.=10 , & % (Pre-operative)	Patients No.=10, & %9 (Post-operative)
Normal morphology: No. (%)	6 (60%)	6 (60%)
The four unilateral post-ankylotic joints: No. (%)	4 (40%)	4 (40%)
3- MRI findings condylar morphology	Patients No.=10 , & % (Pre-operative)	Patients No.=10 , & % (Post-operative)
Normal morphology: No. (%)	6 (60%)	6 (60%)
The four unilateral post-ankylotic joints: No. (%)	4 (40%)	4 (40%)
4- MRI findings glenoid fossa morphology	Patients No.=10 , & % (Pre-operative)	Patients No.=10 , & % (Post-operative)
Normal morphology: No. (%)	6 (60%)	6 (60%)
The four unilateral post-ankylotic joints: No. (%)	4 (40%)	4 (40%)
5- MRI findings Bone marrow edema and Effusion	Patients No.=10, & % (Pre-operative)	Patients No.=10 , & % (Post-operative)
Present: No. (%)	0 (0%)	0 (0%)
Absent: No. (%)	10 (100%)	10 (100%)

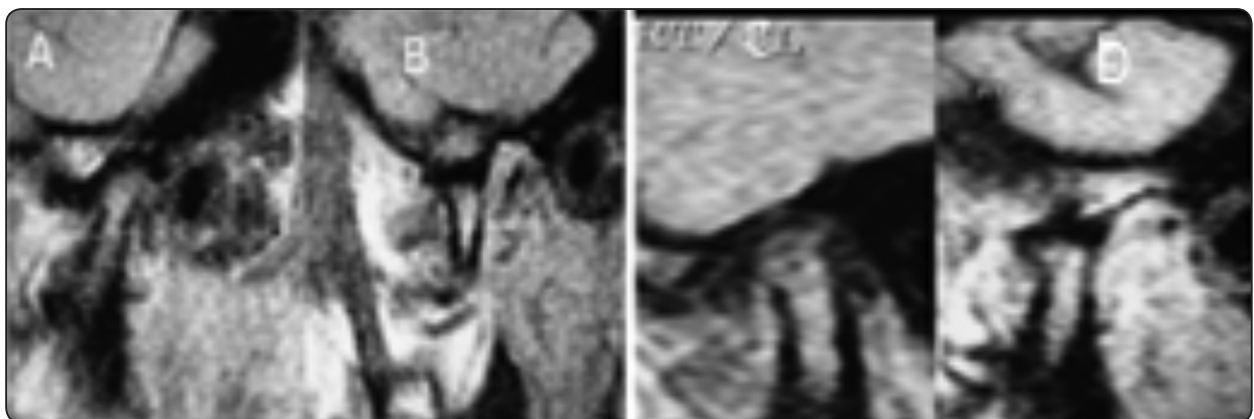

Fig. (4) *MRI images showing ADDWR of Rt. Joint.* A- Pre-operative T1 closed sagittal cut showing ADDWR. B- Pre-operative T1 opened sagittal cut. C- Postoperative T1 closed sagittal cut showing correction of ADDWR. D- Postoperative T1 opened sagittal cut.

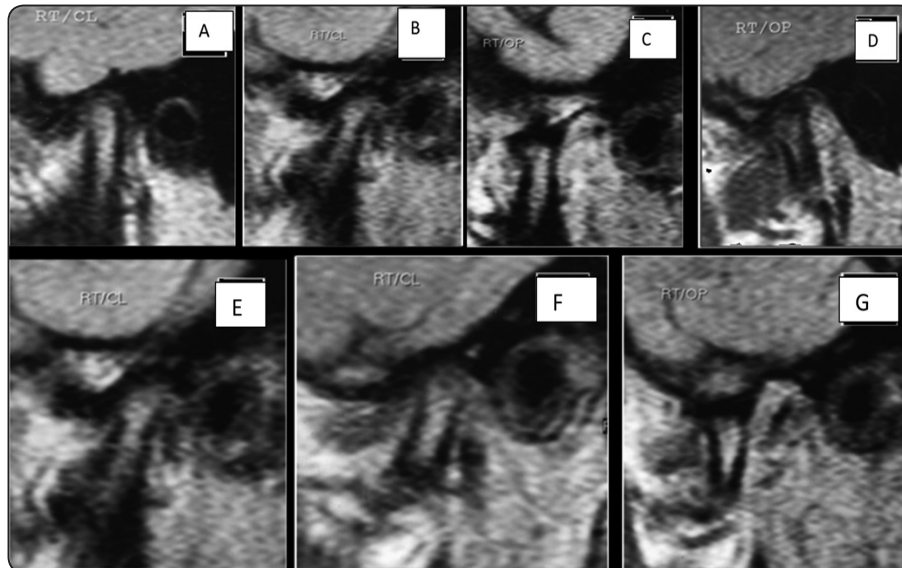


Fig. (5) MRI images of sagittal cuts showing normal Rt. Joint. (A and B) pre-operative sagittal cut showing closed disk positions of joint. (C and D pre-operative) sagittal cut showing open joint. (E and F) Postoperative sagittal cuts showing closed joint. (G) Postoperative sagittal cut showing open joint.

DISCUSSION

During mandibular distraction, although the body of the mandible receives a direct stretch, the distant condyle against the articular fossa undergoes indirect compression. During lengthening of the mandible, the proximal segment with the condyle may be moved back ward and exert stress on the condyle surface. Compressive loading may induce alterations in the disk, condyle, and disk-condyle relationship, and posterior displacement of the condyle could result in degenerative changes in the articular cartilage. Consequently, there has been a great concern that mandibular osteodistraction may create TMJ problems with a distraction rate of 0.10 to 1.0 mm/day.⁵⁻⁷

Articular cartilage in the condyle that is covered with fibrous connective tissue has more adaptive potential, because it helps the TMJ to withstand environmental stress to a better extent than other long bone fibrous joints. However, if compressive forces resulting from distraction exerted on the condyle are beyond the adaptive capacity of the TMJ, degeneration or damage to the cartilage will occur.⁸⁻¹⁰

Zou et al¹¹ and Liu et al.¹² were studied the distraction rate and inflammatory changes in temporomandibular joint (TMJ) and reported that; a distraction rate of 2 mm/day caused degenerative or inflammatory alterations of the condyle and cartilage in white rats. In our study the distraction rate was 1mm/d and there were a little morphological change.

Salvoldelli et al¹³ performed a study to predict stress modification in the temporomandibular joint (TMJ) after symphyseal distraction. The study was done using three-dimensional finite element analysis using a complete mastication model. Geometric data were obtained from MRI and CT scans of a healthy male patient and each component was meshed as various regions. The distraction was performed with a 10 mm expansion after simulation of a surgical vertical osteotomy line on the model in the mandibular midline region. Boundary conditions for jaw closing simulations were represented by different jaw muscle load directions. Stress distributions in both joint disks and condyles during closing conditions were analyzed and compared before and after distraction. Stress distribution

was similar in disks and on condylar surfaces in the pre-operative- and post-distraction models. The outcomes of this study suggest that anatomical changes in TMJ structures should not predispose to long-term tissue fatigue and demonstrate the absence of clinical permanent TMJ symptoms after distraction.

In addition, Norhalt et al ¹⁴ stated that function of the TMJs and muscles were temporarily impaired during the first 6 months following osteodistraction performance. After this period, most variables returned to their preoperative level or improved. These results had emphasized results in our study that showed improvement in two cases of anterior disk displacement after distraction.

Kristina Andersen et al; ¹⁵ were studied a systematic review of animal experimental studies following mandibular distraction osteogenesis on the temporomandibular joint and found that macro-morphologic changes (e.g., condylar size reduction in the antero-posterior dimension, up righting of the condyle relative to the occlusal plane, increased convexity of the condyle in the antero-posterior dimension, and site specific flattening of the condyle) were frequently observed after high daily distraction rates. The macroscopic change of the condyle after DO may be considered as an adaptation of bone to meet new functional demands and can be anticipated to be consistent with the findings of changes in bony metabolism. These results were matched with the result of the current study.

CONCLUSION

We can conclude that; comparing pre-operative- and post-distraction MRI of TMJ; there was no morphological effect on TMJ following mandibular body distraction osteogenesis; on the other hand there was improvement of cases suffered from anterior disk displacement with reduction (ADDWR) following distraction osteogenesis (DO).

ACKNOWLEDGMENT

The authors thank Dr. ALaa Othman for his efforts and co-working in this research study.

CONFLICT OF INTEREST

The Authors declare No conflict of interests.

REFERENCES

- 1- Molina, F.: Combined maxillary and mandibular distraction osteogenesis. *Semin Orthod*, 10:41, 1999.
- 2- Myron, R.: Management of temporomandibular disorders, in *Contemporary oral and maxillofacial surgery*. Mosby, St. Louis. p. 672, 2003
- 3- Schwartz, H.C.: Transport distraction osteogenesis for reconstruction of the ramus-condyle unit of the temporomandibular joint: surgical technique. *J Oral Maxillofac Surg*, 67:2197, 2009.
- 4- Ellis, E. 3rd, and Hinton, R.J.: Histologic examination of the temporomandibular joint after mandibular advancement with and without rigid fixation: an experimental investigation in adult *Macaca mulatta*. *J Oral Maxillofac Surg*, 49:1316, 1991.
- 5- Ahmad, M., Hollender, L., Anderson, Q., Kartha, K., Ohrbach, R., Truelove, E.L., John, M.T. and Schiffman, E.L.: Research diagnostic criteria for temporomandibular disorders (RDC/TMD): development of image analysis criteria and examiner reliability for image analysis. *Oral Surg Oral Med Oral Pathol Radiol Endod*, 107:844, 2009.
- 6- De Leeuw, R., Boering, G., Stegenga, B. and de Bont, L.G.: TMJ articular disc position and configuration 30 years after initial diagnosis of internal derangement. *J Oral Maxillofac Surg*, 103:234, 1991.
- 7- Rao, V.M., Farole, A. and Karasick, D.: Temporomandibular joint dysfunction: correlation of MR imaging, arthrography and arthroscopy. *Radiology*, 174:663, 1990.
- 8- Farhadieh, R.D., Gianoutsos, M.P., Dickinson, R. and Walsh, W.R.: Effect of distraction rate on biomechanical, mineralization, and histologic properties of an ovine mandible model. *Plast Reconstr Surg*, 105:889, 2000.
- 9- Troulis, M.J., Glowacki, J., Perrott, D.H. and Kaban, L.B.: Effects of latency and rate on bone formation in a porcine mandibular distraction model. *J Oral Maxillofac Surg*, 58:507, 2000.

- 10- Ko, E.W., Hung, K.F., Huang, C.S., Chen and P.K.: Correction of facial asymmetry with multiplanar mandible distraction: a one-year follow-up study. *Cleft Palate Craniofac J*, 41:5, 2004.
- 11- Zou, S., Hu, J., Wang, D., Li, J. and Tang, Z.: Changes in the temporomandibular joint after mandibular lengthening with different rates of distraction. *Int J Adult Orthodon Orthognath Surg*, 16:221, 2001.
- 12- Liu, C.M., Liang, L.M., Song, R.Y., Hou, M. and Ma, X.: Sutural distraction osteogenesis for primary cleft palate repair: a pre-operative liminary clinical report. *Zhonghua Zheng Xing Wai Ke Za Zhi*, 19:261, 2003.
- 13- Savoldelli, C., Bouchard, P.O., Manière-Ezvan, A., Bettega, G. and Tillier, Y.: Comparison of stress distribution in the temporomandibular joint during jaw closing before and after symphyseal distraction: a finite element study. *Int J Oral Maxillofac Surg*, 41:1474, 2012.
- 14- Norholt, S.E., Pedersen, T.K. and Herlin, T.: Functional changes following distraction osteogenesis treatment of asymmetric mandibular growth deviation in unilateral juvenile idiopathic arthritis: a prospective study with long-term follow-up. *Int J Oral Maxillofac. Surg*, 42:329, 2013.
- 15- Kristian, A., Thomas, K.P., Ellen, M.H., and Sven, E.: Effect of mandibular distraction osteogenesis on the temporomandibular joint: a systematic review of animal experimental studies. (*Oral Surg Oral Med Oral Pathol Oral Radiol* 117:407- 415, 2014.