



THE KEY: A PILOT STUDY OF A NOVEL TECHNIQUE FOR CONSERVATIVE EXTRACTION OF REMAINING ROOTS

Tadros Ramsis Marcos Kaiser* and Ahmed Tarek Mostafa Elsharkawy**

ABSTRACT

Objectives: The aim of the present study was to determine if the Key can be easily used to extract remaining roots, and to assess the clinical outcome.

Study design: Five patients with remaining roots not suitable for forceps extraction were enrolled in this study, and had their remaining roots extracted using a novel atraumatic extraction system "The Key". Patients were evaluated clinically one week post-operatively.

Results: All the roots were successfully extracted, with average time 25 minutes. No patient complained from excessive intra-operative or post-operative pain, swelling or bleeding. All sockets evaluated one week post-operative showed uneventful soft tissue healing.

Conclusions: The Key may be successfully used for atraumatic extraction of remaining roots. Further studies are recommended with more number of cases, different surgeons, and comparison with other techniques.

INTRODUCTION

In spite of the major advances in dental science we still can't prevent tooth extraction in some cases. Surveys showed that number of extractions made by dentists were 6.6 per week ^(1, 9, 14). Reasons for teeth extraction included: dental caries (51%), periodontal disease (21%), orthodontics (11%) and failed endodontics (4%). Trauma, pericoronitis and other reasons accounted for 5.5% of extractions, with teeth being extracted at the patient's request in preference to other treatments on (7.5%) occasions ⁽⁹⁾.

Many extractions needs surgical intervention especially for remaining roots and third molars. This leads to excessive trauma causing excessive swelling and pain and many complications such as bone fracture, excessive bleeding, wound infection and dry socket. ⁽²⁾

The extraction of teeth by standard techniques or the surgical removal of retained root fragments by conventional surgical methods (elevators and forceps) may result in damage to the labial plate of alveolar bone ⁽¹⁸⁾. Bone resorption following tooth extraction is one of the most important complications

* BDS, Ain Shams University. CEO and Founder of Roman's Clinic.

** Lecturer of Oral and Maxillofacial Surgery, Cairo University. Visiting Lecturer of Oral and Maxillofacial Surgery, Ahram Canadian University.

as it jeopardize implant placement and reconstruction, a systematic review by Tan et al⁽¹⁵⁾ showed that horizontal bone loss of 29- 63% and vertical bone loss of 11- 22% occurs after 6 months following tooth extraction, studies⁽¹⁶⁾ demonstrated rapid reductions in the first 3 to 6 months that was followed by gradual reductions in dimensions thereafter. The preservation of an intact labial plate during extraction is a critical factor whether an immediate implant can be placed or not, and also a determinant of the esthetic results⁽¹⁷⁾, which reinforce the importance of atraumatic tooth extraction.

A lot of interventions lately were introduced to the market trying to decrease this complications such as the use of rotary burs, periostomes^(3,20), using endo H-files⁽⁵⁾, physics forceps^(6, 23) piezoelectric devices^(4, 17), the Easy X-Trac System (Titan Instrument, Hamburg, NY)⁽⁷⁾, and removal of the root fragments with the implant drills during implant site preparation⁽¹⁹⁾.

Although several different "atraumatic" techniques with or without the use of special instruments have been proposed^(11, 12, 14) most of them still traumatize the bone to some extent. The only possible exceptions are extraction methods that apply an orthodontic force, resulting more in an exfoliation rather than extraction of the tooth⁽²⁹⁾.

So we thought to introduce a new technique "The Key", we made a post with large head for root anchorage, a periostome like instrument to cut periodontal ligaments and a crossbar like instrument "The Key" to raise the root .

AIM OF THE STUDY

The aim of this study was to determine if the Key can be easily used to extract remaining roots, and to assess the clinical outcome.

PATIENTS AND METHODS

Five patients requiring extraction of remaining roots were selected from outpatient clinic, oral and

maxillofacial surgery department, faculty of Oral and Dental Medicine, Cairo University.

Inclusion criteria: All of the roots requiring extraction were molars or premolars for males or females patients. Age of patients should be between 18-50 years old.

Exclusion criteria: Each patient was asked about medical history and medication(s) taken to exclude any condition that may affect healing like uncontrolled diabetes, excessive smoking, bone diseases, radiotherapy and bisphosphonate medications. Clinical examination was made for each patient to make sure selected roots were not suitable for forceps extraction.

Then each patient made a periapical x-ray to assess root length, direction, curvature, decay, periapical pathology, approximation to vital structures (like maxillary sinus, and inferior alveolar canal), roots fusion in case of multirouted teeth, and other findings like ankylosed roots or calcified canals.

Local anesthesia was administered in traditional techniques (IANB for mandibular molars and premolars, and infiltration for remaining teeth) patients received one cartridge of Articaine 4% with adrenalin 1:100000.

Then a heavy rubber base impression was taken for teeth adjacent to root to be extracted without a tray, distal for roots directed mesially, and mesial for roots directed distally.

Periodontal ligament of the roots were severed cervically and as apical as possible using periostomes, modification of periostomes was made previously by bending to add angle to the blade for more accessibility in posterior and curved roots (Fig. 1A). Fused roots were separated using surgical fissure burs with coolant.

Root canal of each remaining root was widened using H-File for narrow canals, and drills for wide canals. Then a stainless steel post was inserted in

the canal till it is properly engaged. These posts were modified previously by heat welding a head like component to them to allow gripping by “The Key”, and they had 2 different sizes depending on canal size (Fig. 1B).

The Key is then used, (Fig. 1C). It’s a cross bar like instrument, with key-like working end, that rests on the rubber base cushion, engage the head of the post, and then rotated by hand-force to extract the remaining root (Fig. 2).

Each patient then received a gauze pack to bite on for one hour, and traditional post-extraction instructions were given. Patients were asked to return after 1 week for clinical follow up.

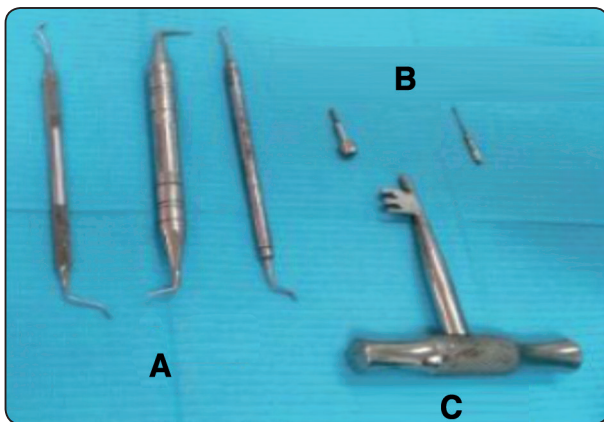


Fig. (1) A photograph showing instruments used in the technique: A) The modified periotomes. B) The modified posts. C) The Key.

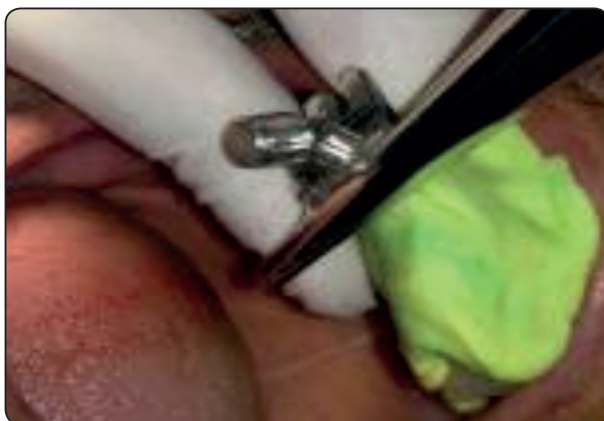

Fig. (2) A photograph showing “the Key” resting on the rubber base and engaging the post head.

Five patients were enrolled in this study, with total number of 9 remaining roots extracted, all of them were molars or premolars. Three of the patients were males and 2 females, age ranged from 25 to 55 with average 45 years.

Clinical application of the technique was easy and acceptable for the patients, none of them complained from pain or excessive pressure. Time taken from starting local anesthesia administration till root delivery ranged from 15 to 35 minutes, with average of 25 minutes. All roots were successfully extracted, and no intraoperative complications (like pain, root fracture, displacement, or bleeding) were noted.

During the one week postoperative follow up all patients reported no swelling or excessive bleeding, only 1 patient reported pain requiring analgesic in the 1st day following extraction. Clinical examination showed uneventful healing with no signs of infection, inflammation or dry socket formation.

DISCUSSION

Several techniques have been introduced for conservative extraction. Periotomes have been successfully used to sever the periodontal ligament fibers and allow atraumatic tooth extraction. Disadvantages when using periotomes are encountered when the force required to advance the instrument fractures the tip of the instrument and/or traumatizes the adjacent soft tissues ^(3,20), and yet they couldn't deliver roots out of the socket.

A powered periotome (powertome 100s, Westport Medical Inc., Salem, OR, USA) has been developed that allows for the precise extraction of a tooth while producing minimal or no alveolar bone loss. It allows precise control over the quantity of force that the periotome tip exerts and the distance it travels into the PDL space ⁽²⁷⁾. However, it requires a special equipment with high cost, and it's not widely available. Unlike “The Key” which is made of local, available cheap instruments.

The use of the SIBS (Sonic handpiece SF1LM; Komet, Rock Hill, SC) might require long operations, the SIBS appears to provide better tactile control, be safer for the integrity of the surrounding tissues as nerves and blood vessels, and be an efficient instrument for atraumatic tooth extraction⁽¹⁹⁾. However, according to Papadimitrou et al⁽¹⁷⁾ a disadvantage of SIBS is that if it is deformed while it oscillates into the periodontal ligament, then the risk of fracture is high. Common complications to sonic, ultrasonic and SIBS instruments included interfering with the function of older cardiac pacemakers⁽²¹⁾. Finally, ultrasonic devices should not be used on patients with known infectious diseases that can be transmitted by aerosols⁽¹⁷⁾, the water spray creates a contaminated aerosol that fills the operating area, exposing personnel and surfaces. The Key overcome these disadvantages.

The physics forceps is a device that use a first-class lever mechanism for atraumatic extraction of a tooth from its socket⁽⁶⁾, It caused less pain in the 1st postoperative day, and no need for raising a mucoperiosteal flap or using elevators which is a major advantage. However, it needs a definite learning curve because the method of delivering the tooth is different than the conventional forceps⁽²⁵⁾, there is still 22% incidence of fracture of the bony plate compared to 25% in conventional forceps⁽²³⁾, and it can't be applied if there is no enough lingual grip.

Removal of canines and premolars in linguover-sion is a challenge, as the use of an elevator and forceps is difficult because of the lingual tilt and adjacent teeth contact⁽²⁶⁾. The use of "The Key" in such cases may be beneficial as it doesn't require any force on adjacent teeth, also the technique is helpful when the adjacent tooth has a large resto-ration or periodontally affected and there is a risk of its dislodgement if forceps or elevators are used, further studies are planned to test this point.

A similar system called "Benex extractor" (by Helmut Zepf Medizintechnik, Tuttlingen, Germany,

and Bien-Air Dental, Bienne, Switzerland) was evaluated in a recent study⁽⁷⁾. The system demonstrated a high success rate (89%) for the atraumatic extraction of severely decayed teeth not suitable for forceps extraction. However, only 43% of multirooted teeth were successfully extracted. Extraction failure was mostly associated with insufficient retention or misplacement of the screw and root fracture. While in the current study, most of the extractions were multirooted teeth, and none of them showed root fractures⁽⁷⁾.

Recent recommendations regarding patients under anticoagulants requiring extraction stated that the relative risk of a thromboembolic event if warfarin is discontinued is less than that of experiencing excessive oral bleeding if warfarin is continued⁽²²⁾. Also long-term aspirin therapy shouldn't be stopped before tooth extraction⁽²⁴⁾, which emphasize the importance of such a conservative technique that don't require flap reflection or excess bleeding.

According to Okabe et al⁽²⁸⁾ when the volume of blood lost during surgery was >50 ml and the time required for the operation exceeded 100 min, the occurrence of bacteremia was higher. This makes "The Key" an important technique for immunocompromised patients, those who had radiotherapy, bisphosphonates, or having risk of bacterial endocarditis.

However, this is just a pilot study, number of cases are limited, only one surgeon performed the operations, no radiographic interpretation was made to assess bone healing, and no comparison with other techniques is made yet.

CONCLUSIONS

The Key may be successfully used for atraumatic extraction of remaining roots. The technique is easy, effective, uses few instruments, and obviates the need for open extraction. However, further studies are recommended with more number of cases, different surgeons, radiographic interpretation for bone healing and comparison with other techniques.

REFERENCES

- 1- P.M Cahen, R.M Frank and J.C Turlot: A survey of the reasons for dental extractions in France. *Journal of dental research* 64:1087, 1990.
- 2- Jaafar N and Nor GM: The prevalence of post-extraction complications in an outpatient dental clinic in Kuala Lumpur Malaysia – a retrospective study. *Singapore dental Journal* 23(1):24, 2000.
- 3- Sneha D. Sharma, B. Vidya, Mohan Alexander and Sunny Deshmukh: Periosteal as an aid to atraumatic extraction: a comparative double blinded randomized controlled trial. *J Maxillofac Oral Surg* 14(3): 611, 2015.
- 4- Cornilio Blus and Szmukler –Moncler Serge: Atraumatic tooth extraction and immediate implant placement with piezosurgery: evaluation of 40 sites after at least 1 year of loading. *The international J. of periodontics and restorative dentistry* 30 (4): 355, 2010.
- 5- V. Sadesh Kannan, G. R. sathya and C. Danavel: A new atraumatic method of removing fractured palatal root using endodontic H-files luted with resin modified Glass Ionomer cement: a pilot study. *Journal of pharmacy and Bioallied sciences* 6 (1):156, 2014.
- 6- Soumen Manadal: Collate on the ability of physics forceps verses conventional forceps in multirrooted mandibular tooth extractions. *J. of dental and medical science* 14 (3):63, 2015.
- 7- Egon Muska, Clemens Walter, Alan Knight, Pankaj Taneja, Yogesh Bulsara, Michael Hahn, Mayur Desai and Thomas Dietrich: Atraumatic vertical tooth extraction: a proof of principle clinical study of a novel system. *J. of oral and maxillofacial surgery* 116 (5)5:303, 2013.
- 8- Kay EJ and Blinkhorn AS: The reasons underlying the extraction of teeth in Scotland. *British Dental Journal* 160:287, 1986.
- 9- I.G. Chestnutta, V.I. Binnieb and M.M. Taylo: Reasons for tooth extraction in Scotland. *Journal of Dentistry* 28: 295, 2000.
10. Angelillo IF, Nobile CGA, Pavia M: Survey of reasons for extraction of permanent teeth in Italy. *Community Dentistry and Oral Epidemiology* 24:336, 1996.
11. Murray H, Locker D, Kay EJ. Patterns of and reasons for tooth extractions in general dental practice in Ontario, Canada. *Community Dentistry and Oral Epidemiology* 24:196, 1996.
12. Hull PS, Worthington HV and Clerehugh V: The reasons for tooth extractions in adults and their validation. *Journal of Dentistry* 25:233, 1997.
13. Angerholm DM, Sidi AD: Reasons given for extraction of permanent teeth by general dental practitioners in England and Wales. *British Dental Journal* 164:345, 1988.
14. Reich E, Hiller KA: Reasons for tooth extraction in the western states of Germany. *Community Dentistry and Oral Epidemiology* 21:379, 1993.
15. Tan wl, wong TIT, wong MCM, lang NP: A systematic review of post extractional alveolar hard and soft tissue dimensional changes in humans. *Clin Oral Implants Res* 23(5):1, 2012.
16. Hammerle D, Araujo MG, Simion M: On Behalf of the Osteology Consensus Group 2011. Evidence-based knowledge on the biology and treatment of extraction sockets. *Clin Oral Implants Res* 23(5):80, 2012.
17. Dimitrios E.V. Papadimitriou, Alessandro Geminiani, Thomas Zahavi, and Carlo Ercoli: Sonosurgery for atraumatic tooth extraction: A clinical report. *J Prosthet Dent* 108:339, 2012.
18. Babbush CA: A new atraumatic system for tooth removal and immediate implant restoration. *Implant Dent* 16:139, 2007.
19. Yalcin S, Aktas I, Emes Y, Kaya G, Aybar B and Atalay B: A technique for atraumatic extraction of teeth before immediate implant placement using implant drills. *Implant Dent* 18:464, 2009.
20. Quayle AA: Atraumatic removal of teeth and root fragments in dental implantology. *Int J Oral Maxillofac Implants* 5:293, 1990.
21. Miller CS, Leonelli FM and Latham E: Selective interference with pacemaker activity by electrical dental devices. *Oral Surg Oral Med Oral Pathol Oral Radiol Endod* 85:33, 1998.
22. Balevi B: Should warfarin be discontinued before a dental extraction? A decision-tree analysis. *Oral Surg Oral Med Oral Pathol Oral Radiol Endod* 110:691, 2010.
23. Samyuktha Hariharan, Vinod Narayanan and Chen Loong Soh: Split-mouth comparison of Physics forceps and extraction forceps in orthodontic extraction of upper premolars. *British J OMS* 52: 137, 2014.

24. Bingjie Zhao, Peihuan Wang, Yabing Dong, Yong Zhu, and Huaqiang Zhao: Should aspirin be stopped before tooth extraction? A meta-analysis. *Oral Surg Oral Med Oral Pathol Oral Radiol* 119:522, 2015.
25. N.J. Perkins, H.M. Perez, C.E. Misch and R. Golden: The physics forceps- a breakthrough in dental extraction technology. *Posters/ British J OMFS* 48: 25, 2010.
26. N. Chhabra, S. Chhabra, A. Kaur and Kanak Nadini Jain: Extraction of single-rooted mandibular canines and premolars in linguversion by a modified technique: technical note. *British J OMFS* 53: 387, 2015.
27. White J, Holtzclaw D, Toscano N.: Powertome assisted atraumatic tooth extraction. *J Implant Adv Clin Dent* 1:6, 2009.
28. K. Okabe, K. Nakagawa and E. Yamamoto: Factors affecting the occurrence of Bacteremia associated with tooth extraction. *Int. J OMFS* 24:239, 1995.
29. Regev E, Lustmann J and Nashef R: Atraumatic teeth extraction in bisphosphonate-treated patients. *J Oral Maxillofac Surg* 66:1157, 2008.