

AUTOLOGOUS PLATELET RICH FIBRIN GLUE LOCAL APPLICATION AT FRACTURE LINE IN TREATMENT OF THE MANDIBULAR ANGLE FRACTURES

Heba Mohammad Fayed*

ABSTRACT

Objective: The aim of this study was to evaluate the application of platelet rich fibrin on the outcome of mandibular fracture. **Methods:** This prospective study was carried on 16 patients with mandibular angle fracture with a mean age of 35 years, PRF was applied on fracture line after reduction. **Results:** significantly higher mean of bone density was recorded in PRF group in first and third months postoperatively. **Conclusion:** PRF seems to be attributed to enhance and accelerate bone formation.

INTRODUCTION

Mandibular fractures treatment is frequent therapy introduced by oral and maxillofacial surgeons as it is a common facial injury. Mandibular angle fracture is one of the most common maxillofacial injuries. Factors such as the area of biomechanics, thinner bone cross-sectional area plus the bony structure of this section of the mandible when compared with the dentate part ⁽¹⁾ and the presence of impacted teeth diminishing bone quantity and stability ;all influencing the occurrence of this injury. As a consequence, most cases of mandibular fractures occur commonly at the angle. In edentulous mandibles, however, fractures of the mandibular body, and in children condylar fractures prevail ⁽²⁾. Angle fractures is characterized by the

highest rate of complications of all fractures of the lower jaw ⁽³⁾.

The first goal of management of any bone fracture is to restore function of the fractured bone by complete reunion of the bony segments and re-establish pre-fracture strength of the bone to restore defects of contour that may occur as a consequence of the injury, secondly; to prevent any infection at the fracture site. The treatment of these fractures is controversial. The causes of injury and the significant incidence of complications increase the doubts in the election. There are several trends that vary from orthopedic treatment to open treatment with different types and number of osteosynthesis plates. Fractures of the mandibular angle are plagued with the highest rate of complications of all bandages,

* Lecturer Oral & Maxillofacial Surgery Department, Faculty of Dentistry October 6 University

splints, circum-mandibular wiring, and extra-oral pins. Semi-rigid fixation with transosseous wiring and miniplates to rigid fixation. In recent years the treatment of mandibular fractures has led to the use of operative as well as conservative methods. Apart from conservative measures, several surgical methods may be applied to treat mandibular fractures. There is no general agreement on specific line of treatment for mandibular fractures due to wide variation of osteosynthesis methods in use^(4,5).

Angiogenesis which is supported by cytokines such as platelet derived growth factor (PDGF), fibroblast growth factor (FGF), transforming growth factor beta (TGF- β), vascular endothelial growth factor (VEGF) and bone morphogenic proteins (BMP). These cytokines are all involved in osteogenesis and angiogenesis, platelets contain a large number of growth factors and cytokines that have a key role in bone regeneration and soft tissue maturation^(6,7). Platelet rich fibrin (PRF), developed in France by Choukroun⁽⁸⁾, is a second generation platelet concentrate that accelerate healing of hard and soft tissue. It is characterized by easy preparation and application, less expense and no biochemical modification (without bovine thrombin compared with platelet rich plasma (PRP) that require anticoagulant). PRF is a strictly autologous fibrin matrix containing a large amount of platelet and leukocyte cytokines. Many in vitro studies have assessed the effects of PRF membranes on the proliferation of large variety of cells, and the influence of leukocytes on both cell reactions and growth factors release were already hypothesized

PATIENTS AND METHODS

This is a prospective study carried on 16 patients with mandibular angle fracture with age ranged from 18 to 52 with a mean age of 35 years. Inclusion criteria include patients with mandibular angle fracture (either isolated or associated with

symphyseal, parasymphyseal or body fractures), with displacement of the fracture segments so the surgical intervention is necessary. Treatment was performed within one week of the fracture occurrence. Exclusion criteria include associated condylar, ramus or coronoid fractures, infected, comminuted mandibular fractures, fractures existed for more than one week, non union and malunion fractures and patients with severe systemic diseases that may not represent a good candidate for surgical intervention.

Personal, past medical and past dental history were obtained for each patient, followed by extra and intra oral clinical examination. Radiographic examination include digital panoramic radiographs and computed tomography examination for accurate assessment of number and location of fracture lines, degree of displacement, detection of the inferior alveolar canal and presence of a tooth within the fracture lines. Preoperative preparations including ECG, chest radiographs and coagulation profile were performed for each patient. The patients were informed about the nature of the surgery including the intra-operative and the postoperative complications and a written informed consent was signed by all the patients prior to surgery.

Patients within the current study were equally divided into two groups; patients within group (1) were treated by open reduction and fixation using mini plates followed by application of PRF on fracture line. Patients within group (2) were treated by open reduction and direct osteosynthesis using one or two mini plates.

Operative procedures

Exposure of fractured mandibular angle was performed through a submandibular approach, the fracture segments were reduced using a bone clamp, and fixation was achieved using one or two 2.0 mm miniplates with at least two conventional screws on each side of the fracture line.

Preparation of Platelet rich fibrin (PRF)

PRF was prepared according to the Choukroun's et.al technique, 10 ml of venous blood was collected in a sterile dry glass tube without an anticoagulant, centrifuged immediately at 3000 rpm for 10 minutes, this step is performed twenty minutes before the surgery, then the platelet poor plasma which accumulated at the top was discarded, PRF was carefully dissected approximately 2 mm below its connection to the red corpuscle beneath to include remaining platelets, which have been proposed to localize below the junction between PRF and the red corpuscle. The obtained PRF glue was locally applied at the fracture site for patients within group (1) prior to insertion of the fixation screws.

Post operative assessment

Clinical and radiographic examination was performed immediately postoperative for evaluation of proper reduction of the fracture and stability of the fracture segments. Patients were recalled for up to six months follow up period with one and three months intervals.

During the follow up period, patients were clinically assessed for range of mandibular movements by measuring of the maximum interincisal mouth opening, ensuring proper occlusion by checking maximal intercuspal relationship, presence of postoperative signs of infection related to soft tissue or hardware, stability of the fractured segments, malunion or nonunion.

Radiographic follow up

Digital panoramic radiographs was performed for radiographic evaluation at the follow up intervals. A qualitative analysis: for evaluation of alignment of the fractured segments and fracture line width.

A quantitative analysis: Radiodensitometric analysis were performed to the digitized images using Digora specially designed software.

For standardized selection of the point of interest position to be under investigation, calculation of X and Y exact coordinates for a two points A and B was performed and repeated during the follow up radiographs. The point A was selected at the fracture line and the point B was selected 5 mm at the same level of the first point but located within the sound bone. Then, the pixel density of these two points were measured according to each point's radio-opacity. The bone density (pixel density) was calculated as the difference between the pixel density of the two points (point A) representing at the fracture line and (point B) at sound bone.

RESULTS

Clinical examination of the patients during the follow up period showed an absolute stability of the fracture segments and a uniform smooth inferior border of the mandible in all the treated patients. Wound dehiscence or plate exposure were not observed in any of the treated cases. Postoperative soft tissue infection was detected in two cases within group (2) at one month postoperative which was managed by proper antibiotics. Otherwise the rest of the cases showed a normal healthy covering mucosa and skin of normal color and texture. Only one patient of group (1) complained of numbness of the lower lip which resolved completely and normal

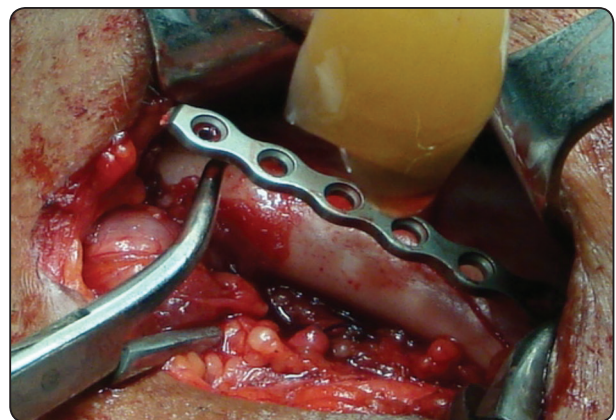


Fig. (1) A photograph showing application of PRF at mandibular fracture

sensations were regained after three months of the follow up period.

Radiographic findings immediately , one , three and six months postoperatively revealed properly reduced fractured segments with narrowing of the interfragmentary gap which became more evident at three and six months post-operative .

(I) Pixel density measurement

From the data represented in table (1) it could be noticed that the mean and standard deviation of bone mineral densities (BMD) for the two groups showed an increase in BMD in both groups at different follow up intervals .

Comparison between groups

Point A: There was no significant difference between groups immediately post-operative and after 6 months. However at one and 3 months, significantly higher mean was recorded in group 1 (p= 0.00), (Table 1, Fig.2)

Point B: There was no significant difference between groups immediately post-operative and after 1, 3 and 6 months (Table 1, Fig.2)

Difference in mineral bone density (B-A): There was no significant difference between groups immediately post-operative and after 6 months. However at one and 3 months, significantly higher mean was recorded in group 2 (p= 0.00), (Table 1, Fig.3)

TABLE (1) Pixel density measurement: Comparison within (repeated measures ANOVA) and between groups (independent t test).

		Group 1		Group 2		t	P (between groups)
		Mean	Std Dev	Mean	Std Dev		
Point A	Immediate Post-operative	16.48 ^c	5.18	16.48 ^d	5.18	0.00	1.00ns
	One.month	145.54 ^b	37.47	43.41 ^c	7.45	7.56	0.00*
	Three.months	243.36 ^a	5.47	115.73 ^b	9.53	32.86	0.00*
	Six.months	247.23 ^a	5.14	247.23 ^a	5.14	0.00	1.00ns
	F	253.34		1709.41		-----	
	P (within group)	0.00*		0.00*			
Point B	Immediate Post-operative	249.25	4.27	248.41	5.94	0.32	0.75ns
	One.month	249.25	4.27	250.39	4.00	-0.55	0.59ns
	Three.months	249.25	4.27	249.29	6.20	-0.01	0.99ns
	Six.months	249.25	4.27	249.24	6.10	0.00	1.00ns
	F	0		0.17		-----	
	P (within group)	1ns		0.92ns			
Difference (Point B-Point A)	Immediate	232.78 ^a	4.32	231.94 ^a	5.87	0.32	0.75ns
	1 month	103.71 ^b	37.53	206.98 ^b	5.41	-7.70	0.00*
	3months	5.89 ^c	2.61	133.56 ^c	6.06	-54.73	0.00*
	6 months	2.03 ^c	2.59	2.01 ^d	5.96	0.01	1.00ns
	F	261.50		2507.42		-----	
	P (within group)	0.00*		0.00*			

Significance level $P \leq 0.05$, *significant, ns=non-significant Tukey's post hoc test: Within the same comparison, means sharing the same superscript letter are not significantly different

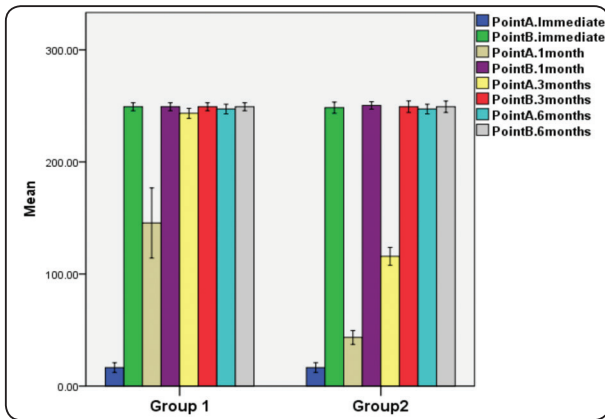


Fig. (2) Bar chart illustrating mean mineral bone density in both groups in different observation times

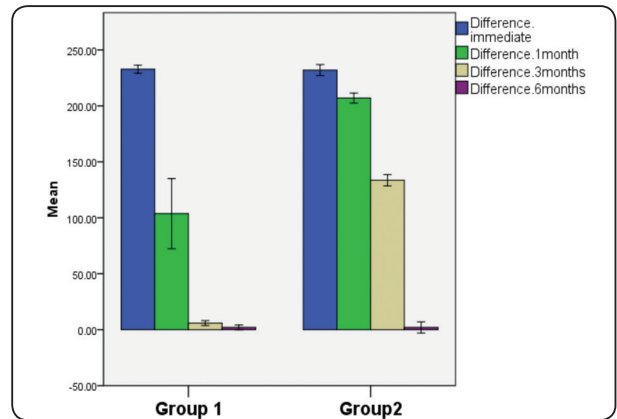


Fig. (3) Bar chart illustrating mean difference in mineral bone density in both groups in different observation times

(II) Maximum interincisal opening

Comparison between groups

By measuring maximum interincisal mouth opening, it could be noticed that records increased by time in both groups with mean and standard deviation 181.24 in group 1 and 189.63 in group 2 .

There was no significant difference between groups pre-operatively, immediately post-operative and after 1, 3 and 6 months post-operatively.

DISCUSSION

The current study showed that the mean bone density in the PRF group was higher than the control group. This finding proved to be statistically significant throughout the follow up period but the percentage change in the bone density from immediate postoperative to 1 months and from 3 to 6 months was not statistically significant comparing the two groups. This means that the mean bone density is significantly higher in the study group but the pattern of improvement is nearly the same throughout one and three intervals comparing the two groups. This comes in agreement with Al Rayess et al. (9) who proved that the mean bone density is significantly higher in the PRF group more than control group but the pattern of improvement

is nearly the same throughout follow up time up to 6 months comparing the two groups following treatment of bilateral mandibular fractures using miniplates with and without PRF membrane.

Dülgeroglu(10) concluded that PRF increases the amount of osseous tissue formation and is efficient in fracture healing after evaluating the effect of PRF on long bone healing in experimental rat model. Which come in accordance to our study.

Al.Khawlani et al.(11) conducted a study to evaluate the validity of application of the PRF versus PRP on the outcome of treatment of the mandibular fracture. They concluded that PRP and PRF seems to accelerate healing bony mandibular fractures, but PRF more efficient than PRP in bone formation.

Cieslik-Bielecka et al.(12) measured the bone density after removal of mandibular odontogenic cysts and application of platelet-rich gel and found a statistically significant increase in bone density measurements at 3 and 6 months after surgery (34% and 41%, respectively) in accordance to our results.

Moreover, our findings was in agreement with that of Shi Zhu et al.(13) who evaluated bone formation in bone tissue engineering by performing histomorphometric analysis to compare the effects of PRP and platelet-enriched fibrin glue. They found

that the nodules contained $14.9 \pm 4.1\%$ newly formed bone when using PRP and $19.8 \pm 3.6\%$ newly formed bone when using platelet-enriched fibrin glue.

The effect of PRF which is used frequently during bone tissue-engineering experimentations concluding that the fibrin content of PRF appears to be a relevant matrix to enhance osteoblast cells growth and differentiation⁽¹⁴⁾. The high contents of growth factor in PRF seems to be attributed to the architecture and intrinsic nature of the PRF biomaterial and because most platelets were activated in the PRF clots (this is the definition of PRF)⁽¹⁵⁾.

REFERENCES

1. Tevepaugh D. B., Dodson T. B.: Are mandibular third molars a risk factor for angle fractures?: *J Oral Maxillofac Surg*; Vol 53,6;646-649, 1995.
2. Lamberg MA, Tasanen A, Kotilainen R : Maxillofacial fractures caused by assault and battery: victims and their injuries. *Proc Finn Dent Soc* 71:162-175, 1975.
3. Ellis E III. Treatment methods for fractures of the mandibular angle. *Int J Oral Maxillofac Surg* ;28:243-252, 1999.
4. Ellis E. III, Walker L. R.: Treatment of Mandibular Angle Fractures Using One Noncompression Miniplates. *J Oral Maxillofac. Surg* ; 54:864-871, 1996.
5. Ellis E.III. :Rigid skeletal fixation of fractures. *J Oral Maxillofac. Surg*; 51:163-173, 1993.
6. Dohan Ehrenfest DM, Diss A, Odin G, Doglioli P, Hippolyte MP, Charrier JB. In vitro effects of Choukroun's PRF (platelet rich fibrin) on human gingival fibroblasts, dermal prekeratinocytes, preadipocytes and maxillofacial osteoblasts in primary cultures. *Oral Surg Oral Med Oral Pathol Oral Radiol Endod*; 108:341-352, 2009.
7. Dohan Ehrenfest DM, Del Corso M, Diss A, Mouhyi J, Charrier JB. Three-dimensional architecture and cell composition of a Choukroun's platelet-rich fibrin clot and membrane. *J Periodontol*; 81:546-555, 2010.
8. Choukroun J, Adda F, Schoeffler C, Vervelle A.: Opportunities in Implant Dentistry: PRF (french). *Implantodontie* ;42:e62, 2001.
9. Al Rayess A. M., El Diban M. M., Melek L. N.:Clinical and radiographic study of healing of mandibular fractures using plasma rich fibrin membrane with miniplate fixation. *Alexandria Dental Journal* Vol.43 Pages:41-47 41, 2018.
10. Dülgeroglu TC, Metineren H. Evaluation of the Effect of Platelet-Rich Fibrin on Long Bone Healing: An Experimental Rat Model. *Orthopedics*. 40: e479-84. 2017.
11. Al-Khawlani E, Adly OA, Hamed TA, Abass AH, Abdelmabood AA. Clinical and radiographic evaluation of platelet-rich fibrin gel on the outcome of mandibular fracture. *Egyptian J Oral Maxillofac Surg*. 5: 77-83, 2014.
12. Cieslik-Bielecka A, Bielecki T, Gazdzik TS, Cieslik T, Szczepanski T. Improved treatment of mandibular odontogenic cysts with platelet-rich gel. *Oral Surg Oral Med Oral Pathol Oral Radiol Endod*;105:423-9, 2008.
13. Shi Zhu SJ, Choi BH, Jung JH, Lee SH, Huh JY, You TM, Li J. A comparative histologic analysis of tissue-engineered bone using platelet-rich plasma and platelet-enriched fibrin glue. *Oral Surg Oral Med Oral Pathol Oral Radiol Endod*; 102:175-179, 2006.
14. Ng AMH, Saim AB, Tan KK, Tan GH, Mokhtar SA, Rose IM, Idrus RBH. Comparison of bioengineered human bone construct from four sources of osteogenic cells. *J Orthop Sci*; 10:192-199, 2005.
15. Igarashi A, Segoshi K, Sakai Y, Pan H, Kanawa M, Higashi Y, Kato Y. Selection of common markers for bone marrow stromal cells from various bones using real-time RT-PCR: effects of passage number and donor age. *Tiss Eng*; 13:2405-2417, 2007.