



CORRELATION BETWEEN BONE DENSITY OBTAINED BY CBCT AND PRIMARY STABILITY OF SINGLE MIDLINE IMPLANT USED TO RETAIN MANDIBULAR OVER DENTURE IN ELDERLY EDENTULOUS PATIENTS

Ahmed M. Abd Alsamad * and Ahmed Fayyad **

ABSTRACT

Introduction: Implant retained over-dentures are widely used for the rehabilitation of edentulous mandible to increase over-denture retention and stability. Implant stability can be measured by various non-invasive clinical test methods as resonance frequency analysis using Osstell. CBCT is widely used in dentistry specially in implant planning but without accurate information about bone density. However, with this increased usage of CBCT in dental field especially in implantology, the predictability of primary implant stability from CBCT image is of great value for oral implantologists.

Methodology: Twenty two completely edentulous patients were included in our study. After performing the conventional steps of complete denture construction, the patients were imaged by CBCT using Planmeca ProMax® 3D Mid (Planmeca, Helsinki, Finland). A virtual implant was placed in the potential implant site in a position simulating the planned position of implant in the midline of mandible and the bone density in the potential implant site (inside) and 1mm around the implant (outside) was assessed. After implant installation, the primary stability was assessed using radiofrequency by the osstell device.

Results: There was non-statistically significant direct correlation between bone density (for both inside and 1mm surrounding the potential implant site) and primary implant stability.

Conclusion: Within the limitation of our study, no correlation was found between bone density measured from cone beam CT and primary stability measured by Osstell in elderly edentulous patients receiving single midline implant

KEYWORDS: CBCT – primary implant stability - bone density

* Lecturer of Oral And Maxillofacial Radiology, Faculty of Oral and Dental Medicine, Cairo University.

** Lecturer of Prosthodontics, Faculty of Oral and Dental Medicine, Cairo University.

INTRODUCTION

Implant retained over-dentures are widely used for the rehabilitation of edentulous mandible. The use of implants increases over-denture retention and stability and enhances patient masticatory function which reduces the rate of bone resorption by regulating the neuromuscular adaptation^(1,2).

The use of at least two implants to support a mandibular over-denture for edentulous patients was recommended by the York consensus statement. However, economic as well as medical problems of some elderly patients sometimes makes this treatment strategy financially challenging and more traumatic for those compromised patients, so in order to reduce the cost and time of treatment the concept of single midline implant retained mandibular over-denture provides another alternative for elderly edentulous patients⁽³⁻⁸⁾.

Although the use of single midline implant is a successful and promising treatment modality for elderly edentulous population, but this success is still considered to be influenced by both the volume (quantity) and density (quality) of the available bone where the implant is to be placed⁽⁹⁾.

Implant stability and osseointegration are strongly related to each other. Stability was defined as the absence of clinical mobility, which is also suggested by many authors as the definition of osseointegration^(10,11).

Implant stability can be measured by various non-invasive clinical test methods as resonance frequency analysis. The resonance frequency analysis is a method used to analysis the first resonance frequency of a small transducer (Smart Peg) attached to an implant fixture or abutment. A new version of a clinical instrument, the Osstell™ Mentor (Integrations Diagnostics AB, Savedalen, Sweden), was developed to analyze resonance frequency by means of a unit called the implant stability quotient (ISQ)⁽¹²⁾.

The resonance frequency of the Osstell system is dependent upon three main factors which are; the design of the transducer itself, the stiffness of the implant fixture and its interface with the tissues and surrounding bone and finally the total effective length above the marginal bone level^(12,13).

There are different factors that determine implant stability. Among these factors are the mechanical properties of the bone tissue at the implant site and how well the implant is engaged with that bone tissue. The mechanical properties of bone are one of the critical factors that are determined by the composition of the bone at the implant site and may fortunately increase during healing because soft trabecular bone tends to undergo a transformation to dense cortical bone at the vicinity of the implant surface⁽¹¹⁾.

Computed tomography (CT) is considered as an objective tool for assessment of bone density in terms of Hounsfield units (HU). HU which is defined as the relative measure of the X-ray attenuation coefficient of any tissue in relation to water, with the HU for water equals zero^(14,15,16).

Misch had used the HU to classify the bone according to its quality into D1: >1,250 HU; D2: 850 to 1,250 HU, D3: 350 to 850 HU. D4: 150 to 350 HU and D5: <150 HU. This classification of bone quality according to HU is the most used method for bone assessment as it is totally objective⁽¹⁷⁾.

Nowadays the role of cone beam CT (CBCT) in dental implantology has been improved in preoperative diagnosis. This is attributed to the advantages of CBCT which includes higher image accuracy, reduced patient radiation dose, low cost, and rapid scan time compared with CT⁽¹⁸⁾.

Unlike HU of CT, the gray scale of CBCT voxels is not accurately representing bone density quantitatively. This inaccurate bone density assessment is related to the absence of calibration of X-rays, projection data discontinuity-related effect and scattered radiation⁽¹⁹⁻²¹⁾.

For that reason CT is the imaging modality of choice for accurate evaluation of bone density. However, with the increased usage of CBCT in dental field especially in implantology, the predictability of primary implant stability from CBCT image is of great value for oral implantologists⁽¹⁶⁾.

Methodology

Twenty two completely edentulous patients were included in this study with age range between 60 and 76 years. All participants in the study were informed with the nature of the research work and informed consents were obtained for every one of them. Full medical and dental histories were taken from the patient to ensure that the patient is medically fit to the research.

Conventional steps of complete denture construction were carried out and all patients received upper and lower complete denture. The lower dentures of the patients were duplicated into a radiographic stent using radio-opaque resin.

The patients were referred to the outpatient clinic of Oral and Maxillofacial Radiology Department – Faculty of Oral and Dental Medicine – Cairo University for CBCT imaging using Planmeca ProMax[®] 3D Mid (Planmeca, Helsinki, Finland). All the selected patients were imaged by CBCT while wearing the radiographic stent to ensure presence of sufficient mandibular bone volume in the midline to accommodate an implant of 10 mm length and 3.7 mm width.

Every patient was positioned with the mid sagittal plan perpendicular on the floor and the occlusal plane horizontal matching with the positioning laser beam of the machine and the whole mandible was included in the field of view. Patient's head was stabilized using head rest. The exposure parameters were adjusted to be 90 kVp, 10 mA, 13 sec exposure time, 400 μ voxel size and field of view 20 cm x 6 cm.

The resultant image was evaluated and measurements were performed using Planmeca Romexis Viewer 3.5.1. (Planmeca, Helsinki,

Finland). A virtual implant was placed in the potential implant site in a position simulating the planned position of implant in the midline of mandible. Using the “3D Implant Verification tool”, the bone density in the potential implant site (inside) and 1mm around the implant (outside) was assessed (Fig. 1).

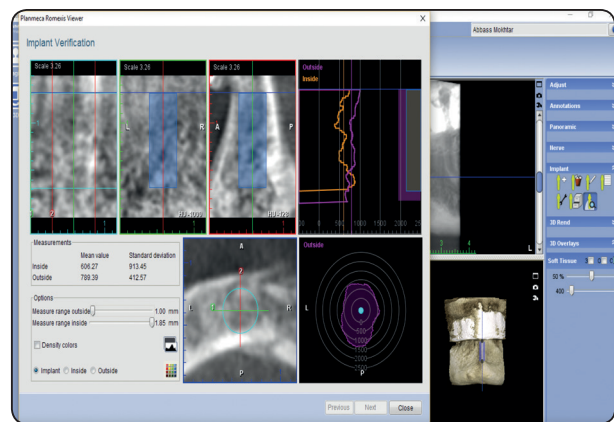


Fig. (1) “3D Implant Verification tool” showing the bone density in the potential implant site and 1mm around the implant

The measurements were performed by an oral and maxillofacial radiologist of 11 years' experience twice with 2 weeks interval between the 2 sessions.

After a period of adaptation and adjustment of the dentures, the surgical phase started where all the patients received a single midline implant of 3.7mm in diameter and 10 mm in length. The position of the implant in the midline was ensured by using a surgical stent to be sure that the implants are installed exactly in the midline for all the patients. After implant installation and before screwing the covering screw, the smart peg was tightened in place in order to assess the primary stability using radiofrequency by the osstell device. Primary stability was assessed at the right, left, buccal and lingual surfaces of the implant. The smart peg was then unscrewed and the covering screw was tightened in place. The flap edges were then approximated and sutured.

The patient was instructed not to use the denture till suture removal so as not to interfere with the healing. After suture removal the denture was slightly relined opposite to the implant site to avoid over loading of the implant in the osseointegration period.

After three months of osseointegration, the implants were assessed both clinically and radiographically to ensure proper osseointegration. Implants were exposed and the covering screw was removed and replaced with the healing collar which was left for 10 days to allow the soft tissue collar around the implant to heal properly. The healing collar was removed after 10 days and the locator abutment was tightened in place with a torque 30 NCm using a torque wrench (Figure 2). The female part was placed precisely over the locator abutment. The counterpart in the denture was ground down to create the necessary space and an overflow hole was drilled to allow for the escape of the excess acrylic resin during the pick-up procedure. Resin was applied to the space created by grinding over the locator abutment and the patient was asked to close in centric occlusion using moderate pressure.

After full polymerization of acrylic resin the denture was finished and polished (Figure 3). The denture was then delivered to the patient after giving him the necessary instructions.

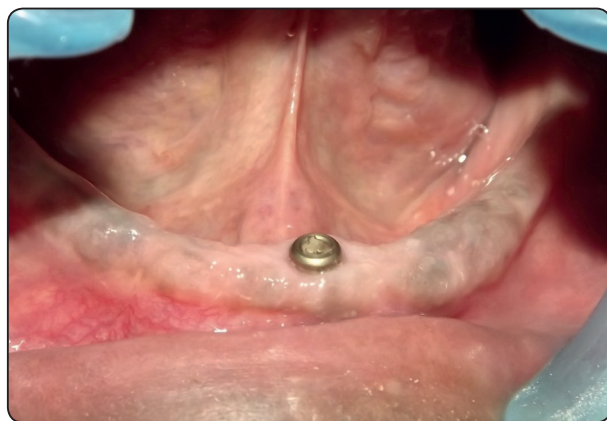


Fig. (2) The locator abutment in place

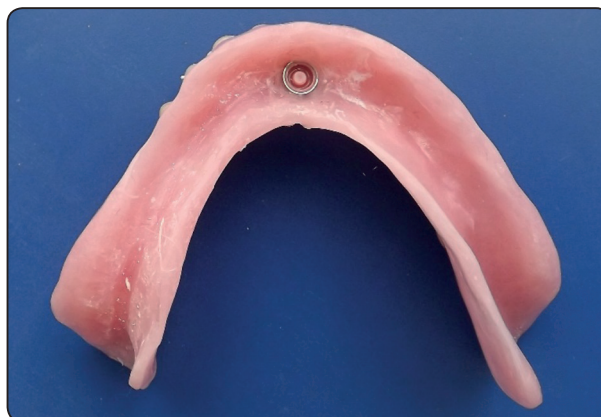


Fig. (3) The female part of the locator attachment after pick-up.

Statistical Analysis

Numerical data were explored for normality by checking the distribution of data and using tests of normality (Kolmogorov-Smirnov and Shapiro-Wilk tests). Data were presented as mean, median, standard deviation (SD), minimum, maximum and 95% Confidence Interval (95% CI) values.

Spearman's correlation coefficient was used to determine the correlations between ISQ and bone density.

Qualitative data were presented as frequencies and percentages.

The significance level was set at $P \leq 0.05$. Statistical analysis was performed with IBM® (IBM Corporation, NY, USA) SPSS® Statistics Version 20 for Windows (SPSS, Inc., an IBM Company).

RESULTS

The present study was conducted on 22 subjects; 20 males (90.9%) and 2 females (9.1%).

Correlation between CBCT bone density and primary implant stability:

There was non-statistically significant direct correlation between bone density (for both inside and 1mm surrounding the potential implant site) and primary implant stability.

TABLE (1) Results of Spearman’s correlation coefficient for the correlation between CBCT bone density and primary implant stability

	Correlation coefficient	P-value
Inside	0.240	0.282
Outside	0.253	0.256

*: Significant at $P \leq 0.05$

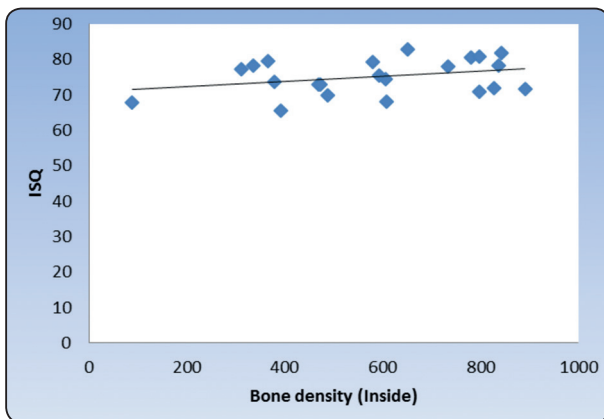


Fig. (4): Scatter diagram representing direct correlation between ISQ and bone density (Inside)

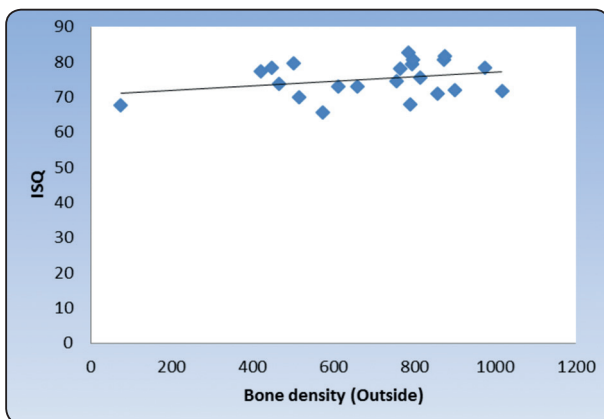


Fig. (5): Scatter diagram representing direct correlation between ISQ and bone density (Outside)

DISCUSSION

The use of magnetic resonance frequency is a very effective tool that is used nowadays to assess the implant primary stability. Many studies were conducted to correlate between bone density and implant stability, but human studies are rare so this study was conducted to correlate between bone density and implant stability in humans.

In our study there was non-statistically significant direct correlation between CBCT bone density and primary implant stability.

Study done by *Wada et al 2015* showed that no correlation was found between CBCT bone density and primary implant stability for one dental implant size but there was a correlation with other three dental implants of different sizes⁽¹⁷⁾. Yet their study was performed on flat part of a pig’s ilium not on patients as well as bone density was assessed in different pattern than our study as they only measure the bone density in the area adjacent to the lateral surface of implant and also consider the bone to be compressed at time of drilling.

In contrary to our results, *Kwon et al 2009* found that bone density obtained using a CBCT showed high correlation with the primary implant stability⁽²²⁾. This may be attributed to imaging of the patients with CBCT after initial osteotomy with gutta percha cone placed in the osteotomy site. Measuring of the bone density adjacent to the radiopaque marker might be affected by the dark hallow around it.

CONCLUSION

Within the limitation of our study, no correlation was found between bone density measured from cone beam CT and primary stability measured by Osstell in elderly edentulous patients receiving single midline implant

REFERENCES

1. Henchman SM, Heusseinger S, Linke JJ, Rraef F, Proschel P.: Improvement and long term stability of neuromuscular adaptation in implant supported overdentures. *Clin Oral Implants Res.* 2009;20:1200-5.
2. Ueda T, Kremer U, Katsoulis J, Mericske-stern R.: Long term results of mandibular implants supporting an overdenture: Implant survival, failure and crestal bone level changes. *Int J Oral Maxillofac Implants.* 2011;26:365-72.
3. Bergendal T, Engquist B.O.: Implant supported overdentures: A longitudinal prospective study. *Int. J. of Oral and Maxillofac Implants.* 1998;13:253.
4. Donatsky O.: Osseointegrated dental implants with ball attachment supporting overdenture in patients with mandibular alveolar ridge atrophy. *Int J Oral Maxillofac Implants.* 1993;8:162-6.
5. Gotfredzen K, Holm B.: Implant supported mandibular overdenture retained with ball or bar attachment: A randomized prospective five-year study. *Int J Prosthodont.* 2000;13:125-30.
6. Thomason JM, Feine J, Extey C, et al.: Mandibular two implant-supported overdenture as the first choice standard of care for edentulous patients-The york consensus statement. *Br Dent J.* 2009;207:185-6.
7. Owen PC.: Appropriatetechn: prosthodontics for the many, not just for the few. *Int J Prosthodont.* 2004;17:261-2.
8. Carlsson GE, Omar R.: The future of complete denture in oral rehabilitation. A critical review. *J Oral Rehabil.* 2010;37:143-56.
9. Cheng T, Li Ma, Liu XL, Sun GF et al.: The use of single implant to retain mandibular overdenture: A preliminary clinical trial of 13 cases. *J of Dental Science.* 2012; 7:261-266.
10. Albrektsson T, Zarb GA.: Current interpretations of the osseointegrated response: clinical significance. *Int J Prosthodont.* 1993;6: 95-105.
11. Meredith N, Sennerby L.: Implant stability measurements using resonance frequency analysis: biological and biomechanical aspects and clinical implications. *Periodontology* 2000. 2008; 47: 51-66.
12. Meredith N, Alleyne D, Cawley P.: Quantitative determination of the stability of the implant-tissue interface using resonance frequency analysis. *Clin Oral Implants Res.* 1996;7: 261-267.
13. Rompen E, DaSilva D, Lundgren AK, Gottlow J, Sennerby L.: Stability measurements of a double-threaded titanium implant design with turned or oxidised surface. *Appl Osseointegration Res.* 2000;1:18-20.
14. Wesolowski JR, Lev MH: CT: history, technology, and clinical aspects. *Semin Ultrasound CT MR.* 2005; 26:376-379.
15. Hao Y, Zhao W, Wang Y, Yu J, Zou D.: (2014). Assessments of jaw bone density at implant sites using 3D cone-beam computed tomography. *European Review for Medical and Pharmacological Sciences.* 2014; 18(9):1398-1403.
16. Capello V, Cauduro A: Clinical Technique: Application of Computed Tomography for Diagnosis of Dental Disease in the Rabbit, Guinea Pig, and Chinchilla. *Journal of Exotic Pet Medicine.* 2008 April;17(2):93-101.
17. Wada M, Tsuiki Y, Suganami T, Ikebe K, Sogo M, Okuno I.: The relationship between the bone characters obtained by CBCT and primary stability of the implants. *Int. Journal of Implant Dentistry.* 2015;2:1-7.
18. Scarfe WC, Farman AG.: What is Cone-Beam CT and How Does it Work? *Dental Clinics of North America.* 2008;52:707-30.
19. Naitoh M, Hirukawa A, Katsumata A, Arijji E.: Prospective study to estimate mandibular cancellous bone density using large volume cone-beam computed tomography. *Clin Oral Implants Res.* 2010;21:1309-13.
20. Nomura Y, Watanabe H, Honda E, Kurabayashi T.: Reliability of voxel values from cone-beam computed tomography for dental use in evaluating bone mineral density. *Clin Oral Implants Res.* 2010; 21:558-62.
21. Campos MJ, da S, et al.: Bone mineral density in cone beam computed tomography: Only a few shades of gray. *World journal of radiology.* 2014; 6: 607-12.
22. Kwon JJ, Song YD, Jun SH.: Correlation between Bone Quality Evaluated by Cone-Beam Computerized Tomography and Implant Primary Stability. *International Journal of Oral & Maxillofacial Implants.* 2014; 24(1):59-64.