

CHEWING EFFICIENCY OUTCOME OF USING A SOFT LINER WITH IMPLANT RETAINED LOWER SINGLE COMPLETE OVER DENTURE

Faten A.S, Abu Taleb*

ABSTRACT

Purpose: The aim of this study was to evaluate the effect of using a soft liner with locator attachment retained lower single complete over denture on the chewing efficiency.

Methodology: Seven patients aged 55-65 year had completely edentulous mandible opposing dentulous maxilla were selected for this study. All patients received a lower single complete over denture constructed over two implants, placed at the canine region and retained with locator attachment. After 3 months of denture using, the patient underwent soft lining of their overdenture. Chewing efficiency was evaluated three months after wearing denture without a soft liner (first measurement) and 3 months again after wearing the relined denture (second measurement) using the two colored chewing gum mixing ability test.

Results: There were statistically significant lower mean scores of the unmixed fraction of chewing gum value for all the chewing cycles of patients wearing lower single complete implant retained overdenture with locator attachment and soft liner compared to scores obtained with those patients wearing overdenture without a soft liner.

Conclusion: Using a soft liner with mandibular single complete overdenture that retained with locator attachment improves the chewing efficiency.

KEY WORDS: Single mandibular complete denture –Implant retained over denture- Locator attachment-Soft liner.

INTRODUCTION

It is a challenging to get comfort, function, proper esthetics and retention in restoring one jaw edentulous patient with natural opposing dentition. Undesirable force on the opposing denture come

from the occlusal plane inclination of the existing natural teeth. To overcome these problems, two things are necessary. One of them is full use must be made of every factor that favors success, the other is the arrangement that forces to which the denture is subject must be reduced as much as possible¹.

* Assistant Prof of Removable Prosthodontics, Prosthodontic Department, Faculty of Dentistry, Tanta University.

The advent of osseointegrated implants provides a treatment modality that allows the remaining maxillary teeth to be kept and maintains the level of alveolar bone in the edentulous mandible². According to the McGill consensus statement; a two-implant overdenture should become the standard of care of the edentulous mandible³.

The durability of the implant retained mandibular overdentures may depend on the degree of retention and stability of the denture and thus on the type of attachment⁴. The attachment systems are used to connect implants to over dentures by either splinting or unsplinting the implants⁵. Many factors affect the selection of the attaching mechanism for an implant retained over denture as the cost effectiveness, amount of retention needed, expected level of oral hygiene, an amount of available bone, patient's social status, patient's expectation, maxilla-mandibular relationship, inter-implant distance, and status of the antagonistic jaw⁶.

At a recent time, the locator attachment system being characterized by a low profile design, ease of seating in the oral cavity by the patient, self-locating feature to fit non-parallel implants up to 40°C divergence has been advocated as a suitable alternative to the classical widely used ball attachment⁷. The attachments have different vertical heights, and they are resilient. In addition, repair and replacement are fast and easy^{8,9}.

The denture base loading is leading to compressive forces that may result in catabolic activity in the underlying bone and more rapid ridge resorption. The use of soft liners can reduce the transmitted forces from 20 to 60% and act as stress regulators¹⁰.

Sandwiching a layer of resilient permanent silicone soft liner within denture base improves retention and acts as a shock absorber by equal distribution of stress during function so that the hard basal seat of the denture receive less impact force. It stretched during insertion and removal of prosthesis

over bony prominences without traumatizing the tissues and spring back into close contact with the undercut area thereby improving the retention¹¹.

To evaluate the masticatory efficiency, many different methods have been reported, including the sieve method¹², which is used to measure the degree of combination of different kinds of test foods after a specified number of masticatory strokes. The masticatory efficiency was evaluated also by using 2-colored paraffin wax cubes. The validity of chewing gum with changeable color has been confirmed as a self-implementable method of evaluating masticatory efficiency. In spite of the validity of some of these methods, the search continues for a simplified and effective way of obtaining an appropriate index¹².

Finally, a method based on a two-color chewing gum has been established in which the mixing degree has been determined by a comparison with a color scale, a scan, or later by specially developed software¹³.

A chewing gum was available as a stick-type gum. The gum base has red, yellow, and blue dyes, citric acid, and xylitol. Under the acid condition, the red dye loses its color because of its pH-sensitive. The pH inside the chewing gum is maintained low by the citric acid while the chewing gum appears yellowish-green before mastication. As mastication proceeds, the chewing gum is mixed with saliva and the pH increases inside the chewing gum because of elution of the citric acid makes the color of the chewing gum to change from yellowish-green to red. The hardness of the chewing gum is adjusted so that it does not adhere to the denture materials and even complete denture wearers who have reduced occlusal force easily chew it¹⁴.

In spite of the several advantages listed in the literature regarding the use of soft liner with complete removable denture, still, there is little documentation about the chewing efficiency of using a soft liner with single complete implant retained over denture.

The aim of this study was to evaluate the effect of using a soft liner with locator attachment retained lower single complete over denture on the chewing efficiency.

MATERIALS AND METHODS

Seven male patients aged 50 -65 years with completely edentulous mandibular and opposing dentition were selected from the outpatient clinic of Prosthodontic Department, Faculty of Dentistry, Tanta University, Egypt. The inclusion criteria included sufficient bone height and width in the inter-foraminal region of the mandible. Exclusion criteria included systemic diseases that may compromise implant surgery, diabetes mellitus, chemotherapy or radiation therapy, uncooperative patient, and smoking. The protocol of the study was explained to patients and all of them signed an informed consent.

Periodontal maintenance principles were carried out for the upper natural teeth¹⁵, occlusal adjustment of the maxillary natural teeth was usually required prior to the construction of a single mandibular complete denture. For all patients, a conventional complete lower denture was fabricated and then duplicated to be used as a radiographic stent. Two DIO dental implants (Dio Implant System, Korea,

SM / IFI 5) with a diameter of 3.8mm and length of 12mm were implanted bilaterally at the canine region of the mandible with flapless technique. Confirmation of the Osseointegration by the aid of digital panoramic x-ray film (figure 1)

After three months, the patient presented for the definitive prosthesis fabrication. The cover screw was removed with a screwdriver and the locator abutment was positioned and tightened with the locator abutment driver (part of locator core tool) (Figure 2). After putting the metal housing, white spacer ring was placed over the head of each abutment to block the area under the housings from any acrylic flow. A transferable mark was placed on the top of each metal housing and the denture was then seated in the patient's mouth to determine where the denture needs to be opened. Holes were made in the denture at the pre-marked locations. Try in the denture for full seating and a mix of auto polymerizing acrylic resin applied inside the holes of the denture. The denture was then inserted into the mouth and the patient was asked to close the mouth in centric occlusal position. Removal of the black inserts of the metal housing with the locator core tool. The appropriate replacement inserts were seated into the metal housing with the insert seating tool. The overdenture was then inserted in

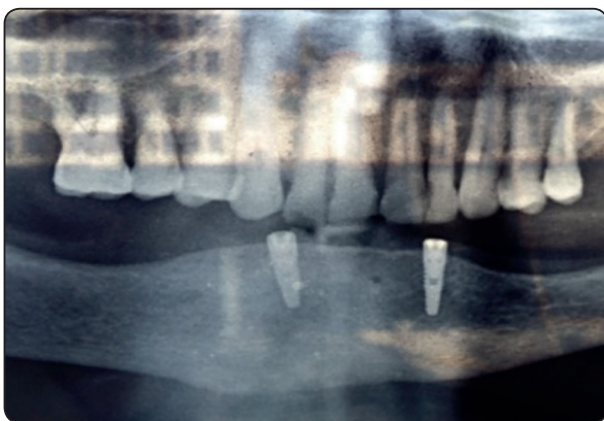


Fig. (1) Panoramic radiograph showed the implant in their position inside the patient's mouth.

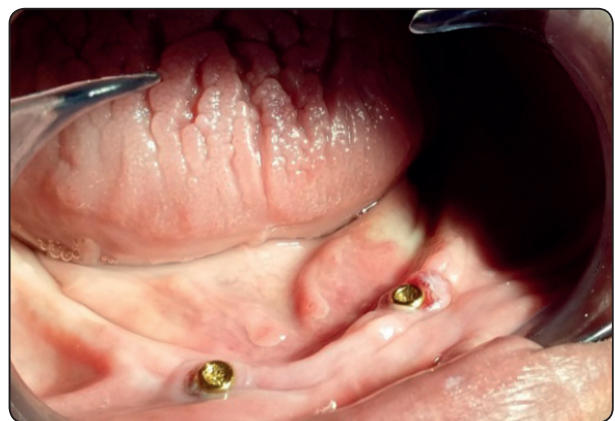

Fig. (2) The locator abutments in their position in the patient's mouth

the patient's mouth and patients were instructed to follow strict oral hygiene measures. After three months, the patients recalled for chewing efficiency measurement (first measurement).

After the first measurement, all dentures were relined with permanent soft liner¹⁶ (Karlin Dental Distributors Inc. EasySoft Liner. Germany). The borders and tissue surface of the denture were trimmed by 1.5-2 mm except in the region of the implant. and the degreasing was done by means of pure medical alcohol and allowed to dry. Later primer liquid supplied by the manufacturer applied uniformly and dried for two minutes. The soft liner applied directly from the cartridge on to the prepared denture base, uniformly maintaining a thickness of 2mm over the tissue surface and borders. Then placed in-patient's mouth and functional molding was accomplished. The patient asked to bite in centric occlusion until material sets completely (figure 3). Excess material removed using a sharp scalpel, fine scissors. The patients received their denture, and the chewing efficiency measured again after three months (second measurement).

Chewing efficiency measurement as described by Schimmel et al¹². Two strips of standard size 30×18×3 mm of two colors white and orange were cut from each gum and mixed manually. The patients were instructed to chew 5 samples

of gum for 5,10,20,30 and 50 cycles respectively with a one-minute interval to avoid fatigue (figure 4). All samples were scanned from both sides, the scanned image was copied into an image of fixed size 1175×925 pixels. As a reference scale, a scanned piece of unmixed gum area of 4779 pixels was copied in each image. The magic wand tool and the histogram function were used to select the unmixed orange part of the image. The number of selected pixels for each side were recorded from the histogram and a mean of these figures was calculated. The ratio was computed for the unmixed fraction using the following formula:

$$\text{Unmixed fraction} = (\text{Pixels white side a} + \text{pixels white side b}) - 2 \times \text{Pixels of Scale} / 2 \times \text{Pixels All}$$

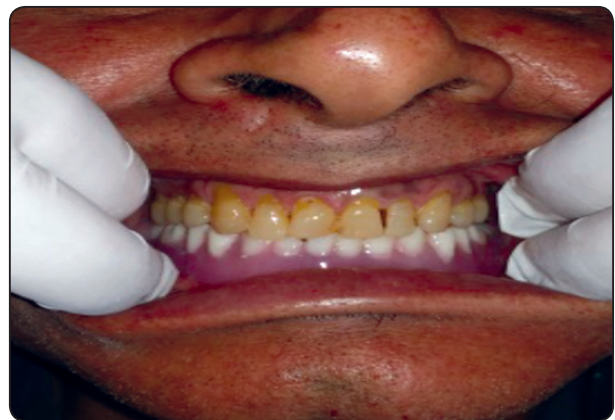

Fig. (3) The relined denture in the patient's mouth



Fig. (4) chewing gum

Statistical analysis

Data were collected, revised, coded and entered into SPSS version 20. The comparison between conventional dentures and relined dentures was done by using Man Whitney -test while the comparison between different chewing cycles (5,10,20,30 and 50) for each denture, Freidman test was used followed by Wilcoxon signed ranked test. The confidence interval was set to 95% and the margin of error accepted was set to 5%. So, the p-value was considered significant at the $p < 0.05$.

RESULTS

The mean ratio of unmixed fractions at different numbers of chewing cycles for conventional and relined lower single complete implant retained over denture are presented in table 1 and graph 1.

The mean ratio of unmixed fractions decreased significantly when the number of chewing cycles increased, which indicated by the higher degree of color mixing. The unmixed value of the

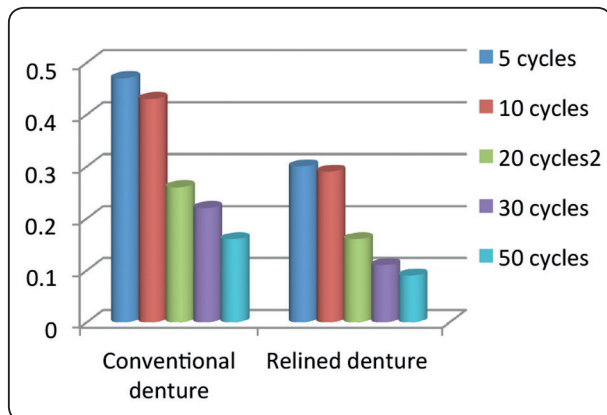
relined denture was significantly lower than the conventional denture as shown in Table 2. The decrease in unmixed value indicates high color mixing and good masticatory efficiency

TABLE (1) Multiple comparison of the unmixed fractions between chewing cycles for both dentures

	Wilcoxon signed rank test, significant* at 5%	
	Conventional dentures	Relined denture
5C-10C	0.061	0.058
5C-20C	0.053*	0.050*
5C-30C	0.045*	0.044*
5C-50C	0.047*	0.046*
10C-20C	0.055	0.050*
10C-30C	0.049*	0.047*
10C-50C	0.048*	0.046*
0C-30C	0.062	0.059
20C-50C	0.040*	0.039*
30C-50C	0.067	0.066

TABLE (2) Comparison the unmixed fractions between the conventional and relined denture at different number of chewing cycles, X; mean; SD; standard deviation

	5 cycles	10 cycles	20 cycles	30 cycles	50 cycles
Conventional denture X±SD	0.47±0.020	0.43±0.019	0.26±0.011	0.022±0.012	0.16±0.047
Relined denture X±SD	0.30±0.023	0.29±0.020	0.16±0.013	0.011±0.013	0.9±0.066
Man Whitney P value	0.024*	0.019*	0.022*	0.023*	0.034*



Graph (1) the mean of unmixed fractions of both dentures at different number of chewing cycles

DISCUSSION

The construction of a lower complete denture against natural teeth is necessary in some conditions. The patient requiring single denture opposing natural teeth faces a challenging job for the dentist thus the treatment planning and the prosthesis to be given should be stable functionally thus controlling the alveolar bone resorption .

Pre-prosthetic procedures were done to correct the occlusal discrepancies present in the maxillary natural teeth before construction of the mandibular single denture to minimize stress on the implants and to increase the stability of the denture¹⁵. In the present study, two implants were placed in the mandibular intraforaminal region, as clinical reports had indicated a higher survival rate for dental implants in the mandible, particularly in the anterior region, which had been associated with better volume and density of the bone^{17,18}. Rehabilitation of the edentulous mandible with two implant-retained overdenture was appeared to increase patient's expectations and reduce direct and after care costs¹⁹.

The locator attachments are more advantageous than ball and bar systems. They are resilient, retentive, durable, and have some built-in angulation compensation. In addition, repair and replacement are fast and easy. The Locator attachments function reasonably well and gave very pleasing results with very good retention and stability. Also, locator attachments provide better hygiene maintenance and help to maintain healthy soft tissue around implants^{20,21}.

Complete dentures are unyielding units and best described as a rigid prosthesis. In dentulous subjects, the periodontal ligament being resilient serves to cushion the impacting forces (viscoelastic theory) applied to natural teeth. The same principle used in dentures in which an elastic material like soft liner can be on the tissue surface of the denture to absorb some of the forces imparted during function so that the trauma to the basal seat would be reduced and

the forces would be more widely distributed over the basal seat. It usually acts as a cushion between the hard denture base and the supporting tissues²².

Chewing gum used to evaluate masticatory efficiency has many advantages. There is no comminution of food particles that may be stuck under dentures or swallowed and therefore lost for analysis. Moreover, the gum has an elastic consistency that allows the use of maximum muscle activity. Furthermore, chewing gum is widely available, stackable and not expensive. Its chewing properties are familiar to most persons. Evaluating the wafer by means of a digital image processing techniques showed a significant correlation between unmixed fractions and the number of chewing strokes in the healthy sample that took part in this study. Thus, the described method seems valuable to assess chewing efficiency¹³.

The computerized analysis was performed for the samples because visual assessment appeared to be less reliable¹². Visual assessment performed by visual inspection of both sides of bolus and scoring the degree of mixing into categories according to reference example or by ranking set samples. While computer analysis can determine various parameters from the digital image, such as the area of unmixed color, size of the separate color areas, maximum length and width of chewed bolus and intensity and distribution of color. All these variables were used as a measure for mixing the samples²³.

Our result of the presented study showed more chewing efficiency with relined single complete overdenture that retained with locator attachment than those without relining. Because of a combination of the advantages of locator attachment and soft liners with implant-retained mandibular overdentures. The advantages of locator attachment include resiliency, fewer stresses to the bone and more chewing efficiency. During the connection of the attachment, the Locator attachment system has a space of 0.2mm between the abutment top and nylon patrix for the retention disk. This allows

vertical resilience and 8° hinging in any direction. The Locator system recorded higher compressible strains and provided excellent settlement of the denture base without fulcrum formation. These are the same results reported by Eltaftazani et al, Kaneko et al, Krennmair et al and Abo Shady et al^{7,20, 24, 25}.

As reported by Sreeharsha et al, the use of soft liners with complete dentures provides better masticatory performance in comparison to complete dentures without the use of soft liners²⁶. So, soft liners can be advised in patients who have severely resorbed residual ridges and patients who cannot tolerate conventional hard acrylic resin denture bases because of underlying thin and non-resilient mucosa as the lower single denture. The advantages of soft liners with implant overdenture allowed energy absorption, and equal force distribution to the implants and edentulous ridge as reported with Elsyad et al²⁷.

The more chewing efficiency was attributed to the presence of implant attachments that stabilize the denture, minimize the discomfort and allow the patient to exert higher bite forces during mastication. Geertman et al²⁸ suggested that the increased retention and stability of the mandibular denture, rather than the degree of support by implants or alveolar mucosa, determine the wearer's ability to comminute food during mastication. In contrast to Bakke et al²⁹ who reported that, the patients with resorbed mandibles may result in pain during chewing and biting due to compression of the tissues and shifting of the denture. Pain and instability of the dentures in patients with resorbed mandibles are considered limiting factors for achieving good muscle action. Several authors (van der Bilt et al. 2010; Muller et al. 2013)^{30,31} described an improvement of the average maximum biting force after implant overdenture treatment. Such treatment allows more usage and training of the masticatory muscles. Therefore, the muscle thickness increased and muscle activity in rest decreased because there was no longer a need to stabilize the loose denture after implant treatment as reported with Boven et al³².

CONCLUSION

The combination of both retentive advantages of locator attachment and the force distributor action of the soft liner with implant retained single complete overdenture improved the chewing efficiency. It is considered a better treatment approach of lower single complete implant retained overdenture.

REFERENCES

1. Pande NA, Kolarkar M. Triad treatment option to restore full mouth. *Indian J. Multidiscip Dent* 2015;5:42-46.
2. Shor A, Goto Y, Shor K. Mandibular two-implant-retained overdenture: prosthetic design and fabrication protocol. *Compend Contin Educ Dent* 2007; 28:80-88.
3. Fueki K, Kimoto K, Ogawa T, Garrett NR. Effect of implant-supported or retained dentures on masticatory performance: A systematic review. *J Prosthet Dent* 2007;98:470-477.
4. Shastry T, Anupama NM, Shetty S, Nalinakshamma M. An in vitro comparative study to evaluate the retention of different attachment systems used in implant-retained overdentures. *J Indian Prosthodont Soc* 2016;16:159-166.
5. Al qutaibi A Y. Attachments Used With Implant Supported Over Denture *Adv Dent & Oral Health*.2016; 1: 1-5.
6. Trakas T, Michalakis K, Kang K, Hirayama H. Attachment systems for implant retained overdentures: A literature review. *Implant Dent* 2006;15:24-34.
7. Eltaftazani I, Moubarak A, El-Anwar. Locator attachment versus ball attachment: 3-dimensional finite element study. 2010.(88th edn), Barcelona, Spain.
8. Chikunov I, Doan P, Vahidi F. Implant retained partial overdenture with resilient attachments. *J Prosthodont*.2008; 17: 141-148.
9. Kleis WK, Kämmerer PW, Hartmann S, Al-Nawas B, Wagner W. A Comparison of Three Different Attachment Systems for Mandibular Two-Implant Over dentures: One-Year Report. *Clin Implant Dent Relat Res*.2010; 12: 209-218.
10. Hiroshi Murata a, Taizo Hamada b, Shinsuke Sadamori. The relationship between viscoelastic properties on soft denture liners and clinical efficacy *Japanese Dental Science Review* 2008; 44:128-132.
11. Singh K, Gupta N. Fabrication and relining of dentures with permanent silicone soft liner: A novel way to increase retention in a grossly resorbed ridge and minimize the trauma of knife edge and severe undercuts ridges. *Dent Med Res* 2016;4:24-28.

12. Schimmel M, Christou P, Herrmann F, Ller M. A two-colour chewing gum test for masticatory efficiency: development of different assessment methods. *Journal of Oral Rehabilitation* .2007 ;34: 671–678.
13. Schimmel M, Christou P, Miyazaki H, Halazonetis D, Herrmann FR, Muller F. A novel colorimetric technique to assess chewing function using two-coloured specimens: validation and application. *J Dent* 2015;43:955–964.
14. Müller F, Hernandez M, Grütter L, Aracil-Kessler L, Weingart D, Schimmel M. Masseter muscle thickness, chewing efficiency and bite force in edentulous patients with fixed and removable implant-supported prostheses: a cross-sectional multicenter study. *Clin. Oral Impl. Res.* 2012; 23: 144–150.
15. Nallaswamy D, Ramaingagam K, Bhatt V. *Textbook of prosthodontics*. New Delhi: Jaypee Brother Medical Publisher. 2003; 250-255.
16. Mosharraf R, Abolhasani M, Pirooz Givchian. A technique for relining bar-retained overdentures. *School of Dentistry, Isfahan University of Medical Sciences, Isfahan, Iran Journal of Prosthetic Dentistry*. 2014; 6: 2-7.
17. Turkyilmaz I, Aksoy U, McGlumphy EA. Two alternative surgical techniques for enhancing primary implant stability in the posterior maxilla: a clinical study including bone density, insertion torque, and resonance frequency analysis data. *Clin Implant Dent Relat Res*.2008; 10:231-237.
18. Drage NA, Palmer RM, Blake G, Wilson R, Crane F, Fogelman I. A comparison of bone mineral density in the spine, hip and jaws of edentulous subjects. *Clin Oral Implants Res.* 2007;18: 496-500.
19. Romanos GE, Nentwig GH. Immediate versus delayed functional loading of implants in the posterior mandible: a 2-year prospective clinical study of 12 consecutive cases. *Int J Periodontics Restorative Dent.* 2006;26:459-569 .
20. Kaneko T, Nakamura S, Hino S, Horie N and Shimoyama T. Two-Implant-Retained Overdentures using Locator Attachments in Completely Edentulous Patients with Severely Resorted Mandible: A Report of Two Cases. *J Dent App.* 2016; 3: 315-318.
21. Prasad DK, Prasad DA, Buch M. Selection of attachment systems in fabricating an implant supported overdenture. *J Dent Implant* 2014;4:1761-1781.
22. Kawano F, Dootz ER, Koran A, Craig RG. Comparison of bond strength of six soft denture liners to denture base resin. *J Prosthet Dent* 1992;68:368-371.
23. Satoh, Fueki K, Sueda S, Sato S, Shiozaki T, Kato M. A new and simple method for evaluating the masticatory function using newly developed artificial test food. *Journal of Oral Rehabilitation* 2003; 30:68-73.
24. Krennmair G SR, Fazekas A, Ewers R, Piehslinger E. implant-supported mandibular overdentures retained with ball or locator attachments: crossover clinical trial. *J Oral Maxillofac Implants.* 2012;276:1560-1568.
25. Abo Shady M, Eltorkey I, Abd Eaal Z. Comparative study of two types of attachments for mandibular implant-retained single complete overdenture. *Tanta Dental Journal* 2016, 13:157–161.
26. Sreeharsha T, Nandeeshwar DB. A Clinical Study to Evaluate and Compare the Masticatory Performance in Complete Denture Wearers with and without Soft Liners. *The Journal of Contemporary Dental Practice*, November-December 2012;13:787-792.
27. Elsyad MA, Khairallah AS. Chewing efficiency and maximum bite force with different attachment systems of implant overdentures: a crossover study. *Clin. Oral Impl. Res.* 2016; 1: 617-621.
28. Geertman, M.E., Slagter, A.P., van Waas, M.A. & Kalk, W. Comminution of food with mandibular implant-retained overdentures. *Journal of Dental Research.* 1994;73: 1858–1864.
29. Bakke M, Holm B & Gotfredsen K. Masticatory function and patient satisfaction with implant-supported mandibular overdentures: a prospective 5-year study. *The International Journal of Prosthodontics.* 2002; 15: 575–581.
30. van der Bilt, A, Burgers M, van Kampen F M, Cune MS. Mandibular implant-supported overdentures and oral function. *Clinical Oral Implants Research.* 2010; 21:1209–1213.
31. Muller F, Duvernay E, Loup A, Vazquez L, Herrmann FR, Schimmel M. Implant supported mandibular overdentures in very old adults: a randomized controlled trial. *Journal of Dental Research.*2013; 92: 1545–1605.
32. Boven GC, Raghoobar G.M, Vissink A, Meijer HJ . Improving masticatory performance, bite force, nutritional state and patient's satisfaction with implant overdentures: a systematic review of the literature. *Journal of Oral Rehabilitation.*2015; 42: 220–233.