

Attenuation of Acetone Induced Liver and Kidney Injury by Ginger and Turmeric Root Powder in Chickens

***Abd El-Rahman, A.A.¹; H.A.M. Elwan²; S.M.A. El-Shafei¹ and A.M.A. Abd El-Hafez²**

¹Dept. of Agricultural Chemistry, Fac. of Agriculture, Minia University, El-Minia, Egypt

²Dept. of Animal and Poultry Production, Fac. of Agriculture, Minia University, El-Minia, Egypt

*Corresponding author: atefnagi2000@yahoo.com

Received on: 19/12/2017

Accepted for publication on: 4/1/2018

Abstract

Ginger and turmeric are commonly used in food as spices with well-reported antioxidant activity. However, hepatoprotective and nephroprotective effects of ginger and turmeric have not been adequately studied. Therefore, the current study used chicken model with acetone induced liver and kidney injuries to evaluate the hepatoprotective and nephroprotective activities of ginger and turmeric because metabolic functions of chicken and human liver is similar. Eighty cocks were randomized into 5 experimental groups of chicks. The first one served as control. While the second group was received 350mg acetone/kg body weight (given in drinking water) per day for 30 days. The third, fourth and fifth groups were received ginger, turmeric and mix of ginger and turmeric by 1% in food respectively after treatment with acetone. Hematological parameters, liver and renal function tests, hepatic oxidative stress enzymes, as well as, histopathological examination scores were determined. Results indicated that, administration of acetone induces alteration in various hematological parameters, hepatic enzymes and hepatic oxidative stress enzymes in chickens. Dietary supplementation of ginger (GEN) and turmeric (TUR) caused a significant amelioration in some hematological parameters in acetone treated chickens. GEN and TUR treatments could reduce damage induced by acetone in alanine aminotransferase (ALT), aspartate aminotransferase (AST), alkaline phosphatase (ALP), lactate dehydrogenase (LDH), gamma-glutamyl transpeptidase (GGT), glucose, total protein and their fractions levels. Furthermore, acetone promoted a significant increase in urea, uric acid and creatinine levels, while treatment with GEN or TUR or GEN+TUR at the same time of treatment with acetone maintained urea and uric acid concentrations at a level similar to the control group. Interestingly, GEN, TUR and GEN+ TUR treatments significantly ameliorated effects of acetone on chickens by improving the levels of the main antioxidant enzymes (superoxide dismutase SOD, glutathione-S-transferase GST) and malondialdehyde (MDA) a reliable marker of lipid peroxidation in the cells. Histologically, acetone appeared to be hepatotoxic in chick's. Hepatocytes were sensitive to the treatment with acetone and contained large number of congested blood vesicles, cytoplasmic vacuoles, pyknotic nuclei, and lymphocytic infiltration in treated animals. Turmeric and ginger treatments improved the vast majority of hepatic changes. Our findings broadly confirmed that, the supplementation of ginger and turmeric significantly alleviated liver and kidney functions, hema-

tological parameters, as well as, hepatic oxidative stress enzymes and may have applications in the field of hepatoprotective drug development.

Introduction

Liver is the organ most frequently injured and largest organ in the body (Lucas and Ledgerwood, 1992). Hepatic injury is a common pathology in poultry and human. It caused by many factors, such as nutrition, diseases, and toxins (Wang *et al.*, 2013). Hepatic fibrosis and cirrhosis act as a sign of liver damage and a factor of liver dysfunction (Bataller and Brenner, 2005). The treatment of hepatic fibrosis and cirrhosis should be tolerable and safe and it has not been approved yet (Schuppan and Kim, 2013).

Acetone is the organic compound with the formula $(\text{CH}_3)_2\text{CO}$. It is a colorless, volatile, flammable liquid that is found in the environment and is produced by industries. It is quickly absorbed by ingestion, inhalation, and dermal exposure. (Armutcu *et al.*, 2005). Acetone administration in animals has been shown to potentiate hepatotoxicity and nephrotoxicity and is related to induction of microsomal enzymes that metabolize these solvents to reactive intermediates (Morgott, 1993). The first step in acetone metabolism is the conversion of acetone into acetol by a cytochrome P450 2E1. Acetol is transformed into methylglyoxal by acetol monooxygenase which further metabolized to pyruvate by two different metabolic routes. (Kalapos, 1999).

Ginger plant (*Zingiber officinale*) is known as one of the important medicinal plant that are rich in phytochemicals and commonly used in food as spice. The main components of ginger are 6-gingerol, 6-

shogaol, 8-gingerol and 10- gingerol (Kim *et al.*, 2007; Schwertner and Rios 2007). These compounds are reported for their antioxidant (Maizura *et al.*, 2011) and anticarcinogenic activities in the skin (Kim *et al.*, 2004; Murakami *et al.*, 2004), gastrointestinal tract (Yoshimi *et al.*, 1992), colon (Bode, 2003; Manju and Nalini, 2005), and breast (Nagasawa *et al.*, 2002). Ginger extract has been reported to exert antitumor and apoptotic effects on several cell lines including leukemia (Lee and Surh, 1998), gastric (Ishiguro *et al.*, 2007), prostate (Nonn *et al.*, 2007), ovarian (Rhode *et al.*, 2007), and lung carcinoma (Wang *et al.*, 2005). Ginger chemopreventive mechanisms are thought to involve the induction of carcinogen-detoxifying enzymes (Nakamura *et al.*, 2004), antioxidant (Ahmed *et al.*, 2000) and anti-inflammatory (Jolad *et al.*, 2004; Grzanna *et al.*, 2005; Lantz *et al.*, 2007) activity.

Turmeric is a member of the ginger family (*Zingiberaceae*) and is a spice that comes from the root *Curcuma longa*. (Chainani, 2003). It has been used as a coloring agent, a spice and a food preservative, as well as, for its various medicinal properties. (Peirce, 1999; Chainani, 2003). The major active compounds in turmeric called curcuminoids. Curcuminoids contain a variety of compounds including, diferuloylmethane, demethoxycurcumin, and bisdemethoxycurcumin. It gives turmeric its bright yellow color and have been extensively studied for their antioxidant, anti-inflammatory, antiviral, and antifun-

gal properties (Young-Joon, 1999; White and Foster, 2000). Many studies have investigated anticarcinogenic activities of curcumin in several types of cancer including colorectal, pancreatic, gastric, prostate, hepatic, breast, and oral cancers. (Cheng *et al.*, 2001; Ireson *et al.*, 2001; Aggarwal *et al.*, 2003). Possible mechanisms for the potential anticarcinogenic effects induced by curcumin include: (1) inhibition of NF- κ B and COX-2 (Surh *et al.*, 2001) (2) inhibition of arachidonic acid metabolism via lipoxygenase and scavenging of free radicals generated in this pathway; (Huang *et al.*, 1991) (3) decreased expression of inflammatory cytokines IL-1 β , IL-6, and TNF- α , resulting in growth inhibition of cancer cell lines; (Cho *et al.*, 2007) and (4) down-regulation of enzymes, such as protein kinase C, that mediate inflammation and tumor-cell proliferation. (Liu *et al.*, 1993). In the last several years, chickens have been used and suggested as an animal model for human liver diseases (Ayala *et al.*, 2009; Makovicky *et al.*, 2011). Thus, the safe plant-derived natural products, which possess antifibrotic ability can be used to treat liver injury as an alternative choice. Therefore, the current study aimed to investigate the effects of ginger and turmeric against liver injury induced by acetone in chickens to evaluate the potential of therapy application.

Materials and Methods

Animal and experimental design.

This experiment was carried out at the farm of Animal and Poultry Production Department, Faculty of

Agriculture, Minia University. A total of 80 cocks of Inshas (Egyptian native improved strain), 6 weeks of age, were obtained from a commercial layer farm. They were randomly allocated into 5 treatment groups, each of which included 8 replicates of 2 cocks. The birds were housed at 2 birds per cage under the same managerial conditions in a windowed poultry house. The photoperiod was 16 light: 8 dark throughout the experiment. The temperature was recorded twice daily and the mean daily temperature was $35 \pm 4^{\circ}\text{C}$. Eighty cocks were randomized into 5 experimental groups of chicks comprising 16 birds per group. The first one served as control and received diet free of additives. The second group was provided with 350mg acetone/kg body weight (given in drinking water), third group was provided with 350mg acetone/kg body weight (given in drinking water) plus 10g ginger/kg diet, fourth group was provided with 350mg acetone/kg body weight plus 10g turmeric/kg diet and fifth group was provided with 350mg acetone/kg body weight (given in drinking water) plus 10g ginger and 10g turmeric/kg diet. Feed and water were available *ad libitum* during the experimental period (30 days).

Medicinal plants preparation

Ginger and turmeric were provided from a private commercial market at El-Minya Governorate Egypt. Then dried at 40°C until constant weight. Dried ginger and turmeric were finally milled, sieved (1 mm mesh) and stored in a well tight polyethylene bags at room temperature 25°C .

Hematological parameters

At the end of the experiment, 5 ml blood, were taken at 07:00 – 08:00 h am from the wing vein under vacuum in clean heparinized tubes before slaughtering time, blood was tested shortly after collection for estimating blood picture. Red blood cells (RBCs) were counted according to (Campbell, 1995). Hemoglobin concentration (Hb %) and packed cells volume percentages (PCV %) were measured according to (Drew *et al.*, 2004). Calculation of the absolute values or the erythrocyte indices, namely mean corpuscular volume (MCV), mean corpuscular hemoglobin (MCH) and mean corpuscular hemoglobin concentration (MCHC) were calculated according to (Konuk, 1975).

Biochemical analysis

At the end of experimental period (10 weeks of age) 5ml of blood samples were collected in non-heparinized tubes from one bird each replicate, then allowed to clot at room temperature. Serum was separated by centrifugation at 5000 rpm for 10 minutes and stored at -20° C until analysis of liver and kidney functions.

Liver Function Tests (LFTs)

Estimation of liver functions by measuring, the activities of liver enzymes such as ALT, AST, ALP, LDH, GGT and glucose using diagnostic kits (Vitro, Germany). Also, total protein, albumin, globulin, albumin globulin ratio were determined using commercial kits (Bio-Med, Egypt), where, alanine and aspartate aminotransferases were determined by method of (Reitman and Frankel, 1957), Gamma glutamyltransferase

activity was determined by the method of Rosalki *et al.* (1970), alkaline phosphatase by the phenolphthalein monophosphate method (Babson, 1965). The activity of LDH was assayed by the method of Horecker and Kornberg (1948), total protein was determined by the Biuret method (Peters, 1968), albumin by the bromocresol green method (Doumas *et al.*, 1971). All analytical testes were done using T80 UV Spectrophotometer UK.

Renal Function Tests (RFTs)

The serum was analyzed for levels of urea, uric acid and creatinine. Results were expressed as mg/dL, using commercially Bio-Med reagent kits Egypt according to (Tietz, 1986; Tietz and Saunders 1990).

Oxidative stress enzymes

The activities of superoxide dismutase (SOD), glutathione-S-transferase (GST), and malonyldialdehyde (MDA) were determined by using assay kit (BioMed chemical company, Egypt). The values of SOD were expressed as U/ml (Kakkar *et al.*, 1984). GST activity was determined by assaying the concentration of GSH with GST assay kit, and the absorbance was scanned at 412 nm by ultraviolet spectrophotometer (Habig *et al.*, 1974). The concentration of MDA, was estimated in blood serum following the manual of MDA assay kit (Jain *et al.*, 1989).

Histopathological examination

Samples from liver was taken from all groups after scarification. They were fixed in 10 % neutral buffer formalin, embedded in paraffin, sectioned at 3 microns and stained with hematoxylin and eosin stain (H&E stain). Then they were

examined by light microscopy (Freida, 1990).

Statistical Analysis

The study was conducted based on a completely randomized design (CRD) with five treatments and 16 replicates. Data were analyzed by Statistical Analysis System software (SAS, Version 9.1.3, 2003) using the generalized linear model (GLM) procedure. However, significant differences among treatment means for each trait in experiment was detected using Duncan's multiple rang test (1955).

Results

Effects of GEN and TUR on hematological parameters

Interaction between cellular constituents and toxic metabolites may cause significant changes in hematological parameters. The analysis of hematological parameters can be diagnostic of harmful effects of toxic compounds on the blood constituents

of an animal. As shown in Figure (1 A, B, C), the administration of acetone induces alteration in various hematological parameters in chickens. RBCs, Hb% and PCV% were significantly ($P < 0.05$) decreased in acetone treated chickens when compared with the control group by 46.70, 41.77 and 31.71% respectively. As shown in Figure 1(A-C), no significant decreases were observed in RBCs, Hb% and PCV% parameters in ACE + GEN, ACE + TUR and ACE+GEN+TUR treatments compared to the control group. In addition, acetone exposure significantly raised MCV and MCH levels by 22.11 and 8.77 % respectively (Figure 1 D, E). These results confirmed that, the dietary supplementation of GEN and TUR caused a significant amelioration in some hematological parameters in acetone treated chickens.

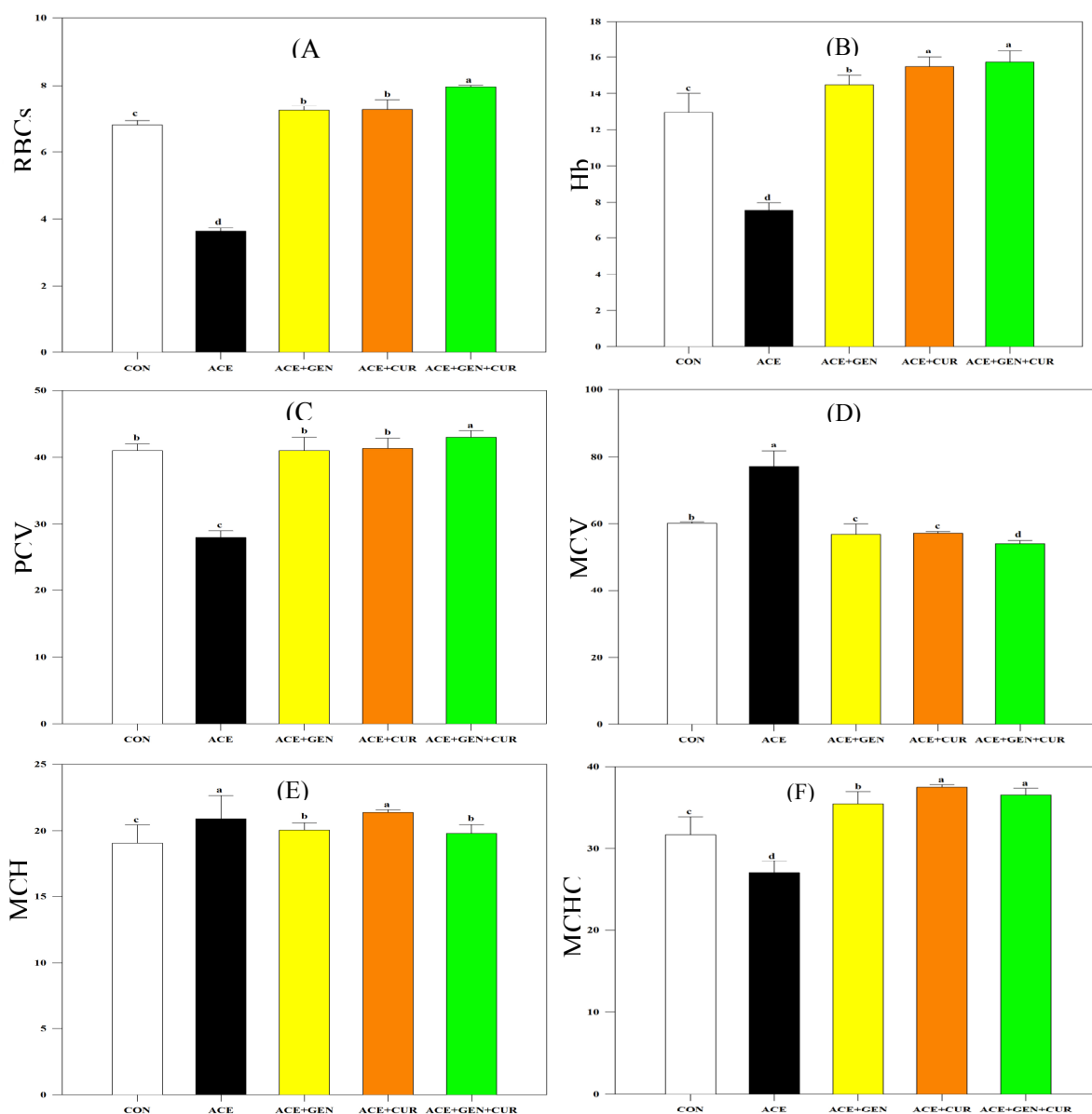


Figure (1): Hematological alterations in RBCs count (A), Hb % (B), PCV% (C), MCV fl/cell (D), MCH pg/cell (E) and MCHC g/dl (F) in chickens of different groups exposed to acetone, ginger and turmeric crushed in drinking water and diet. CON control; ACE acetone; GEN ginger; TUR turmeric.

Effects of GEN and TUR on biochemical parameters

Liver function tests

Liver function tests are groups of blood tests, which are a helpful screening tool, that give information about hepatic dysfunction. In the present study, ALT, AST, ALP, LDH, GGT, glucose, total protein, albumin, globulin and albumin/globulin ratio were determined in serum of all

treated groups. The change in liver function tests were recorded for the chickens of different groups and the results are presented in Table 1. The activities of ALT, AST, LDH and GGT were significantly ($P < 0.05$) elevated in acetone treated chickens as compared to normal chickens (Table 1). Administration of acetone depleted ALP activity, while GEN or TUR or GEN+TUR treatments main-

tained ALP activity at a level similar to the control group (Table 1). In addition, as presented in Table 1, glucose concentration (mg/dl) was significantly increased by the administration of acetone; however, treatment with GEN or TUR or GEN and TUR together restored glucose level by 16.24, 9.28 and 16.10 % respectively compared to the control values recorded in untreated chickens group. The changes of concentration of total proteins and their fractions in blood serum were recorded for the chickens of different groups and the results are presented in Table 1, which indicated that, no significant differences were observed in total protein and globulin (g/dl) levels between control and other treatments. Moreover, it was found that, the level of Albumin (g/dl) in acetone treated group was higher than that of the control chickens. These results, confirmed that, GEN and TUR treatments could reduce acetone-induced chicken liver damage and carcinogenesis.

Kidney function tests

The change in kidney function tests were recorded for the chickens of different groups and the results are presented in Figure 2. Urea, uric acid and creatinine levels (mg/dl) were determined in serum of all treated groups. As indicated in Figure (2A, B, C), acetone promoted a significant increase in urea, uric acid and creatinine levels in serum of chickens by 8.39, 54.72 and 17.65 % respectively, while treatment with GEN or TUR or GEN+TUR at the same time of treatment with acetone maintained urea and uric acid concentrations at a level similar to the control group (Figure 2A and B). Furthermore, the application of GEN or TUR or co-application of GEN with TUR at the same time of treatment with acetone were found to significantly ($P < 0.05$) increase the level of creatinine (mg/dl) by 17.65, 14.29 and 19.24 % respectively.

Table 1. Biochemical changes in liver function tests in chickens of different groups exposed to acetone, ginger and turmeric crushed in drinking water and diet.

Treatments	Liver function tests									
	ALT (U/L) ± SD	AST (U/L) ± SD	ALP (U/L) ± SD	LDH (U/L) ± SD	GGT (U/L) ± SD	GLU (mg/dl) ± SD	TP (g/dl) ± SD	ALB (g/dl) ± SD	GLU (g/dl) ± SD	A/G ratio ± SD
Control	8.00 ± 1.00	18.00 ± 0.25	103.70 ± 0.26	2035.66 ± 14.01	23.00 ± 1.00	244.33 ± 4.04	3.93 ± 0.92	2.10 ± 0.34	1.83 ± 0.58	1.18 ± 0.17
ACE	12.10** ± 0.28	22.33*** ± 1.52	76.33*** ± 1.52	2492.00*** ± 12.16	30.29*** ± 0.61	323.33*** ± 7.63	3.00 ± 0.91	1.43* ± 0.40	1.56 ± 0.51	0.92 ± 0.06
ACE + GEN	8.33 ± 1.15	15.00** ± 1.00	104.36 ± 1.41	2190.00*** ± 36.05	25.33* ± 1.52	204.66*** ± 5.03	3.63 ± 0.45	1.90 ± 0.40	1.73 ± 0.45	1.17 ± 0.51
ACE + TUR	8.00 ± 1.00	14.00*** ± 1.00	102.61 ± 1.40	2156.00*** ± 39.34	25.66* ± 2.08	221.66** ± 12.58	3.26 ± 0.15	1.83 ± 0.11	1.43 ± 0.20	1.30 ± 0.26
ACE+GEN+TUR	7.66 ± 1.52	16.57 ± 0.28	104.06 ± 0.84	2136.66** ± 15.27	27.00** ± 1.00	205.00*** ± 5.00	3.26 ± 0.20	2.06 ± 0.15	1.20 ± 0.34	1.82* ± 0.55

Values are presented as mean ± SD, * $P < 0.05$ significant differences, ** $P < 0.01$ highly significant differences and *** $P < 0.001$ very high significant differences compared to normal group. CON control; ACE acetone; GEN ginger; TUR turmeric.

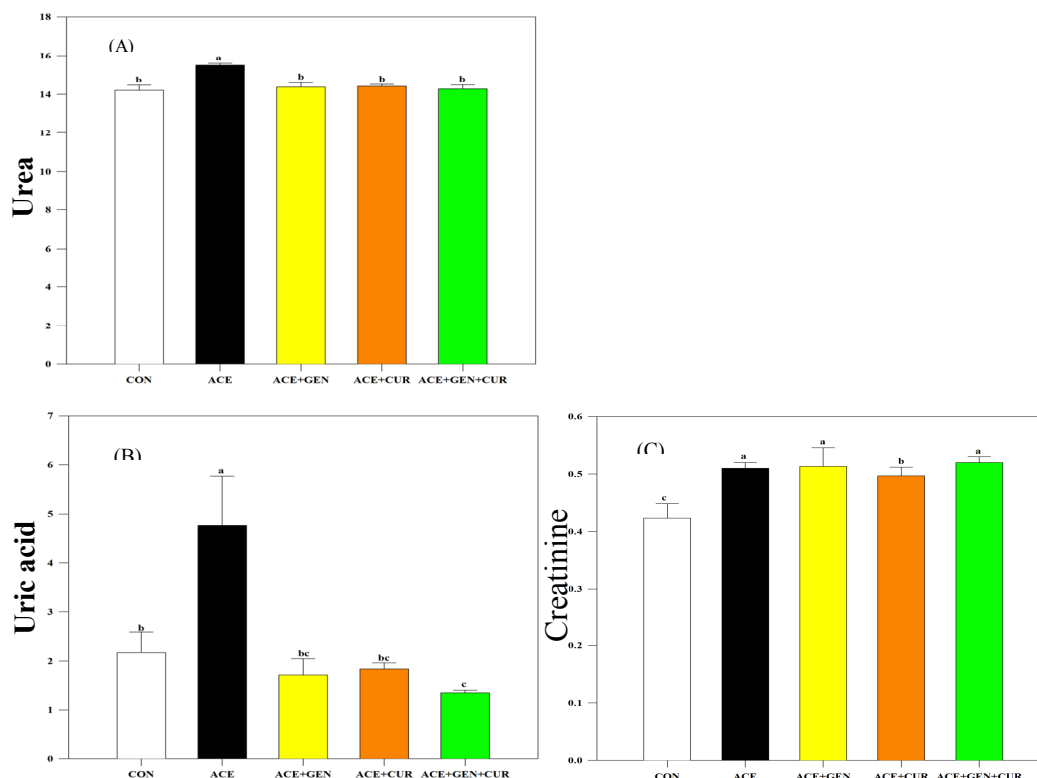


Figure (2): Biochemical alterations in urea mg/dl (A), uric acid (UA) mg/dl (B) and creatinine mg/dl in chickens of different groups exposed to acetone, ginger and turmeric crushed in drinking water and diet. CON control; ACE acetone; GEN ginger; TUR turmeric.

Effects of GEN and TUR on hepatic oxidative stress markers

Antioxidant enzymes play an important role in protection of the body against the harmful effects of free radicals and act as free radical scavengers in conditions associated with oxidative stress by preventing and repairing damages caused by reactive oxygen species (ROS). The main antioxidant enzymes including Glutathione S-transferase (GST) and superoxide dismutase (SOD), were determined in the current study. Moreover, malondialdehyde (MDA) was also determined as a reliable marker of lipid peroxidation in the cells. As indicated in Figure 3A, no significant alterations were noticed between ACE + GEN, ACE + TUR and untreated chickens in GST (IU/L) activity. Furthermore, adding up of

GEN with TUR significantly ($P < 0.05$) increased the GST (IU/L) activity by 12.5%. In Figure 3B, it can be also seen that; the oral administration of acetone was sharply decreased SOD (IU/L) activity by 43.42% compared to untreated normal chickens, whereas the application of GEN or TUR or GEN and TUR together significantly improved SOD activity by 17.77, 18.20 and 26.16% respectively as compared to normal chickens. In addition, MDA (mmol/ml) level as a marker of lipid peroxidation was increased in the serum of acetone treated chickens by 21.74% compared with those normal chickens ($P < 0.05$) (Figure 3C). Interestingly, GEN, TUR and GEN+ TUR treatments significantly ameliorated effects of acetone on chickens by decreasing the level of MDA.

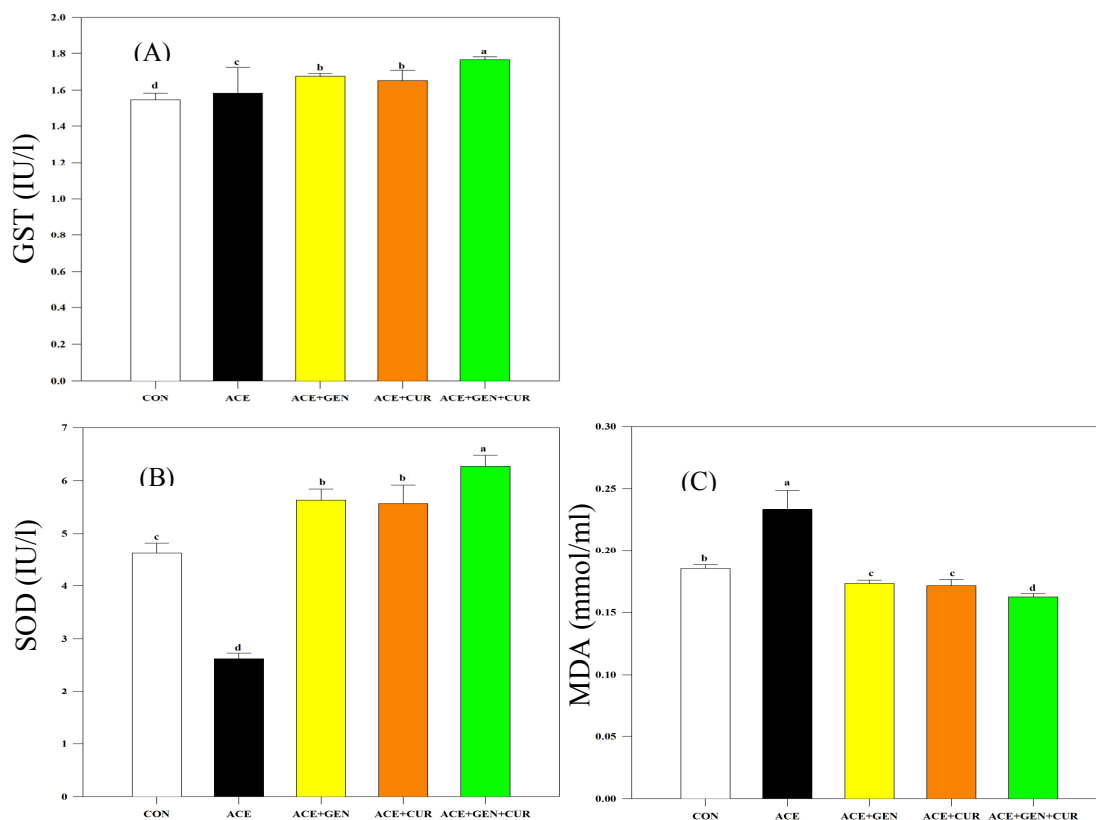


Figure (3): Alterations in GST (IU/L) (A), SOD (IU/L) (B) and MDA (mmol/ml) as the main oxidative stress marker in chickens of different groups exposed to acetone, ginger and turmeric crushed in drinking water and diet. CON control; ACE acetone; GEN ginger; TUR turmeric.

Histopathological observations

The histopathology of liver sections of the control group is shown in Figure 4A which has no pathological changes, showed normal hepatic cells with well-preserved cytoplasm, prominent nucleus, nucleolus, central vein and compact arrangement of hepatocytes separated by widened sinusoids. As shown in Figure 4B, treatment with acetone caused severe liver damage including pyknotic nuclei (pin arrows), congested blood vesicles (bold arrow), vacuolation

(zigzag arrows), loosing connective tissues (small arrows), white blood cells infiltrations with fibroblast cells. These histopathological changes were reduced in the liver of chicks treated with turmeric, ginger and its mixture respectively. Normal hepatic structure with lesser extent of hepatic changes compared to acetone group were observed. Tissue damage, congestion of central vein, cytoplasmic vacuolation and loosing connective tissues were of less extent than the acetone group (Figure 4C, D and E).

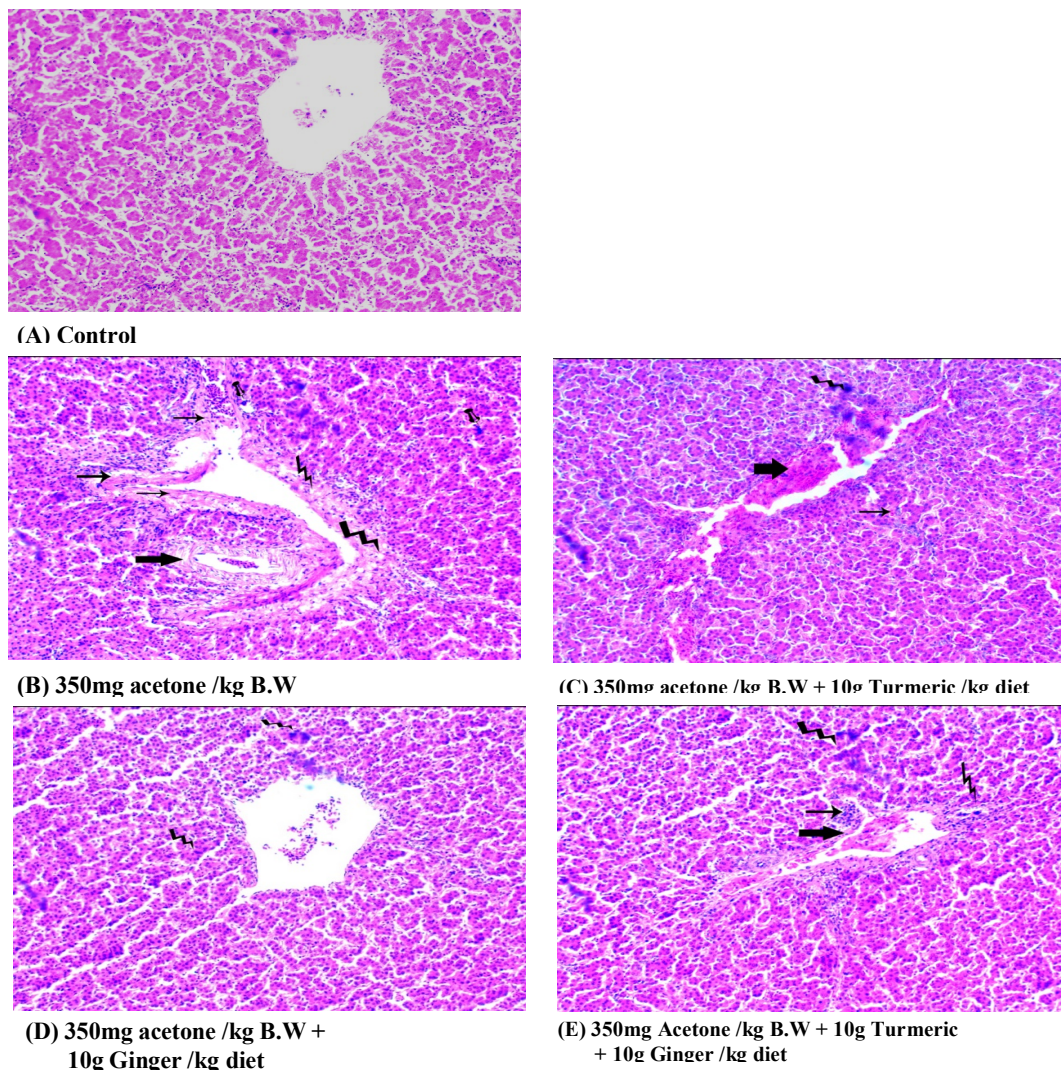


Figure (4): Histopathological examination of chick's livers control (A) and treated with acetone (B), acetone + turmeric (C), acetone + ginger (D) and acetone + turmeric + ginger (E).

(A): Control chick's liver showing no pathological changes, (B): Section of intoxicated chick's liver with acetone showing pyknotic nuclei (pin arrows), congested blood vesicles (bold arrow), vacuolation (zigzag arrows), loose connective tissues (small arrows), (C): Section of acetone + turmeric treated chick's showing improvement in the liver tissue. Arrows indicate normal hepatic cells with lesser extent of cytoplasmic vacuolation (zigzag arrow), congestion of central vein (bold arrow), loose connective tissues (small ar-

row), (D): Section of acetone + ginger treated chick's showing improvement in the liver tissue. Arrows indicate normal hepatic cells with lesser extent of cytoplasmic vacuolation (zigzag arrows), (E): Section of acetone + turmeric + ginger treated chick's showing improvement in the liver tissue. Arrows indicate normal hepatic cells with lesser extent of cytoplasmic vacuolation (zigzag arrows), congestion of central vein (bold arrow), loose connective tissues (small arrow).

Discussion

The first aim of the present study was to examine that ginger and turmeric root powder could provide attenuation effects on acetone-induced blood disorders in chickens. Administration of the toxic chemicals in animals lead to changes in hematological parameters that are indicative of hematological disorders. The alterations in hematological parameters are used to evaluate the effects of toxic condition or stress caused by environmental, nutritional or other factors (Ajagbonna *et al.*, 1999). Hematological parameters including RBCs, Hb%, PCV%, MCV, MCH and MCHC are considered good indicators of the physiological status of animals and valuable in monitoring toxicity (Khan and Zafar, 2005).

The data presented in Figure 1 demonstrated that, administration of acetone in drinking water caused a decrease in the RBCs, Hb% and PCV (Figure 1 A, B, C) and an elevation in MCV and MCH (Figure 1 D, E). However, these deleterious effects were not observed in chickens treated with GEN and TUR indicating that the ginger and turmeric which belong to the same plant family (*Zingiberaceae*) alleviated the disruption caused by acetone. Response of chickens due to dietary ginger or turmeric supplementation on hematological parameters has been evaluated in several studies. Previous study has indicated a significant improvement in both erythrocyte and leukocyte was observed when the diets of broiler chicken was supplemented with 10.0 g/kg turmeric meal (Al-Sultan, 2003). Other study suggested that these improvements were attributed to the

presence of curcumin in turmeric rhizome (Antony *et al.* 1999).

To verify whether ginger and turmeric root powder can directly improve the liver function tests, ALT, AST, ALP, LDH, GGT, glucose, total protein, albumin, globulin and albumin/globulin ratio were determined in serum of acetone treated chickens. GGT, ALT and AST are the main widely used as hepatocellular carcinoma (HCC) tumor marker. GGT is a liver enzyme that metabolizes extracellular glutathione and involves in the transport of amino acids and peptides into cells. It is mainly found in the liver cells and the main function of GGT is to enhance cysteine levels to maintain intracellular homeostasis of oxidative stress in the body (Wu *et al.*, 2016). GGT expression is often significantly increased in human tumors and its activity has been mostly regarded as a factor in reconstitution of cellular antioxidant/antitoxic defenses (Pompella *et al.*, 2006).

Most increases in serum ALT or AST levels are caused by liver damage or disease. These increases are due to additional ALT and AST are released into blood stream (Kim *et al.*, 2008). The Lactic dehydrogenase (LDH) enzyme is found in virtually all animal and human tissues. It plays an important role in cellular respiration and metabolism of glucose by catalyzing the reduction of free pyruvate to lactate and the conversion of lactate to pyruvate in glycolysis and gluconeogenesis respectively (Shamoon and Polus, 2010). Elevated LDH serum expression is often caused by heart, kidney and liver disease as well as in many different types of cancer (Faloppi *et al.*, 2016).

As expected, in the present study significant increasing in the serum concentrations of ALT, AST, LDH and GGT were observed (Table 1) by acetone stimulation, and supplementation of ginger and turmeric root powder alleviated these abnormal increments. Recent studies indicate that, turmeric and ginger have a hepatoprotective characteristic (Bardi *et al.*, 2013; Salama *et al.*, 2013). The hepatoprotective activities are mainly as result of their antioxidant properties. Other studies on liver injury showed that, curcumin and ginger provide hepatoprotective effects against CCl₄-induced acute and subacute liver damage (Patrick-Iwuanyanwu *et al.*, 2007; Gumaa *et al.*, 2017). Collectively, these studies suggest the supplementation of ginger and turmeric root powder could be a potential therapeutic strategy for hepatotoxicity.

Serum ALP concentration is usually measured to reveal changes in its activity. Elevated alkaline phosphatase is most commonly caused by many common diseases, including extrahepatic bile obstruction, intrahepatic cholestasis, infiltrative liver disease, and hepatitis. Little attention has been focused on clinical conditions associated with low or decreased ALP activity in patients (Lum, 1995). The present data suggest that administration of acetone caused decrease in ALP activity, whereas, the supplementation of ginger and turmeric root powder prevented acetone induced ALP depletion (Table 1).

Liver plays a unique role in carbohydrate metabolism. It is responsible for the balance of blood glucose

levels by glycogenogenesis and glycogenolysis (Barthel and Schmoll, 2003). The metabolic homeostasis of glucose is impaired in the presence of hepatic disease and as a result of disorders including insulin resistance, glucose intolerance and diabetes (Nielsen *et al.*, 2005; Picardi *et al.*, 2006). The data in the current study demonstrate that acetone induces a significant increase in serum glucose level as a result of liver disorders and the supplementation of ginger and turmeric root powder-maintained glucose level similar to the control group (Table 1). The other liver injury biomarkers include total proteins and their fractions were determined in the present study. To differentiate between a normal and damaged liver function, estimation of total proteins is helpful as the majority of plasma proteins like albumins and globulins are produced in the liver (Thapa and Walia, 2007). Many measurable liver functions are reflected in the albumin concentration, total protein and others which are the markers of liver biosynthetic capacity. Albumin is the main protein in blood which produced by the liver. Serum albumin level can be used as a supplementary test for hepatic biosynthetic functions (Singh *et al.*, 2011). Hepatotoxicity leads to decrease in albumin biosynthesis. In this respect, our data revealed that, acetone is the only group leads to depletion in serum albumin level (Table 1) as a result of hepatocellular injury whereas, ginger and turmeric supplementation maintained serum albumin concentration at a level similar to the control group. It is confirmed that, they have a protec-

tive effect against hepatotoxicity caused by acetone treatment.

In addition, the nephrotoxicity of acetone has also been investigated in our study. Blood urea, creatinine and uric acid as markers of kidney functions were evaluated. Urea is major end product of amino acid catabolism, produced by liver. It is filtered out of blood by glomeruli in kidneys (Corbett, 2008). It is useful to diagnosis of acute renal failure and an increase in blood urea may be associated with kidney disease (Mitchell and Kline, 2006). Uric acid is an end oxidation product of purine metabolism (Johnson *et al.*, 2011). It is renally excreted and elevated serum uric acid levels may be associated with reduced glomerular filtration rate. It plays an important role in the pathophysiology of possibly in chronic and acute kidney disease (Giordano *et al.*, 2015). Creatinine is a small tripeptide and muscle waste product (Levey *et al.*, 1999). A high serum level of creatinine indicates that the kidneys may not be working properly. It is usually a more accurate marker of kidney function than urea (Jafar *et al.*, 2005). Data in our study indicated that, the acetone administration caused an elevation in serum urea, uric acid and creatinine as a result of glomerular injury. The observed elevation in serum urea, uric acid and creatinine caused by acetone suggest that renal function impairment which might result from intrinsic renal lesions, degeneration of the apical microvilli of renal tubules, congestion or distention of renal tubules or glomeruli caused by this organic solvent (ATSDR, 2011). The deleterious effects of acetone on kid-

ney functions were not observed in chickens treated with GEN or TUR or GEN+TUR at the same time of treatment with acetone indicating that the ginger and turmeric supplementation protected the tissue against congestion or distention of renal tubules and cellular disruption caused by acetone.

In order to examine the effect of ginger and turmeric root powder to alleviate the oxidative stress caused by acetone administration, GST and SOD antioxidant enzyme activities were determined as reliable marker of oxidative stress (Noeman *et al.*, 2011). In addition, MDA level was determined as an end product of lipid peroxidation and also reliable marker of oxidative stress (Onlom *et al.*, 2017). Our results clearly demonstrated that, the ginger and turmeric root powder counteracted acetone induced oxidative stress and ameliorated its effects on antioxidant enzyme activities. In addition, hepatic MDA levels were excellently reduced by ginger and turmeric administration compared to acetone treated group. The observed improvement in biochemical and hematological parameters determined in our study by ginger and turmeric administration suggest that ginger and turmeric have a hepatoprotective characteristic. The chemopreventive effects of ginger and turmeric are not well understood but are mainly a result of their antioxidant properties (Kawamori *et al.*, 1999, Banerjee *et al.*, 2002), up-regulation of carcinogen-detoxifying enzymes (Nakamura *et al.*, 2004), anti-inflammatory (Limtrakul *et al.*, 1997, Lantz *et al.*, 2007) activity as well as their ability to decrease the

formation of pro-inflammatory cytokines.

Histologically, treatment chicks with acetone in the current study, may induce hepatic necrosis or apoptosis which appeared by the presence of irreversible condensation of chromatin in nuclei of some hepatocytes (pyknosis). Cytoplasmic vacuolation was also observed in some hepatocytes, which strongly suggest the presence of ultrastructural changes include deposition of fat droplets (Watanabe and Yanagita, 1983), excess accumulation of glycogen (Nayak et al., 1996), mitochondrial changes (Vickers, 2009), and multiple vacuoles with poor cytoplasmic architecture (Adewole and Ojewole, 2007). Our findings concerning increasing values of AST, ALT and LDH, as well as appearance of necrosis caused by acetone treatment are in agreement with those of other authors who showed that, the appearance of necrosis with vacuolation seemed to be associated with increased levels of hepatic biomarkers such as ALT, AST and LDH (Shimada et al., 2015). As far as we know, this is the first study to show a cell necrosis and vacuolization induced by acetone toxicity. Furthermore, the results of the present work showed that, addition of turmeric, ginger and its mixture respectively, alleviate the effects of acetone and showed normal hepatic structure with lesser extent of hepatic changes compared to acetone group. This effect may be due to containing turmeric and ginger a variety of compounds which have antioxidant, anti-inflammatory and anticarcinogenic

activities (Manju and Nalini, 2005, Maizura et al., 2011).

In conclusion, this study demonstrated the effects of ginger and turmeric root powder against liver injury induced by acetone in chickens. Ginger and turmeric strongly enhanced the protection of liver against injury induced by acetone. This was observed by non-significant alterations which were recorded between ACE + GEN, ACE + TUR, ACE + GEN + TUR groups and untreated chickens in some hematological and biochemical parameters which estimated in our study. These findings suggest that ginger and turmeric root powder are a potential candidate for hepatotoxic therapeutics. Further studies are necessary to elucidate the mechanism of action of ginger and turmeric root powder as a hepatoprotective agents.

References

- Adewole S.O. and Ojewole J.A. (2007). *Artocarpus communis* Forst Root-bark aqueous extract- and streptozotocin-induced ultrastructural and metabolic changes in hepatic tissues of Wistar rats. *Afr. J. Tradit. Complement. Altern. Med.*, 4:397–410.
- Aggarwal B.B., Kumar A., Bharti A.C. (2003). Anticancer potential of curcumin: preclinical and clinical studies. *Anticancer Res*; 23:363-398.
- Ahmed R.S., Seth V., Banerjee B.D. (2000). Influence of dietary ginger (*Zingiber officinales* Rosc) on antioxidant defense system in rat: comparison with ascorbic acid. *Indian J Exp Biol*; 38:604-606.
- Ajagbonna, O.P., Onifada, K.I., Suleiman U. (1999). Haematological and biochemical changes in rat

- given extract of *Calatropis Procera* Sokoto J. Vet. Sci.1:36-42.
- Al-Sultan S.I. (2003). The effect of *Curcuma longa* (turmeric) on overall performance of broiler chickens. *Int J Poult Sci.* 2:351-353.
- Antony S., Kuttan R., Kuttan G. (1999). Immunomodulatory activity of curcumin. *Immunol Investig.* 28:291-303.
- Armutcu F., Coskun O., Gurel A., Sahin S., Kanter M., Cihan A., Numanoglu K.V., Altinyazar C. (2005). Vitamin E protects against acetone-induced oxidative stress in rat red blood cells. *Cell biology and Toxicology.* 21:53-60.
- ATSDR (2011). Agency for Toxic Substances and Disease Registry Division of Toxicology and Environmental Medicine Atlanta, August 2011.
- Ayala I., Castillo A.M., Adanez G., Fernandez-Rufete A., Perez B.G., Castells M.T. (2009). "Hyperlipidemic chicken as a model of non-alcoholic steatohepatitis," *Experimental Biology and Medicine.* 234: 10-16.
- Babson, A.L. (1965). Phenolphthalein Monophosphate: A new substrate for alkaline phosphatase, *Clin. Chem.* 11: 789-795.
- Banerjee S., Bueso-Ramos C., Aggarwal B.B. (2002). Suppression of 7,12-dimethylbenz(a)anthracene-induced mammary carcinogenesis in rats by resveratrol: role of nuclear factor- κ B, cyclooxygenase 2, and matrix metalloprotease 9. *Cancer Res*;62: 4945 – 4954.
- Bardi D.A., Halabi M.F., Abdullah N.A., Rouhollahi E., Hajrezaie M., Abdulla M.A. (2013). In Vivo evaluation of ethanolic extract of *Zingiber officinale* Rhizomes for its protective effect against liver cirrhosis. *BioMed Research Internationala.* Article ID 918460.
- Barthel A. and Schmoll D. (2003). Novel concepts in insulin regulation of hepatic gluconeogenesis. *Am J Physiol Endocrinol Metab*; 285: 685-692.
- Battaller R. and Brenner D. A. (2005). "Liver fibrosis," *The Journal of Clinical Investigation*, 115: 209–218.
- Bode A. (2003). Ginger is an effective inhibitor of HCT116 human colorectal carcinoma in vivo. *Frontiers in Cancer Prevention Research Conference.* Phoenix (AZ).
- Campbell, T. W., (1995). *Avian hematology and cytology* (2nd). Iowa state university press, Ames, pp.104.
- Chainani W.U. (2003). Safety and anti-inflammatory activity of curcumin: a component of turmeric (*Curcuma longa*). *J. Alter. Comp. Med.* 9:161-168.
- Cheng A.L., Hsu C.H., Lin J.K. (2001). Phase I clinical trial of curcumin, a chemopreventive agent, in patients with high-risk or pre-malignant lesions. *Anticancer Res*; 21:2895-2900.
- Cho J.W., Lee K.S., Kim C.W. (2007). Curcumin attenuates the expression of IL-1 β , IL-6, and TNF- α as well as cyclin E in TNF- α -treated HaCaT cells; NF κ B and MAPKs as potential upstream targets. *Int J Mol Med*;19: 469-474.
- Corbett J.V. (2008). *Laboratory tests and diagnostic procedures with nursing diagnoses.* 7th Ed. 90-107.
- Doumas, B.T.; Watson, W.A., Biggs, H.G. (1971). Determination of serum albumin. *J. Clin. Chem. Acta.*, 31: 87-89.
- Drew P., Charles R.J.S., Trevor B., John L. (2004). *Oxford Handbook of Clinical Haematology.* 2th Edition, Oxford University Press, US.

- Duncan D.B. (1955). Multiple range and multiple F tests. *Biometrics* 11:1-42.
- Faloppi L., Bianconi M., Memeo R., Gardini C.A., Giampieri R. Bittoni A., Andrikou K., Del Prete M., Cascinu S., Scartozzi M. (2016). Lactate Dehydrogenase in Hepatocellular Carcinoma: Something Old, Something New. *BioMed research international*.71: 962-980.
- Freida, L.C. (1990). *Histotechnology: A Self-Instructional Text*, p. 90.
- Giordano, C., Karasik, O., King-Morris, K. and Asmar, A. (2015). Uric Acid as a Marker of Kidney Disease: Review of the Current Literature. *Disease Markers*. 382918.
- Grzanna R., Lindmark L., Frondoza C.G. (2005). Ginger-an herbal medicinal product with broad anti-inflammatory actions. *J Med Food*; 8: 125-132.
- Gumaa S.A., Hassan E.M. Khalifa D.M. (2017). Hepatoprotective effect of aqueous extracts of some medicinal plant mixtures on CCl₄-Induced Liver Toxicity. *J. Pharm. Biol. Sci.* 12:43-52.
- Habig W.H., Pabst M.J., Jakoby, W.B. (1974). Glutathione-S-transferases: The first enzymatic step in mercapturic acid formation. *J. Biol. Chem.* 249:7130-7139.
- Horecker B.L., and Kornberg A. (1948). The extinction coefficients of the reduced band of pyridine nucleotides. *J. Biol. Chem.* 175: 385-390.
- Huang MT, Lysz T, Ferraro T. (1991). Inhibitory effects of curcumin on *in vitro* lipoxygenase and cyclooxygenase activities in mouse epidermis. *Cancer Res*; 51:813-819.
- Ireson C., Orr S., Jones D.J. (2001). Characterization of metabolites of the chemopreventive agent curcumin in human and rat hepatocytes and in the rat *in vivo*, and evaluation of their ability to inhibit phorbol ester-induced prostaglandin E2 production. *Cancer Res*; 61:1058-1064.
- Ishiguro K., Ando T., Maeda O. (2007). Ginger ingredients reduce viability of gastric cancer cells via distinct mechanisms. *Biochem Biophys Res Commun*; 362: 218 – 223.
- Jafar T.H., Christopher H., Schmid A., Levey A.S. (2005). Serum creatinine as marker of kidney function in South Asians: A Study of Reduced GFR in Adults in Pakistan. *J. Am. Soc. Nephrol* 16: 1413–1419.
- Jain S.K., McVie R., Duett J., Herbst J.J. (1989). Erythrocyte membrane lipid peroxidation and glycosylated hemoglobin in diabetes. *Diabetes*; 38:1539–1543.
- Johnson R.J., Lanasa M.A., Gaucher E.A. (2011). “Uric acid: a danger signal from the RNA world that may have a role in the epidemic of obesity, metabolic syndrome, and cardiorenal disease: evolutionary considerations,” *Seminars in Nephrology* 31: 394–399.
- Jolad S.D., Lantz R.C., Solyom A.M., Chen G.J., Bates R.B., Timmermann B.N. (2004). Fresh organically grown ginger (*Zingiber officinale*): composition and effects on LPS-induced PGE2 production. *Phytochemistry*; 65:1937-1954.
- Kakkar P., Das B., Viswanathan P.N. (1984). A modified spectrophotometric assay of superoxide dismutase. *Indian J Biochem Biophys*; 21: 130-132.
- Kalapos M.P. (1999). Possible physiological roles of acetone metabolism in humans. *Medical Hypotheses*. 53: 236-242.

- Kawamori T., Lubet R., Steele V.E. (1999). Chemopreventative effect of curcumin, a naturally occurring anti-inflammatory agent, during the promotion/progression stages of colon cancer. *Cancer Res*, 59: 597-601.
- Khan T.A. and Zafar F. (2005). Haematological study in response to varying doses of estrogen in broiler chicken. *Int. J. Poul. Sci*, 4:748-751.
- Kim J.K., Kim Y., Na K.M., Surh Y.J. and Kim T.Y. (2007). [6]-Gingerol prevents UVB-induced ROS production and COX-2 expression *in vitro* and *in vivo*. *Free Radical Research* 41: 603-614.
- Kim S.O., Chun K.S., Kundu J.K., Surh Y.J. (2004). Inhibitory effects of [6]-gingerol on PMA-induced COX-2 expression and activation of NF-KB and p38 MAPK in mouse skin. *Biofactors*; 21:27-31.
- Kim W.R., Flamm S.L., Di Bisceglie A.M., Bodenheimer H.C. (2008). Serum activity of alanine aminotransferase (ALT) as an indicator of health and disease. *Hepatology*, 47: 1363-1370.
- Konuk, T., (1975). Practice of Physiology-1 "Pratik Fizyoloji-1". Ankara: Ankara University Veteriner Fakültesi, A.U. Basimevi, No: 314.
- Lantz R.C., Chen G.J., Sarihan M., Solyom A.M., Jolad S.D., Timmermann B.N. (2007). The effect of extracts from ginger rhizome on inflammatory mediator production. *Phytomedicine*;1 4:123-128.
- Lee E., Surh Y.J. (1998). Induction of apoptosis in HL-60 cells by pungent vanilloids, [6]-gingerol and [6]-paradol. *Cancer Lett*;134: 163-168.
- Levey A.S., Bosch J.P., Lewis J.B., Greene T., Rogers N., Roth D. (1999). A more accurate method to estimate glomerular filtration rate from serum creatinine: A new prediction equation. Modification of Diet in Renal Disease Study Group. *Ann Intern Med* 130: 461-470.
- Limtrakul P., Lipigorngoson S., Namwong O. (1997). Inhibitory effect of dietary curcumin on skin carcinogenesis in mice. *Cancer Lett*, 116: 197-203
- Liu J.Y., Lin S.J., Lin J.K. (1993). Inhibitory effects of curcumin on protein kinase C activity induced by 12-O-tetradecanoyl-phorbol-13-acetate in NIH3T3 cells. *Carcinogenesis*. 14:857-861.
- Lucas C.E., Ledgerwood A.M. (1992). Treatment of the injured liver. In: Nyhus LM, Baker RJ, editors. *Mastery of surgery*. 2nd ed. Boston/Toronto/London: Little, Brown & Co. p. 850.
- Lum G. (1995). Significance of low serum alkaline phosphatase activity in a predominantly adult male population. *Clin. Chem*. 41: 515-518.
- Maizura M., Aminah A., Wan Aida, W.M. (2011). Total phenolic content and antioxidant activity of ke-sum (*Polygonum minus*), ginger (*Zingiber officinale*) and turmeric (*Curcuma longa*) extract *Inter. Food Res. J*. 18: 529-534.
- Makovicky P., Dudova M., Tumova E., Rajmon R., Vodkova Z. (2011). "Experimental study of non-alcoholic fatty liver disease (NAFLD) on a model of starving chickens: is generalization of steatosis accompanied by fibrosis of the liver tissue?" *Pathology Research and Practice*, 207: 151-155.
- Manju V., Nalini N. (2005). Chemopreventive efficacy of ginger, a naturally occurring anticarcinogen during the initiation, post-initiation stages of 1,2 dimethylhydrazine-

- induced colon cancer. *Clin Chim Acta*; 358:60-67.
- Mitchell H.R. and Kline W. (2006). Core curriculum in nephrology, Renal Function Testing. *Am J Kidney Dis*; 47: 174-183.
- Morgott, A. (1993). Acetone" in G.D. Clayton, R.E. Clayton (Eds): *Patty's Industrial Hygiene and Toxicology*, 4th ed., Volume 2A, Wiley & Sons, New York, NY, 1993
- Murakami A., Tanaka T., Lee J.Y. (2004). Zerumbone, a sesquiterpene in subtropical ginger, suppresses skin tumor initiation and promotion stages in ICR mice. *Int J Cancer*;110: 481-490.
- Nagasawa H., Watanabe K., Inatomi H. (2002). Effects of bitter melon (*Momordica charantia*) or ginger rhizome (*Zingiber officinale* rosc) on spontaneous mammary tumorigenesis in SHN mice. *Am. J. Chin. Med.*; 30:195 – 205.
- Nakamura Y., Yoshida C., Murakami A., Ohigashi H., Osawa T., Uchida K., Zerumbone A. (2004). a tropical ginger sesquiterpene, activates phase II drug metabolizing enzymes. *FEBS Lett* 572:245- 250.
- Nayak N.C., Sathar S.A., Mughal S., Duttagupta S., Mathur M., Chopra P. (1996). The nature and significance of liver cell vacuolation following hepatocellular injury – an analysis based on observations on rats rendered tolerant to hepatotoxic damage. *Virchows. Arch.*, 428:353-365.
- Nielsen M.F., Caumo A., Aagaard N.K., Chandramouli V., Schumann W.C., Landau B.R., Schmitz O., Vilstrup H. (2005). Contribution of defects in glucose uptake to carbohydrate intolerance in liver cirrhosis: assessment during physiological glucose and insulin concentrations. *Am J Physiol Gastrointest Liver Physiol*. 288:1135-1143.
- Noeman S.A., Hamooda H.E., Baalash A.A. (2011). Biochemical study of oxidative stress markers in the liver, kidney and heart of high fat diet induced obesity in rats. *Diabetol Metab Syndr*. 3:17.
- Nonn L., Duong D., Peehl D.M. (2007). Chemopreventive anti-inflammatory activities of curcumin and other phytochemicals mediated by MAP kinase phosphatase-5 in prostate cells. *Carcinogenesis*; 28:1188 –1196.
- Onlom C., Phrompittayarat W., Putalun W., Waranuch N., Ingkaninan K. (2017). Immunoaffinity knockout of saponin glycosides from *Asparagus racemosus* to assess antilipid peroxidation. *Phytochem Anal.*; 28: 316-323.
- Patrick-Iwuanyanwu K.C., Wegwu M.O., Ayalogu E.O. (2007). Prevention of CCl₄-Induced liver damage by ginger, garlic and vitamin E. *Pakistan J. Biol. Sci.* 10:617-621.
- Peirce A. (1999). *The American Pharmaceutical Association Practical Guide to Natural Medicines*. New York, NY: The Stonesong Press, Inc., 1999.
- Peters, T.J. (1968). Proposals for standardization of total protein assays. *J. Clin. Chem.*, 14: 1147.
- Picardi A., D'Avola D., Gentilucci U.V., Galati G., Fiori E., Spataro S., Afeltra A. (2006). Diabetes in chronic liver disease: from old concepts to new evidence. *Diabetes Metab Res Rev* 22: 274-283.
- Pompella A., De Tata V., Paolicchi A., Zunino F. (2006). Expression of gamma-glutamyltransferase in cancer cells and its significance in drug resistance. *Biochem Pharmacol.* 71: 231-238.

- Reitman, S. and Frankel, S. (1957). Colourometric of serum transaminases. *Am. J. Clin. Pathol.*, 28:56
- Rhode J., Zick S.M., Fogoros S., Wahl H., Huang J., Rhode M., Tan L., Sorenson D., Liu J.R. (2007). Ginger induces apoptosis, autophagocytosis and growth inhibition in ovarian cancer cells. *BMC Complementary and Alternative Medicine*. 7:44.
- Rosalki S.B., Rao D., Lehman D., Prentice M. (1970). Determination of serum gamma-glutamyl transpeptidase activity and its clinical applications. *Annals of Clinical Biochemistry*, 7:143-144.
- Salama S.M., Abdulla M.A., Al-Rashdi A.S., Ismail S., Alkiyumi S.S., Golbabapour S. (2013). Hepatoprotective effect of ethanolic extract of *Curcuma longa* on thioacetamide induced liver cirrhosis in rats *BMC Complementary and Alternative Medicine* 13:56-61.
- Schuppan D. and Kim Y.O. (2013). Evolving therapies for liver fibrosis. *The Journal of Clinical Investigation*. 123: 1887–1901.
- Schwertner H.A. and Rios D.C. (2007). High-performance liquid chromatographic analysis of 6-gingerol, 8-gingerol, 10-gingerol, and 6-shogaol in ginger-containing dietary supplements, spices, teas, and beverages. *Journal of Chromatography B* 856: 41-47.
- Shamoon R.P. and Polus R.K. (2010). Serum Lactic Dehydrogenase (LDH) Activity in Lymphomas: Prognostic Significance and Relationship to Presentation, Stage and Histologic Type. *Zanco J. Med. Sci.*, 14:85-89.
- Shimada Y., Tomita M., Yoshida T., Fukuyama T., Katoh Y., Ohnuma-Koyama A., Takahashi N., Soma K., Kojima S., Ohtsuka R., Takeda M., Kuwahara M., Harada T. (2015). Inhibition of lipopolysaccharide-induced liver injury in rats treated with a hepatic drug-metabolizing enzyme inducer p,p'-DDT. *Exp. Toxicol. Pathol.*, 67:245-51.
- Singh A., Bhat T.K., Sharma O.P. (2011). Clinical Biochemistry of Hepatotoxicity. *J Clinic Toxicol* S4:001
- Surh Y.J., Chun K.S., Cha H.H. (2001). Molecular mechanisms underlying chemopreventive activities of anti-inflammatory phytochemicals: down-regulation of COX-2 and iNOS through suppression of NFkappa B activation. *Mutat Res*; 481:243- 268.
- Thapa B.R. and Walia A. (2007). Liver function tests and their interpretation. *Indian J Pediatr* 74: 663-671.
- Tietz, N. W., (1986). *textbook of clinical chemistry*. W. B. Saunders, Philadelphia, p 1271- 1281.
- Tietz, N. W., and Saunders, W. B., (1990). *clinical guide to laboratory tests*: 2nd ed. Philadelphia: 26-29
- Vickers A.E. (2009). Characterization of hepatic mitochondrial injury induced by fatty acidoxidation inhibitors. *Toxicol. Pathol.*, 37:78–88.
- Wang C., Zhang T., Cui X., Li S., Zhao X., Zhong X. (2013). "Hepatoprotective effects of a chinese herbal formula, longyin decoction, on carbon-tetrachloride-induced liver injury in chickens," *Evidence-based Complementary and Alternative Medicine*, Article ID 392743, 9 pages.
- Wang G., Li X., Huang F. (2005). Antitumor effect of h-elemene in nonsmall-cell lung cancer cells is mediated via induction of cell cycle arrest and apoptotic cell death. *Cell Mol Life Sci*. 62:881- 893.
- Watanabe M. and Yanagita T. (1983). Toxicological studies on the influ-

- ence of diazepam following prolonged administration of ethanol in the rhesus monkey and rat. *J. Toxicol. Sci.*, 8:243- 267.
- White L.B. and Foster S. (2000). *The Herbal Drugstore*. Emaus, PA: Rodale Inc.
- Wu S.J., Lin Y.X., Ye H., Xiong X.Z., Li F.Y., Cheng N.S. (2016). Prognostic value of alkaline phosphatase, gamma-glutamyl transpeptidase and lactate dehydrogenase in hepatocellular carcinoma patients treated with liver resection. *Int J Surg*. 36:143-151.
- Yoshimi N., Wang A., Morishita Y. (1992). Modifying effects of fungal and herb metabolites on azoxymethane-induced intestinal carcinogenesis in rats. *Jpn J Cancer Res*; 83:1273-1278.
- Young-Joon S. (1999). Molecular mechanisms of chemopreventive effects of selected dietary and medicinal phenolic substances. *Mutat Res.*; 428:305–327.

تقليل تأثير الاسيتون المحفز لحدوث ضرر في الكبد والكلبي بواسطة مسحوق جذور الزنجبيل والكرم في الدجاج

عاطف عبد المحسن عبد الرحمن^١، حماده عبد الحميد مهني علوان^٢، سالي محمد عبد العزيز الشافعي^١ و
ايمن عبد الحميد محمد عبد الحفيظ^٢

^١ قسم الكيمياء الزراعية - كلية الزراعة - جامعه المنيا- مصر
^٢ قسم الإنتاج الحيواني والداجني - كلية الزراعة - جامعه المنيا- مصر

المخلص

عاده ما يستخدم الزنجبيل والكرم في الطعام كتوابل بالإضافة الا ان لهم نشاط مضاد للأكسدة. وبالرغم من ذلك فان التأثير الوقائي للكبد والكلبي لكل من الزنجبيل والكرم لم تتم دراستهم بشكل كاف. لذلك فان الدراسة الحالية قد استخدمت الدجاج كنموذج لدراسة تأثير الاسيتون كمادة محفزة لحدوث اضرار في الكبد والكلبي وذلك بهدف تقييم التأثير الوقائي للكبد والكلبي لكل من الزنجبيل والكرم حيث أن الوظائف التمثيلية لكل من كبد الدجاج والانسان متشابهة. ولقد تم تقسيم ٨٠ ذكر من الدجاج عشوائيا الي خمسة مجموعات استخدمت الاولى كمجموعه ضابطة. اما المجموعة الثانية فقد عوملت بـ ٣٥٠ ملليجرام اسيتون / كجم وزن جسم (أعطيت لها في ماء الشرب) يوميا لمدة ٣٠ يوم. أما المجموعات الثالثة والرابعة والخامسة فقد عوملت بكل من الزنجبيل والكرم بالإضافة الي خليط منهم بنسبه ١ % على التوالي عقب المعاملة بالأسيتون. ومن خلال هذه الدراسة فقد تم تقدير بعض القياسات الهيماتولوجيه ووظائف الكبد والكلبي، نشاط انزيمات الاجهاد الاوكسيدي الكبدي بالإضافة الي الفحص النسيجي للخلايا الكبدية. ولقد أظهرت النتائج ان معاملة الدجاج بالأسيتون أدت الي حدوث بعض التغيرات في العديد من القياسات الهيماتولوجيه بالإضافة الي بعض الانزيمات الكبدية وانزيمات الاجهاد الاوكسيدي الكبدي. الا ان الدعم الغذائي بالزنجبيل والكرم ادي الي حدوث تحسن ملحوظ في بعض القياسات الهيماتولوجيه للدجاج المعامل بالأسيتون. كذلك اتضح ان المعاملة بالزنجبيل والكرم يمكن ان تقلل من الاضرار الناتجة من المعاملة بالأسيتون في مستويات ALT, AST, ALP, LDH, GGT، سكر الجلوكوز في الدم بالإضافة الي المحتوي الكلبي من البروتين ومشتقاته. علاوة على ذلك فان الاسيتون يؤدي الي حدوث زيادة ملحوظه في مستوي اليوريا 'حامض اليوريك' بالإضافة الي الكريتينين بينما المعاملة بالزنجبيل او الكرم او الخليط منهم في نفس وقت المعاملة بالأسيتون حافظت على تركيز اليوريا وحامض اليوريك عند مستوي مشابهه من ذلك الموجود في المجموعة الضابطة. ومن المثير للاهتمام ان المعاملة بالزنجبيل 'الكرم او الخليط منهم قد أدت الي تخفيف الاضرار الناتجة عن المعاملة في الدجاج وذلك بتحسن مستويات نشاط الانزيمات المضادة للأكسدة الرئيسية (SOD, GST) بالإضافة الي MDA والذي يعتبر بمثابة المؤشر الرئيسي لأكسدة الدهون في الخلايا. ومن الناحية الهستولوجيه، فقد اظهر الأسيتون سمية كبدية في الدجاج حيث ان الخلايا الكبدية كانت حساسة للمعاملة بالأسيتون واحتوت على عدد كبير من حويصلات الدم المحتقنة، والعديد من الفجوات السيتوبلازمية، وانكماشات في انويه الخلايا بالإضافة الي حدوث تسلل في الخلايا الليمفاوية. الا ان المعاملة بالكرم والزنجبيل قد حسنت الغالبية العظمي من هذه التغيرات الكبدية. وبشكل عام فان النتائج التي توصلنا اليها تؤكد على نطاق واسع ان الدعم الغذائي بالزنجبيل والكرم ادي الي تخفيف الاضرار الحادثة في وظائف الكبد والكلبي 'القياسات الهيماتولوجيه بالإضافة الي انزيمات الاجهاد الاوكسيدي الكبدي ومن الممكن ان يكون لهم تطبيقات في مجال تطوير الأدوية الوقائية للكبد.