

RETENTION AND CHEWING EFFICIENCY OF TWO DIFFERENT DISTRIBUTIONS OF FOUR MINI-DENTAL IMPLANT IN MANDIBULAR IMPLANT RETAINED OVERDENTURES

Hala Mohamed Abd El Hameed* and Khaled Omran Sultan*

ABSTRACT

Purpose: The purpose of this research was to study the effect of two different distribution of four mini-dental implant retaining mandibular overdenture on it's retention and patient chewing efficiency.

Materials and methods: Twelve completely edentulous male patients were selected from department of Prosthodontics, Faculty of Dentistry; Suez Canal University. Patients received maxillary complete dentures opposing implant retained mandibular overdentures with four mini dental implant .The patients were randomly classified into two equal groups according to mini dental implant's distribution. **Group I** : in which patients received four mini dental implants placed equally in the intrforaminal region. **Group II** : in which patients received four mini dental implants, in the canine and the first molar regions in each side of the arch **Clinical evaluation A-Mandibular overdenture retention** . A- digital forcemeter device was used to measure mandibular overdenture retention. **B- Chewing efficiency (Masticatory performance)** Six chewing efficiency records were made for each patient as follows: 3 times periods at (one, two & three) months for the two types of (hard& soft) food The data obtained were reported in the form of mean values of both the chewing times and number of chewing strokes. Then chewing velocity (stroke/sec) were calculated. These data were recorded and statistically analyzed.

Results: The results of this study showed that there was increase in mean values of chewing efficiency of hard and soft food for both groups in favor to group II with non statistical significant difference between both groups except after three months in masticatory performance. Also there was increase in mean values of mandibular overdenture retention for both groups in favor to group II with highly statistical significant difference during all observation periods at ($p \leq 0.01$).

Conclusion: Within the limitations of this study, it may be concluded that wide distribution of immediately loaded mini-dental implants used in mandibular overdentures through posterior placement beyond the interforaminal area results in favorable response in terms of increased denture retention. This positively reflected on the patient comfort with increased his self confidence and psychological acceptance consequently, improves oral function and chewing efficiency.

*Assistant Professor of Prosthodontics, Faculty of Dentistry, Suez Canal University

INTRODUCTION

Treating edentulous patients with a severely resorbed mandibular ridge always presents a challenge to dentists. According to a survey, 66% of elderly subjects are dissatisfied with their complete dentures because of discomfort, less chewing efficiency, poor fit and retention.¹ The survey further revealed that soreness and pain cause more problems for subjects with mandibular dentures than for those with maxillary dentures.¹

Overdentures have been advocated as a means of preserving the structures associated with mandibular denture support that may augment retention and stability. Mandibular implant retained overdentures are associated with greater patient satisfaction, oral health-related quality of life and improved masticatory function.^{2,3}

Patients must have sufficient bone width for conventional dental implant placement. Hence, for patients having a narrow alveolar ridge and lacking in keratinized mucosa, conventional implants may not be the best treatment option. In this situation, mini dental implants (MDI) serve as an alternative. It was reported that four implants (MDI) were placed between the mental foramina to achieve an acceptable and sufficient retention, for a mandibular overdenture.⁴

Mini-dental implants (MDIs) are cost-effective and have fewer complications during flapless implant placement. Moreover, these implants can be used with reduced bucco-lingual dimension of bone without need of bone grafting procedures.

Therefore, MDIs are important especially in elderly patients with chronic diseases one stage flapless surgery used for MDIs placement provides several merits including improved healing and minimal postoperative discomfort and immediate restoration of mastication and esthetics during the healing period.^{5,6}

Maximum chewing efficiency might be a predictor for biting force, especially in dentate

individuals however, in elderly denture wearers, this association might be less strong because of the reduced physiological capacity. The treatment with conventional full dentures may not only result in poor chewing efficiency but also in low oral health-related quality of life. It remains unclear whether (MDIs) may have the potential to improve those parameters.⁷

Several studies demonstrated a strong correlation between the increased retention of the complete prosthesis and the improvement of the oral function, that as masticatory efficiency and occlusal force, even in the long term.^{8,9}

Long-term data on immediate implant loading exist only for inter-foraminally placed fixtures. Therefore, the aim of this study was to evaluate the influence of shifting (redistributed) implants (MDIs) from their classic inter-foraminal position to a more posterior one on denture retention and chewing efficiency.

MATERIALS AND METHODS

Twelve completely edentulous male patients were selected and informed to be candidates in this research which conducted in the department of Prosthodontics, Faculty of Dentistry; Suez Canal University. Detailed written information about treatment strategy was provided to all patients, and they signed an informed consent.

The patients' medical history and dental health are assessed. Digital Cone beam radiographs were made to estimate the amount of horizontal bone width of the mandible.

Patients were selected according to the following criteria:

- Patients, who are in reasonably good health, had firm healthy mucosa, sufficient inter-arch space Free from any systemic disorders e.g. uncontrolled diabetes, cardiac diseases, blood disorders, and neuromuscular disorders.

- Patients had a minimum period of six months from the last extraction
- Angel's class I jaw relation with no T.M.J. troubles.
- Their age ranged between 50 - 65 years.
- Patients had no previous denture experience
- Normal tongue size and behavior.
- Heavy smoker patients or have history of bad habits e.g. sever clenching, bruxism, gagging reflexes, alcohol or drug abuse are excluded.

Grouping of patients

Patients received maxillary complete dentures opposing implant retained mandibular overdentures with four mini dental implant. The patients were randomly classified into two equal groups (six patients in each group) according to mini dental implant's distribution .

Group I : in which patients received four mini dental implants placed equally in the intrforaminal region of the mandibular arch.

GroupII : in which patients received four mini dental implants , in the canine and at the first molar regions in each side of the mandibular arch .

Preparation of selected patients

All patients received complete upper and lower dentures and left for a period of two weeks follow-up. After this follow-up period, the mandibular implants were placed and the mandibular dentures were converted to implant retained overdentures.

Construction of conventional complete denture

Primary upper and lower impressions were made using alginate impression material (*Cavex CA 37, by Holand*) in suitable stock trays after their modification and poured to obtain the primary casts. Secondary impressions were made using zinc oxide and eugenol impression material (*Cavex outline, by Holand*) in a border molded acrylic special tray.

The impressions were boxed and poured in stone plaster to obtain the master casts on which the occlusion blocks were constructed. Jaw relation record was obtained and the maxillary and mandibular casts were mounted on the articulator for setting-up of teeth which were arranged using the lingualized occlusal concept. (*Acrostone plus, cross linked acrylic teeth, Egypt*) then the denture was waxed up. After trying-in the dentures, flasking, packing, processing, finishing and polishing were carried out. Delivery of the dentures was carried out after performing the necessary adjustment to correct the occlusal discrepancy, and the patients were recalled after 48 hours for the first follow-up visit. Follow-up was continued for two weeks before the start of implant placement.

Preparations for implant placement

For each patient, the lower denture was duplicated into transparent acrylic template to be used as a radiographic stent, in which four metal balls were inserted to determine the bone height at the proposed site for each mini implant (fig.1A&2A). The radiographic stent was modified to a surgical stent, by insertion of small metal tube at the corresponding implant position fixed to the stent with self-cure acrylic resin to be used as a guide during surgical drilling for implant placement.

Implant placement

The Dentium implant system (Slim line, ball type, Dentium Co., Ltd, Korea) with sand blasted acid etched screw type one piece mini-implants, 2.5 mm in diameter and 10 to 12 mm. in length were used according to bone height. The implant were inserted by single-stage flapless surgical approach.

After soft tissue punch, Flapless preparation of the implant site was done by drilling the bone with subsequent drills guided by the surgical template considering the parallelism between the four mini implants using the paralleling tools. This was repeated for the four sites in each group. (Fig 1B).

The mini-implant was removed from its sterile packing and carefully installed into the prepared osteotomy site using the holding cap. Then it was slowly rotated in a clock-wise direction with slight apical pressure. The cap becomes deformed and removed after initial placement half way into the osteotomy site.

The hex driver with the manual one attached to a ratchet wrench and was used to thread the implant to its full length with its head projecting above the

mucosa (**Fig.2B**). Primary stability of each implant was checked using the adjustable torque ratchet to confirm that the initial stability (primary fixation) was not exceeding 35/cm (**Fig.1C**). The same procedure was repeated for the other three implants. (**Fig.1D&2D**)

Post-operative panoramic radiograph was performed to evaluate mini implants placement. (**Fig.3A& 3B**)

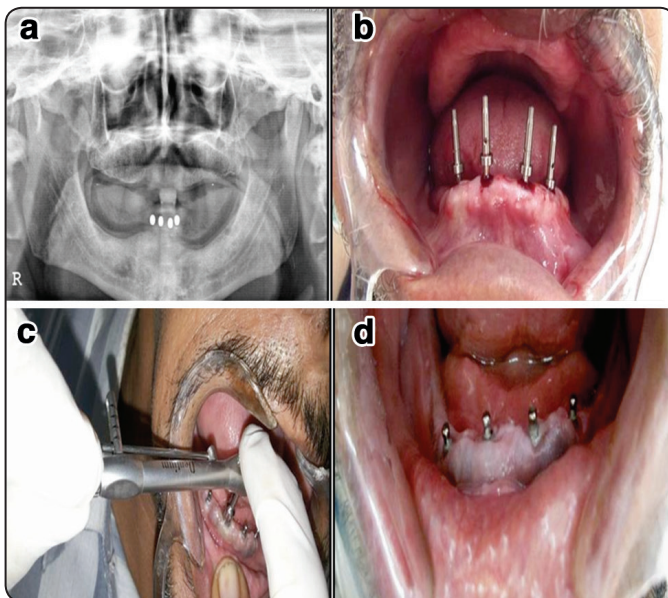


Fig. (1) A,1B,1C&1D) 4mini-implant positioned in inter-foraminal region

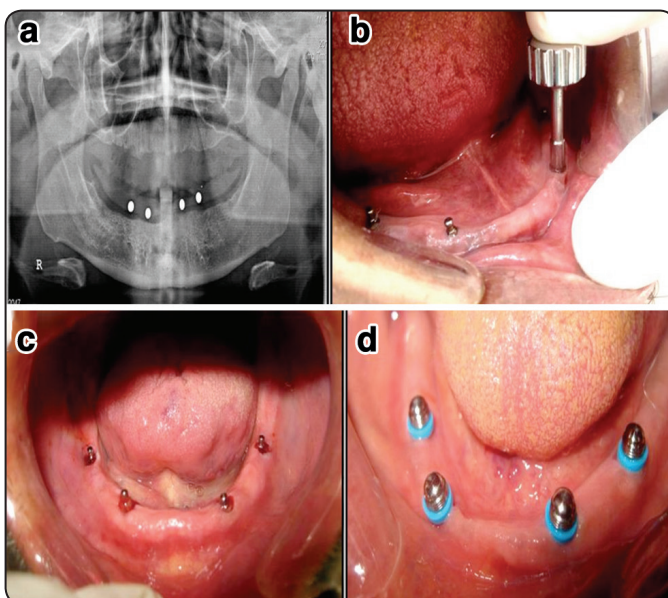


Fig. (2) A,2B,2C&2D) 4mini-implant positioned in the canine & the 1st molar regions

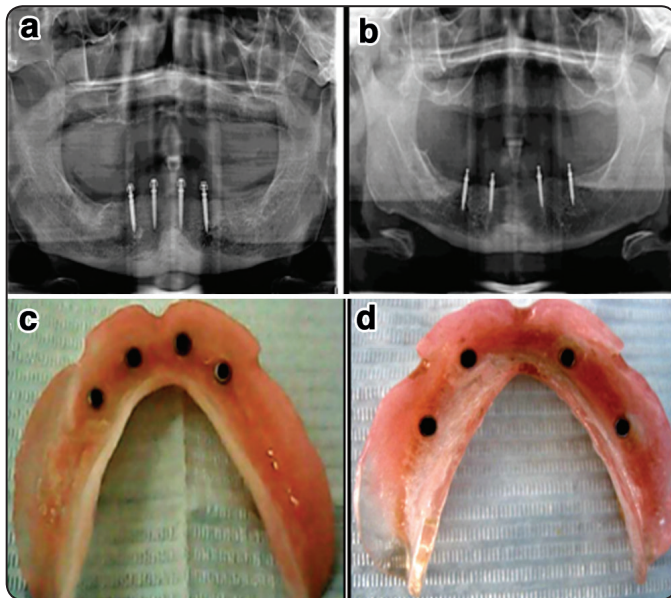


Fig. (3) A & 3B Post-operative panoramic radiograph. (Fig. 3 C&2D) finished overdenture

Direct Pick-up Procedure

Immediately after four mini implant installation, undercut areas around the mini-implant heads were carefully blocked out using sterile orthodontic O rings. The rubber rings and metallic housing caps were placed on the mini-implants (Fig. 2D). The denture base was relieved to accommodate the housing caps and the implant abutments. A small amount of acrylic resin is added to the relief areas of the denture base corresponding to the implant abutments. The denture was inserted into the oral cavity. Once the denture was properly positioned, maintaining it in a passive occlusal contact (very light centric occlusion) while the acrylic sets. Once the acrylic has cured, the denture was removed and the blockout spacers were discarded. Any excess acrylic was removed, the denture base was finished, and delivered to the patient (Fig 3 C&3D).

Patient instructions

The following Instructions were given to each patient:

- Patients were instructed to seat the mandibular denture first. Carefully place and remove the lower denture with special attention to the path of insertion

and removal and snapping of the denture fitting surface onto the implant ball-shaped heads securely.

- The patients were instructed not to eat without the dentures in place. Initially the patients should, eat soft food at the first month, avoiding tough, sticky and resistant food. They should extend the length of time necessary for chewing, should place food on both right and left sides of the mouth, and they should be cautioned on using the anterior teeth for incision.¹⁰

Clinical evaluation

A-Mandibular overdenture retention

A Digital Force Gauge (*Rongsheng –biz, Korea*) was used to record the force needed to dislodge the mandibular overdenture from its Basal Seat. It has a range about 100 Newton and supplied by: Metallic hooks with different lengths, LCD monitor and control buttons. It has the ability to record the peak tensile and compressive forces and save the record on a removable memory card (fig4A). This was done by application of three wire loops to the polished surface of the denture lingually. One in the anterior region at the midline and the other two loops were attached at the 1st molar positions

.These wires were connected to a single curved wire from which forcemeter hook was attached at the center of the denture. The Force Gauge was prepared and the unite measurement was selected in Newton while the record display before measuring should be adjusted to zero. The patient set with his lower teeth parallel to the floor. The forcemeter hook pulled vertically upward and the amount of force required to dislodge the denture was recorded. This procedure was repeated during measuring and the average values were recorded (in Newton).. Retention tests were done at (one, two & three) months from denture insertion (fig4A,4B &4C)

B-Chewing efficiency

Chewing efficiency of the two groups was evaluated for 3 months (one, two & three) months from denture insertion. During each follow-up period, standard 1 cm cubes of two different foods (Carrot and cheese) were given to each patient. He was asked to chew each food cube, measurements

of efficiency was recorded as number of chewing strokes until the patient swallowed. Then, time (in seconds) elapsed from the first chewing stroke until patient swallowing, was calculated. This procedure was repeated 3 times for each patient at each test session. Then the number of chewing velocity (stroke/sec) for each group were calculated Records were collected and values were reported and statistically analyzed.

RESULTS

Data entry and analyses were performed using statistical software program. The quantitative data were presented as mean and standard deviations. Paired t-test was used to compare between the two groups. The test was considered significant when $p \leq 0.05$ and highly significant when $p \leq 0.001$.

Chewing efficiency (Masticatory performance)

Six chewing efficiency records were made for

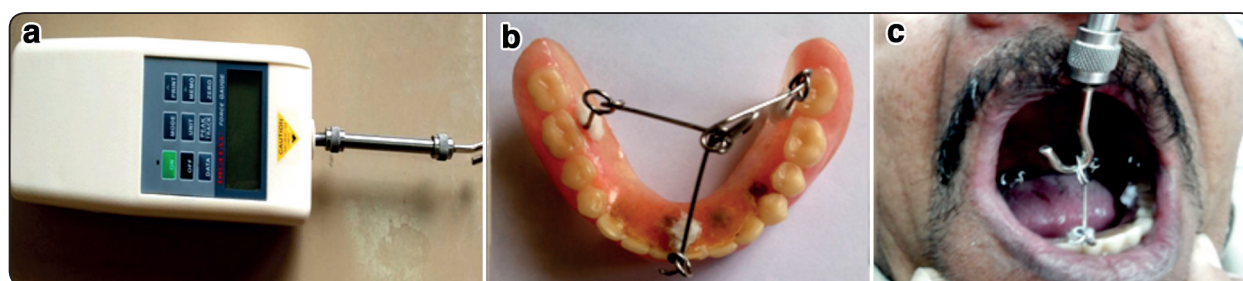


Fig. (4) A, B & C measuring mandibular overdenture retention.

TABLE (1A) Mean values of chewing efficiency for hard food

<i>Groups</i>		<i>Intervals</i>	One month	Two month	Three month
		Mean \pm SD			
group(GI)	Mean \pm SD		1.66 \pm 0.087	1.8 \pm 0.05	1.88 \pm 0.042
group(GII)	Mean \pm SD		1.71 \pm 0.052	1.83 \pm 0.048	1.91 \pm 0.023
	P		0.1	0.23	0.09

*significant at $p \leq 0.05$ ** highly significant $p \leq 0.01$ S D = Standard deviation

each patient as follows: 3 times periods (one, two & three) months for the two types of food (hard & soft) food. The data obtained for each type and at each time period were summarized and reported in the form of mean values of both the chewing times and number of chewing strokes. Then the number of chewing velocity (stroke/sec) were calculated to study the effect of the two different mini-implant distributions on **masticatory performance**.

From the following tables (1a&1b) and (fig.5A&5B) there were increase in Mean values of chewing efficiency for both hard and soft food for

the two tested groups in favor to group II (widely distributed mini-implant) but with non statistical significant difference between both groups except after three months in masticatory performance for soft food at $p \leq 0.05$

From the table (2) and (fig.5C) there were increase in mean values of mandibular overdenture retention for both groups at all the study period in favor to group II (widely distributed mini-implant) with highly statistical significant difference between both groups during all observation periods at $p \leq 0.01$

TABLE (1B) Mean values of chewing efficiency for soft food

<i>Groups</i>		<i>Intervals</i>	one month	two month	three month
		Mean \pm SD	1.64 \pm 0.046	1.71 \pm 0.033	1.76 \pm 0.034
group(GI)		Mean \pm SD	1.67 \pm 0.04	1.74 \pm 0.042	1.81 \pm 0.031
group(GII)		P	0.12	0.07	0.02*

*significant at $p \leq 0.05$ ** highly significant $p \leq 0.01$ S D = Standard deviation Mandibular overdenture retention

TABLE (2) mean values of mandibular overdenture retention (in Newton)

<i>Groups</i>		<i>Intervals</i>	one month	two month	three month
		Mean \pm SD	7.72 \pm 0.36	8.2 \pm 0.347	8.92 \pm 0.402
group(GI)		Mean \pm SD	8.63 \pm 0.308	9.23 \pm 0.344	9.88 \pm 0.47
group(GII)		P	0.003**	0.000**	0.000**

*significant at $p \leq 0.05$ ** highly significant $p \leq 0.01$ S D = Standard deviation

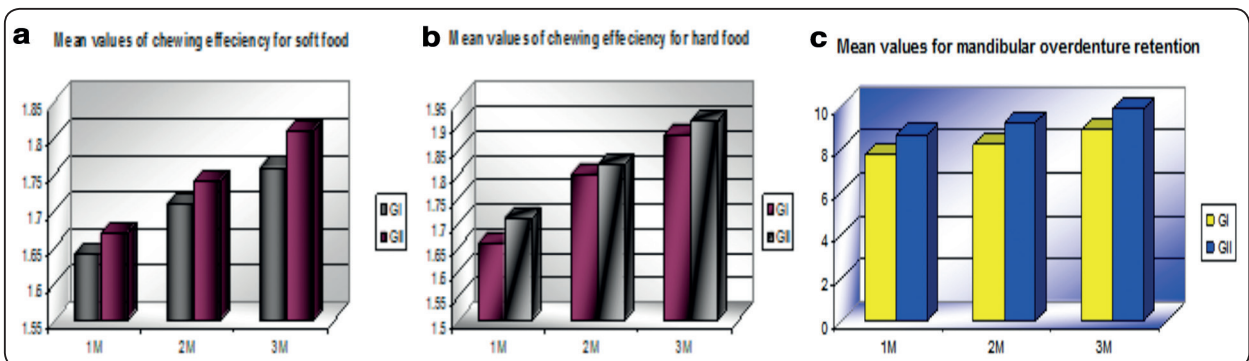


Fig. (5) A, B & C) mean values for chewing efficiency & overdenture retention

DISCUSSION

The main aim for completely edentulous patients is to obtain retentive complete denture enabling them to perform oral functions and efficient chewing ability. This in turn considered great challenge for the prosthodontics especially with compromised prosthetic bed.

In the current study, the selected patients had adequate inter-arch distance to facilitate surgical insertion of the implants and provide sufficient space for the accommodation of the ball and socket attachment in the mandibular implant supporting over-denture.

Cases with abnormal ridge relationship other than Angle's class I were excluded to avoid implant overloading.⁽¹¹⁾

The artificial teeth were arranged according to the lingualized occlusal concept to achieve lever balance by elimination of the buccal cusp contact in centric and eccentric excursions; this provides wide occlusal freedom, as well as occlusal balance and reduces lateral interferences.⁽¹²⁾

Selected patients had been completely edentulous for at least 6 months (new denture wearers). The first was to ensure complete bone healing following teeth extraction, which is essential for initial implant stability for immediate loading

Mini dental implants (MDI) are considered an alternative to the conventional implant placement regimen and are ideal for immediate loading in various bone qualities and quantities. Their conical macro-design has the advantage of allowing for the compression and expansion of the bone of the recipient site as well as the design of their buttress threads that allows for their strong self-tapping property which finally gives the primary stability needed for immediate loading.⁽¹³⁾

Immediate loading protocol was implemented in the current study as findings of research demonstrated highly predictable osseointegration with immediate loaded implants, both clinically and histologically, providing a good peri-implant

health and survival rates similar to that obtained with conventionally loaded implants. such protocol shortens dental rehabilitation times and increases patient acceptance and satisfaction.⁽¹⁴⁾

Four implants with maximum length according to the available ridge height were inserted to retain immediately loaded mandibular over denture in accordance with guidelines of immediate loading protocol and to compensate for reduced surface area of mini dental implants.⁽¹⁵⁾

Although interforaminal implant placement had been recommended for complete denture rehabilitation due to high bone quality, lack of important vital structures, and absence of physiologic mandibular bending effect at that area, the effect of the cantilever design remains the main cause of expected distal implant failure .In the present, widely separated implants were placed beyond the classical interforaminal area to negate both the cantilever effect and to allow better load distribution over a larger area.⁽¹⁶⁾

The result of the current study showed that G II had a significantly greater retention mean value than that of G1. This may be attributed to the resultant second class lever where anterior canine implants act as fulcrum (F), second premolar and first molar implants are the resistance (R), and central loop of the posterior wire where dislodging forces were applied is the force (E). Since, the resistance arm of GII was longer than that of G1. Thus G2 participants have better resistance to the posterior dislodging force.

The power required to exact a similar dislodging force would be much higher in GII due to the reduction in mechanical advantage by lengthening the resistance arm.⁽¹⁷⁾

This study was based on the hypothesis that greater retention and stability of the mandibular overdenture should improve the chewing efficiency and enhance masticatory function.

The current results also in agreement with the study concluded that factors such as denture stability and the presence of pain in denture-bearing areas

have been shown to affect chewing performance and bite force. When these limiting factors exist, the degree of support of mandibular dentures by dental implants could be important for improving the masticatory function. Finally, he recommended a wider distribution of dental implants to support mandibular overdenture⁽¹⁸⁾

However, inserting the implants further apart by shifting them more posteriorly in GII may provide a better load distribution over a larger area, allowing for a wider area for chewing and hence better denture stability.⁽¹⁹⁾

Another explanation of the increased retention and chewing efficiency in group II in relation to group I may be related to the potential for anterior-posterior rotation in GI than that in GII, Denture rotation may cause food particles to lodge under the dentures and result in difficult mastication, particularly when food is masticated with the anterior teeth.⁽²⁰⁾

Many authors concluded that denture stability by mini dental implants with patient convenience without food entrapped under the denture base directly reflected on the patient masticatory function. They explained the increased chewing efficiency after insertion of dental implants due to positive psychological effect of the more stable denture base devoid from tissue soreness and mucosal injury which are the more causes of patient discomfort.^(21,22,23)

CONCLUSION

Within the limitations of this study, it may be concluded that wide distribution of immediately loaded mini-dental implants used in mandibular overdentures through posterior placement beyond the interforaminal area results in favorable response in terms of increased denture retention. This positively reflected on the patient comfort with increased his self confidence and psychological acceptance consequently, improves oral function and chewing efficiency.

REFERENCES

- 1- Thomason JM, Feine J, Exley C, Moynihan P, Müller F, Naert I, et al. Mandibular two implant-supported overdentures as the first choice standard of care for edentulous patients—the York consensus statement. *Br Dent J* 2009; 207: 185–186.
- 2- Khilalian M, Rismanchian M, Fazel A, Basiri K, Azadeh, H, Mahmoodi M, Fayazi S & Sadr- Eshkvar P. Conventional versus implant retained overlay dentures: a pilot study of masseter and anterior temporalis electromyography. *J of Oral Implant* 2014; 40: 418–424.
- 3- Mericske-Stern R, Probst D, Fahländer F, Schellenberg M. Within-subject comparison of two rigid bar designs connecting two interforaminal implants: patients' satisfaction and prosthetic results. *Clin Implant Dent Relat Res* 2009; 11: 228–37.
- 4- Flanagan D, Mascolo A. Mini dental implant in fixed and removable prosthetics: a review. *J Oral Implantol* 2011; 37: 123–32.
- 5- Bidra, A.S. & Almas, K. Mini implants for definitive prosthodontic treatment: a systematic review. *Journal of Prosthetic Dentistry* 2013; 109: 156–164.
- 6- Elsyad MA. Patient satisfaction and prosthetic aspects with mini-implants retained mandibular overdentures. A 5-year prospective study. *Clin Oral Impl Res* 2015; 00: 1–8
- 7- Schimmel M, Christou P, Miyazaki H, Halazonetis D, Herrmann F & Müller F. A novel colourimetric technique to assess chewing function using two-coloured specimens: validation and application. *Journal of Dentistry*. 2015; 43: 955–964.
- 8- Müller F, Duvernay E, Loup A, Vazquez L, Herrmann F R. & Schimmel M. Implant supported mandibular overdentures in very old adults: a randomized controlled trial. *Journal of Dental Research* .2013; 92: 154S–160S.
- 9- Apostolakis D, Brown JE. The anterior loop of the inferior alveolar nerve: prevalence, measurement of its length and a recommendation for interforaminal implant installation based on cone beam CT imaging. *Clin Oral Impl Res* 2012; 23: 1022–30.
- 10- Abd El-wahab K., Aziz E. and Nada A.: The effect of two loading protocols on the supporting structures of mini implants supporting mandibular over-denture. P.H.D. Thesis, Cairo University. 2012.
- 11- Misch C.: Contemporary implant dentistry. 3rd Ed. St. Louis. Elsevier Mosby Missouri. 2008.

- 12- Matsumaru Y.: Influence of mandibular residual ridge resorption on objective masticatory measures of lingualized and fully bilateral balanced denture articulation. *J. Prosthodont. Res.* 2010; 54:112-118.
- 13- Zahran A. and Gould J.: Gould's technique; Clinical innovation of flapless placement of self-tapping implants with the aid of osteotomes in the posterior maxilla. *E.D.J.* 2007; 53:2297-2304.
- 14- Natio T.: Immediate loading of dental implants in selected cases may provide similar success as compared with delayed loading. *J. evid. Dent. pract.* 2005; 5:213-214.
- 15- Misch C., Wang H., Misch C. and Sharawy M.: Rationale for the application of immediate load in implant dentistry: Part II. *J. Implant Dent.* 2004; 13:310-19,
- 16- Ghali R.: Tomographic assessment of implant distribution for mandibular single denture. *E.G.J.* 2011; 57:2361-2370.
- 17- Tabatabaian F, Sabouri A, Sobhani Z. Effect of Inter-Implant Distance on Retention and Stability of Overdenture. Rotterdam, Netherlands: Proceedings of the 36th Annual Conference of the European Prosthodontic Association; Sept 6-8, 2012.
- 18- Alqutaibi AY, Kaddah AF, Farouk M. Randomized study on the effect of single-implant versus two-implant retained overdentures on implant loss and muscle activity: a 12-month follow-up report. *Int. J. Oral Maxillofac. Surg.* 2017; 1-9
- 19- Mohammed A S, Ehab M A: The effect of varying implant position in immediately loaded implant-supported mandibular overdentures: *Journal of oral implantology* . 2013;3:345-354
- 20- Kanazawa M, Feine J, Esfandiari S. Clinical guidelines and procedures for provision of mandibular overdentures on 4 mini-dental implants. *J Prosdent.* 2016; 04-020
- 21- Alam MK, Abdul Rahman S, Basri R, Sing Yi TT, Wong Si-Jie, Soumendra Dental Implants Perceiving Patients' Satisfaction in Relation to Clinical and Electromyography Study on Implant Patients. *journal.pone.* 14, 2015;1-20.
- 22- Ismail S, Aslan MA, Mustafa T, Bereket C, Selim A, Sato S. the effect of implant therapy on maximum bite force in edentulous elderly patients: an in vivo study. *Turkish J of Geriatrics.* 2015; 18: 75-80.
- 23- Enkling N, Saftig M, Worni A, Mericske-Stern R, Schimmel M. Chewing efficiency, bite force and oral health-related quality of life with narrow diameter implants - a prospective clinical study: results after one year. *Clin. Oral Impl. Res.* 2016, 1-7