



## MONITORING OCCLUSAL HARMONY/ DISHARMONY IN IMPLANT RETAINED RESTORATIONS USING DIGITAL OCCLUSAL ANALYZER

Safa'a A Asal\*, Moustafa A Hassaballa\*\* and Abdulaziz A Alkheraif\*\*\*

### **ABSTRACT**

Since dental implants are not anchored to bone with periodontal ligament, subjective evaluation of occlusion is not always reliable enough to guard against the presence of occlusal prematurities. Despite the introduction of the T-scan occlusal analyzer technology, the majority of the clinicians and dental colleges are still depending, to a great extent, on the traditional occlusion indicator materials for implant-prosthetic occlusion establishment. This study was performed to verify whether the use of the articulating paper to calibrate the occlusal contacts of prosthetic restorations is successful enough to fulfill the objectives of a balancing implant-prosthetic occlusion.

**Materials and Methods:** 40 subjects [30 females and 10 males] were selected from the out patient clinic of the Department of Prosthetic Dental Sciences, College of Dentistry, King Saud University, Riyadh. All subjects have received implant restorations where the occlusion of all cases was analyzed solely by the articulating paper. Computerized occlusal analysis was conducted using the T-Scan system III (software version 8.1). Center of force (COF), implant force percentage (IF %), occlusion time (OT), disclusion time (DT), and excursive positions were evaluated for the implants and the adjacent natural teeth. Data were collected, tabulated, and presented as frequencies and percentages. Results: 25% of the treated implant cases were reported to have optimum implant occlusion time (OT < 0.6s) and to have received implant force percentage (IF%) less than the adjacent natural teeth. Moreover, 5 implants (12.5%) were out of occlusion.

**Conclusion:** The use of the articulating paper is not an accurate enough method to employ in the implant occlusion adjustment, while the use of the T-Scan occlusal analyzer as a quantifying, non-subjective occlusal indicator may produce more comprehensive and evidence-based results.

**KEY WORDS:** Occlusion, single implant-prosthetic restoration, articulating paper, T-Scan III occlusal analyzer.

\* Assistant Professor, Department of Prosthodontics, Faculty of Dentistry, Tanta University, Egypt.

\*\* Associate Professor, Department of Prosthodontics, Faculty of Dentistry, Pharos University, Egypt.

\*\*\*Professor, Dental Technology Depart., College of Applied Medical Sciences, King Saud University.

## INTRODUCTION

A partially edentulous mouth can be restored successfully by different treatment modalities. Currently, implant restorations, which are either screw or cement retained, tends to be selected as the treatment of choice. The literature demonstrates that implant-supported single tooth replacement is a predictable procedure with high survival rates<sup>1,2</sup>. In addition, success rate is greater than 95% not only for tooth replacement, but also for the correction of the stomatognathic system<sup>3</sup>. However, one of the direct factors instigating implant complications is the occlusion. Occlusion is a very critical factor for implants longevity, because of the fixed union of the bone to the titanium-surfaced implant and due to the absence of the periodontal ligament (PDL) that has the capacity to captivate occlusal stresses. Scholars have reported that the depressability of the implant, caused by occlusal forces, is five times less than the adjacent natural teeth<sup>4</sup>, and that patients are 8 times less able to discern tactilely occlusal force excess<sup>5</sup>. The main goal, then, is to occlude the natural teeth prior to the implant prosthesis, in order to minimize the excessive load on the implant prosthesis<sup>6</sup>. Therefore, uncontrolled occlusal loads as well as occlusal interferences on implant restorations will be borne totally by the bone-implant interface, causing many problems for the implant, surrounding bone, or for the prosthesis<sup>7,8</sup>. It should be noted that different occlusal indicator materials and techniques (Articulating papers<sup>9</sup>, waxes<sup>10,11</sup>, silk ribbons, metallic shim stock film<sup>12,13</sup>, and silicone impressions<sup>5</sup>) were traditionally used to analyze occlusion and to detect occlusal prematurities. Recently, a digital occlusal analyzer has been developed. This computerized diagnostic device [T-Scan III Computerized Occlusal Analysis System, Tekscan Inc. South Boston, MA, USA] uses time and force to quantify the occlusal contact<sup>14</sup>, to capture real-time occlusal force (in 0.003 second time increments), and to record time-sequence data. There is a debate between authors: some argue that

the use of the T-Scan system is the only reliable method to analyze the occlusal contacts, because the conventional methods are disposed to inaccuracy<sup>15</sup>; while other authors claim that the intense marks obtained with the articulating paper stand for heavier occlusal contact<sup>16</sup>. However, even with the presence of the digital occlusion analyzer, which yields more precise measurements, the majority of practitioners and dental colleges still rely on the articulating paper for implant occlusion calibration. The purpose of this in vivo study was to evaluate the occlusion of implant-retained restorations that have been accepted as being optimal, based solely on articulating paper analysis and the patient's feel (feedback), relative to the occlusion balance and center of force (COF), the occlusion time (OT), the forces percentage on implants and adjacent naturals (IF%), the presence of interferences at excursive movements, and the disclusion time using the digital occlusal analyzer.

## MATERIALS AND METHODS

40 subjects [30 females: mean age (35.2) years old, and 10 males: mean age (38.1) years old] were selected from the out patient clinic of the Department of Prosthetic Dental Sciences, College of Dentistry at King Saud University- Riyadh. All subjects have received implant screw retained restorations, where the occlusion of all cases was analyzed solely by the articulating paper. All participants were selected with the following inclusion criteria: (1) successfully osseointegrated single posterior dental implant, (2) The implant is in occlusion with natural dentition, and 3) with adjacent natural dentition present. The exclusion criteria include: (1) no missing anterior teeth, and (2) no history of bruxism. The selected participants were given detailed information about the investigation as well as written informed consent for their participation. The study protocol was reviewed and approved by the Ethical Committee in the College of Dentistry. Computerized occlusal analysis was conducted using the T-Scan III system

(software version 8.1, Tekscan Inc. South Boston, MA, USA)]. The T-Scan system uses a 100-mm thick recording sensor (high- definition generation III sensor; Tekscan Inc) that scanned in 0.003-second increments. The size of the sensor (large or small) was chosen to suit the patient's dental arch. For each participant, a new sensor was fitted to a rigid, autoclavable, fork-shaped plastic holder and a proper sensitivity range was established<sup>6,14,17,18</sup>. For all scanning procedures, the participants were asked to sit in a relaxed position in the dental chair as previously used during delivery procedure. The sensor was held consistently in the same position with respect to the teeth. It was aligned to be parallel to the occlusal plane and centered on the midline between the central incisors<sup>14</sup>.

Each participant was asked to firmly occlude into the sensor with their teeth until maximum intercuspation occurred, holding their teeth together for 1 to 3 seconds, and then disocclude and re-intercusate into the sensor once again. Occlusion balance was discerned through determination of the center of force (COF). Implant force percentage (IF%) was also evaluated for both the implant and the adjacent natural teeth. The means of occlusion time (OT) and disclusion time (DT) were recorded.

For excursive positions evaluation, the participants were asked to occlude on the sensor in centric occlusion with normal pressure until maximum intercuspation occurs, then hold their teeth together for a period of 1 to 3 seconds followed by a right or left excursion movement<sup>14</sup>. This was repeated 4 times for each side, points of interferences were recorded. The sensitivity of the T-Scan sensor was recalibrated for each participant and maintained across all recordings. All the T-Scan measurements were performed by the same clinician (SA) in order to compensate for individual variations in the measuring procedure. Data were collected, tabulated, and presented as frequencies and percentages.

## RESULTS

TABLE (1) Shows frequencies and percentages of the evaluated variables

Variable		Frequency/ 40	Percent
Center of Force (COF)	Centered	22	55%
	Out of the center	18	45%
Occlusion Time (OT) s	Zero s	5	12.5%
	≤ 0.6s	10	25%
	> 0.6 s	25	62.5%
I F % at MIC	< adjacent	10	25.0%
	≥ adjacent	25	62.5%
	Out of occlusion	5	12.5%
Interferences on the working side	No interference	38	95%
	Interference	2	5%
Interferences on the non-working side	No interference	39	97.5%
	Interference	1	2.5%

**IF % : Implant force percent at maximal intercuspation,**

Table 1 shows occlusal balance in 55% of the treated cases by centralization of COF during maximum intercuspation (MIC) (Fig. 1), while 18 (45%) cases had been reported with the COF out of the center (Fig. 2). 10/40 implants (25%) were reported to have OT < 0.6s and to have received force percentage (IF%) less than the adjacent natural teeth, while 62.5% of the implants were reported to have OT > 0.6s and to have received IF% either equal to or more than the adjacent teeth (Fig. 2). Meanwhile, 5 implants (12.5%) were out of occlusion (Table 1).

On excursive positions, 2 implants (5%) had occlusal interference on the working side, while only 1 implant (2.5%) was reported with occlusal interference on the non- working side. Disclusion time was < 0.4s for all the cases.

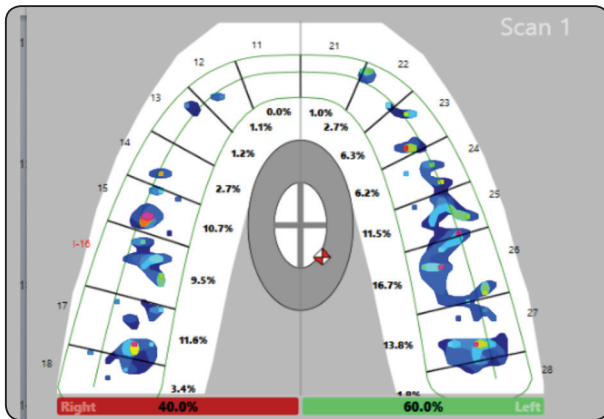


Fig. (1) Shows implant replacing tooth # 16; has IF % (9.5%) less than the adjacent teeth (#15=10.7%, #17=11.6%) with an acceptable force distribution as indicated by centralization of the COF (2D display).

This figure provides an example of Ideal cases: nearly even distribution of occlusal forces, implant having less force than adjacent teeth at the MIC, COF being centralized. OTs is longer than that for natural tooth < 0.6s. DT was < 0.4s. No interferences on eccentric positions.

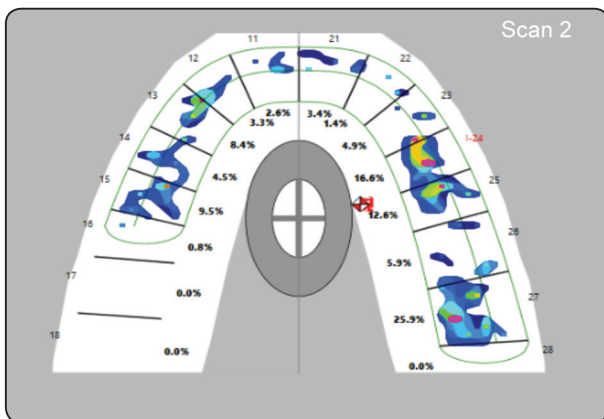


Fig. (2) Shows implant replacing tooth # 24; has IF % ( 16.6%) more than the adjacent teeth (#23=4.6%, #25=12.6%) and the COF is shifted toward the implant side. This figure is one of the cases reported with premature contacts on the tooth # 27 where IF% is 25.9% at MIC (2D display).

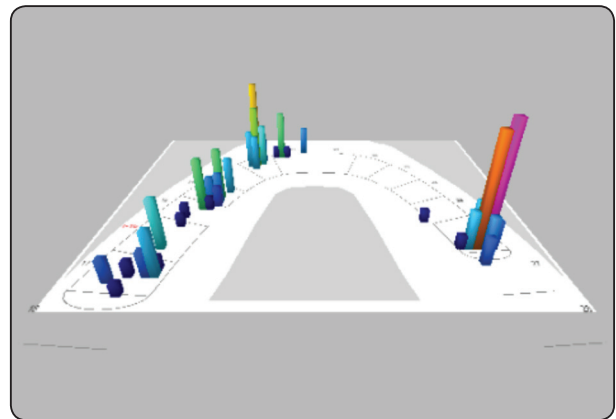


Fig. (3) Shows implant replacing tooth # 16; has right lateral excursive position with interference from natural tooth at the non-working side (3D display).

### DISCUSSION

Despite the introduction of the T-scan occlusal analyzer technology, the majority of the clinicians and dental colleges are still depending, to a great extent, on the articulating paper and the patient’s “feel” feedback for implant-prosthetic occlusion establishment. In this study, we attempted to verify whether the sole use of the articulating paper to evaluate and equilibrate the occlusal contacts of the prosthetic restorations is successful enough to fulfill the objectives of a balancing implant-prosthetic occlusion in the habitual occlusal position. For this purpose, the T-Scan III system has been introduced as an objective method of evaluation and analysis of the implant-prosthetic occlusion because it provides a dynamic and comprehensive visual picture of the patient’s occlusion route. This study runs in the same tract with other studies that have been previously conducted to examine and assess the accuracy of the articulating paper in occlusion adjustment, particularly in the cases of implant restorations<sup>20-22</sup>. The occlusion of a single implant restoration should be designed to minimize the occlusal forces onto the implant, and to ensure even force distribution to the adjacent natural teeth<sup>23-24</sup>. In other words, a single tooth implant restoration

should receive light occlusal contacts on heavy bite (MIP), and lighter or no contact on light bite<sup>25</sup>. In addition, working and non-working contacts should be avoided on a single implant restoration<sup>24</sup>. Besides, even distribution of the occlusal forces throughout the dental arch is also recommended for good dental treatment outcome. This study reported that 45% of the treated patients have COF out of the center. However, this result was not observed in all the studied cases because of interferences from the implants. Some cases, however, were reported with COF shifted to the contralateral side of the implant due to interference from a natural tooth on that side. This truly emphasizes the importance of balancing and equilibrating the occlusion of the existing natural teeth before the adjustment of the implant occlusion<sup>26</sup>. It is important to point out that the use of T-Scan III system permits the application of the time-delayed loading concept on dental implants which is based on the varying nature between the rigidly osseointegrated implant relative to the resilient quality of natural tooth because of the presence of PDL. Therefore, by loading the natural teeth first with  $OT < 0.2s$  followed by loading the implant restoration with  $OT < 0.4s$  (delay after the adjacent natural teeth)<sup>6,27</sup>. Finally followed by fully loading both the teeth and the implant restoration<sup>6</sup> without overloading or premature contacts on excursive movements and with a concurrent acceptable center of force trajectory as possible based on the patient's physiology<sup>28</sup>.

This study reported that 25% of the cases fulfilled an acceptable OT ( $< 0.6$ ); whereas 62.5% had prolonged OT and had the IF% either equal to or more than that of the adjacent natural teeth, which is considered as an occlusal overloading. This could be explained by the fact that the interpretation of the articulating paper marks depends on subjective interpretation as well as on the patient's feel which is decreased by 8 times than that for natural teeth due to the absence of PDL<sup>5</sup>, and that occlusal interferences on the collateral side the implant

may lead to improper control of the mandibular movement. Longevity of implant restorations is not only affected by the absence of occlusal overload but also by the presence of implant controlled functional occlusion as well. Some scholars have reported that omitted occlusal contact of the implant-supported prosthesis is one of the factors related to marginal bone loss<sup>29</sup>. In this study, 12.5 % of implants had been reported to be out of occlusion which resulted in implant- prosthesis without any effective occlusal contacts.

One of the most important guidelines for successful implant occlusion is to eliminate premature contacts during excursive movements<sup>24</sup>. The current study reported two implants (5%) with interference on the working side, one implant (2.5%) with interference on the non-working side, and with an interference from a posterior natural tooth on the non working side in only one case (Fig 3). This supports our assumption of the importance of evaluation and balancing the occlusion of the natural teeth in centric and eccentric positions, before the implant-occlusion adjustment<sup>30</sup>. Indeed, these findings have significant clinical implications because if an operator assumes that there is an overload on the implant side caused by involuntary movement in order to avoid a premature contact, the operator cannot subjectively diagnose the occlusal problem. This means that, the sole use of the articulating paper as an occlusal indicator is not accurate enough method for making occlusal loading, sequencing, and timing. This claim is in agreement with some scholars<sup>5,9,11,22</sup>. However, this conclusion is in disagreement with others<sup>20,31</sup> who claim that, if the articulating paper is correctly and conscientiously used, it will be good enough for implant occlusion adjustment. Moreover, the T-Scan III system enables the clinician to measure the occlusal forces before the implant insertion so that the clinician can correct the aberrant occlusal forces and use these results to load implants subsequently to ensure a balanced occlusal force.



## CONCLUSION

Within the limitation of this study, the following findings could be concluded:

1. The use of the articulating paper is not an accurate enough method to employ in the implant occlusion adjustment,
2. The use of the T-Scan occlusal analyzer as a quantifying, non-subjective occlusal indicator may produce more comprehensive and evidence-based results.
3. The analysis of occlusion and establishment of balanced occlusal forces are essential measures before the adjustment of the implant-prosthetic restorations.
4. Implant occlusion should be re-evaluated and adjusted, if needed, on a regular basis to guard against the development of potential overloading.

## ACKNOWLEDGEMENT

This project was financially supported by the research center of the College of Applied Medical Sciences at King Saud University via providing the researchers with the T-Scan III occlusal analyzer device.

## REFERENCES

1. Jung RE, Zembic A, Pjetursson BE, Zwahlen M, Thomas DS. Systematic review of the survival rate and the incidence of biological, technical, and aesthetic complications of single crowns on implants reported in longitudinal studies with a mean follow-up of 5 years. *Clin Oral Implants Res.* 2012; 23: 2-21.
2. Levin L, Sadet P, Grossmann Y. A retrospective evaluation of 1, 387 single-tooth implants: A 6-year follow-up. *J Periodontol.* 2006; 77:2080-3.
3. Simon RL. Single implant-supported molar and premolar crowns: A ten-year retrospective clinical report. *J Prosthet Dent.* 2003; 90: 517-21.
4. G ionhaku N, Yamaguti K, Yamamoto K, et al. Reappearance of occlusal adjustment supply: Part 1. basic studies. *J Jpn Prosthodont Soc.* 1989; 25:592-9.
5. Millstein PL. An evaluation of occlusal indicator wax. *J Prosthet Dent.* 1985; 53: 570-2.
6. Kerstein RB. Nonsimultaneous tooth contact in combined implant and natural tooth occlusal schemes. *Pract Proceed Aesthet Dent.* 2001; 13: 751-5.
7. Zarb GA, Schmitt A. The longitudinal clinical effectiveness of osseointegrated dental implants: the Toronto Study. Part II: The prosthetic results. *J Prosthet Dent.* 1990; 64:53-61.
8. Sekine H, Komiyama Y, Potta H, Yoshida K. Mobility characteristics and tactile sensitivity of osseointegrated fixture-supporting systems. In: van Steenberghe D, Albrektsson T, Branemark PI, Henry PJ, Holt R, Liden G, editors. *Tissue integration in oral and maxillofacial reconstruction.* Amsterdam: Excerpta Medica. 1986; p.326-32.
9. Schelb E, Kaiser DA, Brukl CE. Thickness and marking characteristics of occlusal registration strips. *J Prosthet Dent.* 1985; 54:122-6.
10. De Boever JA, McCall WD, Jr, Holden S, Ash MM, Jr. Functional occlusal forces: an investigation by telemetry. *J Prosthet Dent.* 1978; 40: 326-33.
11. Breeding LC, Dixon DL, Kinderknecht KE. Accuracy of three interocclusal recording materials used to mount a working cast. *J Prosthet Dent.* 1994; 71: 265-70.
12. Halperin GC, Halperin AR, Norling BK. Thickness, strength, and plastic deformation of occlusal registration strips. *J Prosthet Dent.* 1982; 48: 575-8.
13. Takai A, Nakano M, Bando E, Hewlett ER. Evaluation of three occlusal examination methods used to record tooth contacts in lateral excursive movements. *J Prosthet Dent.* 1993; 70: 500-5.
14. Kerstein RB, Radke J. The effect of disclusion time reduction on maximal clench muscle activity levels. *Cranio.* 2006; 24:156-65.
15. Humphrey S. Implant maintenance. *Dent Clin North Am.* 2006; 50: 463-78, viii.
16. Cohen-Levy J, Cohen N. Computerized analysis of occlusal contacts after lingual orthodontic treatment in adults. *Int Orthod.* 2011; 9: 410-31.
17. Kerstein RB, Grundset K. Obtaining bilateral simultaneous occlusal contacts with computer analyzed and guided occlusal adjustments. *Quintessence Int.* 2001; 32: 7-18.
18. Kerstein RB. Combining technologies: a computerized occlusal analysis system synchronized with a computerized electromyography system. *Cranio.* 2004; 22: 96-109.

19. Martins MJS, Caramelo FJ, Ramalho da Fonseca JA, Nicolau PMG. In vitro study on the sensibility and reproducibility of the new T-Scan III HD system. *Rev Port Estomatol Med Dent Cir Maxilofac.* 2014; 55:14-22.
20. Cotruță AM, Mihăescu C S, Tanasescu LA, Margarit R , Andrei OC. Analyzing the morphology and intensity of occlusal contacts in implant-prosthetic restorations using T-Scan system. *Rom J Morphol Embryol* 2015. 56: 277–81.
21. Millstein PL, Maya A. An evaluation of occlusal contact marking indicators. A descriptive quantitative method. *J Am Dent Assoc.* 2001; 132: 1280–6; quiz
22. Qadeer S, Kerstein R, Kim RJ, Huh JB, Shin SW. Relationship between articulation paper mark size and percentage of force measured with computerized occlusal analysis. *J Adv Prosthodont.* 2012, 4: 7–12.
23. Misch, C.E. Occlusal considerations for implant supported prostheses. In: Misch, C.E., eds. *Contemporary implant dentistry.* 1st ed., St. Louis: Mosby. 1993; pp 705–33.
24. Engelman MJ. Occlusion in : clinical decision making and treatment planning in osseointegration. 1st ed., Chicago: Quintessence Publishing Co. 1996; pp 169-76.
25. Lundgren, D., Laurell L. Biomechanical aspects of fixed bridgework supported by natural teeth and endosseous implants. *Periodontology* 2000. 1994; 4: 23–40.
26. Misch CE, Bidez MW, Judy KWM, Kircos LT, Meffert R, Misch CM, et al. *Dental implant prosthodontics*, 2st ed., chapter 25, Mosby, Inc.2005, pp 472-9.
27. Chapman R. Principles of occlusion for implant prostheses: guidelines for position, timing, and force of occlusal contacts. *Quintessence Int.*1987; 20:473-80.
28. Patel SI. Stevens C., Keith S, Patel S. Implant occlusion in the digital age of dentistry, A Tekscan, Inc. Publication. 2016. <http://www.linea.bg/wp-content/themes/Linea-child/resources/Implant%20eBook>.
29. Misch CE, Suzuki JB, Misch-Dietsh FM, Bidez MW. A positive correlation between occlusal trauma and peri-implant bone loss: literature support. *Implant Dent.* 2005;14: 108-16.
30. Misch CE. Occlusal considerations for implant-supported prosthesis. In Misch CE, editor: *Contemporary implant dentistry*, ST Louis, Moasby. 1993.
31. Carey JP, Craig M, Kerstein RB, Radke J. Determining a relationship between applied occlusal load and articulating paper mark area. *Open Dent J.* 2007; 1:1–7.