

Isolation and Molecular Identification of Duck Hepatitis A Virus in Sharkia Governorate

Mohamed N. Hassaan^{1*}, Abeer M. Shahin² and Amal A.M. Eid²

¹Veterinary Hospital, Faculty of Veterinary Medicine, Zagazig University, 44511, Egypt

²Avian and Rabbit Medicine Department, Faculty of Veterinary Medicine, Zagazig University, 44511, Egypt

Article History: Received: 8/2/2018 Received in revised form: 23/2/2018 Accepted: 28/2/2018

Abstract

Thirty two flocks were examined to investigate the incrimination of DHAV in the nervous signs and massive mortalities recorded among ducklings during 2014-2016 in Sharkia Governorate. The examined birds aged (2-11 days) were suffering from nervous signs; ataxia followed by opisthotonos, kicking spasmodically then rapid death. Enlarged liver with marked petechial haemorrhages, enlarged spleen, nephritis and swelling of the kidneys were seen. Viral isolation in ECE revealed stunting, subcutaneous hemorrhages covering the body, necrotic areas and greenish discoloration of embryonic liver in 22 samples (68.75%). DHAV identification was succeeded by RT-PCR using RNA extracted from the livers of collected samples and specific primers based on 3D gene in all above positive samples. It could be concluded that RT-PCR could be carried out on hepatic tissues for rapid diagnosis of common DHAV. The subtyping of DHAV is useful for accurate diagnosis to avoid vaccination failure.

Keywords: DHAV, Molecular identification.

Introduction

An acute contagious, rapidly spreading and highly lethal viral infection of young ducklings was recorded by Woolcock [1]. The disease causes highly economic losses in ducklings due to high mortalities. There are three heterologous duck hepatitis virus (DHV) types; I, II and III [1]. The DHV type I has spread worldwide with mortalities more than 80% in ducklings less than 3 weeks of age [2]. Currently, DHV type I is renamed duck hepatitis A virus (DHAV) and subdivided into three genotypes DHAV-1, DHAV-2 and DHAV-3 [3]. There is a limited cross-neutralization between DHAV-1 and DHAV-3 [4]. However, no cross-neutralization was found between DHAV-1 and DHAV-2 [5]. On the other hand, the DHV type II and DHV type III are members of the astroviridae and renamed as duck astrovirus type I (DAstV-I) and duck astrovirus type II (DAstV-II) respectively [6]. The DHAV was firstly isolated in white pekin ducklings on Long Island on New York during the spring of 1949 [7]. In Egypt, Refaie [8] identified DHAV from Pekin, Balady and Rowan sick ducklings for the first time. Recently, Sultan and Talaat [9]; Erfan *et al.*, [10]; Bayoumie and Abd EL-Samie, [11] and EL-Samadony *et al.*, [12] studied molecular characterization and epidemiology of DHAV from different duck

breeds in Egypt. The DHAV is a non-enveloped single stranded RNA genome of approximately 7.8 kb [13]. It is icosahedral particle, resistant to ether and chloroform and capable of survival for long periods under natural environmental circumstances [1].

Transmission of duck virus hepatitis (DVH) infection can arise from aerosols or oral route [14]. Recovered ducks may excrete virus in dropping up to 8 weeks PI [15]. Wild birds were incriminated as mechanical carrier of virus over short distances and healthy carriers were responsible for new outbreaks at great distances [16].

Morbidity can reach 100%, with 95% mortality in ducklings less than one week and may reach 50% or less in ducklings between 1-3 weeks of age [17].

The disease is characterized by imbalance, lethargy and ataxia in ducklings which are falling on their sides and kicking spasmodically followed by opisthotonos within 1-2 hours prior to death. Marked petechial and or ecchymotic haemorrhages are the mostly seen lesions in enlarged liver of affected ducklings. Enlarged spleen and kidneys with some congestion of renal blood vessels may also occur in DHAV infection [6].

Histopathologically, hepatocytic necrosis and bile duct hyperplasia with haemorrhage and inflammatory cells aggregations are seen in livers [6]. Virus isolation in embryonated chicken egg (ECE) is commonly used through inoculation of the liver homogenate into the allantoic sac of ECE (8-10 days) [17]. Pathological lesions in the embryos include stunting and edema of the abdominal and hind limbs, with subcutaneous haemorrhages over the whole body. Livers may be red and yellowish, swollen and may have some necrotic foci. Greenish allantois is more obvious in survived embryos [6].

Up to 2005, DHAV was detected only associated with causing disease in Mallard and Pekin ducklings but in the last decade, it is reported to cause pancreatitis and encephalitis in Muscovy ducks [18]. The diagnosis of DHAV is usually based on epidemiological information, clinical signs, pathological changes and viral isolation [19, 20] and the methods for detection of antibody against DHAV in duck sera include neutralization tests [21, 22] indirect hemagglutination tests [23] gel diffusion assays [24] and ELISA [25]. These assays are time-consuming and don't provide the needed sensitivity to detect low-level of virus [26]

Reverse transcriptase polymerase chain reactions (RT-PCR) have been established and are beneficial for identifying DHAV infection [27] beside sequencing of VP1 genes to detect mutations [28].

The current work aimed to confirm DHAV responsibility on losses of ducklings at Sharkia Governorate. This goal was investigated via virus isolation in ECE and detection by RT-PCR.

Material and Methods

Sampling

Liver and spleen tissue pools (3/each) were collected from 32 duckling flocks from different localities at Sharkia Governorate. The examined birds aged (2-11 days) from February 2014 to April 2015. These flocks are progeny of vaccinated duck breeders against DHAV and had a history of high mortality rate and nervous signs.

Sample preparation and virus isolation

Tissue suspension of collected samples was prepared [4]. An inoculum of 0.2 ml prepared with 10% (w/v) PBS with antibiotics (penicillin 10000 IU/ml and streptomycin 10 mg/ml) was used for virus isolation in ECE. The embryos were examined for any pathological lesions [6].

Histopathological Examination

Liver specimens of affected ducklings were fixed in 10% buffered neutral formalin solution, processed in paraffin sections (5 microns thickness) and stained with haematoxylin and eosin (H&E), then examined microscopically [29].

RNA Extraction

Viral RNA was extracted from 50 µl of supernatant of affected liver and spleen tissue pools by Gene JET RNA Purification Kit according to the manufacturer's instruction (ferments#K0731). The cDNA used immediately for PCR or stored at -20°C.

PCR reaction

The PCR was performed in a total of 25 µl in a sterile 0.2 ml RNase free PCR tubes. For one reaction, the assay was optimized to 12.5µl of DreamTaq Green PCR master mix (2X), 0.25µl of appropriate forward and reverse primers (100 pmole/µl), 2µl of cDNA and 10ul of RNase-free water.

A specific pair of primers were used the forward ComF (5'-AAG AAG-GAG-AAA-ATY-[C or T]-AAG-GAA-GG-3') and the reverse one ComR(5'-TTG-ATG-TCA-TAG-CCC-AAS-[C or G]-ACA-GC-3') based on 3D gene.

The optimized PCR cyclic reaction conditions were performed in MWG-Biotech Thermal cycler and described as following, initial denaturation at 95°C for 3 min, followed by 37 cycles of denaturation at 95°C for 30 sec, annealing at 50°C for 30 sec and extension at 72°C for 60 sec. A final extension step at 72°C for 10 minutes was also performed [4].

Agarose gel electrophoresis of RT-PCR product

The 1.5% agarose gel was prepared in 1X TAE buffer and 50 µl of ethidium bromide was added to melted agarose to give total concentration of 0.5 µg/ml. Electrophoresis was done at 100 volts for 40 min, then the bands were viewed by UV trans-illuminator [4].

Results

Clinical findings

The examined ducklings under current study were suffering from nervous signs including ataxia followed by opisthotonos (loss of balance falling on their sides and kick spasmodically) then death (Figure 1 A). The postmortem findings appeared mainly in the liver, which was enlarged and displayed distinct petechial and/or ecchymotic hemorrhages (Figure 1 B).

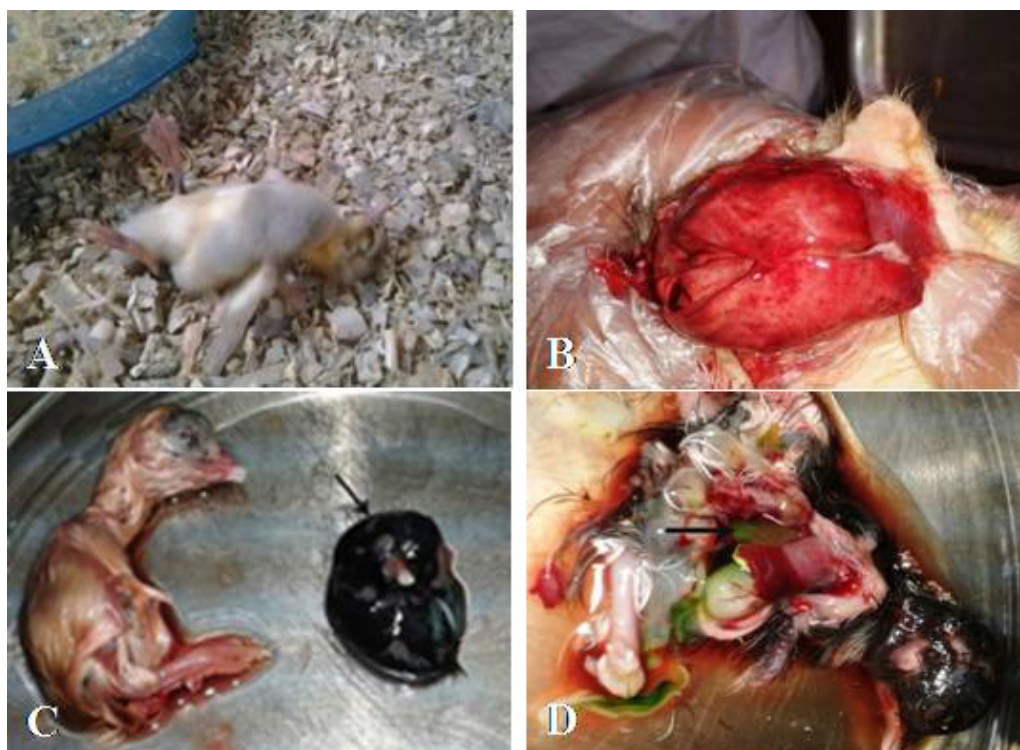

Figure 1: (1 A-D): A: Pekin ducklings, 6 days-old, flock number 9 showing opisthotonos. B: Liver of pekín ducklings, 11 days-old, flock number 8, showing petechial haemorrhage. C: Dead embryo of flock number 12 showing stunting 7 days PI compared with the control (arrow head). D: Liver of dead embryo showing greenish discoloration (arrow) in flock number 12

Virus isolation

The inoculated ECE showed pathological changes as stunting embryos with subcutaneous hemorrhages covering the body and edema in the hind limbs and abdominal region in 22 out of 32 examined samples (Figure 1 C). The embryonic liver was enlarged, greenish in color, also showed some necrotic foci (Figure 1 D). The allantoic fluid

color changed to green in case of embryos that take longer to die.

Histopathological Findings

The liver of affected ducklings showed marked inflammation in the portal tract and in among hepatocytes (Figure 2A). Dilated central veins which engorged with blood and hydropic degeneration associated with extravasated erythrocytes were observed (Figure 2B). The portal tracts were surrounded

with aggregation of inflammatory cells and mild fatty changes of hepatocytes (Figure 2C).

Portal area showed congested blood vessels and lymphatic infiltration (Figure 2D).

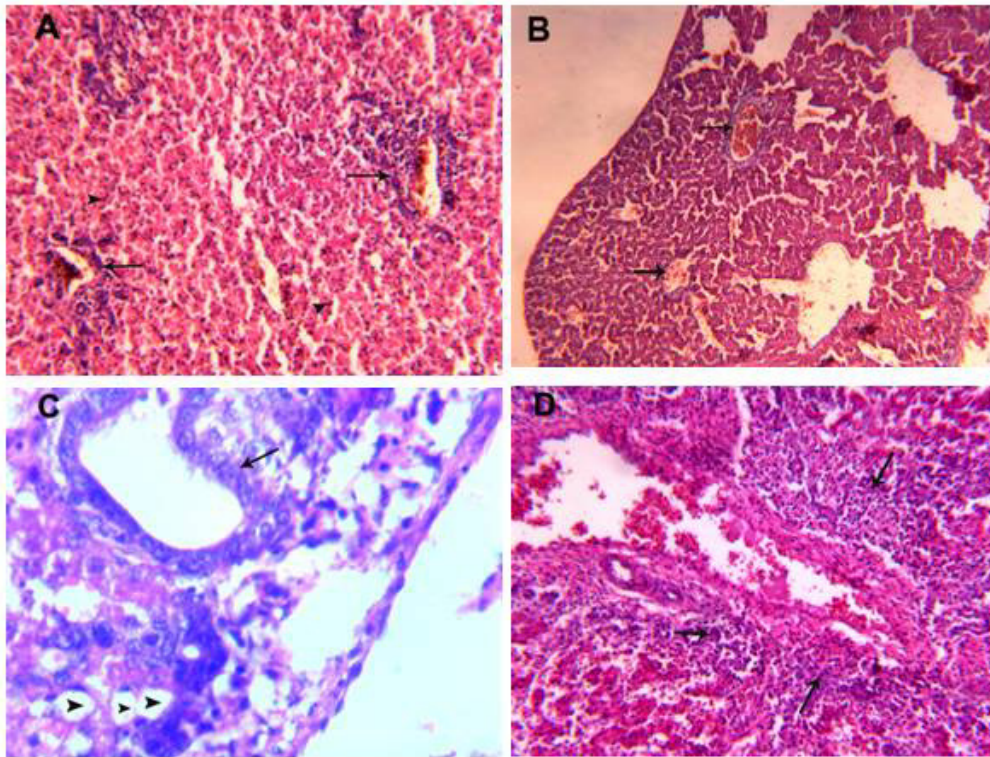


Figure 2: Liver of Mallard duckling, 8 days old showing marked inflammation in the portal tracts (arrows) H&E x 200 (A). Liver of Mallard duckling, 8 days old showing dilated central veins engorged with blood (arrows) H&E x 100 (B). Liver of Pekin duckling, 11 days old showing periportal vacuolation of hepatocytes (arrow) H&E x 300 (C). Liver of Pekin duckling, 6 days old showing portal area with congested hepatic artery and lymphatic infiltration (arrows) H&E x 200 (D).

RT-PCR analysis

Using RT-PCR techniques with specific primers, The DHAV was detected in 22 out of 32 tissue samples with a percentage of 68.75%. A DNA fragment of 467 bp was amplified 3D gene for general detection of common DHAV (Figure 3).

Discussion

Sudden onset with rapid deaths among ducklings were recorded in different farms at Sharkia Governorate. In a trial to isolate and molecularly identify the causative agent, thirty two farms were subjected to the possibility of DHAV incrimination. The examined flocks revealed an acute lethal disease in ducklings

(2-11 days) of age. Our results are comparable with these of Woolcock [1] who observed similar disease among ducklings and explained that age resistance occurs at ≥ 7 weeks of age. In the current investigation, the commonly recorded clinical signs among examined ducklings were lethargy, ataxia followed by opisthotonos then death. Rapid deaths frequently occurred within 1-2 hours after the onset of signs. Peaked mortalities in examined flocks occurred at 2nd and 3rd day after showing signs, and its course take 6-7 days as high as (up to 70%). The obtained results were parallel to that previously recorded in DHV infection [6, 10].

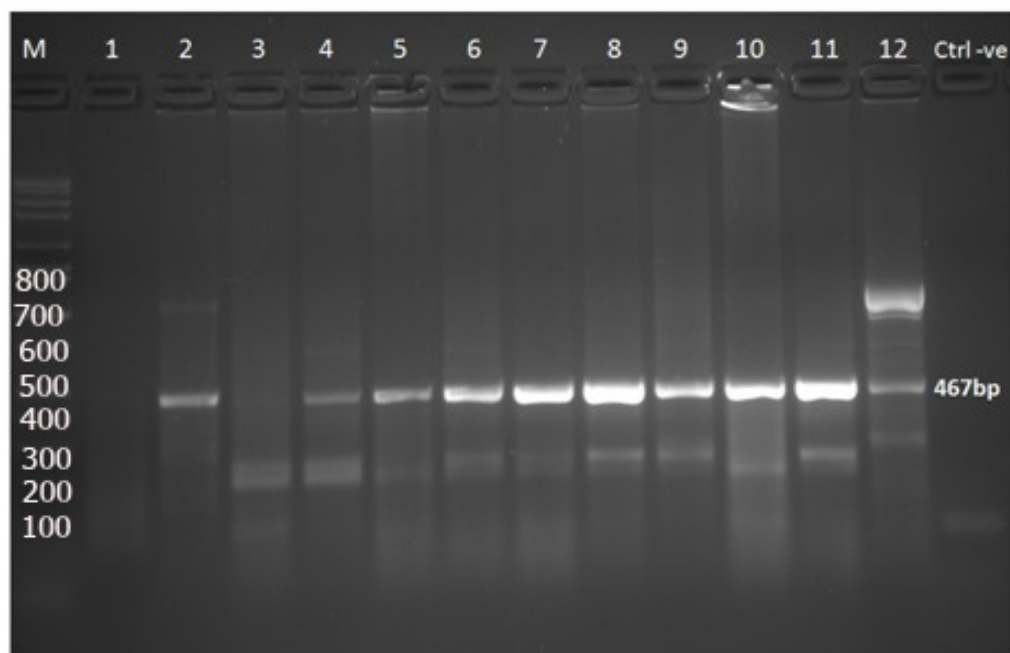


Figure 3: Molecular identification of DHAV using RT-PCR: Agarose gel electrophoresis of the RT-PCR products of DHAV. Lane M: DNA Ladder (marker) 100 bp. Lanes: 2, 4, 5, 6, 7, 8, 9, 10, 11 and 12 were positive at 467bp. Lanes: 1, 3 were negative. Lane (Ctrl -ve): negative control

Liver of examined ducklings were enlarged with distinct petechial and ecchymotic haemorrhages. Enlarged spleen was evidenced in 15 flocks. Ducklings also revealed enlargement of the kidneys with congestion of renal blood vessels in all flocks. Similarly, variable lesions were recorded among liver and kidneys [6, 30].

Histopathological examination of affected livers showed inflamed portal tract with marked dilatation and congestion of central veins and dilated sinusoids with hemolysed RBCs, massive hepatocyte necrosis, hydropic degeneration with variable fatty changes. These results were analogous to those reported by El-Samadony *et al.*, who stated that hepatocellular necrosis in addition to vacuolar degeneration are present associated with dilated sinusoids with hemolysed RBCs in histopathological picture of affected livers [12].

Diagnosis of DHAV infection is based on virus isolation following the inoculation of tissue suspension from suspected ducklings into the allantoic cavity of 9-11 day-old ECE [31]. Our results included stunting and

subcutaneous edema particularly of the head, abdominal and hind limbs with hemorrhages over the whole body. Enlarged embryonic liver with congestion necrotic patches were observed in inoculated ECE. The previously mentioned embryo lesions were reported as DHV pathological effect by many authors in previous studies [10] and [11].

Cheng et al [27] stated that reverse transcriptase polymerase chain reactions (RT-PCR) have been developed for identifying DHAV infection. The partially magnified region of the 3D gene (467bp) of DHAV of our samples using RT-PCR was detected in 22 samples (68.75%). Similarly, the presence of mentioned band indicates positive DHAV presence [9, 10,12]. The RT-PCR confirmed the ECE inoculation results and consequently the RT-PCR could be a rapid and specific detection of the DHAV RNA as described by Liu et al [32] and Wei et al [33]. Although all investigated birds were aroused from vaccinated breeders against DHAV, the positive virus infection was watched in our study in 68.75% of examined progeny and in consequence tremendous economic losses up to 70% were recorded. The failure in

protection by maternal derived immunity (MDI) may be attributed to low MDI or misapplication as well as the possibility of vaccination of challenge virus among vaccinal strains [10].

It could be concluded that RT-PCR could be carried out on hepatic tissues for rapid diagnosis of common DHAV. The subtyping of DHAV is useful for accurate diagnosis to avoid vaccine failure.

References

- [1] Woolcock, P.R. (2003): Duck hepatitis. In: Saif, Y.M., Barnes, H.J., Glisson, J.R., Fadly, A.M., McDougald, L.R., Swayne, D.E. (Eds.), *Diseases of Poultry*, Eleventh ed. Iowa State University Press, Ames, IA, 343-354.
- [2] Todd, D.; Smyth, V.J.; Ball, N.; Donnelly, B.M.; Wylie, M.; Knowles, N.J. and Adair, B. (2009): Identification of chicken enterovirus-like viruses, duck hepatitis virus type 2 and duck hepatitis virus type 3 as astroviruses. *Avian Pathol*, 38(1): 21–29.
- [3] Wang, L.; Pan, M.; Fu, Y. and Zhang, D. (2008): Classification of duck hepatitis virus into three genotypes based on molecular evolutionary analysis. *Virus Genes*, 37(1): 52-59.
- [4] Kim, M.C.; Kwon, Y.K.; Joh, S.J.; Kwon, J.H.; Kim, J.H. and Kim, S.J. (2007): Development of one-step reverse transcriptase-polymerase chain reaction to detect duck hepatitis virus type 1. *Avian Dis*, 51(2): 540–545.
- [5] Tseng, C.H. and Tsai, H.J. (2007): Molecular characterization of a new serotype of duck hepatitis virus. *Virus Res*, 126(1-2): 19-31.
- [6] OIE, (2010): Duck Virus Hepatitis. OIE Terrestrial Manual 2010. (Chapter 2.3.8), available online at: http://www.oie.int/fileadmin/Home/eng/Health_standards/tahm/2.03.08_DVH.pdf
- [7] Levine, P.P. and Fabricant, J. (1950): A hitherto-undescribed virus disease of ducks in North America. *Cornell Vet*, 40:71-81.
- [8] Refaie, E.R.M. (1969): studies on some diseases of ducklings with special reference to salmonellosis and duck viral hepatitis. *Vet Med J*, 16: 3-12.
- [9] Sultan, H.A. and Talaat, S.M (2014): Isolation and Molecular Characterization of Duck Viral Hepatitis Disease Virus in Egypt. Submitted (24-NOV-2014) *Birds and Rabbit Dis. Dept. Faculty of Veterinary Medicine, University Sadat City, Area No. 1 Sadat, Menoufiya 32511, Egypt*.
- [10] Erfan, A.M.; Selim, A.A.; Moursi, M.K.; Nasef, S.A. and Abdelwhab, E.M. (2015): Epidemiology and molecular characterisation of duck hepatitis A virus from different duck breeds in Egypt. *J Vet Microbiol*, 177(3-4): 347-352.
- [11] Bayoumie, H.A.A. and Abd EL-Samie, L.K. (2015): Molecular characterization of a duck virus hepatitis isolate isolated from Sharkia governorate. *Assiut Vet Med J*, 61 (147): 56-65.
- [12] EL-Samadony, H.A.; Tantawy, L.A. and Mekky H.M. (2016): Isolation and molecular detection of duck viral hepatitis. *Global Veterinaria*, 16(4): 314-322.
- [13] Tseng, C.H.; Knowles, N.J. and Tsai, H.J. (2007): Molecular analysis of duck hepatitis virus type 1 indicates that it should be assigned to a new genus. *Virus Res*, 123: 1902-1903.
- [14] Priz, N.N. (1959): Comparative study of virus hepatitis in animals (dogs and ducks) using different routes of influence. *Vopr Virusol.*, 696-700.
- [15] Reuss, U. (1959): Virusbiologische Untersuchungen bei der Entenhepatitis. *Transboundary and Emerging Diseases*, 6(3):209-248.
- [16] Asplin, F.D. (1965): Duck hepatitis. Vaccination against two serological types. *Vet Rec*, 77:1529-1530.
- [17] Woolcock, P.R. (2008): Duck hepatitis. In: *A Laboratory Manual for the Isolation, Identification and Characterization of Avian Pathogens*, 5th Edition, Dufour-Zavala L., Swayne D.E., Glisson J.R., Pearson J.E., Reed W.M., Jackwood M.W. and Woolcock P.R.,

- eds. American Association of Avian Pathologists, Jacksonville, Florida, USA, 175-178.
- [18] Guerin, J.L.; Albaric, O.; Noutary, V. and Boissieu, C. (2007): A duck hepatitis virus type I is agent of pancreatitis and encephalitis in Muscovy duckling. In: Proceedings of the 147th American Veterinary Medicine Association/50th American Association of Avian Pathologists Conference, 14-18 July, Washington, DC, USA, Abs. 4585.
- [19] Vertinskii, K.I.; Bessarabov, B.F.; Kurilenko, A.N.; Strel'nikov, A.P. and Makhno, P.M. (1968): The pathogenesis and diagnosis of viral hepatitis of ducklings. *Veterinariia*, 45: 27-30.
- [20] Maiboroda, A.D. (1972): Formation of duck hepatitis virus in culture cells. *Veterinariya*, 8: 50-52.
- [21] Hwang, J. (1969): Duck hepatitis virus-neutralization test in chicken embryos. *Am J Vet Res*, 30: 861-864
- [22] Woolcock, P.R.; Chalmers W.S.K. and Davis, D. (1982): A plaque assay for duck hepatitis virus. *Avian Path*, 11(4): 607-610.
- [23] Taylor, P.L. and Hanson, L.E. (1967): Indirect hemagglutination with duck hepatitis virus. *Avian Dis*, 11: 586-593.
- [24] Gabridge, M.G. and Newman, J.P. (1971): Gel diffusion method for determining the titer of duck hepatitis virus. *Appl Microbiol*, 21: 147-148.
- [25] Zhao, X.; Phillips, R.M. and Zhong, A. (1991): Studies on the detection of antibody to duck hepatitis virus by enzyme-linked immunosorbent assay. *Avian Dis*, 35(4):778-782.
- [26] Ling, K.S.; Wechter, W.P. and Jordan, R. (2007): Development of a one-step immunocapture real-timeTaqMan RT-PCR assay for the broad spectrum detection of Pepino mosaic virus. *J Virol Methods*, 144: 65-72.
- [27] Cheng, A.; Wang, M.; Xin, H.; Zhu, D.; Li, X.; Chen, H.; Jia, R. and Yang, M. (2009): Development and application of a reverse transcriptase polymerase chain reaction to detect Chinese isolates of duck hepatitis virus type 1. *J Microbiol Methods*, 77: 1-5.
- [28] Jin, X.; Zhang, W.; Gu, C.; Cheng, G. and Hu, X. (2008): Identification and molecular analysis of the highly pathogenic duck hepatitis virus type 1 in Hubei province of China. *Res Vet Sci*, 85: 595-598.
- [29] Suvarna, K.S.; Layton, C. and Bancroft, J.D., (2012): Bancroft's Theory and Practice of Histological Techniques E-Book. Elsevier Health Sciences.
- [30] Gough, R.E. and McNulty, M.S. (2008): Viral diseases In: *Poult. Dis*. PP. 350-357. Edited by Pattison, McMulin, Broadbury and Alexander. Saunders El Sevier.
- [31] Woolcock, P.R. (2010): DVH. In: *Manual of Diagnostic Tests and Vaccines for Terrestrial Animals*. Office International des Epizooties, Paris, France.
- [32] Liu, G.; Wang, F.; Ni, Z.; Yun, T.; Yu, B.; Huang, J. and Chen, J. (2008): Genetic diversity of the VP1 gene of duck hepatitis virus type I (DHV-I) isolates from southeast China is related to isolate attenuation. *Virus Res*, 137: 137-141.
- [33] Wei, C.Y.; Zhu, W.J.; Chen, J.D.; Zhao, F.R.; Wang, Y.J.; Xie, J.X.; Wang, H. and Zhang, G. (2012): Complete genome sequence of a novel DHAV discovered in southern China. *J Virol*, 86: 10247.

الملخص العربي

عزل والتعرف الجزيئي لفيروس التهاب الكبدى (A) بالبط فى محافظة الشرقية
محمد نزيه حسان^١، عبيد محمد شاهين^٢ و أمال انيس مهدى عيد^٢
^١المستشفى البيطرى التعليمى -كلية الطب البيطرى-جامعة الزقازيق
^٢قسم طب الطيور والأرانب-كلية الطب البيطرى-جامعة الزقازيق

تم اختبار ثلاثين قطيع لاستبيان مسئولية فيروس التهاب الكبدى فى البط (DHAV) عن الأعراض العصبية والوفيات الهائلة المسجلة بين صغار البط خلال الفترة ٢٠١٤-٢٠١٦ فى محافظة الشرقية. وكانت الطيور التي تتراوح أعمارهم بين (٢-١١ يوما) تعاني من أعراض عصبية، وترنحات متبوعة بأعراض تشنجية ثم الموت السريع. كما شوهد تضخم فى الكبد مع نزيف ملحوظ على سطحه، تضخم الطحال، التهاب الكلية وتورم فى الكلى. وأظهرت نتائج العزل الفيروسي عن التقزم، والنزف تحت الجلد التي تغطي الجسم، والمناطق النخرية والنتلون الأخضر فى الكبد الجينية فى ٢٢ عينة (٦٨.٧٥٪). وقد تأكد وجود فيروس التهاب الكبد فى البط بواسطة اختبار تفاعل التتابع الانزيمى المتسلسل (RT-PCR) باستخدام الحمض النووي الريبي المستخرج من كبد العينات التي تم جمعها وبإدئات محددة على أساس الجين 3D في جميع العينات الإيجابية أعلاه. ويمكن استنتاج أنه يمكن استخدام اختبار تفاعل التتابع الانزيمى المتسلسل (RT-PCR) فى التشخيص السريع لمرض التهاب الكبدى من أنسجة الكبد فى الطيور المصابة ، واستخدام التصنيف الفرعى لفيروس التهاب الكبدى (DHAV) لتشخيص دقيق لتجنب فشل اللقاح.