



## **Favourable Lipid Modulatory And Renal Protective Effects Of Ginger And Fish Oil In Hypercholesterolemic Male Rats**

Farahat A.A., Salem H.A., Abass H.I, Elmosalamy S.H, Hassan N. M.  
Department of Physiology, Faculty of Veterinary Medicine, Cairo University, Egypt

### **Abstract**

Hypercholesterolemia is one of the most important risk factors for atherosclerosis and subsequent cardiovascular diseases. In the present study, the therapeutic effects of ginger and fish oil supplementation on serum lipid profile and kidney functions in high cholesterol diet-induced hypercholesterolemia in rats have been evaluated. The animals were divided into 4 groups of 12 rats each. Group I served as the control. Rats in groups II, III and IV were fed with an atherogenic diet for 8 weeks, group III received atherogenic diet supplemented with 5% ginger, group IV received atherogenic diet supplemented with 10 % fish oil. The treatment with ginger and fish oil results in significant reduction in elevated serum total cholesterol, triglycerides(TG), low density lipoproteins (LDL) and very low density lipoproteins (VLDL) and elevation in high density lipoproteins (HDL), marked modulation of atherogenic index (AI) has been noted. Also, there was significant reduction in serum urea, uric acid and creatinine levels which was markedly elevated by atherogenic diet. We concluded that dietary supplementation with ginger and/or fish oil have favorable effects on serum lipid parameters and kidney functions in hypercholesterolemic male rats.

**Key words:** hypercholesterolemia, ginger, fish oil, lipid, kidney

### **Introduction**

Hypercholesterolemia is a metabolic disorder characterized by high serum levels of cholesterol and LDL-c (**Akinyemi et al., 2015**). Hypercholesterolemia also considered as one of the major risk factors of many cardiovascular diseases (**Tzang et al., 2009**). Cardiovascular diseases remain one of the major causes of mortality. They are common not only in general population but also in individuals with chronic liver disease (**Tandra & Vuppalanchi, 2009**) and in those with diabetes or metabolic syndrome, where the imbalance of cholesterol homeostasis increases the independent risk factor for development of peripheral vascular (PVD) and coronary artery disease (CAD) (**Rozman& Monostory, 2010; Stapleton et al., 2010**).

Although hypercholesterolemia itself is asymptomatic, atherosclerosis may result from chronic increase of serum cholesterol (**Bhatnagar et al., 2008**). Long standing increase in serum cholesterol attributes to the formation of arterial atheromatous plaques (**Finn et al., 2010**). Hypercholesterolemia is well known to be an independent risk factor for renal injury and to aggravate the pathogenesis of a variety of clinical and experimental renal diseases (**Fadl Alla et al., 2014**).

In the search for naturally occurring compounds, various efforts are now concentrated on many herbal plant extracts and natural products due to their potential to induce antioxidant activity and other biological functions that have several beneficial effects on the living organisms (**Olorunnisola et al., 2012**). Fish oil contains the omega-3 fatty acids eicosapentaenoic acid (EPA) and docosahexaenoic acid (DHA), precursors of certain eicosanoids, It was shown to have favorable modulatory effect on lipid metabolism (**Hamadani et al., 2011**). In addition, it has beneficial effect on the course of glomerular injury and was proven to have significant renal protective activity (**Fernandez et al., 2004**). Ginger is considered one of the medicinal plants that have many functional properties that can affect positively many physiological functions (**kumar and Sharma, 2014**). Ginger was stated to reduce LDL concentration, increase in HDL and reduce triglyceride concentrations, Ginger can reduce the risk of heart disease due to the rich phytochemistry of ginger that includes components that scavenge free radicals produced in biological systems and led to decrease in lipid peroxidation. Also it led to reduction in renal nephropathy and has significant renal protective power (**Afshari et al., 2007**).

## Material And Methods

### Animals and Experimental design:

Forty eight mature male Sprague-Dawley rats, of an average body weight 150-200g, were obtained from the animal house, Faculty of

### Experimental design:

Groups	Rats(no.)	Treatment
Group (I)	12	Rats served as control, maintained on control diet and ad libitum water supply for 8 weeks
Group (II)	12	Rats served as hyperchoestrolemic rats, maintained on atherogenic diet and ad libitum water supply for 8 weeks.
Group (III)	12	Rats served as hyperchoestrolemic rats+ fishoil, maintained on atherogenic diet + 10% fish oil and ad libitum water supply for 8 weeks.
Group (IV)	12	Rats served as hyperchoestrolemic rats+ ginger, maintained on atherogenic diet + 5% ginger and ad libitum water supply for 8 weeks

**Sampling and techniques:** The animals were starved overnight for 12h before blood was collected Blood was collected from eye canthus in all rats under light ether anesthesia into heparinized tubes, then these tubes centrifuged for 10 minutes at 4000 r.p.m to obtain plasma. Serum samples also collected and centrifuged for 4000 r.p.m.

### Chemicals:

**Fish oil:** Spring Valley fish oil was purchased from Spring Valley, USA. It was added by 10 % to the atherogenic diet on the expense of fat ( **Sinclair and Gibson, 1992**).**Ginger:** Ginger (fine powder) 400 mg. was purchased from Arab Company for Pharmaceuticals & Medicinal Plants (MEPACO-MEDIFOOD) – Egypt. It was added by 5% to atherogenic diet on the expense of carbohydrates (**Uz et al., 2009**).**Thiouracil:** Thyrocil

Veterinary Medicine, Cairo University. They were housed in plastic cages with wood shaving bedding and a constant cycle of 12h light and 12h darkness. Rats were kept for two weeks before the experiment for adaptation.

(propylthiouracil) 50 mg. we add them to the atherogenic diet by 0.1%. It was purchased from AMOUN PHARMACEUTICAL CO. S.A.E. – Egypt (**Lin et al., 2017**).**Other chemicals:** Cholesterol, all vitamins and minerals were obtained from El-Gomhoriya Company, Cairo, Egypt. Bile salts were obtained from El Shark El Awsat Company, Cairo, Egypt. Milk powder, butter, wheat flour, sugar were purchased from the local market.

### Preparation of atherogenic diet:

Atherogenic diet was prepared according to **Maruthappan and Shree 2010**. With modification by the addition of bile salts to diet to enhance cholesterol absorbtion and thiouracil to induce atherosclerosis in rats. Composition of normal and atherogenic diet.

Composition	Normal diet (%)	Atherogenic diet (%)
Protein (milk powder)	12	10
Carbohydrates (wheat flour)	71	58.4
Sugar	05	05
Fat (butter)	05	16
Salts	04	04
Vitamins	01	02
Fibers	02	01
Cholesterol	-	01
Bilesalts		2.5
thiouracil		0.1
Total weight	100 g	100 g

**Biochemical Measurements: Cholesterol and high density lipoproteins** were estimated according to (**Finley et al., 1978**). Measurement of **triglyceride levels** was according to

**Scheletter and Nussel, 1975**. Kits were purchased from Gamma trade-cairo-egypt.

**Low density lipoproteins (LDL)-Cholestrol** was determined according to **Friedewald et**

al.(1972) equation ( $LDL-C=TC- HDL-C-TG/5$ ).

The Friedewald equation is used to calculate **Very low density lipoprotein cholesterol**.

The formula published by **Friedewald et al** in 1972 was validated by **Warnick et al** in 1990 ( $VLDL-c = Triglycerides/5$ )

**Atherogenic index** was calculated by using the formula of **Schulpis and Karikas,1998** .

**Atherogenic Index (AI) = Total Cholesterol – HDL**

**HDL**

**Urea** was determined according to **Fawcett and Scott, 1960**. **Uric acid** was determined according to **Fossati et al., 1980** method. While **Creatinine** was determined according to **Schirmeister et al., 1964** method. Kits were purchased from Biodiagnostic company–Egypt.

**Histopathological studies:** Autopsy samples were taken from heart, thoracic aorta and kidneys of rats in different groups at the end of experiment and stained by hematoxyline and eosin stain then examination was done by using light electric microscope (**Bancroft et al., 1996**).

**STATISTICAL ANALYSIS:** All data presented as mean ± standard error (SE) and

**Table (1):** Effect of Ginger and Fish oil on Cholesterol, Triglycerides, LDL, HDL, VLDL concentration and Atherogenic index(AI) in hypercholesterolemic (Hyperchol.) male rats

Groups parameters	Control	Hyperchol.	Hyperchol.+ ginger	Hyperchol.+ fish oil	LSD
Cholesterol mg/dl	a 77.8 ±3.6	b 242.5 ±8.6	c 91.5 ±4.4	d 153.9 ±4.6	11
Triglycerides mg/dl	a 62.3 ±1.6	b 130.1 ±2.8	c 75.1 ±1.0	d 98.5 ±2.1	4.3
LDL mg/dl	a 26.4 ±3.1	b 209 ±7.5	c 38 ±2.6	d 106.6 ±3.3	8.8
HDL mg/dl	a 38.9 ±1.5	b 18 ±0.9	c 34.4 ±1.1	d 24 ±0.4	2
VLDL mg/dl	a 12.5 ±0.3	b 26 ±0.3	c 15 ±0.2	d 19.7 ±0.4	0.73
AI	a 1.0 ±0.04	b 12.6 ±0.3	c 1.6 ±0.05	d 5.4 ±0.09	0.25

Means ± S.E, (N) number of rats/group=12, Means within the same row having different superscript letters are significantly different at P < 0.05

**Effect of Ginger and Fish oil on Urea, Uric acid and Creatinin concentration in hypercholesterolemic male rats**

Data illustrated in table (2) showed that the urea, uric acid and creatinin levels were elevated in hypercholesterolemic male rats if compared with treated groups and even control group. Upon

were subjected to analysis of variance (ANOVA) test according to **Snedecore and Cochran(1980)** .Treatment means were compared by least significant difference test (LSD) at 0.05 levels of probability.

**RESULTS**

**Effect of Ginger and Fish oil on Cholesterol, Triglycerides, LDL, HDL, VLDL concentration and Atherogenic index(AI) in hypercholesterolemic male rats**

Data presented in table(1) revealed that the highest cholesterol , triglycerides,LDL,VLDL levels were recorded in hypercholesterolemic male rats , while HDL concentration was significantly lower and AI was significantly elevated if compared with treated groups and even control group. Upon supplementation of atherogenic diet with ginger and fish oil lipid profile parameters showed significant modulation when compared with hypercholesterolemic group. As these groups showed significant decrease in cholesterol, triglycerides, LDL and VLDL levels. Moreover, HDL was significantly elevated and AI was significantly alleviated if compared with hypercholesterolemic rats at P < 0.05.

supplementation of atherogenic diet with ginger and fish oil, urea uric acid and creatinin showed significant amelioration when compared with hypercholesterolemic group. As these groups showed significant decrease in urea, uric acid and creatinin levels if compared with hypercholesterolemic rats at P < 0.05.

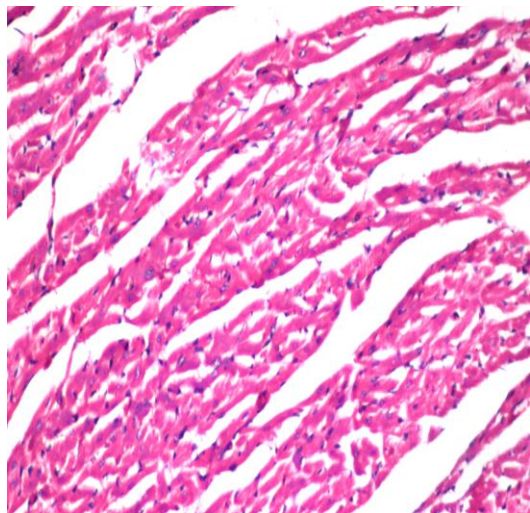


**Table (2):** Effect of Ginger and Fish oil on Urea, Uric acid and Creatinin concentration in hypercholesterolemic(Hyperchol.) male rats

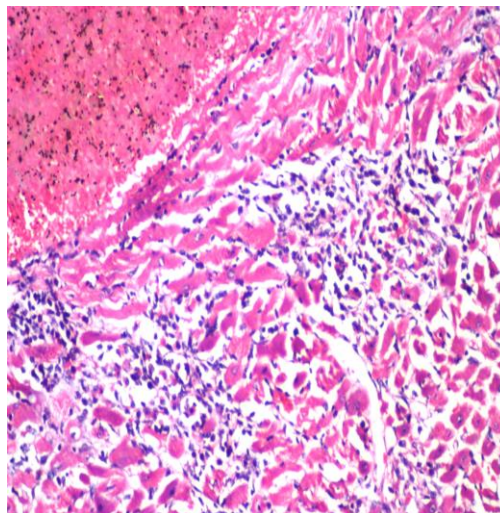
Groups parameters	Control	Hyperchol.	Hyperchol.+ ginger	Hyperchol.+ fish oil	LSD
Urea mg/dl	a 36.3 ±1.2	b 77 ±1.6	c 39.5 ±1.1	e 52.8 ±1.3	2.4
Uric acid mg/dl	a 1.9 ±0.03	b 6.0 ±0.09	c 2.3 ±0.06	e 3.2±0.07	0.11
Creatinin mg/dl	a 0.8 ±0.02	b 1.9 ±0.02	a 0.79 ±0.02	d 1.3 ±0.07	0.09

Means ± S.E, (N) number of rats/group=12, Means within the same row having different superscript letters are significantly different at P < 0.05

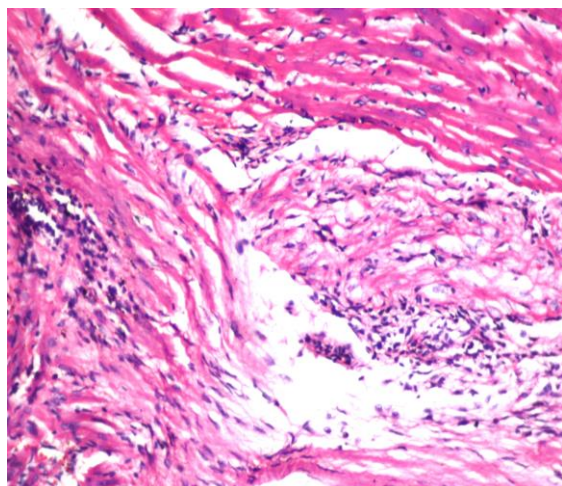
**Histopathological findings:**



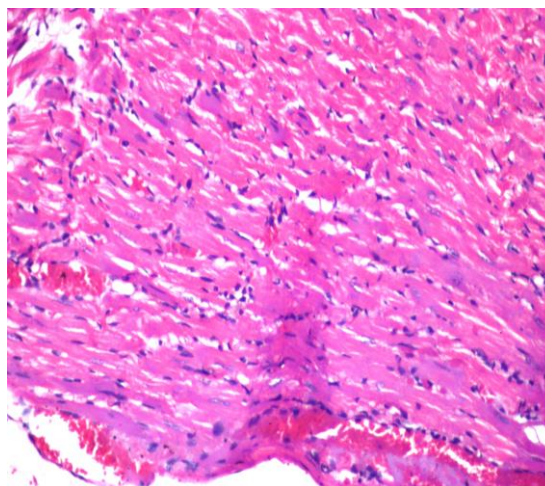
**Fig.1 (Control):** Heart showing no histopathological alteration and the normal histological structure of the myocardial bundles (H&E X 400).



**Fig.2 (Hyperchol.):** Heart showing Multiple focal areas of degeneration with inflammatory cells infiltration were detected in the myocardium (recent infarctions) associated with focal haemorrhages (H&E X 400).

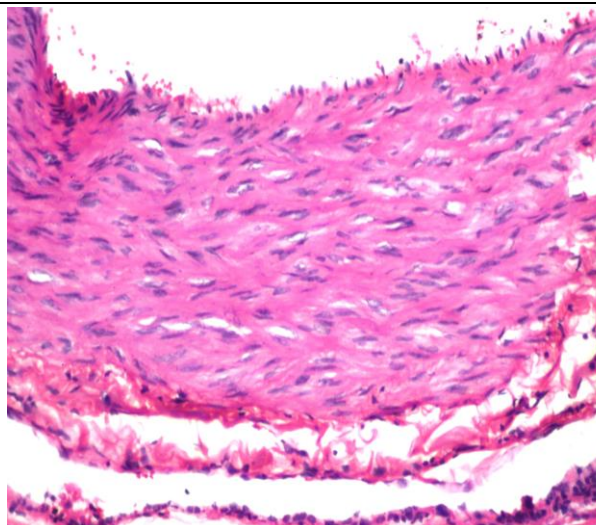


**Fig.3 (Hyperchol.+ Ginger):** The myocardium showed few focal degenerative change while others had less focal inflammatory cells infiltration (H&E X 400).

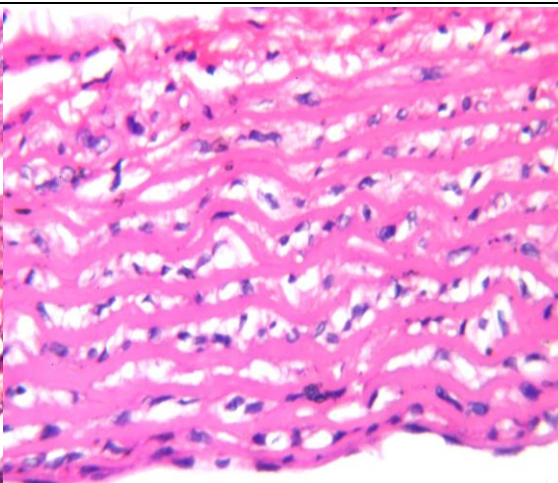


**Fig.4 (Hyperchol.+Fish oil):** The myocardium showed few degenerative change associated with congestion in the blood vessels (H&E X 400).

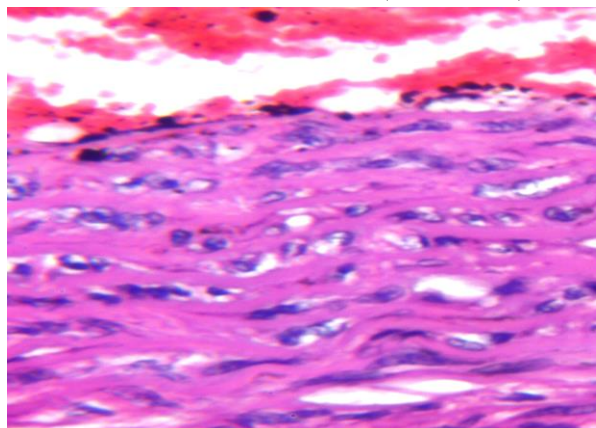




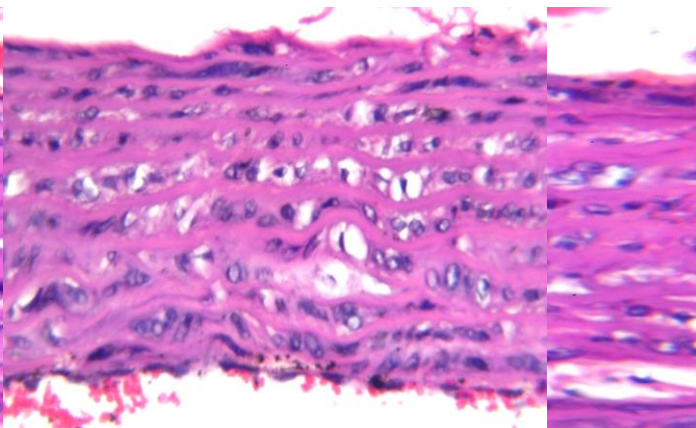
**Fig.5 (control):** Aorta showing no histopathological alteration and the normal histological structure of the tunica intima , media and adventitia of the vascular wall (H&E X 400).



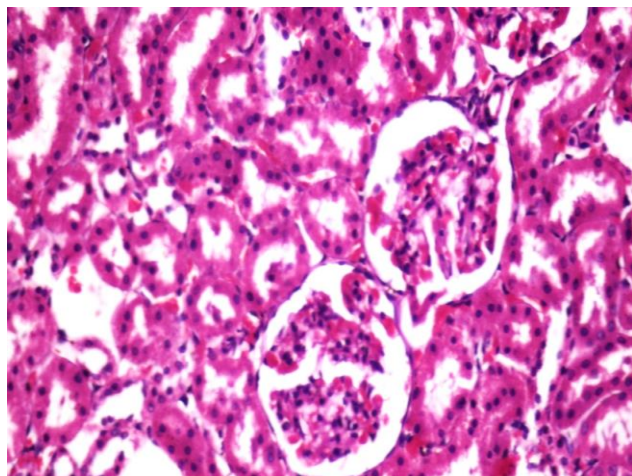
**Fig.6 (Hyperchol.) :**Aorta showing diffuse vacuolization in The media of the vascular wall (H&E X 400).



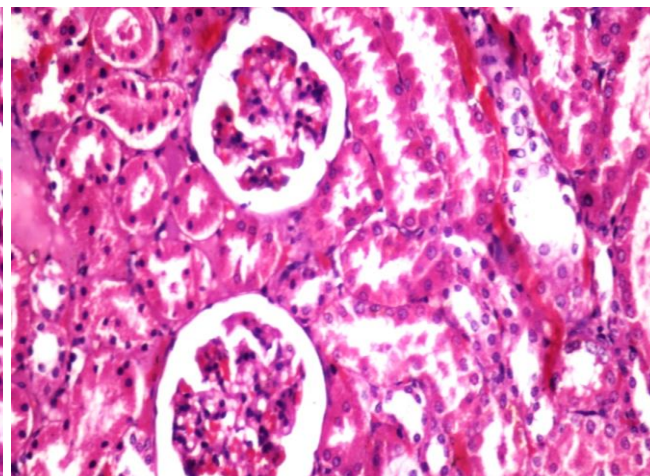
**Fig.7 (Hyperchol.+Ginger):** Aorta showing Few vacuolization in the media(H&E X 400).



**Fig.8 (Hyperchol.+Fishoil) :**Aorta showing focal few vacuolization in the media (H&E X 400).

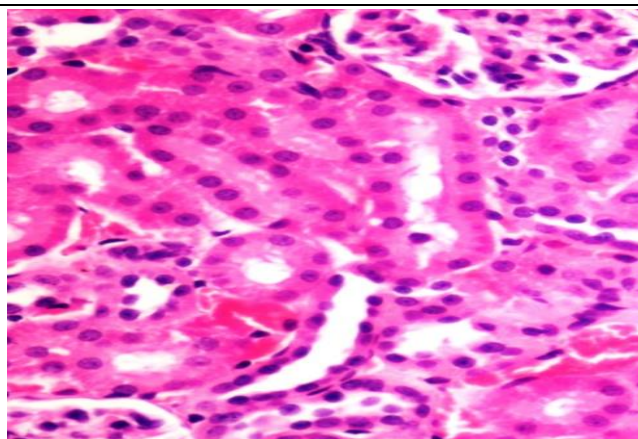


**Fig.9 (Control):** : Kidneys showing Normal renal glomeruli and renal tubules (H&E X 400).

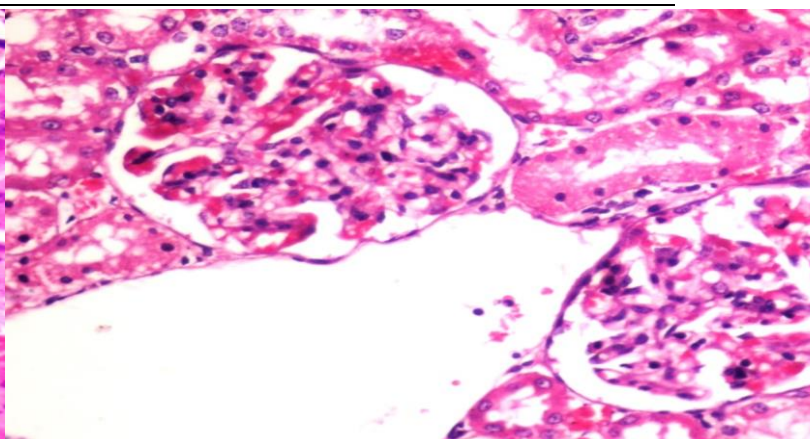


**Fig.10 (Hyperchol.) :** Kidneys showing degenerative renal tubules (H&E X 400).





**Fig.11 (Hyperchol.+Ginger):** Kidneys showing congestion in the interstitial blood vessels with no changes in renal tubules (H&E X 400).



**Fig.12 (Hyperchol.+Fish oil):** Kidneys showing congestion of the glomerular and peritubular blood capillaries and few alteration in renal tubules (H&E X 400).

### Discussion

In the present study, atherogenic diet feeding for 8 weeks was chosen as the experimental model of hypercholesterolemia. High fat diet containing 1 % cholesterol + 0.25 % bile salts was able to increase total cholesterol and LDL-C in Sprague Dawley rats likely by attenuation of bile acid production. Despite, such elevations alone will not promote atherosclerosis unless a thyroid hormone inhibitor is added (thiouracil), Propylthiouracil inhibits thyroid hormone by blocking iodine oxidation resulting in decrease of lipid metabolism. The presence of bile salts aids cholesterol and fat Absorption, and also suppresses conversion of cholesterol to bile acids reduces removal of cholesterol and increases cholesterol levels (**Shyam Sunder et al., 2010**). These was found to be on line with our results illustrated in Table (1), as it shows that the highest cholesterol levels were recorded in the untreated hypercholesterolemic group if compared with control and rats receiving several treatments. In addition, untreated hypercholesterolemic rats showed significant elevation in LDL-C, VLDL-C , AI and triglycerides if compared with control and all treated groups . However, it showed significant reduction in HDL cholesterol comparable with control group and those groups treated with ginger or fish oil . These results was found to agree with **Murugaiah et al., 1999; Stoilova et al., 2007; Abd El-Hamid et al., 2015**. Several studies revealed a significant elevation of plasma leptin concentration in hyperlipidemic

and diabetic rats. Leptin levels were positively correlated with triglyceride, cholesterol and LDL and an inverse relationship was found between leptin and HDL (**Zabut et al.,2007**). The hypercholesterolemia itself might induce increased serum leptin level (**Hang et al., 2012**). Hypercholesterolemic rat model is represented for cardiovascular and cerebrovascular disease research, which can be established by feeding with 0.5%-1.0% cholesterol-supplement diet for several weeks. Dietary 0.5%-1.0% cholesterol can increase serum VLDL and LDL levels dramatically in rats. In this case, dietary cholesterol remarkably disturbed triglyceride (TG) metabolism (**Wang et al., 2010**).

Also, the high levels of LDL-C found in hypercholesterolemic rats, may be attributed to a down regulation in LDL receptors by cholesterol and saturated fatty acids included in the diet, moreover, this increase in LDL-C level after high fat diet consumption might be explained via involvement of two enzymes namely cholesterol ester hydrolase and cholesterol ester synthetase. These enzymes balance the cholesterol levels in the blood. With increased esterifying activity (when cholesterol ester hydrolase: cholesterol ester synthetase is lowered) cholesterol will be predominantly in its ester form (as in LDL-C) and can lead to the development and progression of atherosclerosis (**Hussein et al., 2014**).

Hepatic TG level is controlled mainly by TG synthesis, beta-oxidation and secretion in the form of lipoprotein. The hepatic TG accumulation by high dietary cholesterol was

involved in the stimulation of fatty acid and TG synthesis in rats. Hepatic fatty acid beta-oxidation is another factor to affect the hepatic TG level. Carnitine palmitoyltransferase 1 (CPT1) is the rate-limiting enzyme of the mitochondria beta-oxidation pathway, hepatic CPT1 activity mRNA levels were inhibited drastically by the cholesterol treatment. Those results demonstrated that the cholesterol administration reduced fatty acid catabolism, which may account for the enhancement of hepatic TG level (Wang et al., 2010).

AI or LDL/HDL cholesterol ratio is one of the important components and indicators of vascular risk, the predictive value of which is greater than the isolated parameters. In this respect, an increase in total cholesterol concentration, and specifically LDL cholesterol, is an atherogenic lipid marker, whereas reduced HDL cholesterol concentration is correlated with numerous risk factors, including the components of the metabolic syndrome (Millán et al., 2009).

**Histopathological findings of hypercholesterolemic group in fig.2** showed multiple focal areas of degeneration with inflammatory cells infiltration were detected in the myocardium (recent infarctions) associated with focal haemorrhages, The myocardial vascular wall was thick and showed vacuolization in the media. While **fig.6** showed diffuse vacuolization in the media in the vascular wall of aorta. These findings agree with **Munshi et al. (2014)**, they recorded that The hypercholesterolemic (HC) rats showed histopathological changes representing structural alterations of the aortic wall indicating development of atherosclerotic changes. Similarly, the myocardial tissue was found to be damaged in the Hypercholesterolemic diet group. (Suanarunsawat et al., 2011).

Data presented in our study revealed that Ginger treatment increase the activity of liver microsomal aryl hydroxylase (AHH), and bile acid secretion. 7 $\alpha$ -Hydroxylase is the rate-limiting enzyme in the catabolic conversion of cholesterol to bile acids in the liver. The activation of this enzyme by ginger, increases bile acid secretion and in turn decrease the concentration of serum cholesterol observed in the ginger-treated rats (Murugaiah et al., 1999 and Olubunmi, 2011).

Whereas ginger treatment decreased the concentration of both LDL and VLDL in these rats, ginger is known to have strong antioxidant activity and thus it may prevent LDL oxidation in the serum, thus allowing normal binding of LDL to its receptors, permitting its uptake, and lysis by the cells. Thus, the LDL concentration of plasma may be decreased in ginger treated animals (Murugaiah et al., 1999 and Stoilova et al., 2007). And HDL-C increased significantly (Olubunmi, 2011). Administration of ginger showed significant decrease in plasma leptin levels in hyperlipidemic and diabetic rats. These explained due to gingerol which is a major chemical component of the ginger rhizome cause decreased in plasma leptin levels (Saravanan et al., 2014) so that led to elevation in HDL-C and may also due to ginger behaves like hypocholesterolaemic agents (Omnia, Abd El-Hamid et al., 2015). Though the atherogenic index was increased on feeding the atherogenic diet, it significantly decreased in rats treated with ginger, emphasizing the protective role of ginger in atherosclerosis (Murugaiah et al., 1999). Results revealed that there is lowering in the concentration of serum triglycerides on ginger supplementation if compared with hypercholesterolemic group, this may have resulted from stimulation of the skeletal muscle lipoprotein lipase and adipose tissue hormone-sensitive lipase activity by ginger administration, leads to increase in the uptake of plasma triglycerides by skeletal muscle and adipose tissue. Also, decreased levels of free fatty acids on ginger supplementation may also be a cause for reduced triglyceride levels, because ginger has an inhibitory action on the lipogenic enzymes (Murugaiah et al., 1999; Olubunmi, 2011).

**Histopathological findings of the GINGER treated group in fig.3** showed that myocardium has few focal degenerative change while others had less focal inflammatory cells infiltration. On the other hand, aorta in **fig.7** revealed few vacuolization detected in the media. These results in accordance with (Ilkhanizadeh et al., 2016, they recorded significant amelioration of changes in the heart structure upon ginger treatment. The findings indicated that ginger extract significantly reduces heart structural abnormalities.

Data presented in this study revealed significant reduction in serum cholesterol, LDL, VLDL triglycerides, significant elevation in HDL cholesterol and significant improvement in atherogenic index after administration of fish oil to hypercholesterolemic rats. These results agree with **Luka and Mohammed, 2013** and **Abdel-Moneim et al., 2015**.

Fish oil containing EPA and DHA long chain polyunsaturated fatty acids (PUFAs) was able to reduce serum tri-acylglycerol (TAG) and cholesterol and increased secretion of cholesterol, phospholipids and bile acids in rats, however most of cholesterol secreted in the form of HDL (**Morgado et al., 2005**). The n-3 fatty acids stimulate cholesterol secretion into bile salts, which can give reason why fish oil intervention shows no increase in serum cholesterol. In addition, **de Castro et al. (2015)** reported that serum TAG, total cholesterol and HDL cholesterol were higher in fructose fed rats and fish oil reversed these alterations. Also, these groups have lower non-HDL cholesterol, which indicates a significant reduction in more atherogenic lipoproteins. N-3 fatty acids was recorded to upregulate lipogenic gene expression of (SREBP-1c) and (ChREBP) are major transcriptional regulators that induce key lipogenic enzymes to promote lipogenesis in the liver (**de Castro et al., 2015**). The increase in HDL-C observed in our study, might be due to stimulation reverse cholesterol transport as demonstrated by previous study (**Makni et al., 2008**). fish oil administration in hyperlipidemic rats inhibits the activity of 3-hydroxy-3-methylglutaryl-CoA reductase (HMG-CoA reductase), which is the rate-limiting enzyme in cholesterol biosynthesis (**Luka and Mohammed, 2013**)

**In addition, fish oil treated group in fig.4** showed focal few inflammatory cells infiltration was detected in the myocardium. The subpericardium blood vessels were congested while the deep myocardial one showed thick hypertrophied wall with vacuolar endothelium. Aorta in **fig.8** showed focal few vacuolization in the media. These results in parallel with **Park and Park (2009)**. Moreover, **Rahman et al., 2016** recorded that dietary supplementation of fish oil to hypercholesterolemic rats led to alleviation of the myocardial injury induced by hypercholesterolemia.

Data presented showed significant elevation in serum (urea, uric acid and creatinine) in hypercholesterolemic group comparable with control and all treated groups. Recent studies have shown that orally feeding animals with high fat diet for a period of time can raise their cholesterol, increase production of low density lipoprotein cholesterol (LDL-C) and promote the de novo synthesis of purine nucleotide. This will eventually lead to increased generation of uric acid while its excretion is decreased (**Pang et al., 2017**). Another study found that high cholesterol levels can also cause oxidative stress, and uric acid production was accelerated in case of oxidative stress, which ultimately leads to elevated serum uric acid levels (**Bainbridge and Roberts, 2008**). Urea and creatinine levels are considered as markers of kidney injury when they are elevated in blood (**Khan et al., 2010**). Kidneys remove metabolic waste products such as urea, uric acid, creatinine, so body fluids homeostasis are maintained. It has been suggested that the concentrations of the metabolites increase in blood during renal diseases or renal damage may be due to enhancement in the activities of xanthine oxidase, lipid peroxidation, and increased triacylglycerol and cholesterol levels (**Khan et al., 2010**; **Barakat & Mahmoud, 2011**). Elevation in serum urea level in hypercholesterolemic group indicates the impairment in the kidney function, as the mechanism of removing it from the blood might have been affected. It may also be an evidence of impairment at the renal glomerular and tubular levels, it has been confirmed by many biochemical and histopathological findings that kidney functions were affected in hypercholesterolemia conditions (**Barakat & Mahmoud, 2011**). So that creatinin removal was impaired too (**Allen, 2012**).

**Histopathological findings of the hypercholesterolemic rats in fig.10** revealed that Kidneys has degenerative renal tubules. These results agree with **Schaeffner et al. (2003)** they observed that hypercholesterolemia results in severe tubular degeneration and necrosis, protein cast accumulation, and medullary congestion.

Results showed that ginger treatment showed significant improvement in serum urea, uric acid and creatinine if compared with



hypercholesterolemic group. These results in accordance with **Hamed et al., 2012**, who confirmed the potent nephroprotective properties of ginger. They found that treatment with different extracts of ginger ameliorated kidney function markers (urea, creatinine and total proteins). Additionally, **Mehrdad et al. (2007)** stated that ginger has a beneficial effect for removal of urea and creatinine from plasma of normal mice treated with its alcoholic extract and considered as a therapeutic herb to manage renal function. These results agree with **Lebda et al. (2012)**. They reported that the presence of polyphenols and flavonoids in ginger extract might be responsible for the antioxidant nephroprotective activities and the reduction of serum urea and creatinine levels. These found to be inline with **Rodrigues et al., 2014** recorded significant improvement in kidney functions with gingerol-enriched fraction supplementation and this protection was associated with reductions in oxidative stress and (nitric oxide) NO production and with down regulation of inflammatory gene expression.

Based on the in vivo results, the oral administration of ginger exerts notable hypouricemic effects in hyperuricemic but not in normal rats. These results indicate that ginger might have fewer side effects than allopurinol in treatment of hyperuricemia as allopurinol led to serum uric acid levels reduction of both hyperuricemic and normal rats (**Al-Azzawie and abd, 2015**). The inhibitory effect of ginger and its major flavonoid Gingerols on serum xanthin oxidase (XO) activity was also confirmed as XO is the key enzyme in the catabolism of purines and has a critical role in the endogenous production of uric acid (**Owen and Johns, 1999**).

**Histopathological findings of the ginger treated group in fig.11** revealed that kidneys showing congestion in the interstitial blood vessels with no changes in renal tubules. The

#### Conclusion

It could be concluded that ginger and fish oil supplementation decrease cholesterol, LDL, VLDL and triglycerides, while it increases HDL and showed anti-atherogenic potency against

corrective histopathological findings after treatment with ginger extracts give an additional support that ginger mops up free radicals generation, reduces inflammation, improves kidney function, and induces healthy state of renal cells, suggesting its role as renal protective agent. This was attributed to their abundance of natural antioxidants: flavonoids, sterols, and alkaloids (**Hamed et al., 2012**).

Data presented in this study showed significant amelioration in serum (urea, uric acid and creatinine) in fish oil treated group when compared with hypercholesterolemic group. These results found to agree with **Soltan (2012)**. These result may be due to the containing fish oil on polyunsaturated EPA and DHA. **de Assis et al. (2015)** stated that dietary n-3 polyunsaturated fatty acids reverse renal insult that increase the amounts of advanced glycation end product in rats. It has been reported that the high advanced glycation end products (HAGE) in fat-containing diet elevates the serum creatinine, tumor necrosis factor- $\alpha$ , thiobarbituric acid reactive substances (TBARS), and reactive oxygen species (ROS) levels and receptor for advanced glycation end products of the kidneys. Omega-3 Polyunsaturated fatty acids ameliorate these alterations and prevent renal dysfunction via antioxidant and anti-inflammatory pathways. DHA and EPA have several anti-inflammatory effects as they are oxidized by cyclo-oxygenase, lipoxygenases, or cytochrome P450 monooxygenases to produce docosanoids and EPA-derived eicosanoids, which have anti-inflammatory effects (**Katakura et al., 2014**).

**Histopathological findings of fish oil treated group in fig. 12** showed improvement in renal abnormalities induced by hypercholesterolemic diet, same results obtained by **Hassan et al. (2015)**, they documented fish oil nephroprotective potency against cisplatin nephrotoxicity

hypercholesterolemia as well as they revealed marked improvement in renal functions and attenuate insult induced by atherogenic diet in cardiac tissue, aorta and kidney.

## References

- Abd El-Hamid O.M., El-Shawarby R.M. and Abd-Elsamad N.A. (2015):** Biochemical effect of ezetimibe/ simvastatin and ginger root extract on hyperlipidemia and diabetes mellitus induced experimentally in rats . *BENHA VETERINARY MEDICAL JOURNAL*,28(1):53-66
- Abdel-Moneim A., Mahmoud B., Mahmoud R. (2015):** the benefecial effects of fish oil supplementation on hyperlipidemic and hypothyroid albino rats. *asian j pharm clin res*, 8 (4):324-329
- Afshari, A.T.; Shirpoor, A.; Farshid, A.; Saadatian, R.; Rasmi, Y.; Saboory, E.; Ilkhanizadeh, B.; Allameh, A.(2007):** The effect of ginger on diabetic nephropathy, plasma antioxidant capacity and lipid peroxidation in rats. *Food Chem.* , 101: 148–153
- Akinyemi AJ, Oboh G, Ademiluyi AO, Boligon AA, Athayde ML.(2015):** Effect of two ginger varieties on arginase activity in hypercholesterolemic rats. *Journal of Acupuncture and Meridian Studies* , 9(2):80-87
- Al-Azzawie H. F. and abd S. A. (2015):** effect of some plant extracts on serum uric acid levels, and xanthine oxidase activity in vitro and in oxonate-induced hyperuricemic rats. *ejpmr*,2(6): 55-61
- Allen PJ (2012):** Creatine metabolism and psychiatric disorders: Does creatine supplementation have therapeutic value?". *Neurosci Biobehav Rev*. 36 (5): 1442–1462.
- Bainbridge SA, Roberts JM (2008):** Uric acid as a pathogenic factor in preeclampsia. *Placenta*, 29 (Suppl. A): 67–72.
- Bancroft, J.D., A. Stevens and D.R. Turner, (1996):** Theory and Practice of Histological Techniques. 4th Edn., Churchill, Livingston, New York, London, San Francisco, Tokyo.
- Barakat, L. A. A., & Mahmoud, R. H. (2011):**The antiatherogenic, renal protective and immunomodulatory effects of purslane, pumpkin and flax seeds on hypercholesterolemic rats. *North American Journal of Medical Sciences*, 3(9):411–417.
- Bhatnagar D.,Soran H., Durrington P.N.(2008):** Hypercholesterolaemiaand its management. *BMJ* , 337(a993):503-508
- de Assis AM , Rech A, Longoni A, da Silva Morrone M, de Bittencourt Pasquali MA, Perry ML, Souza DO, Moreira JC (2015):** Dietary n-3 polyunsaturated fatty acids revert renal responses induced by a combination of 2 protocols that increase the amounts of advanced glycation end product in rats. *Nutr Res.* , 35(6):512-22
- de Castro GS, Deminice R, Simões-Ambrosio LM, Calder PC, Jordão AA, Vannucchi H (2015):** Dietary Docosahexaenoic Acid and Eicosapentaenoic Acid Influence Liver Triacylglycerol and Insulin Resistance in Rats Fed a High-Fructose Diet. *Mar Drugs*. 1;13(4):1864-81
- FadlAlla, E.A.S., Owiss, N.A., Seddik, A.A.,Galal, S.M. 2014:** Hypolipidemic, antioxidant and renal protective effect of seeds mixture rich in omega-3 and omega-6 fatty acids in rats. *Life Science Journal*, 11: 866-877.
- Fawcett J.K. Scott J.E. (1960)** *J. Chim. Pathol.* 13 : 156.
- Fernandez R., Piechnik J. , Fabris R., Malnic G.and Fernandes L.C. (2004):** Effect of chronic fish oil supplementation on renal function of normal and cachectic rats. *Braz J Med Biol Res* 37(10) : 1481-1489.
- Finley PR et al.(1978):** *Clin Chem.*, 24:391.
- Finn AV, Nakano M, Narula J, Kolodgie FD, Virmani R ( 2010):** Concept of vulnerable/unstable plaque . *Arterioscler. Thromb. Vasc. Biol.* 30 (7): 1282–1292.
- Fossati, P., Prencipe, L., and Berti, G. (1980) ,** *Clin. Chem.* 26(2): 227-231 .
- Friedewald WT, Levy RI, Fredrickson DS.(1972):** Estimation of the concentration of low-density lipoprotein cholesterol in plasma, without use of the preparative ultracentrifuge. *Clin Chem.*;18:499-502
- Hamadani M., and Asadiagajari M., Vahdatpour T., Salehzadeh Y. and Vahdatpour S. (2011):** Efficiency of dietary fish oil for regulation of hyperlipidemia and hyperglycemia in diabetic rats. *Annals of Biological Research*, 2 (3):75-81
- Hamed, M. A., Ali, S. A., & Saba El-Rigal, N. (2012):** Therapeutic Potential of Ginger against Renal Injury Induced by Carbon Tetrachloride in Rats. *The Scientific World Journal*, 2012, 840421.

- Hang, Q., He, B., Yang, F., Zeng, H., Zhao, Q. (2012):** Effect of High-Cholesterol Diet on Serum Leptin and Blood Lipid in Rabbits. *Journal of Animal and Veterinary Advances*, 11:1719-1721
- Hans L.K., Goup X.J., Kawano S., Saito M., Kimura Y., Okada H. (2005):** Antiobesity actions of *Zingiber officinale* Roscoe, *Yakugaku Zasshi*, 125: 213-217.
- Hassan HA, Edrees GM, El-Gamel EM, El-Sayed EA. (2015):** Proanthocyanidin and fish oil potent activity against cisplatin-induced renal cell cycle arrest and apoptosis in rats. *Ren Fail.*, 37(8):1356–1362
- Hussein A. S., El-Senosi A.Y., Ragab R. M., Hammad M.M.F. (2014):** Hypolipidemic effect of curcumin in hyper-cholesterolemic rats. *BENHA VETERINARY MEDICAL JOURNAL*, 27(2) :277-289.
- Ilkhanizadeh, B., Shirpoor, A., Khadem Ansari, M. hasan, Nemati, S., & Rasmi, Y. (2016).** Protective Effects of Ginger (*Zingiber officinale*) Extract against Diabetes-Induced Heart Abnormality in Rats. *Diabetes & Metabolism Journal*, 40(1): 46–53.
- Katakura, M., Hashimoto M, Inoue T, Mamun A, Tanabe Y, Iwamoto R & Arita M & Tsuchikura S & Shido O. (2014):** Omega-3 Fatty Acids Protect Renal Functions by Increasing Docosahexaenoic Acid-Derived Metabolite Levels in SHR.Cg-Lepr(cp)/NDmcr Rats, a Metabolic Syndrome Model. *Molecules* (Basel, Switzerland). 19: 3247-3263.
- Khan R. A., Khan M. R., Sahreen S., and Bokhari J.(2010):**Prevention of CCl4-induced nephrotoxicity with *Sonchus asper* in rat,” *Food and Chemical Toxicology*, 48, (8-9): 2469–2476.
- kumar G, Sharma A (2014)** Medicinal properties of *Zingiber officinale* Roscoe - A Review. *IOSR Journal of Pharmacy and Biological Sciences (IOSR-JPBS)*, 9(5): 124-129
- Lebda MA, Taha NM, Korshom MA, Mandour AEI, El-Morshedy AM. (2012):** Biochemical effect of ginger on some blood and liver parameters in male New Zealand rabbits. *Online J. Anim. Feed Res.*, 2(2): 197-202.
- Lin, P.-Y., Chen, C.-H., Wallace, C. G., Chen, K.-H., Chang, C.-L., Chen, H.-H., ... Yip, H.-K. (2017):** Therapeutic effect of rosuvastatin and propylthiouracil on ameliorating high-cholesterol diet-induced fatty liver disease, fibrosis and inflammation in rabbit. *American Journal of Translational Research*, 9(8): 3827–3841.
- Luka, C.D and Mohammed, A (2013):** Effect of Fish Oil on High Lipid Fed Albino Rats. *Journal of Medical and Applied Biosciences*, 5 (1):1-7
- Makni M., Fetoui H., Gargouri N.K., Garoui E.M., Jaber H., Makni J., Boudawara T., Zeghal N. (2008):** Hypolipidemic and hepatoprotective effects of flax and pumpkin seed mixture rich in  $\alpha$ -3 and  $\alpha$ -6 fatty acids in hypercholesterolemic rats. *Food and Chemical Toxicology*, 46 : 3714–3720
- Maruthappan, V., & Shree, K. S. (2010):** Effects of *Phyllanthus reticulatus* on lipid profile and oxidative stress in hypercholesterolemic albino rats. *Indian Journal of Pharmacology*, 42(6):388–391.
- Mehrdad M., Messripour M., and Ghobadipour M.(2007):** The effect of ginger extract on blood urea nitrogen and creatinine in mice. *Pakistan Journal of Biological Sciences*, 10 (17):2968–2971.
- Millán, J., Pintó, X., Muñoz, A., Zúñiga, M., Rubiés-Prat, J., Pallardo, L. F., ... Pedro-Botet, J. (2009).** Lipoprotein ratios: Physiological significance and clinical usefulness in cardiovascular prevention. *Vascular Health and Risk Management*, 5: 757–765.
- Morgado, N.; Rigotti, A.; Valenzuela, A.(2005):** Comparative effect of fish oil feeding and other dietary fatty acids on plasma lipoproteins, biliary lipids, and hepatic expression of proteins involved in reverse cholesterol transport in the rat. *Ann. Nutr. Metab.*, 49: 397–406.
- Munshi RP, Joshi SG, Rane BN (2014):** Development of an experimental diet model in rats to study hyperlipidemia and insulin resistance, markers for coronary heart disease, 46 (3) : 270-276
- Murugaiah J.S., Namasivayam N., and Menon V.P. (1999):** Effect of Ginger (*Zingiber officinale* R.) on Lipids in Rats Fed Atherogenic Diet *J Clin. Biochem. Nutr.*, 27: 79-87.
- Olorunnisola OS, Bradley G, Afolayan AJ.(2012):** Protective effect of *T. violacea* rhizome extract against hypercholesterolemia-induced oxidative stress in Wistar rats. *Molecules*. 17(5):6033–6045.



- Olubunmi B. A. (2011):** Effect of Ginger Powder (*Zingiber Officinale*) on Plasma Lipid Profile and Liver Enzyme Activities of Hypercholesterolemic Rats. *Journal of Life Sciences*, 5 : 712-716
- Owen, PL, Johns, T. (1999):** Xanthine oxidase inhibitory activity of Northeastern North American plant remedies used for gout. *Journal of Ethnopharmacology*, 64: 149-160
- Pang M. , Fang Y., Chen S. , Zhu X., Shan C., Su J., Yu J., Li B., Yang Y., Chen B., Liang K., Hu H , Lv G.(2017):** Gypenosides Inhibits Xanthine Oxidoreductase and Ameliorates Urate Excretion in Hyperuricemic Rats Induced by High Cholesterol and High Fat Food (Lipid Emulsion). *Med Sci Monit.* , 4(23):1129-1140.
- Park S and Park y (2009):** Effects of dietary fish oil and trans fat on rat aorta histopathology and cardiovascular risk markers. *Nutrition Research and Practice* , 3(2), 102-107
- Rahman MS, Asaduzzaman M, Munira S, Begum MM, Rahman MM, et al. (2016)** Comparative Study of Anti-Hyperglycemic and Anti- Hyperlipidemic Effects of Honey, *Coccinia cordifolia* and *Hilsha* Fish Oil in Streptozotocin Induced Diabetic Rats. *Biol Med (Aligarh)* 8(2):272.
- Rodrigues, F. A. P., Prata, M. M. G., Oliveira, I. C. M., Alves, N. T. Q., Freitas, R. E. M., Monteiro, H. S. A., ... Havt, A. (2014):** Gingerol Fraction from *Zingiber officinale* Protects against Gentamicin-Induced Nephrotoxicity. *Antimicrobial Agents and Chemotherapy*, 58(4), 1872–1878.
- Rozman D. and Monostory K. (2010):** Perspectives of the non-statin hypolipidemic agents. *Pharmacology & Therapeutics*. 127: 19–4
- Saravanan, G., Ponnuragan, P., Deepa, M. A. and Senthilkumar, B. (2014),** Anti-obesity action of gingerol: effect on lipid profile, insulin, leptin, amylase and lipase in male obese rats induced by a high-fat diet. *J. Sci. Food Agric.*, 94: 2972–2977.
- Schaeffner ES, Kurth T, Curhan GC et al (2003):.** Cholesterol and the risk of renal dysfunction in apparently healthy men. *J Am Soc Nephrol.* , 14: 2084–2091.
- Scheletter G. and Nussel E. (1975):**Arbeitsmed Sozialmed Pracentimed 10:25.
- Schirmeister, J., William, H and Kiefer, H (1964):** Creatinine standard and measurement of serum creatinine with picric acid. *Deutsche Medizinische Wochenschrift*, 89: 1018-1021.
- Schulpis K, Karikas GA.(1998):** Serum cholesterol and triglyceride distribution in 7767 school-aged Greek children. *Pediatrics* ,101:861-864
- Shyam Sunder A., Rama Narsimha Reddy A., Rajeshwar Y., Kiran G., Krishna Prasad D., Baburao B., Thirumurugu S., Karthik A.** Protective effect of methanolic extract of *Trianthema portulacastrum* in atherosclerotic diet induced renal and hepatic changes in rats. *Der Pharmacia. Lettre.*, 2:540–545.
- Sinclair and R. Gibson, eds. 1992.:** Essential fatty acids and eicosanoids Champaign, Illinois, USA. American Oil Chemists' Society. 353pp
- Snedecore, G.W.and Cochran, W.G. (1980):** Statistical methods.7thed.,Ames:Iowastate university press.
- Soltan S S (2012):** the Effects of Varieties Sources of Omega-3 Fatty Acids on Diabetes in Rats . *Food and Nutrition Sciences*, 3:1404-1412
- Stapleton PA, Goodwill AG, James ME, Brock RW, Frisbee JC(2010):** Hypercholesterolemia and microvascular dysfunction: interventional strategies. *J Inflamm (Lond)* , 7:54
- Stoilova A., Krastanov A., Stoyanova A., Denev P, Gargova S. (2007):** Antioxidant activity of a ginger extract (*Zingiber officinale*). *Food Chemistry* ,102 : 764–770
- Suanarunsawat, Thamolwan & Devakul Na Ayutthaya, Watcharaporn & Songsak, Thanapat & Thirawarapan, Suwan & Pongshompoo, Somlak. (2011):** Lipid-Lowering and Antioxidative Activities of Aqueous Extracts of *Ocimum sanctum* L. Leaves in Rats Fed with a High-Cholesterol Diet. *Oxidative medicine and cellular longevity*. 962025.
- Tandra, S., & Vuppalanchi, R. (2009):** Use of statins in patients with liver disease. *Curr. Treat. Options Cardiovasc. Med.* 11(4), 272–278.
- Tzang B. S. , Yang S.F. , Fu S.G. ,Yang H.C. ,Sun H. L., Chen Y.C. (2009):** Effects of dietary flaxseed oil on cholesterol metabolism of hamsters. *Food Chemistry*, 114 :1450–1455.
- Uz Uz E, Karatas OF, Mete E et al.(2009):** The effect of dietary ginger (*Zingiber officinalis* Roscoe) on renal ischemia/reperfusion injury in rat kidneys. *Renal Failure* ,31: 251–260
- Wang, Y.-M., Zhang, B., Xue, Y., Li, Z.-J., Wang, J.-F., Xue, C.-H., & Yanagita, T.**

(2010): The mechanism of dietary cholesterol effects on lipids metabolism in rats. Lipids in Health and Disease, 9: 4.

**Warnick GR, Knopp RH, Fitzpatrick V, Branson L.(1990):** Estimating low-density lipoprotein cholesterol by the Friedewald equation is adequate for classifying patients on

the basis of nationally recommended cutpoints. Clin Chem., 36(1):9-15.

**Zabut, B., Naji, H., Holi, B., Yousef, A.( 2007):** Leptin and Soluble Leptin Receptor among Obese Adults in the Gaza Strip. The Islamic University Journal (Series of Natural Studies and Engineering), 15: 127-140.

### الملخص العربي

#### تحسن في مستويات دهون الدم ووظائف الكلي نتيجة استخدام الزنجبيل و زيت السمك في ذكور الفئران عالية الكوليستيرول

ارتفاع كوليستيرول الدم هو احد أهم العوامل للإصابة بتصلب الشرايين وأمراض القلب والأوعية الدموية. قد تم في هذه الدراسة تقييم الآثار العلاجية للزنجبيل وزيت السمك علي مستوى الدهون في الدم ووظائف الكلي وذلك في ذكور الفئران التي تم تغذيتهم بنظام غذائي عالي الكوليستيرول. تم تقسيم الحيوانات الي اربع مجاميع تتكون من اثني عشرة فأرا لكل منهما. المجموعة الاولى هي المجموعة الضابطة. ثم تم تغذية بقية المجاميع بالنظام الغذائي عالي الكوليستيرول لإحداث تصلب الشرايين لمدة ثمانية أسابيع , بينما المجموعة الثالثة تم إضافة 5% من الزنجبيل إلي النظام الغذائي. المجموعة الرابعة تم إضافة زيت السمك بنسبة 10 % إلي نظامهم الغذائي. أدت هذه المعاملات إلي إنخفاض معنوي في مستويات الكوليستيرول الكلي, الدهون الثلاثية , والبروتينات الدهنية منخفضة الكثافة, والبروتينات الدهنية شديدة إنخفاض الكثافة وأرتفاع معنوي في البروتينات الدهنية عالية الكثافة وتحسن في معامل حدوث تصلب الشرايين. بالإضافة إلي إنخفاض معنوي في مستويات اليوريا وحمض اليوريك و الكرياتينين والتي أرتفعت نتيجة النظام غذائي عالي الكوليستيرول. وقد خلصنا من هذه النتائج إلي تحسن ملحوظ في دهون الدم ووظائف الكبد نتيجة إضافة الزنجبيل و زيت السمك إلي النظام الغذائي لذكور الفئران عالية الكوليستيرول.