



## Marginal bone level evaluation for combined tooth-implant retained Kennedy Class I Partial denture versus implant retained partial denture using extracoronar attachments

Ahmed A.Elwahed Shaban <sup>\*1</sup>, Bassem Mohsen<sup>1</sup>, Aya M. Fawzy<sup>1</sup>, Shams Waaz Amgad<sup>2</sup>

Codex : 16/1910

Aadj@azhar.edu.eg

### KEYWORDS

*Partial edentulism, tooth and implant connection, combination fixed partial dentures, bridges, dental implants*

### ABSTRACT

**Aim:** This study was conducted to evaluate and compare marginal bone level for Tooth-implant supported Kennedy class I partial denture compared to implant supported Kennedy class I partial denture using extracoronar attachments. **Subjects and Methods :** Ten male partially edentulous patients (Kennedy class I) with the canines are the last standing abutments were selected and all patients were rehabilitated with metallic partial denture supported by osseointegrated implants one on each side of the arch positioned in the premolar area and were randomly divided into two equal groups according to type of abutments, Group I; Patients were rehabilitated with Tooth Implant Retained partial denture with extra coronal attachment, Group II; Patients were rehabilitated with splinted Implant Retained partial denture with extra coronal attachment on each side. Evaluation by measuring marginal bone level for last main abutments was made at the time of insertion, after 6 month, after 12 month and last after 18 month using radiographic evaluation. **Results:** Partial dentures retained by two splinted implants showed better non-significant difference in marginal bone loss as compared with tooth implant retained Partial dentures. **Conclusion:** Using tooth implant retained partial dentures shows better effect on supporting structure as compared compared with tooth implant retained Partial dentures.

### INTRODUCTION

The mutual usage of teeth and implants as anchors for prosthetic restorations remains a debatable issue for the restoration of partial edentulism.<sup>1</sup> Implants become osseointegrated and consequently have an unyielding connection to supporting bone, teeth are supported by the periodontal ligament, permitting for physiologic mobility. Complications such as breakage of mechanical parts and a higher frequency of caries at the crown margin and tooth intrusion have been designated. The use of both rigid and non-rigid connectors of different designs has been suggested to diminish these effects.<sup>2,3</sup>

1. Department of Prosthodontics, Faculty of Oral and Dental Medicine, Future University, Egypt
2. Department of fixed prosthodontics, Faculty of Oral and Dental Medicine, El Minia University, Egypt.

\* Corresponding Author e-mail: ahmed.shaban@rocketmail.com

A study confirms that the stress-breaking action of the non-rigid connector, clarifying decrease of stresses within the implant by a factor of 24 when the force is applied on the tooth side. There are numerous reasons support the joining of teeth and implants. When the implant segments are not self-sustained, either because of inadequate number, very short implants or inadequate bone, it might be essential to construct a mixed prosthesis. Additional causes include financial concerns for extra placement of implants and surgical augmentations in order to achieve completely implant-supported restorations. In addition, it is thought that the tooth will provide additional support for the restoration and increase the antirotational resistance of the screw joint. Finally, in periodontally compromised cases, the implants can provide stabilization of the teeth.<sup>4,5</sup>

Tooth-to-implant connection can be a rational treatment choice in certain clinical situations, but that rigid connection should be used with caution particularly when there are periodontal problems.<sup>6</sup> It has been stated that the usage of tooth-implant supported prosthesis significantly reduce mechanical problems hazard once compared to implant supported prosthesis. However these studies lack a long-term follow-up period. Excessive loading on implants and/or the supporting bone is risky. When implant components are exposed to excessive stress continuously, this phenomenon leads to affecting implant components or fracture of components due to metal fatigue. The purpose of this article to investigate the connection of implants and teeth and recommend a design concept that can minimize biologic and technical complications

## MATERIALS AND METHODS

Ten male partially edentulous patients (Kennedy class I) with the canines are the last standing abutments were selected and all patients were rehabilitated with metallic partial denture supported by two osseointegrated implants one on each side of the arch positioned in the area of premolar area

and were randomly divided into two equal groups according to type of abutments, Group I; Patients were rehabilitated with Tooth Implant Retained partial denture with extra coronal attachment, Group II; Patients were rehabilitated with splinted Implant Retained partial denture with extra coronal attachment on each side.

## Surgical procedures for both groups

### A. Pre-surgical preparation

Surgical stents were constructed (Fig.1 )

A hole was drilled in the implant site corresponding to the premolar area in the preoperative Surgical stents

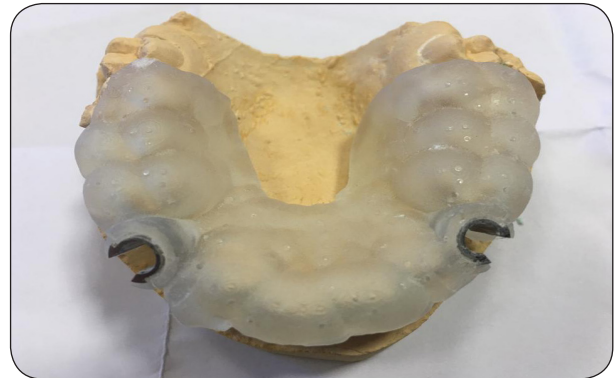


Fig. (1) Surgical stent

### B. Implant selection

A color guided implant system; V-TPS (Vacuum-Titanium Plasma Spray) coating root form, cylindrical screw, internally hexed titanium implants and self tapping expansion thread system were used. They are available in five diameters and five lengths ranging from 8 to 16 mms. The 10 mmlength and 3.75 mm diameter was used. . ring infiltration anesthesia was given at the corresponding side to the surgical region

The autoclaved surgical stent was seated in the patient's mouth to identify exact area for implant insertion. Mucoperiosteal flap was made.

Surgical stent was modified and introduced in the patient's mouth, to mark the exact fixture site.

### C. Surgical procedures for both groups

Osteotomy was made using successive drills at predetermined implant site and Implant fixtures were inserted in place and titanium cover screws of the same diameter of the implant were screwed into implant fixture. The flap was irrigated with saline, repositioned and secured by interrupted sutures. (Fig.2)

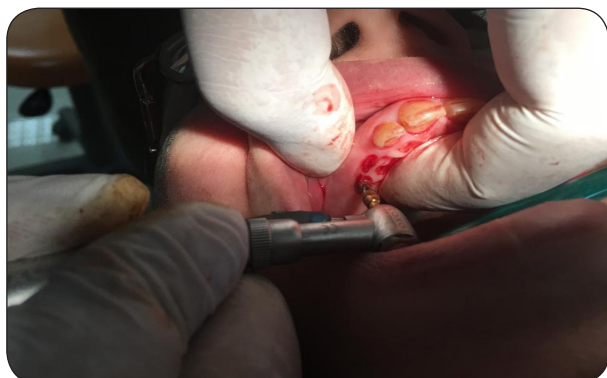

Fig. (2) Osteotomy with successive drills

Three months after implant placement, the patient was recalled, and Fixture position was detected by palpation with the aid of surgical stent and the site was marked and exposed.

The cover screw was unthreaded and a healing collar of 4mm length was selected, inserted and threaded into the implant by the aid of implant driver and tightened well.(fig 3)

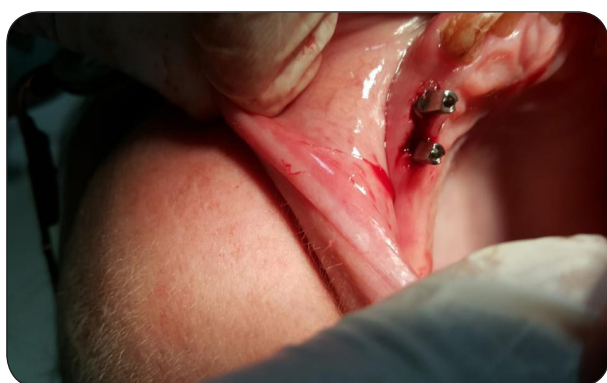

Fig. (3) Implant abutments in place

## Prosthetic treatment

### Preparation of the abutment teeth :

Primary impressions were made using alginate impression material in a suitable stock tray and poured in dental stone to obtain the primary casts on which individual trays were constructed on a 2mm spacer.

All teeth were prepared with a deep chamfer finishing line extend sub-gingivally (0.51mm) with sufficient occlusal (2-2.5mm) and circumferential reduction (1-1.5mm) to receive two full porcelain veneered crowns.

Gingival margin of the prepared abutments were retracted by retraction cord before impression making.

Putty impression was made. Dual impression was carried out in the conventional manner. The prepared abutments were protected by readymade temporary crowns which were cemented using temporary cement. The impression was then washed, inspection and poured in extra-hard dental stone

The obtained cast was sawed to obtain separate removable dies for the prepared abutments. The dies were indicated by ditching and the wax patterns of both crowns were built-up and the unilateral OT attachments was added to wax pattern. The dies were replaced on the cast which was placed on the table of the milling machine. The framework was waxed, sprued, flaked and processed into metallic framework

Centric occluding relation following the inter-occlusal wax wafer technique was made and a try in stage was made successfully. and final pickup impression were done fig 4,5

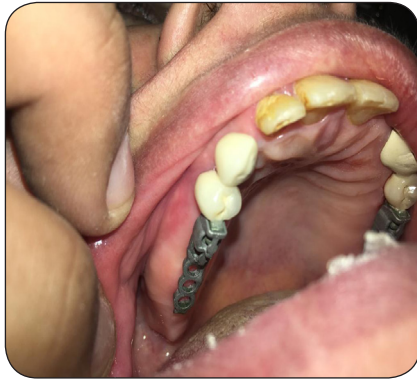

Fig. (4) Try in for framework

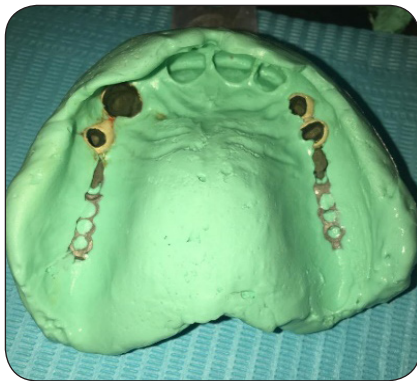

Fig. (5) Pickup impression

**Radiographic evaluation**

- Cone beam C.T. were developed and image processed.
- A line tangential to the apex and perpendicular to abutments long axes was drawn . Two lines were drawn one on the mesial and the other on the distal side of the abutment starting from the alveolar crest extended along tooth lamina dura till the tangential line at the tooth apex. (Fig. 6)
- The amount of bone loss was calculated by subtracting the measured distances between each radiographic evaluation made at the time of denture insertion and the recall appointments.
- Data were collected for all patients at different follow-up intervals. Data were tabulated and statistically analyzed.




Fig. (6) Radiographic evaluation

**RESULTS**

Table (1)

Relation in marginal bone level between abutments in RPD with *tooth implant retained* RPD with *splinted implant* abutments retained RPD :

Treatment modality	RPD with <i>tooth implant connection</i>		RPD with <i>splinted implant</i> abutments retention		P-Value
	(Group I)		(Group II)		
Time	Mean	S.D.	Mean0.37	S.D.	
Zero-time –6 M	1.12	0.15	1.34	0.32	1.05
Zero-time –12 M	1.94	0.21	2.38	0.37	1.9
Zero-time–18 M	2.1	0.19	2.98	0.347	1.6

*S.D.= Standard deviation.*

*P-Value < 0.05 is significant value*

The amount of bone loss was calculated by subtracting the measured distances between each radiographic evaluation made at the time of denture insertion and the recall appointments.

**DISCUSSION**

The design of the finished partial denture was the same for all patients of both groups for more reliable results. The design was formulated according to the common principles and concepts followed in distal extension cases. <sup>(11)</sup>





In this study the mean values for the amount of marginal bone loss around the abutments teeth in group I RPD with *tooth implant connection* group was 1.94 mm while in group II RPD with *total implant* abutments retention group was 2.38 mm, twelve months after wearing the partial denture. The insignificant difference between the two groups at the end of one-year follow up period may be due to the strain concentrated on the periodontal ligaments of abutment teeth and its surrounding tissues from repeated removal forces of prosthesis retained by tooth implant abutments. In agreement with Gun-gor et al. this strain concentrated on the bone and the tensile stresses on the periodontal tissues might cause resorption around the cervical region which is same situation as group II RPD with *total implant* abutments retention group which produce stresses on the crestal bone due to absence of periodontal ligament around implant fixture and load concentration in the crestal area <sup>(11)</sup>

Marginal bone loss around implants due to stresses upon them and most of the occlusal stresses dissipated along the saddle area lead to insignificantly marginal bone loss compared to group II retained two splinted implants with additional retentive means to the abutments and that also reflects posteriorly on marginal bone loss around posterior implants leading to insignificant marginal bone loss compared to Group I <sup>(12)</sup>

Rigid precision attachments are designed to mechanically engage the abutment teeth so as to prevent muscular and gravitational forces from dislodging the denture during function. Unfortunately, rigid connectors apply lateral forces to the abutment teeth that are ultimately destructive through their torquing action. These attachments may be no less harmful to the abutment teeth than conventional clasps. The effect of this forces on the alveolar ridge bone dissipated through the periodontal ligament for group I in addition to saddle area. <sup>(13)</sup>

By contrast, the passive, free-moving attachment dissipates destructive lateral forces, preventing their

infliction on the abutment teeth. Although the partial cannot be dislodged during function, it can move in a vertical direction slightly to release the forces instead of passing along these forces to the abutment teeth. The result is physiologic stimulation of the abutment teeth and the edentulous ridges. Clinical experience has shown that this physiologic stimulation results in increased longevity of the abutment teeth, even when a few teeth are required to carry the load of an entire arch. The stimulation of the edentulous ridge also prevents the bone resorption that typically reduces tissue support for the partial denture. The tissue under a well-fitting precision attachment partial is typically pink, healthy and firm. <sup>(14)</sup>

With the introduction of unilateral attachment, it was possible to restore distal extension areas without the need of cross arch extension. The support of RPD and its connection with fixed prosthesis generates cross arch stability throughout masticatory activity and permits function similar to that of fixed prosthesis. Use of stress attachment system minimizes the metal display which improves esthetics. <sup>(15)</sup>

## CONCLUSION

Within the limitation of the results of this study, it could be concluded that using tooth implant supported partial dentures retained by extracoronal OT unilateral attachments showed the same clinical effect on marginal bone loss when compared with implant supported partial dentures.

## REFERENCES

1. Menicucci G, Mossolov A, Mozzati M, Lorenzetti M, Preti G. Tooth-implant connection: some biomechanical aspects based on finite element analyses Clin. Oral Impl. Res, 13, 2002; 334-341
2. Hoffmann O, Zafiroopoulos GG, Tooth-Implant Connection: A Review Journal of Oral Implantology, Vol. XXXVIII/No. Two/2012

3. Ramoglu, S., Tasar, S., Gunsoy, S., Ozan, O. & Meric, G. Tooth-Implant Connection: A Review. *ISRN Biomaterials* 2013, 1–7 (2012).
4. Winston W. Chee, Mordohai N, Tooth-to-Implant Connection: A Systematic Review of the Literature and a Case Report Utilizing a New Connection Design, *Clinical Implant Dentistry and Related Research*, Volume 12, Number 2, 2010
5. Ramoglu, S., Tasar, S., Gunsoy, S., Ozan, O. & Meric, G. Tooth-Implant Connection: A Review. *ISRN Biomaterials* 2013, 1–7 (2012).
6. Hita-Carrillo C, Hernández-Aliaga M, Calvo-Guirado JL. Tooth-implant connection: A bibliographic review. *Med Oral Patol Oral Cir Bucal*. 2010 Mar 1;15 (2):e387-94.
7. Patel H, Patel K, Thummer S, Patel R. Use of precision attachment and cast partial denture for long-span partially edentulous mouth - A case report *International Journal of Applied Dental Sciences* 2014; 1(1): 22-25.
8. Wangoo A, Kumar S, Phull S, Gulati M. Prosthetic Rehabilitation Using Extra Coronal Castable Precision Attachments. *Indian Journal of Dental Sciences [serial online];6(4):038-040, October 2014*
9. Bulent B, Polat S, Sahin V, Tokar E, & Goktug G, A Technique for Fabrication of an Extracoronal Attachment-Retained Removable Partial Denture to Fit an Existing Fixed Partial Denture *Journal of Prosthodontics* 138–140, 2012.
10. Sravanthi G, Dinesh B, Taruna M, Prasad V: Unilateral Attachment Retained Distal Extension Removable Partial Denture, *Indian J Dent Adv*; 6(4): 1727-1730, 2014.
11. Gungor MA, Artunc C, Sonugelen M and Toparli M: The evaluation of the removal forces on the conus crowned telescopic prostheses with the finite element analysis (FEA). *J Oral Rehabil*, 29(11): 1069-75, 2002
12. Ogata K: Longitudinal study on torque around sagittal axis in lower distal extension dentures. *J. Oral Rehab.*; 20: 203, 1993.
13. Ito K, Gomi Y, Sato S, Arai Y and Shinoda K: Clinical application of a new compact CT system to assess 3-D images for the preoperative treatment planning of implants in the posterior mandible A case report. *Clin Oral Implants Res*, 12(5): 539-42,2001.
14. Jain AR, Philip JM and Ariga P: Attachment- retained unilateral Distal Extension (Kennedy's class II modification I) Cast partial Denture. *Int J Prosthodont Restor Dent*; 2(3):101-107, 2012.
15. Sravanthi G, Dinesh B, Taruna M, Prasad V: Unilateral Attachment Retained Distal Extension Removable Partial Denture, *Indian J Dent Adv*; 6(4): 1727-1730, 2014.





# الأزهر

## مجلة أسبوت طب الأسنان

النشر الرسمي لكلية طب الأسنان  
جامعة الأزهر أسيوط  
مصر

AADJ, Vol. 2, No. 1, April (2019) — PP. 141

## مقارنة تقييم مستوي هامشي للعظام للاطقم الجزئية كينيدي التصنيف الأول المدعّم بالزرعات مقابل المدعّم بالاسنان والزرعات معا

احمد عبدالواحد شعبان<sup>1</sup>, باسم محسن<sup>1</sup>, ايه محمد فوزى<sup>1</sup>, شمس وعظ امجد<sup>2</sup>

<sup>1</sup> قسم التركيبات المتحركة بكلية طب الفم والاسنان جامعة المستقبل، القاهرة، مصر

<sup>2</sup> قسم التركيبات المثبتة بكلية طب الفم والاسنان جامعة المنيا، مصر

\*\* البريد الإلكتروني: AHMED.SHABAN@ROCKETMAIL.COM

### الملخص :

**الهدف:** الغرض من الدراسة محاولة مقارنة تقييم مستوي هامشي للعظام للاطقم الجزئية كينيدي 1 المدعّم بالزرعات مقابل المدعّم بالاسنان والزرعات معا.

**المواد والاساليب:** تم وضع غرسات في 10 مرضي يعانون من فقد اسنان الخلفيه علي الجانبين حتي الناب ثم تم وضع غرسات لكل مريض في موضع الضواحك لتقييم معدل البقاء من وقت وضع الاستعاضة والمتابعة لمدة 6 اشهر ونسبه وسنه ونصف بعد وضع الغرسات.

**النتائج:** لا يوجد فرق احصائيا في مستوي العظام الهامشي باستخدام للاطقم الجزئية كينيدي 1 المدعّم بالزرعات مقابل المدعّم بالاسنان والزرعات معا. الخلاصه: استخدام الغرسات السنيه يساعد في دعم للاطقم الجزئية كينيدي 1.

**الكلمات المفتاحيه:** طقم اسنان جزئي، اتصال بين السنه وزرعات السنيه، طقم اسنان جزئي مدعوم، كباري مثبتة